İstanbul Üniversitesi Diş Hekimliği Fakültesi Dergisi
Cilt: 48, Sayı: 2 Sayfa: 43-50, 2014

RIDGE SPLIT AND AUGMENTATION TECHNIQUE FOR THE MANAGEMENT OF ATROPHIC MAXILLA: CASE REPORT

Atrofik Maksilla Tedavisinde Kret Ayırma ve Ogmentasyon Yöntemi: Olgu Sunumu

Zekai YAMAN[1], Pınar CEBE[1], Berkay Tolga SÜER [2]

Makale Gönderilme Tarihi: 11/11/2013
Makale Kabul Tarihi: 10/03/2014

ABSTRACT

The success of dental implant treatment is being adversely affected by the excess alveolar crest resorption. Many techniques including bone augmentation, guided bone regeneration, ridge split and alveolar distraction techniques have been implemented successfully to overcome this problem. Ridge split technique is based on separation of the buccal and palatal cortical bone into two separate cortical plates in the horizontal plane and augmenting in between using various bone substitutes or placing implants directly. The main advantage of this technique is that it allows the augmenting bone horizontally while preserving the buccal cortical plate.

In this case report, the treatment of maxillary horizontal ridge deficiency in edentulous patient was described in steps using piezosurgery, mini-distractors and xenogenic bone substitute. Fixed prosthetic restorations were delivered at the implant placement surgery based on immediate loading protocol.

Keywords: *Ridge split, maxillary alveolar distraction, mini-distractor, piezosurgery, dental implant*

ÖZ

Dental implant tedavisinin başarısı alveolar kretin aşırı rezorpsiyonlardan olumsuz etkilenir. Kemik greftleme yöntemleri, yönlendirilmiş kemik rejenerasyonu, kret ayırma ve alveoler distraksiyon teknikleri bu problemin çözümü için başarıyla uygulanmaktadır. Kret ayırma-genişletme yöntemi, bukkal ve palatal kemik kortekslerini horizontal yönde iki kortikal laminaya ayırarak (ridge split) inley tarzda çeşitli kemik greftleri veya doğrudan implant yerleştirilmesi esasına dayanır. Tekniğin en önemli avantajı, bukkal kortikal tabakanın korunarak, kemiği horizontal yönde genişletmeye izin vermesidir.

Bu olgu sunumunda, üst çenesi total dişsiz olan hastada, maksiller alveoler kretin horizontal yöndeki yetersizliğinin piezocerrahi aygıt, mini-ekspandır ve ksenojenik kemik grefti kullanarak rehabilitasyonu basamaklar halinde anlatılmıştır. Cerrahi girişimler ile aynı seansta yerleştirilen implantlar hemen yükleme prensipleri uyarınca yüklenerek sabit protetik restorasyonları tamamlanmıştır.

Anahtar kelimeler: *Kret ayırma, maksilla alveoler ekspansiyon, mini-ekspandır, piezocerrahi, dental implant*

1. Amerikan Hastanesi Ağız ve Diş Sağlığı Bölümü, Nişantaşı, İstanbul.
2. GATA Haydarpaşa Eğitim Hastanesi, Ağız, Diş ve Çene Cerrahisi Bölümü, Üsküdar, İstanbul.

Introduction

Today in dentistry, the primarily preferred technique for the replacement of missing teeth and for the rehabilitation of oral functions is the implant-supported fixed prosthetic restorations. Following the loss of natural teeth, a quick resorption occurs in alveolar ridges, being more distinct in the first 6 months and as a result, there might not be enough volume of residual bone to allow for inserting dental implants. It is known that the alveolar bone resorption starts first in horizontal and then in vertical direction and that it is seen more pronounced on the buccal than the palatal/lingual surface of the alveolar ridge (1).

For cases when there is not enough volume of bone to place dental implants in the alveolar ridges, the augmentation methods described as implant preparation surgery and intended to increase the bone volume have been defined (2, 3). Among the fundamental techniques can be counted the methods of inlay or only autogenous bone augmentation (4); guided bone regeneration (GBR) (5, 6); alveolar distraction (7), as well as ridge splitting and augmentation (8-10). It has been reported that, in selected cases where the vertical bone volume is preserved but the horizontal volume is not sufficient, the ridge splitting and augmentation techniques can be successfully implemented (11).

The ridge splitting and augmentation method can be deployed in cases where the alveolar ridge is as wide as 3-5 mm and as high as 8-10 mm (12). The technique is based on splitting the alveolar ridge into two cortical plates as buccal and palatal/lingual in corono-apical direction in a depth of 6-8 mm starting from the top of the ridge. The buccal and palatal/lingual segments are not completely separated from the base during the splitting, and the apical connection is preserved in the form of green stick fracture. The ride split technique is mainly used in maxilla, while it is rarely preferred due to the extremely cortical structure of the mandible. The technique can be applied in single step, which involves splitting of ridges and placement of implants; and in two steps involving splitting of ridges and a waiting period of 4-6 months following the augmentation before implant placement surgery (12). The piezoelectric surgical devices implemented for conducting bone osteotomy through the use of micrometric ultrasonic vibrations have been widely used in recent years in maxillofacial surgery. Its biggest advantages are that it allows for cutting with micrometric sensitivity while cutting hard tissues, it offers a clear vision of the surgical site due to its cavitation effect, it does not cause any damage to the soft tissues while performing these cuts, and that the bone tissue heals more quickly and seamlessly, after the cuts made by piezosurgery device (13, 14).

Starting from the treatment planning, this article presents in steps the ridge split-expansion and xenogenic bone augmentation method, which we implemented by using piezosurgery device and mini-expanders in an edentulous patient.

Case Report

The 63-year-old female patient applied to our clinic with the demand of fixed prosthesis for her totally edentulous maxilla. The patient's past medical history showed that there was no systemic problem, and the clinic and radiologic examinations showed that the alveolar ridge volume was adequate in vertical direction but it wasn't adequate in horizontal direction for endosseous implant placement. According to the Computed Tomography (CT) scan views, the width of the alveolar ridge was between 3-5 mm (Figure 1, 2).

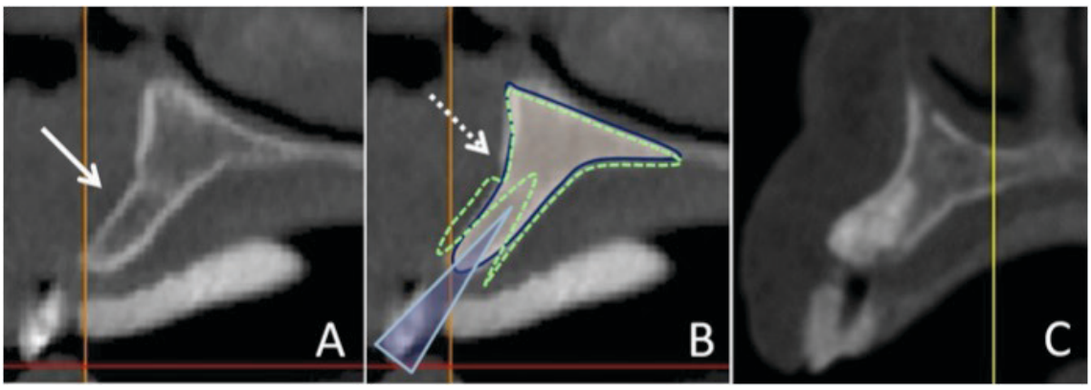

Figure 1. In axial CT view, the alveolar crest was observed to be insufficient in the horizontal direction (white arrow) (A), the schematic drawing shows the ridge split technique planned to be applied (B), the axial CT view reflecting the appearance of substitute after the ridge split and then augmentation with xenograft (C).

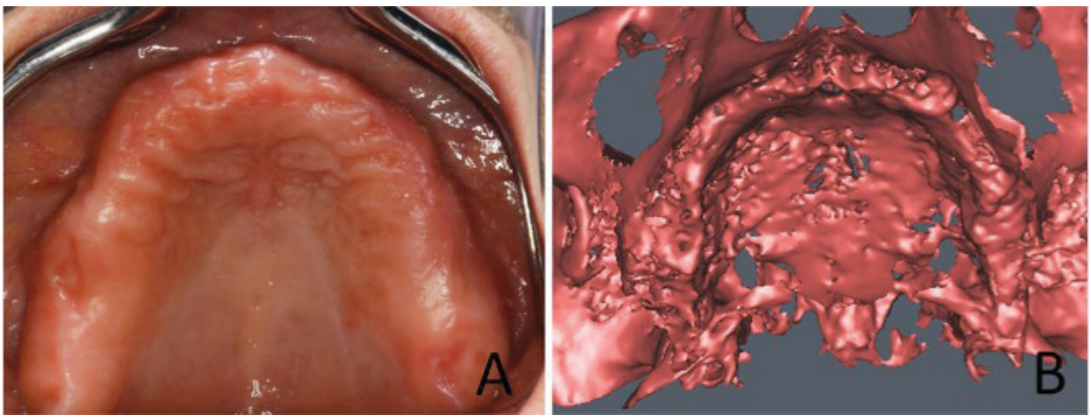

Figure 2. Clinic and 3D-CT constructed view of patient's edentulous maxilla.

In order to be able to apply implant supported fixed prosthesis to the patient, ride split-expansion and bone augmentation had to be made in the whole arch of maxilla.

Surgical Technique

Under local anesthesia, full thickness mucoperiosteal incision was made in a manner so that they would remain in 1 mm palatal of alveolar ridge, but the mucoperiosteal flap was not reflected (Figure 3A). Following the line of mucosal incision, the insert of the piezoelectric device (Piezosurgery II, Mectron, Italy) was placed in the mucosal incision line till the tip of the insert reached to the top of the alveolar crest and then the crestal bone was cut horizontally through saw insert (OT2) (Figure 3B). The depth of the bone cut was adjusted with the help of depth line marks found on saw insert.

Mini-expanders were used for adjusting the alveolar ridges horizontally (Mr. Curette Tech, Korea). The wings of expanders placed inside the bone with their edges closed were opened step by step to ensure a controlled ridge expansion in bucco-palatal direction. We continued on horizontal expansion through the whole arch (Figure 3C).

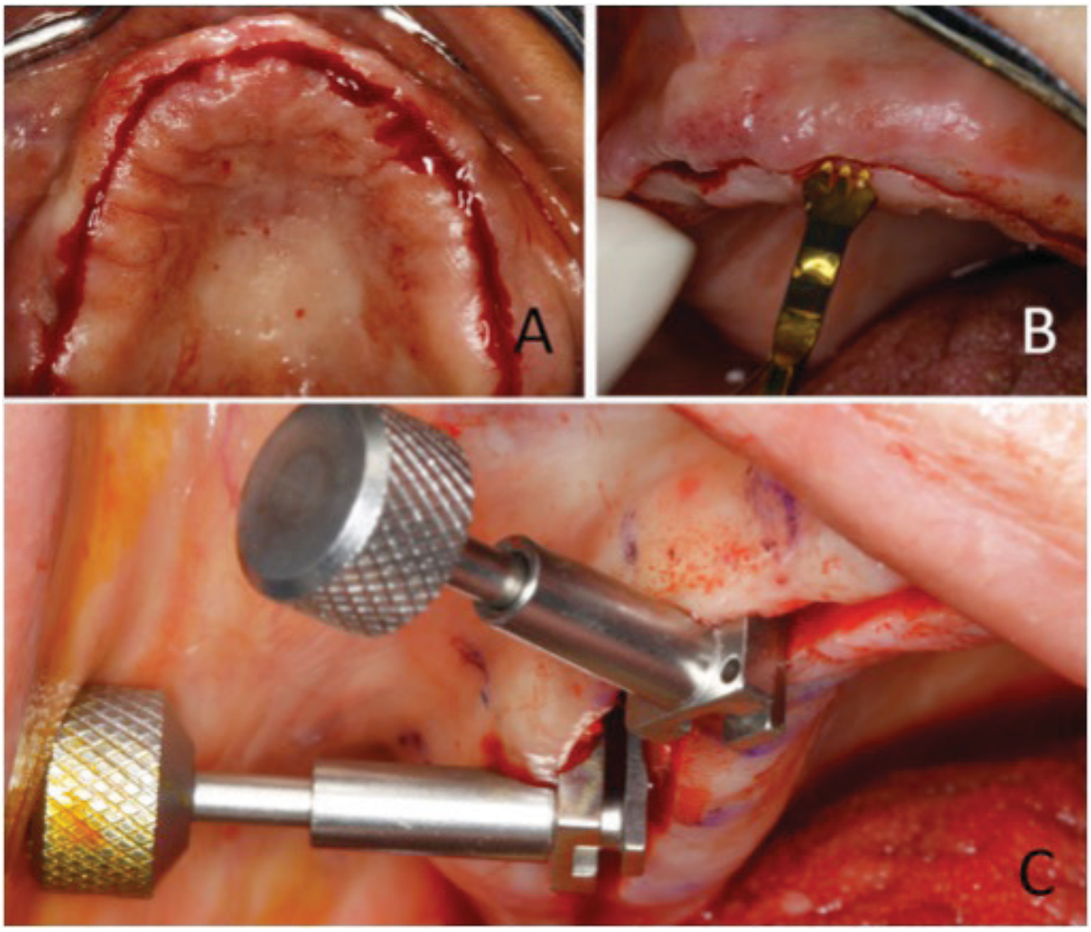

Figure 3. A) Full thickness mucoperiosteal incisions were made in a manner so that they would remain in 1 mm palatal of alveolar ridge crest, B) Following soft tissue incision, horizontal bone cuts were performed through saw insert (OT2), C) use of mini-expanders for horizontal splitting of alveolar ridges.

In parts where horizontal expansion was achieved, xenogeneic bone substitute obtained from bovine (Cerabone, Botiss, Germany) were used as augmentation material in inlay manner. Bone grafts were covered by oxidized cellulose polymer (Surgicel, Ethicon, USA). Following the expansion of alveolar ridge in the direction of buccopalatal (Figure 4A), the soft tissues were kept together through interrupted sutures and left for secondary healing (Figure 4B). Following a healing period of 4 months for the consolidation of one augmentation and healing of wound, dental implant treatment planning was initiated (Figure 4C).

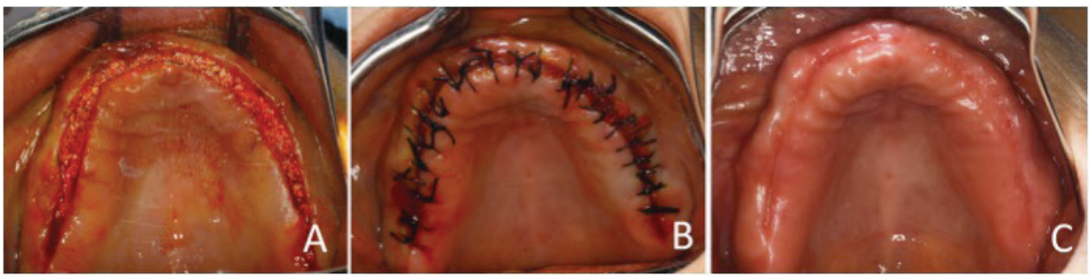

Figure 4. Following the expansion of alveolar ridge in bucco-palatal direction the spaces created by expansion were filled with xenograft. Bone grafts were covered by oxidized cellulose polymer (Surgicel, Ethicon, USA) (A), the soft tissues were hold together with nterrupted sutures and left to secondary healing (B). The clinical view of the patient after a healing period of 4 months (consolidation of bone augmentation) and uneventful wound healing (C).

The CT images of the patient were inspected in implant planning program to plan the fixed prosthesis in maxilla (Figure 5A). Surgical stent was used to place dental implants according to flapless surgical method (Implant Direct, Legacy, USA) (Figure 5B). Implant stability was evaluated through insertion torque value (ITV) and implant stability quotient (ISQ).

The implant stability quotient values (ISQ) and the insertion torque values (ITV) were interpreted in combination and it was concluded that the implants were suitable for immediate functional loading through temporary crowns. The abutments were placed on the implant fixtures with screws (Implant Direct, Legacy Implant System). The laboratory studies were completed within 24 hours and the plastic crowns were temporarily cemented (Figure 5C).

Figure 5. CT views were reviewed using implant program to plan the fixed prosthesis in maxilla (A). The implants were placed by flapless method using surgical stent (B). The laboratory studies were completed within 24 hours and the plastic crowns were temporarily cemented (C).

Following a waiting period of six months, the permanent restorations were delivered through cemented, 3-zirconia bridges. The control panoramic radiography indicated that the implant and prosthetic structured had a satisfying concordance. Through endosseous dental implant placement, the totally edentulous case was satisfactorily treated with fixed prosthetic restorations (Figure 6).

Figure 6. After 13 months of ridge split and bone augmentation surgery, the ¾ profile (left), and clinical pictures (right top) and panoramic radiography (right bottom) of the patient.

Discussion

Ride split technique is based on splitting of edentulous alveolar ridge into two cortical plates as buccal and palatal/lingual through a sagittal cut and expansion of it in buccal direction by use of various instruments. It has been reported that if the restrictions of technique is understood well and if it is applied accurately, it might be alternative to other methods such as guided bone regeneration (GBR) or block bone grafting (15-17).

It is accepted as prerequisite for ride split technique that the ridge width must be at least 3 mm in horizontal direction, and at least 8 mm in vertical direction (15). According to the Jensen et al. (12), in cases when the alveolar ridge width is below 3 mm, the splitting procedure will result in unfavorable fractures of the plates, due to the fact that, in such cases, the buccal and palatal cortical plates conjoin to include to medullar bone tissue in between them. For the same reason, as in mandibular ridges, the technique has limited usage in compact bone fields. On the other hand, the splitting technique is not convenient for ridges with irregular alveolar defects or excessive vestibular protrusion, GBR or onlay grafting methods can be preferred. Jensen and Ellis (18) developed "book bone flap" technique as alternative for irregular ridge defects. In such technique, as different from the standard method, the buccal cortical bone is separated from the alveolar base with periosteal connections preserved and it repositioned as desired.

In ridge split technique, in bone cuts made in sagittal direction along with the ridge, manual tools such as osteotome or rotary instruments such as diamond disc and fissure burr are used as standard of care. In recent years, however, the device developed by Vercollotti, namely piezosurgery and operating according to piezoelectric ceramic principles

and able to perform bone cut with micron sensitivity have been preferred (13, 19). The piezosurgery device is primarily preferred in bone surgery also by the authors of this study (13, 14, 19-22).

In ride split technique, as different from the block bone grafting, there is no need for a second surgical field. It has been reported that since the loose cancellous bone is pressed during the procedure, they attain a more compact structure and the tendency of buccal cortical plate to turn into its former position contributes to the primary stability of implants. As a result of 5 years long follow-up of 97 implants placed trough the ride split technique, Engelke et al. (15) reported less postoperative infection compared to the GBR technique supported by membrane, in addition to a cumulative success rate of 86.2%. In their literature reviews, Aghaloo and Moy (11) looked at various augmentation techniques and determined that the implant success rate was 95.5% in GBR technique, 90.4% in onlay graft technique and 94.7% in distraction osteogenesis technique. Chiapasco et al. (3) reported the survival rate of implants placed by ride split technique was between 91% and 97.3% (94 at average), and implant success rate as between 86.2% and 97.5% (95.5 at average). In their clinic studies, González-García et al. (17) found that the average "implant stability quotient" (ISQ) of implants placed by ridge split technique was 69.48, and the implant survival rate was 100%.

Conclusion

The ridge split technique is a reliable method and its application yields predictable results for horizontal augmentation of narrow ridges in anterior region of maxilla. Having chosen right cases, it allows for placing dental implant in the same session. Especially with the development of piezosurgery inserts and alternative equipments, it may have a widespread area of usage in implant dentistry in years ahead.

REFERENCES

1. Araújo MG, Lindhe J. Dimensional ridge alterations following tooth extraction. An experimental study in the dog. J Clin Periodontol 2005;32(2):212-8.
2. Esposito M, Grusovin MG, Kwan S, Worthington HV, Coulthard P. Interventions for replacing missing teeth: bone augmentation techniques for dental implant treatment. Cochrane Database Syst Rev 2008;16(3):CD003607.
3. Chiapasco M, Casentini P, Zaniboni M. Bone augmentation procedures in implant dentistry. Int J Oral Maxillofac Implants 2009;24 Suppl:237-59.
4. Jensen SS, Terheyden H. Bone augmentation procedures in localized defects in the alveolar ridge: clinical results with different bone grafts and bone-substitute materials. Int J Oral Maxillofac Implants 2009;24 Suppl:218-36.
5. Nyman SR, Lang NP. Guided tissue regeneration and dental implants. Periodontol 2000 1994;4:109-18.
6. Jovanovic SA, Nevins M. Bone formation utilizing titanium-reinforced barrier membranes. Int J Periodontics Restorative Dent 1995;15(1):56-69.
7. Chin M. Distraction osteogenesis for dental implants. Atlas Oral Maxillofac Surg Clin North Am 1999;7(1):41-63.
8. Simion M, Baldoni M, Zaffe D. Jaw bone enlargement using immediate implant placement associated with a split-crest technique and guided tissue regeneration. Int J Periodontics Restorative Dent

1992;12(6):462-73.
9. Scipioni A, Bruschi GB, Calesini G. The edentulous ridge expansion technique: a five-year study. Int J Periodontics Restorative Dent. 1994;14(5):451-9.
10. Chiapasco M, Ferrini F, Casentini P, Accardi S, Zaniboni M. Dental implants placed in expanded narrow edentulous ridges with the Extension Crest device. A 1-3-year multicenter follow-up study. Clin Oral Implants Res 2006;17(3):265-72.
11. Aghaloo TL, Moy PK. Which hard tissue augmentation techniques are the most successful in furnishing bony support for implant placement? Int J Oral Maxillofac Implants 2007;22 Suppl:49-70.
12. Jensen OT, Kuhlke KL, Cottam J, Foley BD. Maxillary alveolar split horseshoe osteotomy. In: Jensen OT (Ed). The osteoperiosteal flap. A simplified approach to alveolar bone reconstruction. Chicago: Quintessence Books, 2010, p.189-201.
13. Yaman Z, Suer BT. Piezoelectric surgery in oral and maxillofacial surgery. Annals of Oral&Maxillofacial Surgery 2013;1(1):1-9.
14. Yaman Z, Suer BT, Cebe P, Keles M. Piezosurgical excision of a large maxillary odontoma. In: Ronchi P (editor): XVII Congresso Nazionale della Societa Italiana Chirurgica Maxillo-Facciale (SICMF). Medimond International Proceedings 2011, p.417-21.
15. Engelke WG, Diederichs CG, Jacobs HG, Deckwer I. Alveolar reconstruction with splitting osteotomy and microfixation of implants. Int J Oral Maxillofac Implants 1997;12(3):310-8.
16. Oikarinen KS, Sàndor GK, Kainulainen VT, Salonen-Kemppi M. Augmentation of the narrow traumatized anterior alveolar ridge to facilitate dental implant placement. Dent Traumatol 2003;19(1):19-29.
17. González-García R, Monje F, Moreno C. Alveolar split osteotomy for the treatment of the severe narrow ridge maxillary atrophy: a modified technique. Int J Oral Maxillofac Surg 2011;40(1):57-64.
18. Jensen OT, Ellis E. The book flap: a technical note. J Oral Maxillofac Surg 2008;66(5):1010-4.
19. Vercellotti T. Essentials in piezosurgery. Clinical advantages in dentistry. Milan: Quintessence Int. Books, 2009; p.95-107.
20. Yaman Z. Piezoelektrik ultrasonik aygıtların ağız cerrahisi ve implantolojide klinik uygulamaları. Dişhekimliğinde Estetik ve Implant 2009;14:26-33.
21. Yaman Z, Suer BT. Clinical efficiency of piezoelectric devices for harvesting of ramus bone graft. Presentation. 2nd Balkan Association of Maxillofacial Congress (BAMFS) and 5th Oral and Maxillofacial Surgery Society (ACBID) Conference 25-29 May 2011, Antalya, Turkey.
22. Yaman Z. Maksiller sinüs kemik greftleme operasyonlarında piezocerrahi aygıtların kullanımı. Quintessence Türkçe 2010;2:17-28.

Corresponding Author:
Berkay Tolga SÜER
Ağız, Diş ve Çene Cerrahisi
GATA, Haydarpaşa Eğitim Hastanesi,
Diş Hekimliği Bölümü,
Tıbbiye Caddesi, Selimiye Mahallesi,
Üsküdar/İstanbul, 34668.
Tel: 0 216 5422020-4622
e-mail: berkaysuer@gmail.com