EJMI

DOI: 10.14744/ejmi.2021.49333
EJMI 2021;5(3):329–333

Research Article

Histopathological Effects of Boric Acid Solution on Middle Ear Mucosa in Guinea Pigs

Ahmet Yukkaldiran,[1] Riza Dundar,[2] Tarik Yagci,[2] Yilmaz Ozkul,[3] Demet Etit,[3] Servet Erdemes[4]

[1]Department of Otorhinolaryngology, Sanliurfa Training and Research Hospital, Sanliurfa, Turkey
[2]Department of Otorhinolaryngology, Bilecik Training and Research Hospital, Bilecik, Turkey
[3]Department of Otorhinolaryngology, Izmir Katip Celebi University, Ataturk Training and Research Hospital, Izmir, Turkey
[4]Department of Otorhinolaryngology, Siverek State Hospital, Sanliurfa, Turkey

Abstract

Objectives: In this study, we aimed to histopathologically reveal the effects of 4% boric acid solution used in diseases such as external otitis and otomycosis, in which the tympanum and tympanic membrane do not participate in the infection process, on the healthy tympanic mucosa.

Methods: A, B, C, D group guinea pigs were administered 4% boric acid solution for 7, 14, 21, 28 days respectively. The tympanic bullae of group A, B, C, D guinea pigs were excised on the 8,15, 22,29 days respectively.

Results: While 5 of the samples taken from the right tympanic bullae of group A were grade 2 and 1 was grade 3, all of the samples taken from the right tympanic bulla of the subjects in group B were grade 3, all samples taken from the right tympanic bullae of the subjects in group C were grade 4, and all of the right tympanic bullae of the subjects in group D were grade 4 regarding the histopathological changes.

Conclusion: We determined that the use of 4% boric acid solution for more than 1 week in cases accompanied by tympanic membrane perforation such as chronic otitis media led to an increase in the inflammation score and histopathological changes in the tympanic mucosa.

Keywords: Boric acid, Histopathologically, Inflammation score, Guinea pig, Tympanic bullae

Cite This Article: *Yukkaldiran A, Dundar R, Yagci T, Ozkul Y, Etit D, Erdemes S. Histopathological Effects of Boric Acid Solution on Middle Ear Mucosa in Guinea Pigs. EJMI 2021;5(3):329–333.*

Chronic suppurative otitis media (CSOM) is an important and common cause of hearing impairment in low- and middle-income countries.[1] CSO is defined as persistent tympanic membrane perforation and ear discharge lasting more than two weeks. Among the treatment options, systemic antibiotics, topical steroids and antibiotics, and antiseptic drops are preferred.

In a Cochran Review[2] published in 1998, it was concluded that topical treatment with antibiotics or antiseptics was more effective than systemic antibiotics, aural wash only, or no treatment. In the same study, topical quinolones were better than non-quinolone topical antibiotics. Topical antiseptic treatments such as boric acid and burow solutions have been found in many treatment protocols as appropriate treatment methods in terms of both their efficacy and cost.[3] The most commonly used treatment in CSOM is ototopical antimicrobial drops. In the treatment of ear infections, the low absorption of systemic drugs in the ear and administered drugs in the resistance of microorganisms to antibiotics support the preference of lo-

Address for correspondence: Ahmet Yukkaldiran, MD. Sanliurfa Egitim ve Arastirma Hastanesi Kulak Burun Bogaz Anabilim Dali, Sanlıurfa, Turkey
Phone: +90 507 845 88 62 **E-mail:** ayukkaldiran@gmail.com

Submitted Date: June 14, 2021 **Accepted Date:** August 23, 2021 **Available Online Date:** September 22, 2021

©Copyright 2021 by Eurasian Journal of Medicine and Investigation - Available online at www.ejmi.org
OPEN ACCESS This work is licensed under a Creative Commons Attribution-NonCommercial 4.0 International License.

cal treatment options.[4-6] Topical agents can pass through the tympanic membrane at high levels and are commonly used in chronically infected ears.[7] As a topical agent, boric acid solutions have antiseptic and acidic properties and are used in the treatment of CSOM. Few studies have been conducted to examine the use of such solutions in patients with CSOM.[8-9] Apart from CSOM, these solutions, which are used in diseases of the auricle and external auditory canal for their antimicrobial and acidic properties, are among the preparations frequently used, especially in the treatment of otomycosis. In cases where the tympanic membrane is perforated, the safety of solutions prepared with alcohol is controversial, but its ototoxic effect in humans has not been proven.

In this study, we aimed to histopathologically reveal the effects of 4% boric acid solution used in diseases such as external otitis and otomycosis, in which the tympanum and tympanic membrane do not participate in the infection process, on the healthy tympanic mucosa, by investigating on guinea pigs, and whether the effect will be reversible for certain periods.

Methods

At the beginning of our study, experimental animal study approval was obtained from the Animal Ethics Committee of DOLLVET A.Ş, and all animals included in the study were treated as per the protocols accepted by this committee. The surgical phase of the study and the optimum care of the experimental animals were completed in the DOLLVET VETERINARY VACCINE, PHARMACEUTICALS, and experimental animal breeding unit. In our study, a total of 8-week old 24 guinea pigs weighing between 300 and 1000 g were used. The right ears of all guinea pigs were determined as the experimental group, and a 4% boric acid solution prepared with distilled water was applied to the right ear. The left ears of the subjects were determined as the control group, and 0.9% NACI saline was administered. Guinea pigs were divided into four groups, with 6 in each group. Groups were named as A, B, C, D. Before starting the surgical procedure, both ears of the guinea pigs were evaluated under a Carl-ZEISS Opmi-9FC microscope, the plugs were cleaned, and those with middle ear or EAC infections were excluded from the study. Anesthesia was provided with intraperitoneal xylazine (Bacilazine, 5 mg/kg; Animedica GmbH, Senden-Bosensell, Germany) and Ketamine (Ketalar, 50 mg/kg; Eczacıbaşı, Warner-Lambert, İstanbul, Turkey). The tympanic membranes of the guinea pigs were widely perforated under the microscope with the help of a fine spike without damaging the middle ear mucosa. In order not to close the perforated area, sponges were placed in contact with the middle ear mucosa. This procedure was performed for both ears of all guinea pigs. 4% boric acid solution prepared with distilled water was applied two times a day to the right ear of the guinea pigs with the help of an insulin injector, 3-4 drops each time. 0.9% NACI saline was applied to the left ears by the same method, dose, and duration. A and B group guinea pigs were administered for 7 and 14 days, respectively, and C and D group guinea pigs were administered for 21 and 28 days. Sacrification of guinea pigs was performed by applying 80 mg/kg pentothal. The tympanic bullae of group A and B guinea pigs were excised on the 8th and 15th days, and the tympanic bullae of group C and D guinea pigs were removed on 22nd and 29th days, respectively. Appropriately removed tympanic bullae underwent a series of procedures for histopathological examination. The prepared tissue samples were examined in terms of vascular occlusion, edema, and the presence of inflammatory cells and graded as follows; Grade 1 normal histological tissue image, Grade 2 mild vascular occlusion, and edema, no inflammatory cells, Grade 3 moderate vascular occlusion and edema, very few inflammatory cells are present, and Grade 4 severe vascular occlusion and edema, with numerous inflammatory cells. The inflammatory process was evaluated by observing the vascular occlusion, the density of inflammatory cells, and edema. If there was no inflammation in the evaluated samples, it was scored as 1 (+). It was scored 2 (++) in the presence of mild inflammation, 3 (+++) in the presence of moderate inflammation, and 4 (++++) in the presence of severe inflammation.

Statistical Analysis

Data were analyzed using the Statistical Package for Social Sciences 26.0 for Mac (SPSS Inc., Chicago, IL). A normal distribution of the quantitative data was examined via Kolmogorov–Smirnov, and Shapiro–Wilk tests. Non-parametric tests were applied to data of questionably normal distribution. Mann–Whiney U tests were used to compare independent groups. Kruskal–Wallis H test was used to compare groups of independent continuous variables, and Bonferroni post hoc analysis was used for multiple comparison tests. Data are expressed as mean±standard deviation. The results for all items were expressed within a 95 % reliance and at a level of $p<0.05$ significance.

Results

Histopathological changes were detected in the samples excised from the right tympanic bullae of 6 guinea pigs in group A, which were excised on the 8th day. Five had a grade 2 (Fig. 1), and one had grade 3 (Fig. 2) histopathological changes. All of the samples removed on the 15th day, excised from the right tympanic bullae of the subjects in group B, showed grade 3 histopathological changes.

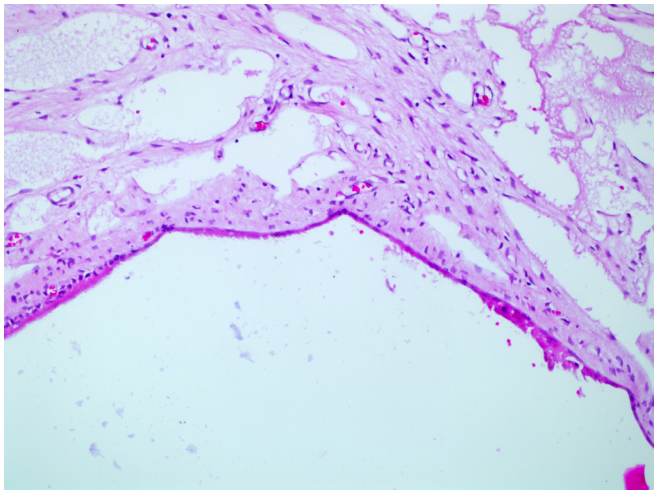

Figure 1. Grade 2 histopathological change in tympanic bulla.

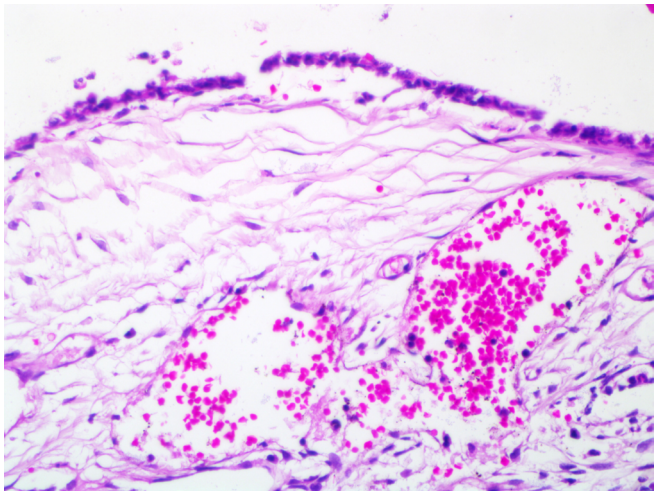

Figure 2. Grade 3 histopathological change in tympanic bulla

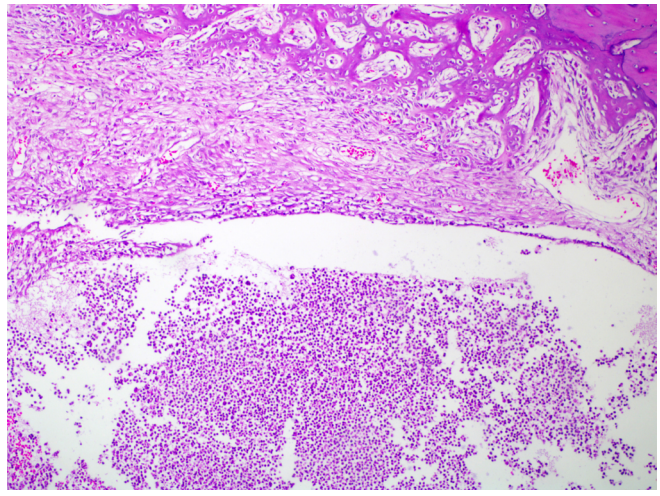

Figure 3. Grade 4 histopathological change in tympanic bulla.

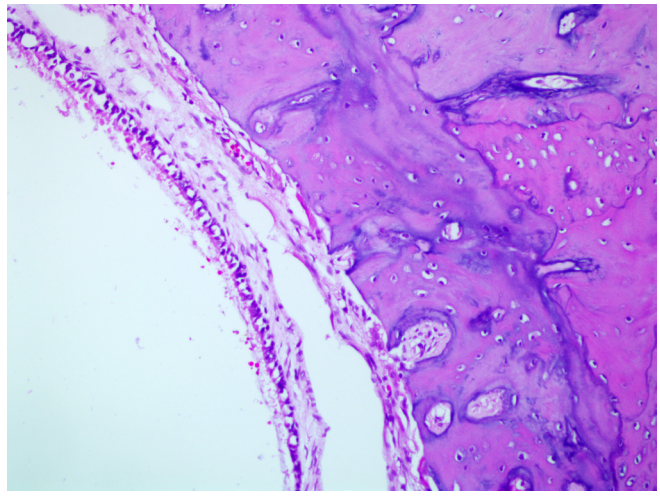

Figure 4. Grade 1 histopathological change in tympanic bulla.

Grade 4 (Fig. 3) histopathological changes were detected in all samples taken from the right tympanic bullae of the subjects in group C, which were excised on the 22nd day. Histopathological changes at grade 4 (Fig. 3) were detected in all of the right tympanic bullae excised on the 29th day of the subjects in group D. Grade 1 (Fig. 4) histopathological changes were observed in all left tympanic bullae of group A, which were excised on the 8th day, group B on the 15th day, group C on the 22nd day, and group D on the 29th day. When the inflammation scores of the four groups were compared, the inflammation score of group A was lower than that of groups C and D and was statistically significant when comparing the right tympanic bullae (p=0.001). A comparison of the right tympanic bullae of the groups is shown in Figure 5. In comparing the right and left tympanic bullae of each group, the inflammation scores on the right were higher than on the left (p=0.02). There was no

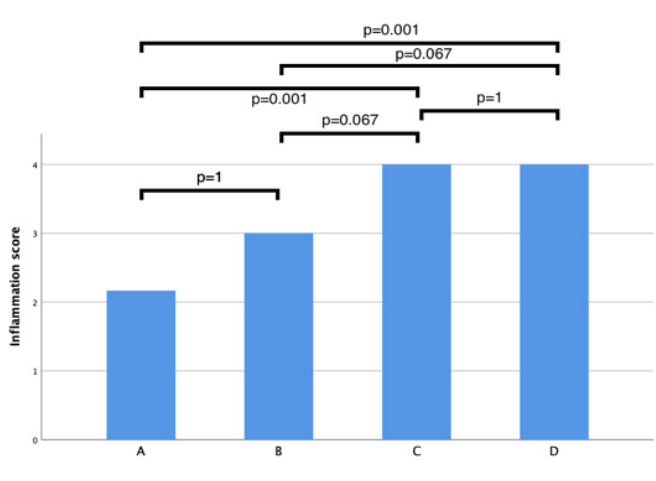

Figure 5. The simple bar graph represents the mean inflammation score of the right tympanic bulla of the groups. The p values for the comparison of the groups are given.

significant difference between the groups when comparing the left tympanic bullae of the groups (p> 0.05). Inflammation scores of the right and left tympanic bulla groups are shown in Table 1.

Discussion

Ear drops are used in the treatment of external otitis and middle ear infection accompanied by tympanum perforation. Otorrhea is a common otological problem that is usually treated with topical antibiotic preparations.[10] Antiseptic drops (e.g., boric acid solution, aluminum acetate) are widely preferred to treat CSOM in developing countries due to their wide availability and low cost. The purpose of topical antiseptic drops is to create an acidic environment by changing the alkaline environment in the ear and preventing the easy proliferation of outer ear and tympanic bacteria and the acidic environment. It was reported that after the application of the topical antiseptic solution to the tympanum, some patients with CSOM experienced complaints such as pain and burning. Although topically applied antibiotics are not more effective than topical antiseptics, combined topical treatment with antibiotics and antiseptics is more effective than systemic treatment.[11] Boric acid is formed as a result of the reaction of borate minerals with sulfuric acid. The pKa of this chemical is 9.24, and this chemical is found in nature as a white, crystalline powder. In 1948, salts of boric acid and sodium borate were used for the first time in the United States as an insecticide and pesticide. The use of boric acid in medicine is quite common; besides being used as an eyewash solution, it is also used as an antiseptic for minor cuts and burns. Boric acid solutions have acidic properties and antiseptic properties and are frequently used for these purposes.[12] It is used in the treatment of external ear infections, CSOM with cholesteatoma, otomycosis, and tympanum infections. Ozcan et al. reported that 4% boric acid solution prepared with 70% alcohol is an effective and inexpensive treatment option in the treatment of otomycosis as well as local cleaning of the ear and reported that they used 4% boric acid solution prepared with distilled water or alcohol by taking advantage of the acidic and antiseptic properties of boric acid solution in their clinics, especially in otomycosis, CSOM with cholesteatoma, and external ear infection.[13] Minja et al. used boric acid solution prepared with 70% alcohol in the treatment of children diagnosed with suppurative otitis media, and it was reported that boric acid solution prepared with alcohol solution was effective in the treatment of these patients.[12] There are also studies reporting that boric acid solution is less effective than other topical ear drops in the treatment of CSOM. For example, Macfadyen et al. found that topical ciprofloxacin ear drops were more effective than the topical boric acid solution in treating children with CSOM diagnosis, improving both discharge and hearing at second and fourth weeks. They also reported that the use of topical ciprofloxacin compared to boric acid had significantly fewer side effects such as ear pain, irritation, and bleeding during ear cleaning.[14]

Table 1. Inflammation scores of the groups

Group	Number	Right	Left	P
A	6	2.2±0.4	1.0±0.0	0.02
B	6	3.0±0.0	1.0±0.0	0.02
C	6	4.0±0.0	1.0±0.0	0.02
D	6	4.0±0.0	1.0±0.0	0.02

Our study aimed to histopathologically reveal the effects of 4% boric acid solution prepared with distilled water on the guinea pig tympanic mucosa. Hence, we wanted to determine whether its use in otomycosis, external otitis infections where the tympanum is not involved in the process, causes temporary or permanent damage to the tympanic mucosa, the inflammatory response of the tympanic mucosa and whether the duration of use of boric acid solution also contributes to this possible effect. In anatomical studies, it was revealed that the structural form of the pig tympanum and the human tympanum are very similar to each other.[15] Therefore, guinea pigs were used in our study. Inflammation is an adaptive response triggered by harmful stimuli such as infection and tissue damage.[16] Histopathological changes can be observed in body tissues as a result of long-term infections. In the inflammatory response triggered by infection or tissue damage, blood elements such as plasma and leukocytes move to the injury site. In the inflammatory response, mediators such as various cytokines and chemokines are secreted initially; these mediators' main and immediate first effect is to produce inflammatory exudate. Thanks to these mediators, they provide access to extravascular tissues by providing the extravasation of plasma proteins and leukocytes (neutrophils) typically found in blood vessels.[16] Neutrophils try to kill invading substances by secreting various agents. Due to this strong effect of neutrophils, damage to the host tissue is inevitable.[17] In the literature review, experimental studies are investigating the ototoxic effects of boric acid solution on inner ear functions.[18-20] However, no experimental study has been performed on the tympanic mucosa in terms of histopathological changes. Our study is important because it is the first study examining the effects of 4% boric acid solution prepared with distilled water on the tympanic mucosa. Our study found the lowest inflammation score in group A due to the use of the boric acid solution prepared with distilled

water for one week. An increase in inflammation scores was observed after 2-3-4 weeks of use of the current solution in groups B, C, and D, respectively. In parallel with the increased inflammation score, especially in groups C and D, we detected histopathological changes in the middle ear mucosa indicating chronic inflammation in groups C and D. We think that a foreign body reaction against the current solution develops in long-term use of the probable boric acid solution.

Conclusion

In conclusion, we determined that the use of 4% boric acid solution prepared with distilled water for more than one week in cases accompanied by tympanic membrane perforation such as CSOM led to an increase in the inflammation score in the tympanic mucosa, and we found that it caused histopathological changes in the tympanic mucosa due to chronic inflammation. In clinical use, we recommend using 4% boric acid solution prepared with distilled water in conditions such as external otitis, external auditory canal otomycosis in which CSOM and tympanic membrane are intact, for no longer than one week.

Our study has several limitations as it is the first study to investigate the effects of topical boric acid solution on the tympanic mucosa. It should be supported by more experimental studies on animal models in the future.

Disclosures

Ethics Committee Approval: DOLLVET A.Ş. Animal Experiments Local Ethics Committee (DOLLVET-HADYEK), No: 2014/39, Date: 20.06.2014.

Peer-review: Externally peer-reviewed.

Conflict of Interest: None declared.

Authorship Contributions: Concept – A.Y., R.D.; Design – A.Y., R.D.; Supervision – A.Y., R.D., D.E., Y.O.; Materials – A.Y., R.D., S.E., D.E.; Data collection &/orprocessing – A.Y., R.D., T.Y., S.E.; Analysis and/or interpretation – A.Y., R.D.; Literature search – A.Y., R.D., Y.O., T.Y.; Writing – A.Y., R.D.; Critical review – A.Y., R.D.

References

1. Berman S. Otitis media in developing countries. Pediatrics 1995;96:126–31. [CrossRef]
2. Acuin J, Smith A, Mackenzie I. Interventions for chronic suppurative otitis media (Cochrane Review). Chichester, UK: John Wiley & Sons Ltd; 2004.
3. Paediatric Society of Papua New G. Standard treatment for common ıllnesses of children in Papua New Guinea: a manual for nurses, health extension officers and doctors. Port Moresby: PNG Department of Health; 2016. p. 1–172.
4. Supance JS, Bluestone CD. "How I do it"--otology and neurotology. A specific issue and its solution. Medical management of the chronic draining ear. Laryngoscope 1983;93:661–2.
5. Esposito S, Noviello S, Errico GD, Montanaro C. Topical ciprofloxacin vs intramuscular gentamicin for chronic otitis media. Arch Otolaryngol Head Neck Surg1992;118:842–4. [CrossRef]
6. Fairbanks DN. Topical therapeutics for otitis media. Otolaryngol Head Neck Surg 1981;89:381–5. [CrossRef]
7. Dohar JE. All that drains in not infectious otorrhea. Int J Pediatr Otorhinolaryngol 2003;67:417–20. [CrossRef]
8. U.S. Environmental Protection Agency, Office of Pesticide Programs. Reregistration eligibility decision document: boric acid and its sodium salts. EPA 738-R-93-017. Washington DC: Government Printing Office; 1993.
9. WHO. Boron, Environmental Health Criteria, 204. Geneva, Switzerland: WHO; 1998.
10. Kashiwamura M, Chida E, Matsumura M, Nakamaru Y, Suda N, Terayama Y, et al. The efficacy of Burow's solution as an ear preparation for the treatment of chronic ear infections. Otol Neurotol 2004;25:9–13. [CrossRef]
11. Verhoeff M, van der Veen EL, Rovers MM, Sanders EA, Schilder AG. Chronic suppurative otitis media: a review, Int J Pediatr Otorhinolaryngol 2006;70:1–12. [CrossRef]
12. Minja BM, Moshi NH, Ingvarsson L, Bastos I, Grenner J. Chronic suppurative otitis media in Tanzanian school children and its effects on hearing. East Afr Med J 2006;83:322–5. [CrossRef]
13. Ozcan MK, Ozcan M, Karaarslan A, Karaarslan F. Otomycosis in Turkey: predisposing factors, aetiology and therapy. Laryngol Otol 2003;117:39–42. [CrossRef]
14. Macfadyen C, Gamble C, Garner P, Macharia I, Mackenzie I, Mugwe P, et al. Topical quinolone vs. antiseptic for treating chronic suppurative otitis media: a randomized controlled trial. Clin Otolaryngol 2005;30:193–4. [CrossRef]
15. Garcia Lde B, Andrade JS, Testa JR. Anatomical study of the pigs temporal bone by microdissection. Acta Cir Bras. 2014;29 Suppl 3:77–80. [CrossRef]
16. Medzhitov R. Origin and physiological roles of inflammation. Nature 2008:24;454:428–35. [CrossRef]
17. Nathan C. Points of control in inflammation. Nature 2002;420:846–52. [CrossRef]
18. Ozdemir S, Tuncer U, Tarkan O, Akar F, Surmelioglu O. Effects of topical oxiconazole and boric acid in alcohol solutions to rat inner ears. Otolaryngol Head Neck Surg 2013;148:1023–7.
19. Aktas S, Basoglu MS, Aslan H, Ilknur AE, Dundar R, Katilmis H, et al. Hearing loss effects of administering boric alcohol solution prepared with alcohol in various degrees on guinea pigs (an experimental study) Int J Pediatr Otorhinolaryngol 2013;77:1465–8. [CrossRef]
20. Ozturkcan S, Dundar R, Katilmis H, Ilknur AE, Aktas S, Haciomeroglu S. The ototoxic effect of boric acid solutions applied into the middle ear of guinea pigs. Eur Arch Otorhinolaryngol 2009;266:663–7. [CrossRef]