ORIGINAL ARTICLE

Can formation of avascular necrosis really be prevented in Delbet type 2 femoral neck fractures?

Mehmet Sait Akar, M.D., Şeyhmus Yiğit, M.D.

Department of Orthopedics and Traumatology, Dicle University Faculty of Medicine, Diyarbakır-*Turkey*

ABSTRACT

BACKGROUND: Fractures of proximal femur are rarely seen in childhood. These fractures can result in serious complications such as avascular necrosis (AVN), coxa vara, and early closure of the femoral epiphysis. The aim of this study is to investigate retrospectively the Delbet type 2 fractures that are commonly seen and has high rates of AVN.

METHODS: Forty-two patients whose Delbet type 2 fractures were treated in our hospital between January 2009 and June 2018 were analyzed. The patients' mechanism of fracture formation, displacement of the fracture, presence of accompanying injuries, timing of surgery, open or closed reduction, whether the screws cross the epiphyseal growth plate epiphyseal line, and AVN data were analyzed retrospectively.

RESULTS: Of the 42 screened patients, 34 patients with complete follow-up graphs and files were included in the study. The mean age of the patients was 11.02 years (1–17 years old), and the mean follow-up time was 40.82 months (range 24 to 98 months). When the follow-up radiographs of the patients were examined, it was found that AVN in 9 patients (26.5%), coxa vara in 2 patients (5.9%), and non-union in 1 patient (2.9%). The AVN rate was significantly higher in patients with high-energy injuries and high fracture displacement at baseline (p=0.034 and p=0.047, respectively).

CONCLUSION: According to our findings in Delbet type 2 fractures, other than the severity of the trauma and the initial displacement of the fracture, factors related to the treatment process do not have a significant effect on the development of AVN. Age was not determined as a risk factor for the development of AVN in these patients.

Keywords: Avascular necrosis; Delbet classification; pediatric femur neck fracture.

INTRODUCTION

"True fractures of the proximal end of the femur in children are so rare that no one has a great experience of them" (Blount 1955).[1] This statement used by Blount in 1955 is still valid. Some researchers emphasized that an orthopedist may not experience a fracture of proximal femur in children throughout his life.[2] It is difficult to agree on treatment approach and complications because of the rare nature of the fractures and different aspects in the time and the technique of operations between surgeons.

Proximal femur fractures in children were divided into four subgroups by Delbet according to the location of the fracture. Pediatric proximal femoral fractures were first defined by Delbet and widespread by Colonna[3] and classified as; type I transepiphyseal, type II transcervical, type III cervicotrochanteric, and type IV intertrochanteric fracture. Type I fractures are the rarest one. Type II fractures are femoral neck fractures and complications such as avascular necrosis (AVN) and early closure of the epiphyseal plate are mostly seen in these group. For this reason, type I and type II fractures are intracapsular fractures and the two groups with the highest rates of AVN.

Proximal femoral fractures are misclassified as femoral neck fractures in the literature. Delbet type 4 and some of the type 3 cases are located away from localization, which is

Cite this article as: Akar MS, Yiğit Ş. Can formation of avascular necrosis really be prevented in Delbet type 2 femoral neck fractures?. Ulus Travma Acil Cerrahi Derg 2022;28:107-112.

Address for correspondence: Şeyhmus Yiğit, M.D.
Dicle Üniversitesi Tıp Fakültesi, Ortopedi ve Travmatoloji Anabilim Dalı, Diyarbakır, Turkey
Tel: +90 412 - 241 10 00 E-mail: seyhmusygt@gmail.com

Ulus Travma Acil Cerrahi Derg 2022;28(1):107-112 DOI: 10.14744/tjtes.2020.33568 Submitted: 18.09.2020 Accepted: 10.10.2020
Copyright 2022 Turkish Association of Trauma and Emergency Surgery

thought to impair the femoral neck and head circulation. It is clear that when Delbet type 3 and type 4 fractures are included to study, it may lead to misleading results on the prognostic factors that may affect complications such as AVN and early closure of the femoral head epiphysis. Therefore, we thought that it would be more appropriate to include only Delbet type 2 fractures in our study. The purpose of this study is to scan the risk factors that may affect the complications after femoral neck fractures (Delbet type 2), which are rare in children but have high risk of AVN, retrospectively. According to our hypothesis, complications such as AVN, coxa vara, and early epiphyseal closure depend on the severity of trauma due to the vascular damage that occurs during the trauma and cannot be changed much more with treatment.

MATERIALS AND METHODS

Thirty-four patients with complete follow-up graphs and hospital records with femoral neck fractures treated in our hospital between January 2009 and June 2018 were retrospectively analyzed. The patient data included age, gender, length of follow-up (months), mechanism of injury, presence of initial displacement, additional injury, time of operation, whether the screws cross the epiphyseal growth plate and open or closed reduction of fracture were collected from hospital records including patient's radiographs. Patients with inadequate hospital records and who were not surgically treated were excluded from the study. All patients were routinely evaluated preoperatively. Clinical examination data were reviewed.

All patients were operated under general anesthesia in a supine position, accompanied by fluoroscopy. Closed reduction was performed to displaced fractures. In case of closed reduction failure, operation continued with open reduction. Fixation was performed with two or three partially threaded screws in the patients. Pelvipedal plastering splint was performed in children under 6 years of age who could not be adapted. When adequate calluses occurred, the splints were removed and physical therapy was started.

Clinical and radiographic follow-up was performed routinely in all patients at the 2nd, 4th, 6th, and 12th weeks and 6th, 12th, and 24th months after surgery. Clinical and radiographic follow-up was continued if there was insufficient bone union. The patients were retrospectively analyzed in terms of post-operative union and AVN, early closure of the femoral head epiphysis, coxa vara, and coxa valga. AVN was classified according to the Ratliff's classification system.[1] Coxa vara was defined as neck – shaft angles of <130° and coxa valga was >150°, respectively.[4]

The patients were divided into two groups according to mechanism of injury, presence of initial displacement, open or closed reduction of fracture, whether the screws cross the epiphyseal growth plate, and time to operation. Mechanisms such as falling from height and traffic accident were Group 1, patients with simple fall and sports injury were Group 2. According to time of surgery, Group 1 is determined to be operated in the first 24 h and Group 2 was operated after 24 h. The groups separated by determined risk factors and their relationship with AVN development were analyzed statistically.

The study was approved by the Ethics Review Committee of Dicle University Faculty of Medicine, Diyarbakır, Turkey (185/04.06.2020). Informed consent was obtained from all participants. All data were obtained without a personal identification document and made in accordance with the Declaration of Helsinki regulation.

Statistical Analysis

The effects of the age of patients on AVN were statistically compared as applicable using the Student's t-test and Mann–Whitney U-test. Mechanism of injury, initial fracture displacement, times of operation, type of reduction (open or closed), fixation material, and whether screws cross the epiphyseal growth plate were statistically analyzed among patients with and without AVN. Intergroup statistics were performed using Chi-square test and Fisher's exact test for categorical variables. If $p<0.05$, null hypotheses of no difference were rejected. Statistical analysis was conducted using the IBM SPSS STATISTICS version 23 (IBM SPSS, Inc., Chicago, IL, USA).

RESULTS

The mean age of the patients was 11.02 years (range, 1–17 years), nine of the patients were female and 25 were male. The average follow-up was 40.82 months (range 24–98 months). While 24 (70.6%) of the patients had a history of severe trauma such as a traffic accident and falling from high, 10 of them (29.4%) had a basic trauma history. Displacement that might require reduction initially was determined in 19 of the patients (55.9%). Additional injury was detected in 8 (23.5%) of the patients (Table 1). According to operation data; 30 (88.2%) of the patients were operated in the first 24 h and 4 (11.8%) of the patients were operated after 24 h. Closed reduction and internal fixation (CRIF) was performed in 27 (79.4%) of the patients, and open reduction and internal fixation (ORIF) in 7 of them (20.6%).

According to the follow-up radiographs of the patients, AVN was detected in 9 of the patients (26.5%), coxa vara was detected in 2 of the patients (5.9%), and non-union of the fracture was detected in 1 of the patients (2.9%). All of these complicated patients have a history of high-energy injuries. The rate of AVN was significantly higher in patients with high-energy injuries ($p=0.034$). Initial displacement is a statistically significant risk factor for the development of AVN ($p=0.047$) (Table 2).

Table 1. Associated injuries

Gender/Age	Injury mechanism	Associated injuries
10 / Male	Fall	Clavicle fracture
15 / Male	Fall	Distal Radius fracture
7 / Male	Fall	Nasal fracture
12 / Male	Traffic accident	Calcaneus fracture + Crush foot injury
7 / Male	Fall	Olecranon fracture
2 / Female	Fall	Distal femur fracture + iliac fracture + ankle fracture
16 / Female	Fall	Olecranon fracture
16 / Male	Traffic accident	Hemothorax + liver and spleen laceration

The mean age of the patients who developed AVN was 11.33 (7–14) and the mean age of the other group without AVN was 10.92 years. There was no significant difference between the ages of patients with and without AVN (p=0.875). Two of the patients who developed AVN were older than 12 years.

According to the follow-up radiographs of the patients with AVN, the development period of AVN was within the first 12 months (8–12 months) in five of the patients and after 12 months (13–15 months) in four of the patients (Fig. 1). It was observed that AVN occurred earlier in patients with increased displacement radiological. It was detected that coxa vara could be observed radiographically in two patients between the 22nd and 24th months. AVN was accompanied in one of the patients who developed coxa vara. Non-union was detected in one patient. It was operated again and union was achieved.

All 9 patients who developed AVN were patients who underwent closed reduction. However, there was no significant difference between open and closed reduction on the development of AVN (p=0.151). It was determined that variables such as the early or late operation of the patients (p=0.554), whether the screws cross the epiphyseal (p=0.439), and the presence of accompanying injuries (p=0.403) did not make any significant difference on the development of the AVN.

DISCUSSION

In 1962, Ratliff[1] was noted to develop AVN after pediatric femoral neck fractures and emphasized that it is impossible to predict in which patient's AVN may occur. In a meta-analysis by Moon and Mehlman,[5] 360 patients were examined and according to Delbet classification; 8.1% of the cases were found to be type 1, 40.3% of type 2, 33.3% of type 3, and 18.3% type 4 fractures. According to the Delbet classification, the AVN ratios of the groups were 38%, 28%, 18%, and 5%, respectively. Inan et al.[6] were examined proximal femur fractures in a study, and they emphasized that Delbet type 2 fractures were seen most frequently and the highest rate of AVN was found in this group. In a study conducted by Wu et al.,[7] the relationship between fracture localization and AVN was investigated, and it was determined that AVN rates in-

Table 2. Patients who develop complications

Case number	Gender/Age	Injury mechanism	Initial displacement	Ratliff type of avascular necrosis	Coxa vara	Non union	Neck shortening
1	Female/12	Fall	No	2	No	No	No
2	Male/12	Fall	No	3	No	No	Yes
3	Male/11	Fall	Yes	3	No	No	Yes
4	Male/10	Fall	Yes	1	Yes	No	Yes
5	Female/13	Fall	Yes	2	No	No	Yes
6	Male/12	Traffic accident	Yes	3	No	No	Yes
7	Female/9	Fall	Yes	–	Yes	No	Yes
8	Male/14	Traffic accident	Yes	2	No	No	No
9	Male/7	Fall	Yes	1	No	No	Yes
10	Female/11	Fall	Yes	2	No	No	No
11	Male/16	Traffic accident	Yes	–	No	Yes	No

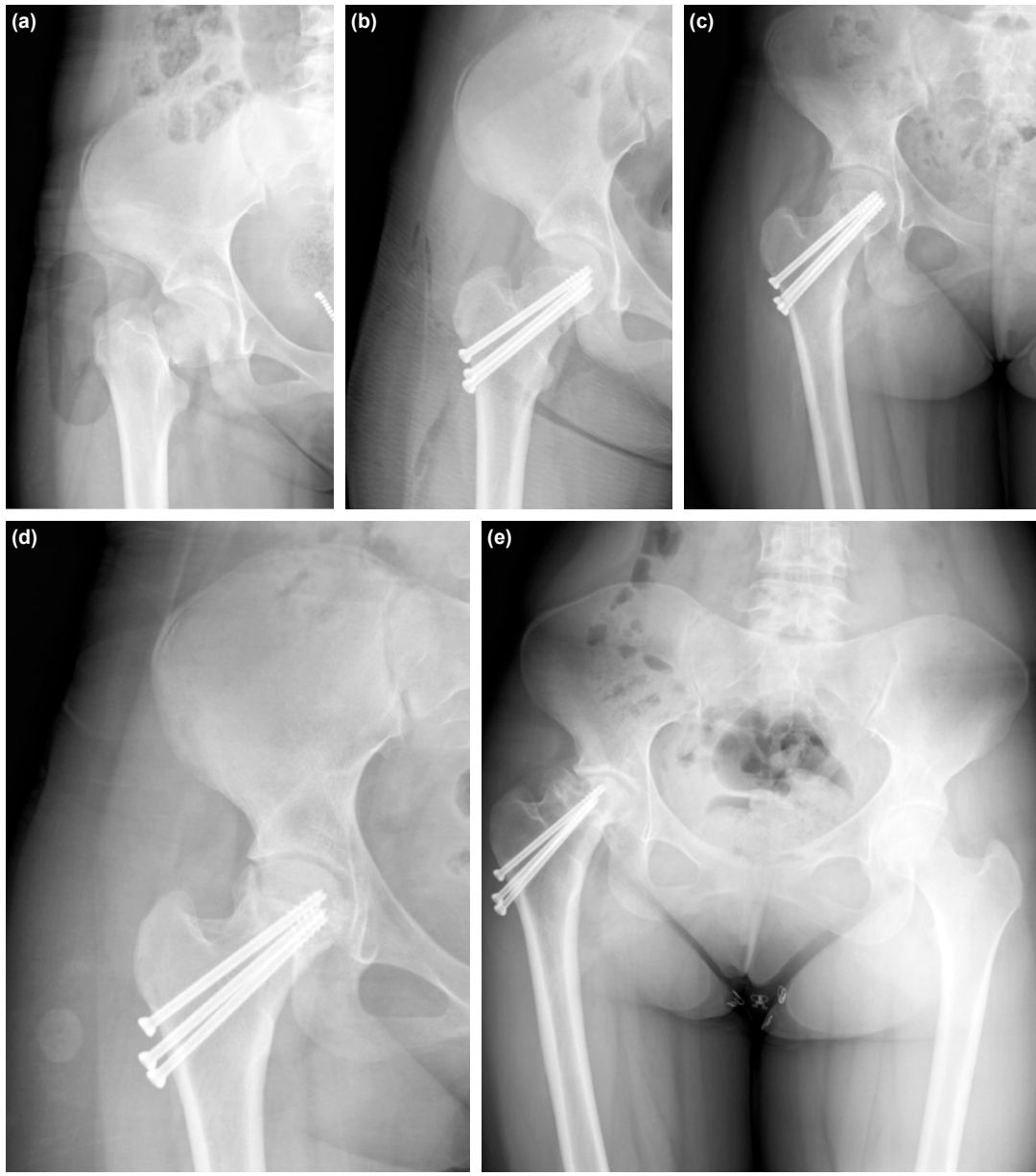

Figure 1. Anteroposterior hip radiographs of a 13-year-old girl who had a right displaced transcervical femur neck fracture due to fall from a high. **(a)** Pre-operative. **(b)** Early post-operative. **(c)** At 6 months postoperatively; everything seems normal on the patient's 6th month control radiograph. **(d)** At 13 months postoperatively; AVN findings are low on the 13th month control radiograph. **(e)** At 84 months postoperatively; Ratliff type 2 AVN on the 84th month control radiograph.

creased as the fracture approached to the head of the femur. In literature, it has been done by including all Delbet types in studies related to femoral neck fractures and complications. To the best of our knowledge, there have been no studies investigating only Delbet type 2 fractures and their relationships with complications such as AVN, coxa vara, coxa valga, and early epiphyseal closure.

Wang et al.[8] in the study in which 80 patients with Delbet type 2 and type 3 were examined, they found a significant relationship between AVN and especially posterior displacement in lateral X-ray. In another study made by Wang et al.[9] with 239 patients, having an initial displacement and being over 12 years of age were identified as risk factors for AVN development and a significant difference was found. In our study, it was observed that the fracture was more displaced in high-energy traumas. Similar to the studies in the literature, in our study, a significant relation was found between the initial displacement and the development of AVN. In our study, the average age of patients who developed AVN was 11.33 (7–14), and two patients older than 12 years were detected. According to us, the most important result we obtained in our study is that when Delbet type 2 fractures are isolated, the age of the patient is not a risk factor for

the development of AVN. Perhaps, age is a risk factor for Delbet type 2 fracture. If you evaluate all pediatric proximal femur fractures together, age may be an indirect risk factor for AVN.

AlKhatib et al.[10] found that there was no relationship between the proximal femur fractures treated in the first 24 h and after 24 h in terms of the risk of developing AVN. However, there are studies in the literature that support the opposite. Bukva et al.[11] found that a significant difference in terms of better results in proximal femur fractures treated within the first 12 h. Azam et al.[12] found an increase in AVN and other complications in delays of 48 h and longer. In our study, we did not find a significant relationship between the timing of surgery and the development of AVN.

In literature, the effect of open and closed reduction on the success of treatment is controversial. In studies that advocate ORIF, it has been argued that especially reducing the pressure within the capsule reduces the development of AVN.[13] Ng and Cole[14] found that early decompression in pediatric femoral neck fractures did not make a significant difference to AVN development. In 12 patients with femoral neck fractures, Song et al.[15] performed ORIF with arthrotomy and hematoma decompression. None of the patients had AVN, non-union, coxa vara, or early physical closure. In another study conducted by Song,[16] it was found that the application of ORIF for the displaced pediatric femoral neck fracture is more appropriate than CRIF. In our study, no significant difference was found between ORIF and CRIF in terms of developing AVN. However, all of our patients with AVN were also patients who underwent CRIF. AVN was not detected in any patient treated with ORIF.

Forlin et al.[17] observed that the screws crossed the epiphyseal growth plate in 11 of 15 patients with early epiphyseal closure. However, it was emphasized that early epiphyseal closure may be developed secondary to factors such as AVN, damage during trauma, or screws passing through the epiphyseal growth plate. Canale and Bourland[18] observed that early epiphyseal closure was observed more frequently in cases where the screws passed the epiphyseal growth plate. In our study, we found that the fact that the screws passed the epiphyseal growth plate did not have a significant effect in terms of AVN development. Our findings are in the same direction with Forlin results. When the literature is examined, the relationship between the order of complications occurring after femoral neck fractures and the reasons for their occurrence are not evident. It is not possible to distinguish complications such as AVN, coxa vara, early physical closure, and femoral shortness on the affected side. The question of which one is the main initiator has not been found in the literature. When both the literature and the cases in our study are examined, it is likely that the complications after femoral neck fractures develop secondary to vascular damage during the initial trauma formation.

Ratliff[1] observed that AVN always occurs within 1 year after injury. However, he could not confirm the findings of McDougall. McDougall[19] stating in his study that "radiological findings of AVN may not be evident for 2 years after an injury." Togrul et al.[20] emphasized that detection of the AVN development is not possible until the epiphyseal growth plate closure in femur neck fractures. Our study also supported the claim of McDougall, unlike Ratliff. In our cases, the development time of AVN was observed in the first 12 months (8–12 months) in five of the patients and after 12 months (13–15 months) in four of the patients. In other words, we found that some patients developed AVN after 12 months (Fig. 1). In the study related with the samples taken from the screw line during the implant removal of the proximal femoral fractures, Maeda et al.[21] emphasized that AVN findings are common around 1 year but there is no complete recovery in cases after 1 year. Findings in this study were also supported by our study. Follow-up of patients for at least 24 months is important for observing complications, especially AVN.

The limitations of the study are; being retrospectively designed inadequate number of patients and insufficient data about the clinical results of the patients. In addition, we could not examine the vascular damage radiological and histological that occurred at the time of trauma. Multicenter prospective studies with vascular examination are needed in this field due to the relatively low number of cases.

As a conclusion, unlike the literature, when you only study Delbet type 2 fractures, the ages of the patients were not determined as risk factors for the development of AVN. The factors including type of fracture, initial displacement, and severity of trauma have significant effects on results. These data support the thesis that the damage occurred before starting treatment. Complications such as coxa vara, non-union, and early epiphyseal closure can be considered as the final results of AVN due to vascular damage. As AVN development can be seen after 12 months, follow patients for at least 24 months. Efficacy of the surgeons to prevent the complications is limited, which may depending on the mechanisms that occur at the beginning of the trauma, despite the appropriate medical treatment.

Ethics Committee Approval: The study was approved by the Ethics Review Committee of Dicle University Faculty of Medicine, Diyarbakır, Turkey (Approval number: 185, date: 04.06.2020).

Peer-review: Internally peer-reviewed.

Authorship Contributions: Concept: M.S.A.; Design: Ş.Y.; Supervision: Ş.Y.; Resource: Ş.Y.; Materials: M.S.A., Ş.Y.; Data: M.S.A., Ş.Y.; Analysis: M.S.A., Ş.Y.; Literature search: M.S.A., Ş.Y.; Writing: M.S.A., Ş.Y.; Critical revision: M.S.A., Ş.Y.

Conflict of Interest: None declared.

Financial Disclosure: The authors declared that this study has received no financial support.

REFERENCES

1. Ratliff AH. Fractures of the neck of the femur in children. J Bone Joint Surg Br 1962;44-B:528–42.
2. Hamilton CM. Fractures of the neck of the femur in children. JAMA 1961;178:799–801.
3. Colonna PC. Fractures of the neck of the femur in children. Am J Surg 1929;6:793–7.
4. Bagatur AE, Zorer G. Complications associated with surgically treated hip fractures in children. J Pediatr Orthop B 2002;11:219–28.
5. Moon ES, Mehlman CT. Risk factors for avascular necrosis after femoral neck fractures in children: 25 Cincinnati cases and meta-analysis of 360 cases. J Orthop Trauma 2006;20:323-9.
6. Inan U, Köse N, Omeroğlu H. Pediatric femur neck fractures: A retrospective analysis of 39 hips. J Child Orthop 2009;3:259–64.
7. Wu C, Ning B, Xu P, Song J, Wang D. Efficacy and complications after delayed fixation of femoral neck fractures in children. J Orthop Surg (Hong Kong) 2020;28:2309499019889682.
8. Wang W, Li Y, Guo Y, Li M, Mei H, Shao J, et al. Initial displacement as a risk factor for avascular necrosis of the femoral head in pediatric femoral neck fractures: A review of one hundred eight cases. Int Orthop 2020;44:129–39.
9. Wang WT, Li YQ, Guo YM, Li M, Mei HB, Shao JF, et al. Risk factors for the development of avascular necrosis after femoral neck fractures in children: A review of 239 cases. Bone Joint J 2019;101-B:1160–7.
10. AlKhatib N, Younis MH, Hegazy A, Ibrahim T. Early versus late treatment of paediatric femoral neck fractures: A systematic review and meta-analysis. Int Orthop 2019;43:677–85.
11. Bukva B, Abramović D, Vrgoč G, Marinović M, Bakota B, Dučić S, et al. Femoral neck fractures in children and the role of early hip decompression in final outcome. Injury 2015;46 Suppl 6:S44–7.
12. Azam MQ, Iraqi A, Sherwani M, Abbas M, Alam A, Sabir AB, et al. Delayed fixation of displaced Type II and III pediatric femoral neck fractures. Indian J Orthop 2009;43:253–8.
13. Bali K, Sudesh P, Patel S, Kumar V, Saini U, Dhillon MS. Pediatric femoral neck fractures: Our 10 years of experience. Clin Orthop Surg 2011;3:302–8.
14. Ng GP, Cole WG. Effect of early hip decompression on the frequency of avascular necrosis in children with fractures of the neck of the femur. Injury 1996;27:419–21.
15. Song KS, Kim YS, Sohn SW, Ogden JA. Arthrotomy and open reduction of the displaced fracture of the femoral neck in children. J Pediatr Orthop B 2001;10:205–10.
16. Song KS. Displaced fracture of the femoral neck in children: Open versus closed reduction. J Bone Joint Surg Br 2010;92:1148–51.
17. Forlin E, Guille JT, Kumar SJ, Rhee KJ. Complications associated with fracture of the neck of the femur in children. J Pediatr Orthop 1992;12:503–9.
18. Canale ST, Bourland WL. Fracture of the neck and intertrochanteric region of the femur in children. J Bone Joint Surg Am 1977;59:431–43.
19. Mcdougall A. Fractures of the neck of the femur in childhood. J Bone Joint Surg 1961;43-B:16.
20. Togrul E, Bayram H, Gulsen M, Kalaci A, Ozbarlas S. Fractures of the femoral neck in children: Long-term follow-up in 62 hip fractures. Injury 2005;36:123–30.
21. Maeda S, Kita A, Fujii G, Funayama K, Yamada N, Kokubun S Avascular necrosis associated with fractures of the femoral neck in children: Histological evaluation of core biopsies of the femoral head. Injury 2003;34:283–6.

ORİJİNAL ÇALIŞMA - *ÖZ*

Delbet tip 2 femur boyun kırıklarında avasküler nekroz oluşması gerçekten engellenebilir mi?

Dr. Mehmet Sait Akar, Dr. Şeyhmus Yiğit

Dicle Üniversitesi Tıp Fakültesi, Ortopedi ve Travmatoloji Anabilim Dalı, Diyarbakır

AMAÇ: Çocuklarda proksimal femur kırıkları oldukça nadir görülmektedir. Bu kırıklar avasküler nekroz, koksa vara, femurbaşı epifizinin erken kapanması gibi ciddi komplikasyonlarla sonuçlanabilmektedir. Bu çalışmanın amacı en çok görülen ve avasküler nekrozun yoğun olarak saptandığı delbet tip 2 kırıkların geriye dönük incelenmesini içermektedir.

GEREÇ VE YÖNTEM: Hastanemizde Ocak 2009 - Haziran 2018 yılları arasında tedavi edilen Delbet tip 2 kırıkları olan 42 hasta tarandı. Hastaların, kırıkların oluşum mekanizması, kırığın deplase olup olmaması, eşlik eden yaralanmaların varlığı, cerrahi zamanlaması, açık ya da kapalı redüksiyon yapılması ve vidaların epifiz hattını geçip geçmemesi, AVN verileri geriye dönük olarak incelendi.

BULGULAR: Taranan 42 hastadan takip grafileri ve dosyaları tam olan 34 hasta çalışmaya dahil edildi. Hastaların yaş ortalaması 11.02 yıl (1–17 yaş arası), ortalama takip süresi 40.82 ay (24–98 ay) idi. Hastaların takip grafileri incelendiğinde dokuz hastada (%26.5) avasküler nekroz, iki hastada (%5.9) koksa vara, bir hastada (%2.9) kaynamama geliştiği saptandı. Yüksek enerjili yaralanması olan ve başlangıçta kırık deplasmanı fazla olan hastalarda AVN oranı anlamlı olarak daha yüksek saptandı (sırasıyla, p=0.034, p=0.047).

TARTIŞMA: Delbet tip 2 kırıklarda bulgularımıza göre, travmanın şiddeti ve kırığın ilk yer değiştirmesi dışında tedavi süreciyle ilgili faktörlerin avasküler nekroz (AVN) gelişimi üzerinde önemli bir etkisi yoktur. Bu hastalarda yaş AVN gelişimi için risk faktörü olarak belirlenmemiştir.

Anahtar sözcükler: Avasküler nekroz; Delbet sınıflaması; pediatrik femur boyun kırıkları.

Ulus Travma Acil Cerrahi Derg 2022;28(1):107-112 doi: 10.14744/tjtes.2020.33568