DOI: 10.4274/tjcd.74508
Turk J Colorectal Dis 2017;27:161-164

CASE REPORT

Ingested Foreign Bodies and Their Removal via Endoscopy from Duodenum and Colon in Patient with Situs Inversus Totalis

Situs İnversus Totalisli Olgunun Yuttuğu Yabancı Cisimlerin Duodenum ve Kolondan Endoskopi ile Çıkarılması

Ahmet Bozdağ[1], Abdurrahman Şahin[2], Pınar Gündoğan Bozdağ[3], Özkan Alataş[3], Zeynep Özkan[1]

[1]University of Health Sciences, Elazığ Training and Research Hospital, Department of General Surgery, Elazığ, Turkey
[2]Fırat University Faculty of Medicine, Department of Gastroenterology, Elazığ, Turkey
[3]University of Health Sciences, Elazığ Training and Research Hospital, Department of Radiology, Elazığ, Turkey

ABSTRACT

Situs inversus totalis (SIT) is a rare congenital anomaly characterized by a reversal or mirroring of the normal anatomic positions of the visceral organs. In this case, diagnosis and treatment of diseases is difficult due to the different position of the organs. With the more frequent clinical application of endoscopy methods today, there are also examples in the literature of SIT patients undergoing these procedures. Although the English literature includes case reports presenting the use of endoscopy in patients with SIT, none discuss the removal of foreign bodies in such patients. In this paper, we aim to present a case in which upper gastrointestinal endoscopy and colonoscopy were used to remove two sewing needles impacted at different locations in the digestive system of a patient with SIT.
Keywords: Foreign body, situs inversus totalis, endoscopy

ÖZ

Situs inversus totalis (SİT) viseral organların normal anatomik lokalizasyonunun ayna görüntüsü olacak şekilde farklı yerleşimi olan konjenital gelişimsel bir anomalidir ve çok ender rastlanılmaktadır. Organların farklı yerleşiminden dolayı hastalıkların teşhis ve tedavisi zorlaşmaktadır. Günümüzde endoskopik yöntemlerin giderek artan bir şekilde klinikte uygulanması ile SİT olgularına da bu işlemlerin yapıldığı literatürde görülmektedir. İngilizce literatürde endoskopik işlemlerin SİT'li hastalara uygulandığı olgu sunumları bildirilmekle beraber yabancı cisim çıkarılması ile ilgili olgu bulunmamaktadır. Biz de SİT olan ve iki adet dikiş iğnesinin sindirim sisteminin farklı lokalizasyonlarında impakte olduğu hastada üst gastrointestinal endoskopi ve kolonoskopi ile tedavi ettiğimiz olguyu sunmayı amaçladık.
Anahtar Kelimeler: Yabancı cisim, situs inversus totalis, endoskopi

Introduction

Situs inversus is a rare congenital anomaly characterized by reverse localization of the human internal organs. It is categorized in two groups as; the partial situs inversus and situs inversus totalis (SIT). In SIT, both thoracic and intra-abdominal organs are transposed through the sagittal plane. This case is also defined as the arrangement of the internal organs as a mirror image of the normal human anatomy. SIT is formed when the embryonic midgut rotates 270° in the clockwise direction instead of 270° in counter clockwise direction. Consequently, all thoracic and abdominal visceral organs are located inversely compared to the people with normal internal organ anatomy. In the partial situs inversus, one or more internal organs are located in the opposite positions. The incidence rate of SIT is reported as 1:10.000/1:20.000.[1,2]

Address for Correspondence/Yazışma Adresi: Ahmet Bozdağ MD
University of Health Sciences, Elazığ Training and Research Hospital, Department of General Surgery, Elazığ, Turkey
Phone: +90 533 652 51 63 **E-mail:** abozdag80@hotmail.com **ORCID ID:** orcid.org/0000-0003-1973-2511
Received/Geliş Tarihi: 21.06.2017 **Accepted/Kabul Tarihi:** 17.08.2017
This study was presented as a poster presentation in 20th National Surgery Congresss, 13-17 April 2016, Antalya, Turkey.

©Copyright 2017 by Turkish Society of Colon and Rectal Surgery
Turkish Journal of Colorectal Disease published by Galenos Publishing House.

Foreign body ingestion in adults mainly occurs due to mental retardation, psychological disorders, tooth loss in the elderly, and habit of eating fast.[3] Approximately 95% of the swallowed foreign bodies pass through stomach into the intestines and they are discarded from the body through the passage without causing any symptoms or injuries. On the other hand, some pointed and sharp-edged objects get stuck especially where the gastrointestinal (GI) tract narrows down and may cause various serious clinical symptoms such as perforation, migration or obstruction. Thus; persisting complaints or complications observed in follow-up require endoscopic or surgical intervention.

In the literature in English; several successful endoscopic and laparoscopic intervention procedures have been described in SIT cases, however no article explaining the removal of swallowed foreign bodies with upper GI endoscopy and colonoscopy in the SIT cases have been found.

In this study, we present the removal of swallowed foreign bodies by upper GI endoscopy and colonoscopy procedure in the SIT cases.

Case Report

The 30-year-old female patient applied to the emergency room with the complaint of abdominal pain, expressed especially left side of her abdomen. She did not have any other complaint such as nausea, vomiting, diarrhea or constipation. Physical examination did not reveal any abdominal sensitivity, rebound or defense. Laboratory test results were normal. In the plain abdominal radiograph, a foreign body (a needle) in the abdomen was detected, and also dextrocardia was diagnosed. In anamnesis, the patient did not remember swallowing any needles. She had no mental disorder. She stated that she was interested in doing needlework as an amateur and she was putting the needle in her mouth while doing the needlework now and then. The patient was monitored for one week. Since the objects did not move during the monitorization, the patient was subjected to lower and upper abdominal tomography scan (Figure 1) and (Figure 2). The patient was diagnosed with SIT. The foreign body was detected in the duodenum and ascending colon. Upper GI system endoscopy and colonoscopy were performed. Upper GI system endoscopy showed a needle stuck in the duodenal mucosa and it was tried to be removed out by using the snare. As the needle broke into two, each part was removed separately (Figure 3). Colonoscopy revealed the needle stuck into ascending colon mucosa. The object was successfully removed out with snare (Figure 4). Further examination was performed up to the cecum and no other pathologies were detected. The patient was kept under observation for six hours and discharged with medical recommendations. Informed consent was obtained from the patient.

Figure 1. Coronal section of body computerized tomography scan shows situs inversus totalis and two metallic objects in the duodenum and ascending colon at the left side of the body

Figure 2. Hyperdense object in ascending colon on axial section of abdominal tomography scan

Figure 3. A foreign object (sewing needle) stuck in duodenal mucosa in endoscopic image

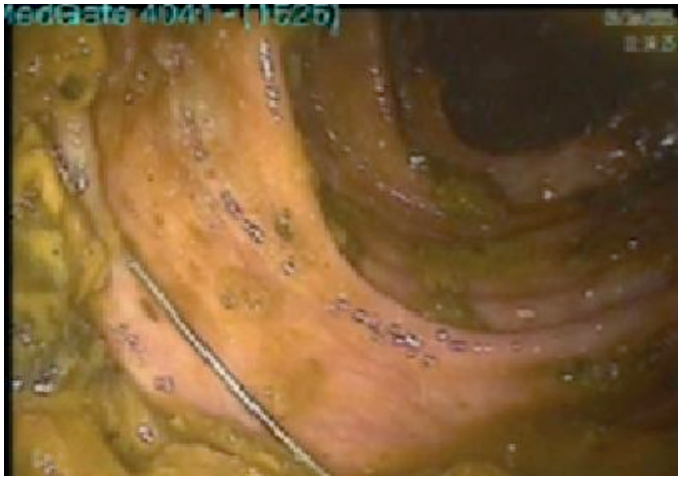

Figure 4. A foreign object (sewing needle) stuck in ascending colon mucosa in a colonoscopic image

Discussion

In SIT, the heart, spleen, stomach and aorta are located on the right side whereas the liver, inferior vena cava and cecum are located on the left side of the body. The first reported SIT case was in 1600s by Fabricus and it was related with recessively transmitted autosomal genetic susceptibility.[4,5] This anomaly was reported to be observed in 3-5% of patients with congenital heart diseases and it was also reported to be accompanied with bi-lobed or symmetric liver, intestines and mesenteric mal-rotation, reversed pulmonary lobulation, spleen agenesis or multiple spleens, and anomalies particularly with larger vascular bodies.[4,6] Besides these anomalies, SIT is considered to have no effect on normal lifetime or a pre-malign state.[4] Diagnosis of SIT is mostly coincidental during radiological imaging rather than physical examination. In our case, although the patient already knew that she had SIT, she did not tell this in the initial admission. The case was diagnosed with dextrocardia in X-ray imaging and with reversed visceral organs in abdominal tomography scan. When the patient was examined again, she stated that she knew the presence of SIT. Indeed, the patient had already been further examined before and no abnormalities had been reported then. Computerized abdominal tomography scan is a successful radiological examination technique in the diagnosis of SIT.[4] Some sections of thoracic organs and the entire abdominal organs are observed to be in reverse position. In our case, thoracic and abdominal computed tomography were applied for the detection of the exact localization of the foreign bodies which were observed in X-ray imaging, to make sure whether the situs inversus was total or not, and also together with SIT, to observe foreign objects (needles) in duodenum and colon area following cecum, i.e. in the left ascending colon.

Although foreign body swallowing is mostly seen in adults with mental or physical disabilities, in the cases with senility or tooth loss, it was also frequently reported that especially in Muslim countries, putting the scarf needle in the mouth and then unintentionally swallowing it is common. Similarly; foreign bodies such as needles, which are put in the mouth during free-time or occupational activities, can also be ingested unintentionally.[3]

In the case that presented in this study, the patient had no history of swallowing a foreign object.

Ingested foreign bodies are mostly removed out of the body through the digestive system without causing any problems. On the other hand, some pointed, sharp-edged or larger objects can get stuck into the anatomically narrow areas or somewhere in the digestive system therefore, may cause bleeding, perforation, fistula, peritonitis, sepsis or even death.[7] Examination of patients with SIT can also be misleading. Due to reversed organs, the location of symptoms and complaints are also reversed. In our case, this was the reason why the patient had abdominal pain in left side and the foreign body was in duodenum and the ascending colon.

American Gastroenterological Association made a classification in terms of managing foreign bodies in the human body. We followed our case for one week with X-ray imaging and physical examinations based on this classification. Due to the persistence of the foreign body in the patient's abdomen, we decided to perform endoscopic examination and to remove the foreign body, if possible.

In several publications, selection among three different levels of endoscopic procedure in cases of SIT is reported. Traditionally, the reverse positioning of the endoscopist with respect to the patient is recommended to overcome the anatomical difficulties.[8] It is well known that several endoscopic interventions including upper GI endoscopy, colonoscopy, endoscopic retrograde cholangiopancreatography have been successfully applied to the patients with SIT. Nowadays, abdominal surgery including laparoscopic or minimally invasive interventions can be performed safely on the patients with SIT.[9,10] In a study carried out in Korea, only 5 of the patients with SIT were reported to be subjected to colonoscopy among the 35000 colonoscopy cases. The authors evaluated the success of the colonoscopy with the rate of cecal intubation and the degree of procedural difficulty with the cecal intubation time. In SIT patients, the cecum time was prolonged compared to other patients and all patients except one with obstruction were achieved to cecum. There were no complications during the procedure and no transposition was detected by colonoscopists.[10] In our case, despite time was not recorded, cecum was easily achieved with no

retention and no complications occurred. The duration of the procedure was not different from that of other foreign body removal procedures. In upper GI endoscopy, 2nd part duodenum was easily reached and there was no prolongation or complication during the operation. In our literature scan through PubMed and Google Scholar, we did not find any article related to removal of ingested foreign bodies with upper GI endoscopy and colonoscopy from the SIT cases. In this case, swallowed foreign bodies were successfully removed by using endoscopic methods with experienced endoscopists and no difficulties were encountered during the procedure.

Clinicians should always keep in mind that, patients may have different anatomies. Investigation of patients' medical history is very crucial, since some patients may not reveal their medical conditions without being asked or they may simply be not be aware of it. Additionally, computerized abdominal tomography, which is the most successful imaging technique for the localization of the ingested foreign bodies, for the detection of the patients' anatomical variations and potential complications before performing any intervention. Endoscopic procedures are safely carried out in patients with SIT by experienced endoscopists.

Ethics

Informed Consent: Consent form was filled out by the participant.

Peer-review: External and internal peer-reviewed.

Authorship Contributions

Surgical and Medical Practices: A.B., A.Ş., Concept: P.G.B., Z.Ö., Design: Z.Ö., A.B., Data Collection or Processing: Ö.A., A.Ş., Analysis or Interpretation: A.Ş., Ö.A., P.G.B., Literature Search: Z.Ö., A.B., Writing: Z.Ö., A.B.

Conflict of Interest: No conflict of interest was declared by the authors

Financial Disclosure: The authors declared that this study received no financial support.

References

1. Kim YW, Ryu H, Kim DS, Kim IY. Double primary malignancies associated with colon cancer in patients with situs inversus totalis: two case reports. World J Surg Oncol 2011;9:109.
2. Pehlivan M, Kıvrak M, Gökgöz T, Ertuğrul E. Alt Kadran Ağrısıyla Karakterize Nadir Bir Akut Karın Olgusu: Situs İnversus Totalisve Perfore Apandisit. Turkiye Klinikleri Journal of Surgery 2003;8:162-166.
3. Emir S, Özkan Z, Altınsoy HB, Yazar FM, Sözen S, Bali I. Ingested bone fragment in the bowel: Two cases and a review of the literatüre. World J Clin Cases 2013;1:212-216.
4. Benjelloun EB, Zahid FE, Ousadden A, Mazaz K, Taleb KA. A case of gastric cancer associated to situs inversus totalis. Cases J 2008;1:391.
5. Machado NO, Pradeep C. aparoscopic cholecystectomy in a patient with situs inversus totalis: feasibility and technical difficulties. JSLS. 2006;10:386-391.
6. Ye MF, Tao F, Xu GG, Sun AJ. Laparoscopy-assisted distal gastrectomy for advanced gastric cancer with situs inversus totalis: A case report. World J Gastroenterol 2015; 21:10246-10250.
7. Zeynep O, Kement M, Öncel M, Kaptanoğlu L, Gezen C. The effect of sodium phosphate enema in patients ingested foreign bodies: a prospective, randomized trial-Sodium phosphate enema in patients ingested foreign bodies. Health 2010;11:1294.
8. Pathak KA, Khanna R, Khanna NN. Situs inversus with cholelithiasis. J Postgrad Med 1995;41:45-46.
9. Kamani L, Kumar R, Mahmood S, Siddiqui F. Therapeutic ERCP in patient with situs inversus totalis and ampullary diverticulum. J Coll Physicians Surg Pak 2014;24:365-366.
10. Choi DH, Park JW, Kim BN, Han KS, Hong CW, Sohn DK, Lim SB, Choi HS, Jeong SY. Colonoscopy in situs inversus totalis patients. Am J Gastroenterol 2008;103:1311-1312.