CASE REPORT

Successful simultaneous ipsilateral stenting of common iliac artery stenosis and transfemoral aortic valve replacement

Aynı anda aynı taraftaki ana iliyak arter darlığına stent yerleştirilmesi ve transfemoral aort kapak replasmanı

Abdullah Nabi Aslan, M.D., Hacı Ahmet Kasapkara, M.D.,[#] Serkan Sivri, M.D., Murat Can Güney, M.D.,[#] Engin Bozkurt, M.D.[#]

Department of Cardiology, Atatürk Training and Research Hospital, Ankara, Turkey
[#]Department of Cardiology, Yıldırım Beyazıt University Faculty of Medicine, Ankara, Turkey

Summary– Transcatheter aortic valve replacement (TAVR) was designed to treat elderly patients with severe aortic stenosis at high risk for surgery, and is most commonly performed with retrograde approach through femoral arteries. However, in up to 30% of cases, it is either not possible to use this access route or it is considered to have high risk of vascular injury. Alternative approaches have been described for patients with no suitable femoral access: trans-subclavian, transaortic, or direct aortic access; however, since the introduction of new valves deployed with low-profile delivery systems, another alternative transcatheter approach has been discovered. Presently described is experience in 2 cases in which patients were treated with transfemoral TAVR using Edwards SAPIEN 3 transcatheter heart valves immediately following ipsilateral common iliac artery stenting.

Özet– Transkateter aort kapak replasmanı (TAKR) cerrahi açıdan yüksek riskli ciddi aort darlığı olan yaşlı hastaları tedavi etmek için tasarlanmış olup en sık femoral arterlerden geriye doğru olarak uygulanır. Ancak olguların yaklaşık %30'unda, bu giriş yolu ya kullanılamaz ya da damar yaralanması açısından yüksek risk taşır. Femoral giriş yerinin uygun olmadığı hastalarda, subklaviya yolu, aort yolu ve doğrudan aort girişimi gibi yaklaşım seçenekleri tanımlanmıştır. Fakat, düşük profilli sistemlerle yerleştirilebilen yeni kapakların ortaya çıkmasından sonra, başka bir kateter yoluyla yaklaşım seçeneği keşfedildi. Burada biz aynı taraftaki ana iliyak artere stent uygulaması sonrası eş zamanlı Edwards SAPIEN 3 kapak kullanılarak transfemoral TAKR yapılan iki olguluk deneyimimizi sunduk.

Transcatheter aortic valve replacement (TAVR) using stent-based bioprostheses has emerged as a promising alternative to surgical aortic valve replacement (AVR) in selected patients.[1] Femoral artery is the most commonly used access site for TAVR. However, when this is unsuitable due to small or diseased iliofemoral arteries, alternative access routes such as transapical approach, trans-subclavian approach, or direct aortic access via minimal thoracotomy may be considered.[2] Since the introduction of new valves deployed with low-profile delivery systems, another alternative approach has emerged for TAVR procedures: a stepwise approach of first stenting iliofemoral artery and then performing TAVR procedure through the stented artery during same session.

Abbreviations:

AS	*Aortic stenosis*
AVR	*Aortic valve replacement*
CAD	*Coronary artery disease*
CAG	*Coronary angiography*
CIA	*Common iliac artery*
MSCT	*Multi-slice computed tomography*
PAD	*Peripheral artery disease*
TAVR	*Transcatheter aortic valve replacement*

CASE REPORT

Case 1– A 65-year-old man presented at polyclinic with history of exercise-induced chest pain ongoing for 1 year and New York Heart Association Class IV dyspnea. He had been diagnosed with hypertension, chronic obstructive pulmonary disease, and chronic

Received: January 16, 2016 *Accepted:* June 28, 2016
Correspondence: Dr. Abdullah Nabi Aslan. 1238. Cadde, Ata Apt., No: 10/35, Yukarı Öveçler, Ankara, Turkey.
Tel: +90 312 - 291 25 25 e-mail: drnabiaslan@hotmail.com
© 2017 Turkish Society of Cardiology

renal failure (glomerular filtration rate: 19.9 mL/min), and had undergone coronary artery bypass grafting and left subclavian artery angioplasty. Echocardiography revealed severe aortic stenosis (AS) (mean gradient: 40 mmHg; aortic valve area: 0.64 cm^2), moderate tricuspid regurgitation, systolic pulmonary artery pressure of 60 mmHg, and normal left ventricular function (ejection fraction: 65%). Patient was evaluated for standard AVR and underwent pre-operative screening. Coronary angiography (CAG) showed patent bypass grafts. To evaluate extent of calcification and possibility of performing TAVR, multi-slice computed tomography (MSCT) was performed, which confirmed severe stenosis of right common iliac artery (CIA) and severe tortuosity and calcification of left iliofemoral arteries. Left and right subclavian arteries were also heavily calcified and small in size. Assessment of heart team was to perform TAVR due to several comorbidities and high mortality risk scores (Logistic European System for Cardiac Operative Risk Evaluation [EuroSCORE]: 24.8%; Society of Thoracic Surgeons [STS] score: 5.2%). Approaches other than CIA were excluded based on both severe subclavian arteriopathy and surgical inexperience. Following careful and comprehensive evaluation of 3-dimensional computed tomography, stepwise approach of iliac artery stenting followed by TAVR procedure via same artery was planned. Patient was taken to catheterization laboratory. Peripheral angiography confirmed severe stenosis of right CIA (Figure 1a). After inserting 8-F sheath into left and right femoral arteries, 9x80 mm self-expanding stent was implanted in right CIA. Post-dilatation with 8x60 mm balloon was performed and stenosis was completely relieved (Figure 1b). Next, 14-F e-sheath was inserted into right femoral artery through the stent (Figure 1c), and aortic balloon valvuloplasty with 23x40 mm balloon and TAVR using 26 mm SAPIEN 3 valve (Edwards Lifesciences, Irvine, CA, USA) were successfully performed under local anesthesia and rapid ventricular pacing (Figure 1d). Echocardiography showed normal valve function with mean gradient of 7 mmHg and aortic regurgitation was absent. Two Perclose ProGlide percutaneous closure devices (Abbott Vascular, Inc., Santa Clara, CA, USA) were used to close right femoral artery. Final iliofemoral angiography indicated normal position of stent in right CIA and no vascular complication. Patient had uneventful postprocedural course and was discharged from hospital on second postprocedural day with normal valve function.

Case 2– A 91-year-old woman was admitted to department of emergency medicine with shortness of breath and palpitations. Her medical history included type 2 diabetes mellitus, hypertension, and chronic renal failure (glomerular filtration rate: 40.9 mL/min). Echocardiography revealed severe AS (mean gradient: 51 mmHg; aortic valve area: 0.67 cm^2) and normal left ventricular function (ejection fraction 60%). Patient was evaluated for standard AVR and underwent preoperative screening. CAG revealed coronary artery disease (CAD) with severe lesion in right coronary artery, and peripheral angiography showed severe stenosis of both common iliac arteries (Figure 2a). Heart team recommended TAVR due to co-morbidities and high risk scores (Logistic EuroSCORE: 29.5%; STS score: 7.8%). As in first case, 2-step approach of CIA stenting immediately followed by TAVR through same artery was performed. After inserting 8-F sheaths into left and right femoral arteries, 9x29 mm balloon-expandable stent was implanted into right CIA (Figure 2b). After insertion of 14-F e-sheath (Figure 2c), aortic balloon valvuloplasty and TAVR via right femoral

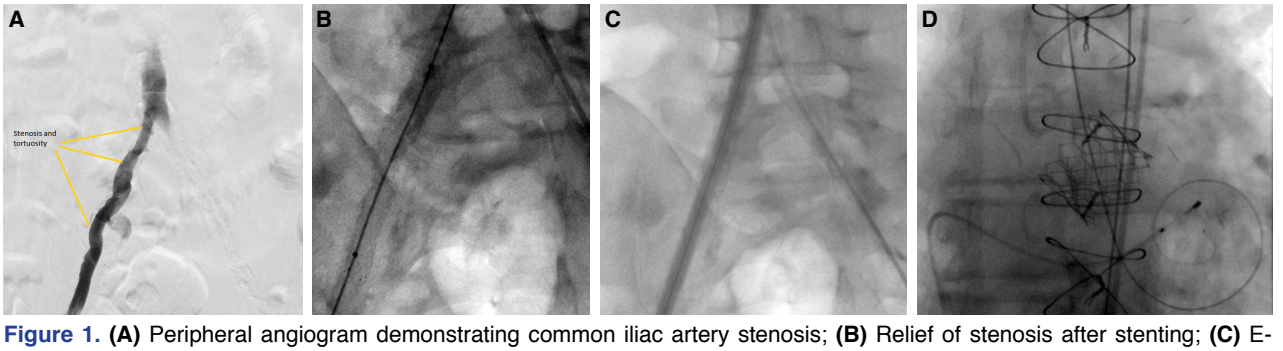

Figure 1. **(A)** Peripheral angiogram demonstrating common iliac artery stenosis; **(B)** Relief of stenosis after stenting; **(C)** E-sheath passed through the stent; **(D)** Successful deployment of SAPIEN 3 valve.

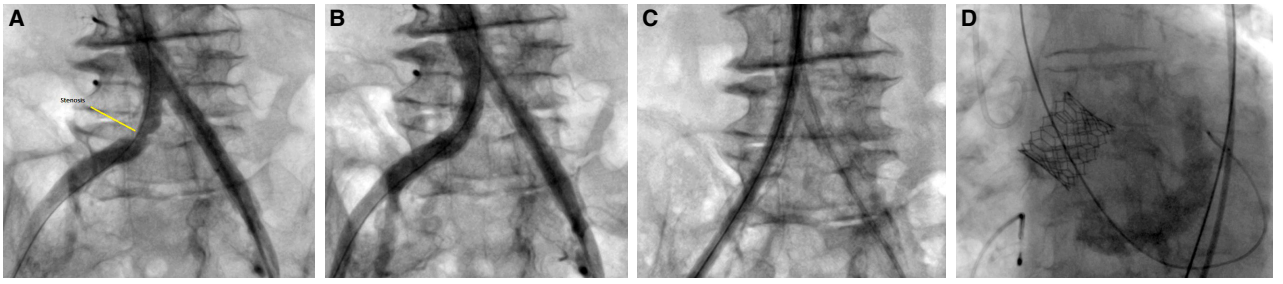

Figure 2. **(A)** Peripheral angiogram illustrating common iliac artery stenosis; **(B)** Relief of stenosis after stenting; **(C)** E-sheath passed through the stent; **(D)** Successful deployment of SAPIEN 3 valve.

artery were successfully performed with 20x40 mm balloon and 23 mm Edwards SAPIEN XT valve (Edwards Lifesciences Corp., Irvine, CA, USA) under local anesthesia and rapid pacing (Figure 2d). Afterwards, aortography indicated appropriate positioning of prosthetic valve with trivial paravalvular aortic regurgitation. Echocardiography also showed normal valve function with mean gradient of 9 mmHg and trivial paravalvular aortic regurgitation. Two Perclose ProGlide percutaneous closure devices were used to close the access site. Final iliofemoral angiography demonstrated normal position of stent in right CIA and no vascular complication. After 4 days of follow-up, patient was discharged from hospital with normal valve function and no complications.

DISCUSSION

TAVR is a promising alternative treatment modality to surgical AVR for patients with severe AS and at high surgical risk. Commonly, transfemoral route is used for TAVR procedure, as vessel diameter required for 18-F introducer sheath and delivery catheter should be >6 mm. This technique has become popular due to a number of advantages, including shorter procedure and recovery times,[3] less postprocedural pain,[4] and ability to perform procedure under conscious sedation.[5] In addition, a meta-analysis comparing transfemoral and non-transfemoral routes in 17 020 patients who underwent TAVR procedure revealed that transfemoral access was associated with lower rate of 30-day and 1-year mortality compared with non-transfemoral access.[6] However, peripheral artery disease (PAD), iliofemoral tortuosity, circumferential calcification, heavily atheromatous or aneurysmal aorta, and small vessel caliber preclude this approach. It is known that risk factors for AS are similar to those of atherosclerosis.[7] As a result, CAD, as well as carotid artery disease and PAD, are often found concurrently in elderly patients presenting with severe symptomatic AS. Fusini et al. reported that iliac and femoral stenosis was found in 29.2% and 22%, respectively, of TAVR candidates.[8] PAD has a pivotal role in access site evaluation of TAVR patients, but may also have great impact on clinical outcome after TAVR due to increased rate of periprocedural and postprocedural complications.[9] It is a primary limitation for transarterial approach and therefore prevalence of up to 50% is seen in transapical TAVR patients.[10] Axillary and subclavian approaches are feasible alternatives, but are also limited by similar problems. Transapical approach is well-recognized alternative, but creation of an apical scar remains a concern, particularly in frail elderly patients and those with dilated or impaired left ventricle. Also, although experience and skill with non-transfemoral approaches remain center-specific, new technologies allow increased availability of transfemoral access, and proportional need for transthoracic approaches may decrease overall. Pre-procedural imaging to assess anatomy, calcification, and caliber of aortoiliofemoral tree is considered standard practice before all TAVR procedures. Accurate pre-intervention screening of vascular anatomy using angiography or MSCT of iliofemoral arteries is mandatory for TAVR in order to assess presence and severity of atherosclerotic disease and to determine feasibility of arterial approach.[11] Ideally, iliofemoral arteries should be free of heavily calcified plaques or significant tortuosity and have diameter large enough to accommodate large femoral sheath.[12] With the help of new generation bioprostheses requiring lower-profile delivery systems for deployment, such as SAPIEN 3 and CoreValve Evolut R (Medtronic, Inc. (Minneapolis, MN, USA) valves, smaller diameter iliofemoral

arteries may now be used more frequently than before. Newest generation of Edwards SAPIEN device, the SAPIEN 3 prosthesis, received its European CE mark in January 2014. Several changes have been made in comparison with the earlier SAPIEN XT device: 1) low-profile 14-F (23 mm and 26 mm device) or 16-F (29 mm device) access sheath; 2) new sizing algorithm for the device itself, which even allows minor undersizing; and 3) most importantly, a paravalvular sealing cuff to reduce residual paravalvular regurgitation.[13] Vascular complications contribute significantly to morbidity and mortality during and after TAVR via femoral arterial access in randomized trials and daily practice. Catheter systems are continuously being optimized, including lower-profile sheath designs. Current generation e-sheath for TAVR with Edwards SAPIEN 3 is nominal 14-F (~4.7 mm) or 16-F (~5.3 mm) femoral sheath with a dynamic expansion mechanism. Because it is the inline diameter, actually 14-F sheath corresponds to a 18 F sheath that is the true outline diameter and 16 F sheath to 20 F sheath. In addition, this sheet system expands transiently (14-F up to 22-F and 16-F up to 26-F) during passage of the SAPIEN 3 transcatheter heart valve and abates to lower-profile diameter thereafter. The expansion mechanism facilitates placement of the large femoral sheath in frail TAVR population with atheroma-altered iliofemoral vessels, vascular calcification burden, or vessel tortuosity, and may therefore reduce adverse events at vascular access site. Manufacturer recommends minimal vessel size of 5.5 mm for the 14-F e-sheath (23-mm and 26-mm SAPIEN 3 valve) and 6.0 mm for the 16-F e-sheath (29-mm SAPIEN 3 valve). CoreValve Evolut R is another new generation transcatheter aortic bioprosthesis that can be delivered with 14-F equivalent (18-F) inline sheath in vessel of diameter ≥5 mm.[14]

In conclusion, TAVR can be performed using various alternative access sites. In present cases, although preprocedural evaluation with MSCT and angiography revealed PAD hindering transfemoral route, stenting of iliac artery immediately followed by TAVR procedure was performed without any vascular complications. Principal reasons we preferred this access site were availability of valves deployed with lower-profile delivery systems, possible higher complication rate and lower success rate with alternative access sites, and relieving iliac stenosis and AS simultaneously. We were particularly careful of risk of stent shifting during advancement of e-sheath, aortic balloon, and valve. This approach may become a standard TAVR technique in the future if application with large number of patients proves its efficiency.

Conflict-of-interest issues regarding the authorship or article: None declared.

REFERENCES

1. Webb JG, Pasupati S, Humphries K, Thompson C, Altwegg L, Moss R, et al. Percutaneous transarterial aortic valve replacement in selected high-risk patients with aortic stenosis. Circulation 2007;116:755–63.
2. da Gama Ribeiro V, Vouga L, Markowitz A, Bezerra HG, Braga P, Ansari M, et al. Vascular access in transcatheter aortic valve implantation. Int J Cardiovasc Imaging 2011;27:1235–43.
3. Yamamoto M, Meguro K, Mouillet G, Bergoend E, Monin JL, Lim P, et al. Effect of local anesthetic management with conscious sedation in patients undergoing transcatheter aortic valve implantation. Am J Cardiol 2013;111:94–9.
4. Amat-Santos IJ, Dumont E, Villeneuve J, Doyle D, Rheault M, Lavigne D, et al. Effect of thoracic epidural analgesia on clinical outcomes following transapical transcatheter aortic valve implantation. Heart 2012;98:1583–90.
5. Motloch LJ, Rottlaender D, Reda S, Larbig R, Bruns M, Müller-Ehmsen J, et al. Local versus general anesthesia for transfemoral aortic valve implantation. Clin Res Cardiol 2012;101:45–53.
6. Chandrasekhar J, Hibbert B, Ruel M, Lam BK, Labinaz M, Glover C. Transfemoral vs Non-transfemoral Access for Transcatheter Aortic Valve Implantation: A Systematic Review and Meta-analysis. Can J Cardiol 2015;31:1427–38.
7. Pohle K, Mäffert R, Ropers D, Moshage W, Stilianakis N, Daniel WG, et al. Progression of aortic valve calcification: association with coronary atherosclerosis and cardiovascular risk factors. Circulation 2001;104:1927–32.
8. Fusini L, Mirea O, Tamborini G, Muratori M, Gripari P, Cefalù C, et al. Incidence and severity of atherosclerotic cardiovascular artery disease in patients undergoing TAVI. Int J Cardiovasc Imaging 2015;31:975–85.
9. Smith CR, Leon MB, Mack MJ, Miller DC, Moses JW, Svensson LG, et al. Transcatheter versus surgical aortic-valve replacement in high-risk patients. N Engl J Med 2011;364:2187–98.
10. Rodés-Cabau J, Webb JG, Cheung A, Ye J, Dumont E, Feindel CM, et al. Transcatheter aortic valve implantation for the treatment of severe symptomatic aortic stenosis in patients at very high or prohibitive surgical risk: acute and late outcomes of the multicenter Canadian experience. J Am Coll Cardiol 2010;55:1080–90.
11. Delgado V, Ewe SH, Ng AC, van der Kley F, Marsan NA,

Schuijf JD, et al. Multimodality imaging in transcatheter aortic valve implantation: key steps to assess procedural feasibility. EuroIntervention 2010;6:643–52.
12. Hayashida K, Lefèvre T, Chevalier B, Hovasse T, Romano M, Garot P, et al. Transfemoral aortic valve implantation new criteria to predict vascular complications. JACC Cardiovasc Interv 2011;4:851–8.
13. Murray MI, Geis N, Pleger ST, Kallenbach K, Katus HA, Bekeredjian R, et al. First experience with the new generation Edwards Sapien 3 aortic bioprosthesis: procedural results and short term outcome. J Interv Cardiol 2015;28:109–16.
14. Medtronic, Inc. IFU M054712T001.

Keywords: Iliac artery stenting; SAPIEN 3 valve; severe aortic stenosis; transcatheter aortic valve replacement.

Anahtar sözcükler: İliyak artere stent yerleştirilmesi; SAPIEN 3 kapak; ciddi aort darlığı; transkateter aort kapak replasmanı.