DOI: 10.4274/turkderm.galenos.2020.00344
Turkderm-Turk Arch Dermatol Venereology 2020;54:76-8

Trichoscopic clues for the diagnosis of alopecia areata

Alopesi areata tanısında trikoskopik ipuçları

Güldehan Atış, Zeynep Altan Ferhatoğlu*

University of Health Sciences Turkey, Hamidiye Faculty of Medicine, İstanbul Haydarpaşa Numune Training and Research Hospital, Clinic of Dermatology, İstanbul, Turkey

*University of Health Sciences Turkey, Hamidiye Faculty of Medicine, Sultan Abdülhamid Han Training and Research Hospital, Clinic of Dermatology, İstanbul, Turkey

Keywords: Trichoscopy, alopecia areta, yellow dots, black dots

Anahtar Kelimeler: Trikoskopi, alopesi areata, sarı noktalar, siyah noktalar

Introduction

Alopecia areata (AA) is an autoimmune, non-scarring alopecia that affects approximately 0.1% to 0.2% of the general population[1]. In localized forms, single or multiple non-inflamed, well-defined, smooth, round alopecia areas appears, mostly on the scalp[1,2]. The disease in some patients may progress and affect the whole scalp (alopecia totalis) or all whole body hairs (alopecia universalis)[1,2].

Nail changes such as pitting, trachyonychia, onychorrhexis, Beau's lines, nail thinning or thickening, leukonychia, onychomadesis, koilonychia and red spots on the lunula are observed in 7% to 66% patients with AA[2].

Trichoscopy, also known as hair and scalp dermoscopy, is a useful non-invasive technique for the diagnosis and therapeutic monitoring of many hair and scalp disorders[3].

A close evaluation of the follicular ostium, scalp, and hair shaft facilitates the diagnosis of AA and helps determine the optimum biopsy area if it is necessary[1]. Moreover, some trichoscopic features can enable the assessment of disease activity and treatment efficacy in AA[4].

Yellow dots (Figure 1-4) are common trichoscopic findings of AA. They are observed in 6-100% of patients with AA and are more common in light-skinned patients (Fitzpatrick's type I-III)[4]. Yellow dots are formed when follicular infundibula become filled with keratin and sebum. They appear as yellow, yellow-brown, yellow-pink or whitish polycyclic or round dots. They may emerge on alopecic areas, along with the other trichoscopic signs of AA, such as short (miniaturized) regrowing hairs, exclamation mark hairs, black dots and/or broken hairs[3,4]. Yellow dots are more common in inactive and long-lasting disease but can also be seen in acute forms of AA[4]. Yellow dots are the most sensitive trichoscopic findings of AA[2,4]. However, they are not specific for AA; they are observed also in other hair disorders, such as androgenetic alopecia, dissecting cellulitis, discoid lupus erythematosus (large, dark yellow dots), congenital hypotrichosis, trichotillomania, chronic telogen effluvium, traumatic alopecia and kerion celsi[2,4].

Black dots (Figure 2) correspond to hair shafts in follicles that are destroyed or broken exclamation mark hairs or tapered hairs before emerging from the scalp level. Black dots are

Address for Correspondence/Yazışma Adresi: Güldehan Atış MD, University of Health Sciences Turkey, Hamidiye Faculty of Medicine, İstanbul Haydarpaşa Numune Training and Research Hospital, Clinic of Dermatology, İstanbul, Turkey Phone: +90 532 792 70 93 E-mail: guldehan.atis@gmail.com
Received/Geliş Tarihi: 15.06.2020 **Accepted/Kabul Tarihi:** 18.06.2020 **ORCID:** orcid.org/0000-0001-5069-044X

©Telif Hakkı 2020 Deri ve Zührevi Hastalıklar Derneği
Türkderm-Deri Hastalıkları ve Frengi Arşivi Dergisi, Galenos Yayınevi tarafından basılmıştır.

observed more commonly in acute forms of AA, i.e. with active hair loss[3,4]. Black dots are also seen in numerous hair diseases, such as tinea capitis, scarring alopecia, androgenetic alopecia, traumatic alopecia, trichotillomania, dissecting cellulitis, traction alopecia and chemotherapy-induced alopecia[3,4].

The incidence of black dots is 0-84% in patients with AA[4]. The presence of numerous black dots during trichoscopic examination is highly suggestive of AA[3].

Flame hairs (Figure 2) are one of the trichoscopic findings that made a sign of an acute disease. They pathologically corresponds to pigmented cast[3].

Exclamation mark hair (Figure 3) is a common pathognomonic trichoscopic finding of AA that is characterized by a broken hair that is relatively thicker at its distal end than the proximal end. It happens because of an arrest in the anagen phase and abrupt cessation of hair shaft formation[1]. Exclamation mark hairs are more common in acute and progressive forms of AA, but they are also presented in the non-progressive and stable forms of the disease. The incidence of exclamation mark hairs is 12-71% in patients with AA. Exclamation mark hairs are also present in tinea capitis, anagen effluvium, trichotillomania and chemotherapy-induced alopecia[4].

Tapered hairs are lengthened exclamation mark hair with a thinner proximal end, similar to exclamation hairs. Tapered and exclamation mark hairs are considered synonymous in some reports[5]. They are usually localized on the perilesional hair-bearing area. Tapered hairs can also be seen with the naked eye. They are pathognomonic findings with the exclamation mark hairs for AA[4].

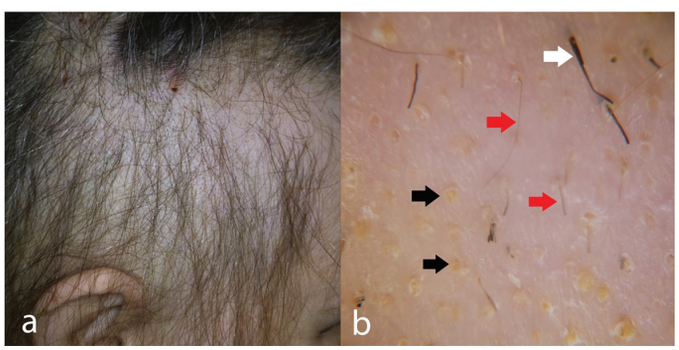

Figure 1. a) Clinical apperence of the patient **b)** yellow dots (black arrows), broken hair (white arrow), short vellus hairs (red arrows) (x10)

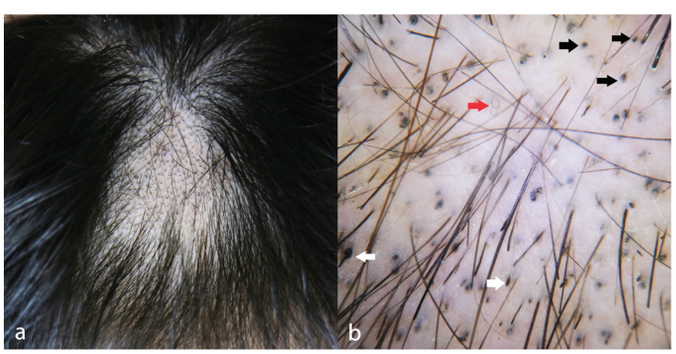

Figure 2. a) Clinical apperence of the patient **b)** black dots (black arrows), flame hairs (white arrows), pigtail hairs (circle hairs) (red arrows) (x10)

Broken hairs (Figure 1) occur as a result of hair shaft breakage secondary to inflammatory process or rapid regrowth. They are findings of acute AA, i.e. with active hair loss. Broken hairs are also frequently observed in trichotillomania. Loss of broken hairs, black dots and exclamation mark hairs indicate good response to therapy[4].

Dystrophic-broken hair due to the interruption of mitotic activity in anagen follicles are observed in AA frequently[1].

Short vellus hair (Figure 1) is another trichoscopic finding of AA; it indicates late-stage or inactive disease[2,4]. The transformation of a vellus hair into a terminal hair is a good sign of hair regrowth. Short vellus hairs are one of the most sensitive trichoscopic features of AA but are not specific to the disease. They are also observed in tinea capitis, traction alopecia, chronic and acute telogen effluvium, trichotillomania, congenital triangular alopecia, primary cicatricial alopecia and traumatic alopecia[4].

Pigtail hairs (circle hairs) (Figure 2, 4) are trichoscopic findings of AA that are characterized by coiled regrowing hairs with tapered ends[4].

Upright regrowing hairs are healthy hairs that have tapered distal ends and regrowing in an upright position[4].

Pohl-Pinkus constrictions are findings of active hair loss that are characterised by zones of reduced-thickness hair shafts. These constriction zones occur due to the rapid and repeated suppression of the mitotic and metabolic activity of hair follicles. Pohl-Pinkus constrictions are not a common trichoscopic feature of AA, having an incidence of merely 2-10%[4].

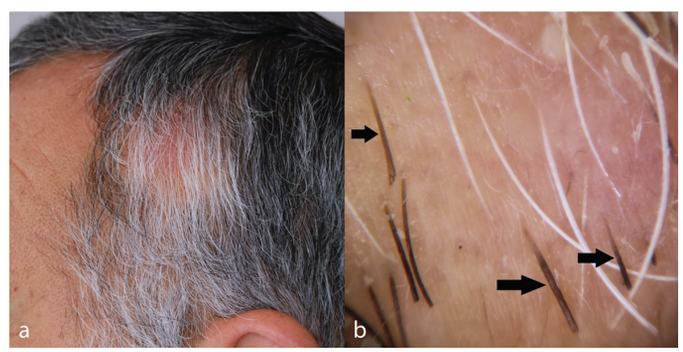

Figure 3. a) Clinical apperence of the patient **b)** exclamation mark hairs (black arrows) (x10)

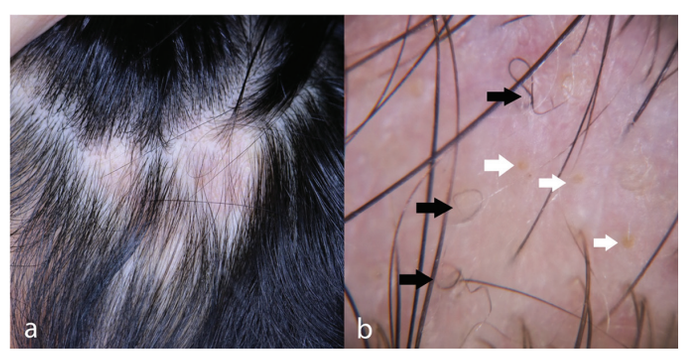

Figure 4. a) Clinical apperence of the patient **b)** pigtail hairs (circle hairs) (black arrows), yellow dots (white arrows) (x10)

Conclusion

Yellow dots and short vellus hairs are the most common and sensitive features seen during trichoscopic examination in patients with AA. Black dots, tapered hairs, exclamation mark hairs and broken hairs are also common trichoscopic features. By contrast, pigtail hairs (circle hairs), upright regrowing hairs and Pohl-Pinkus constrictions are rare trichoscopic findings of AA. In addition to clinical findings, trichoscopic examination is simple, helpful modality that plays an important role in the diagnosis of AA.

References

1. Strazzulla LC, Wang EHC, Avila L, et al: Alopecia areata: Disease characteristics, clinical eveluation, and new perspective on pathogenesis. J Am Acad Dermatol 2018;78:1-12.
2. Darwin E, Hirt PA, Fertig R, Doliner B, Delcanto G, Jimenez JJ: Alopecia areata: Review of epidemiology, clinical features, pathogenesis, and new treatment options. Int J Trichology 2018;10:51-60.
3. Vincenzi C, Tosti A: Nonscarring alopecias. Dermoscopy of the hair and nails. Ed. Tosti A. Second edition. Boca Roton, CRC PressTaylor&FrancisGroup, 2016;34-40.
4. Waskiel A, Rakowska A, Sikora M, Olszewska M, Rudnicka L: Trichoscopy of alopecia areata: An update. J Dermatol 2018;45:692-700.
5. Kibar M, Aktan Ş, Lebe B, Bilgin M: Trichoscopic findings in alopecia areata and their relation to disease activity, severity and clinical subtype in Turkish patients. Australas J Dermatol 2015;56:1-6.