Two Turkish siblings with MEGDEL syndrome due to novel *SERAC1* gene mutation

Özlem Ünal[1], R. Köksal Özgül[2], Didem Yücel[2], Dilek Yalnızoğlu[3], Ayşegül Tokatlı[1], H. Serap Sivri[1], Burcu Hişmi[1], Turgay Coşkun[1], Ali Dursun[1]

Divisions of [1]Pediatric Metabolism, and [3]Pediatric Neurology, Department of Pediatrics Faculty of Medicine and [2]Institute of Child Health, Hacettepe University, Ankara, Turkey.
E-mail: unalozlem@gmail.com
Received: 23 September 2014, Revised: 20 March 2015, Accepted: 12 May 2015

SUMMARY: Ünal Ö, Özgül RK, Yücel D, Yalnızoğlu D, Tokatlı A, Sivri HS, Hişmi B, Coşkun T, Dursun A. Two Turkish siblings with MEGDEL syndrome due to novel *SERAC1* gene mutation. Turk J Pediatr 2015; 57: 388-393.

Association of 3-methylglutaconic aciduria with impaired oxidative phosphorylation, deafness, encephalopathy, leigh-like lesions on brain imaging, progressive spasticity and dystonia defined as a distinct entity under the name of MEGDEL syndrome. It is an autosomal recessive disorder due to mutation in the serine active site-containing protein 1 (SERAC1). SERAC1 is localized at the interface between the mitochondria and the endoplasmic reticulum in the mitochondria-associated membrane fraction that is essential for phospholipid exchange. It was identified as a key player in the phosphatidylglycerol remodeling that is essential for both mitochondrial function and intracellular cholesterol trafficking. Here we report two new Turkish sibling patients affected with MEGDEL syndrome due to *SERAC1* gene mutation. The patients were presented with 3-methylglutaconic acid and 3-methylglutaric aciduria, microcephaly, growth retardation, dysmorphic features, severe sensorineural deafness, progressive spasticity, dystonia, seizures, basal ganglia involvement. Metabolic acidosis, mild hyperammonemia and lactic acidemia were accompanied with clinical findings in newborn period.

Key words: MEGDEL syndrome, 3-methylglutaconic aciduria, Deafness, Leigh syndrome, Mitochondrial disease.

MEGDEL syndrome (OMIM 614739), is an autosomal recessive disorder which is clinically characterized by deafness, encephalopathy, progressive spasticity, dystonia, and Leigh-like lesions on neuroimaging. The underlying biochemical abnormality is unknown however patients with MEGDEL syndrome show marked 3-methylglutaconic aciduria with impaired oxidative phosphorylation.[1] Leigh encephalopathy and deafness are differentiating findings of MEGDEL syndrome from other 3-methylglutaconic aciduria syndromes including 3-methylglutaconyl-Coa hydratase deficiency (AUH), Barth syndrome, Costeff syndrome, dilated cardiomyopathy and ataxia syndrome. *SERAC1* gene mutations have been shown to cause MEGDEL syndrome, resulting in abnormal mitochondrial oxidative phosphorylation functions and abnormal accumulation of unesterified cholesterol within cells. Antioxidant defence impairment due to abnormal catalase metabolism/transport.[2]

Here, we present two Turkish siblings with MEGDEL syndrome due to novel *SERAC1* gene mutation.

Case Reports

Case 1

The patient (AF) was the second child to consanguinous parents born at 37 weeks with a birth weight of 2400 g. Newborn period was complicated with respiratory distress, hypoglycemia and presumed sepsis. At 6 months, her parents were concerned that she did not turn to sound and was delayed in motor skills compared to her peers. She was seen at our hospital at 1.5 years of

age for developmental delay, abnormal oral, lingual movements and hearing loss. Physical examination revealed weight 9.5 kg (10-25 p), height 77 cm (25-50 p), head circumference 43.2 cm (<3 p), she had microcephaly, and global developmental delay most prominent in language and gross motor areas. She did not follow objects or respond to sound, she was able to sit with support. Video-EEG monitoring showed normal awake and sleep EEG. Metabolic work up showed markedly increased levels of 3-methylglutaric acid, 3-methylglutaconic acid, and 3OH isovaleric acid in organic acid analysis of urine, and otherwise normal levels for blood pH, ammonia, lactate, pyuvate, aminoacids. Brain stem auditory evoked responses (BAER) was compatible with severe sensorineural hearing loss, visual evoked potentials (VEP) showed bilateral delayed P1 latencies, electroretinogram (ERG) was normal. Brain magnetic resonance imaging (MRI) showed bilateral symmetric lesions on nucleus caudatus and nucleus lentiformis (Fig.1). Leucine restricted diet and carnitine supplementation were started considering the diagnosis of 3-MGA-uria type I.

Neurological evaluation between 2 years 10 months and 4 years 7 months showed a progressive course consisting of oral dyskinezia, choreiform movements involving hands, increased deep tendon reflexes, progressive spasticity and dystonia in all extremities accompanied with growth retardation. Electroencephalography at 3 years of age showed diffuse voltage suppression activity during sleep without epileptiform activity.

At 6 years of age, she had spasticity with clonus and flexion contractures, she was able to sit with support yet had poor had control. Evoked potential responses at that time were similar to inital studies. Magnetic resonance spectroscopy showed decreased NAA at the level of basal ganglia, and lactate elevation in cerebral white matter. Baclofen was added to treatment at this time. 3-methyl glutaconyl-CoA hydratase activity was normal. Around 8.5 years she started to have seizures consisting of staring, right sided stiffening, difficulty breathing. She was started on lamotrigine for management of her seizures.

At 9 years of age, she was admitted to emergency department with questionable seizures wherein she would have stiffnes, trembling of hands, eye deviation, paleness and tendency to sleep. Laboratory work up showed metabolic acidosis (blood pH 7.36 and bicarbonate 13.1 mmol/L) without hypoglycemia and ketonuria and was managed with bicarbonate treatment within 24 hours. Muscle biopsy showed non-specific findings. Repeat organic acid analysis showed similar findings with 5-fold increase in 3-methyl glutaconic acid, 2 -fold increase in 3-methyl glutaric acid, 2/3-fold increase in 3-OH isovaleric acid.

Last follow up at 15 years, showed growth retardation with weight 17 kg (<3p) and height 108 cm (<3p). She had microcephaly with head circumference of 46.5 cm, dysmorphic features including triangular face, pointed chin, prognatism and prominent ears (Fig. 2). Neurological examination was remarkable for decreased eye contact, she followed light but did not fix and follow objects, had restricted conjugate lateral gaze bilaterally, face was hypomimic, decreased gag reflex, swallowing difficulty, she had spasticity and flexion contractures, was able to sit with support and was wheel chair bound. Failure to thrive is noted during follow up.

Case 2

Younger sibling of the first case initially presented to our hospital with growth retardation and developmental delay at one

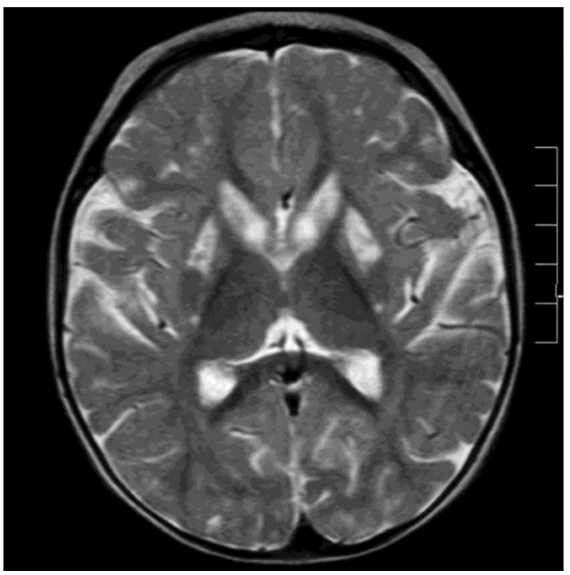

Fig. 1. Cranial magnetic resonance imaging of the first sibling.

Fig. 2. Facial appearence of the first sibling.

year of age. Her medical records revealed that she was born at term with a birth weight of 2680 g (50-75 p), height 49 cm (50-75 p) and head circumference 33 cm (25-50 p). As a newborn she developed respiratory distress, had metabolic acidosis (pH: 7.13 pCO_2: 16.5 mmHg HCO_3^-: 5.2 mmol/L), mildly elevated serum ammonia (245 μg/dL, N: <180) and lactic acid levels (8.3 mmol/L, N: <2). She also had hypoglycemia at 22 mg/dl, blood biochemistry was otherwise within normal limits. Metabolic acidosis was resolved in 8 hours with intravenous bicarbonate treatment, and hypoglycemia was corrected by cessation of oral feedings and administration of intravenous glucose infusions. Ammonia and lactate levels returned to normal limits (43 μg/dL and 2.3 mmol/L, respectively) in two days during the course of intravenous fluid treatment. And, she was gradually started on breast feeding. Urine organic acid analysis showed nonspecific findings, suggestive of liver damage, and no further work up for metabolic disorders were done at that time. Physical examination at 13 months old showed weight 8.4 kg (10-25 p), height 70.5 cm (10 p), head circumference 44 cm (5-10 p), she was able to sit with support, could not walk, and had no verbal output, she was noted to be unresponsive to sound since birth. She was diagnosed with methyl glucotonic aciduria after her older sister and was started on leucine restricted diet and carnitine supplement. Developmentally she functioned at 8 months level in motor skills and at 10 month level in cognitive skills when she was 2 years old, and bilateral sensorineural hearing loss was detected on audiological evaluation. She was started on leucine restricted diet and carnitine supplement at 1 year of age.

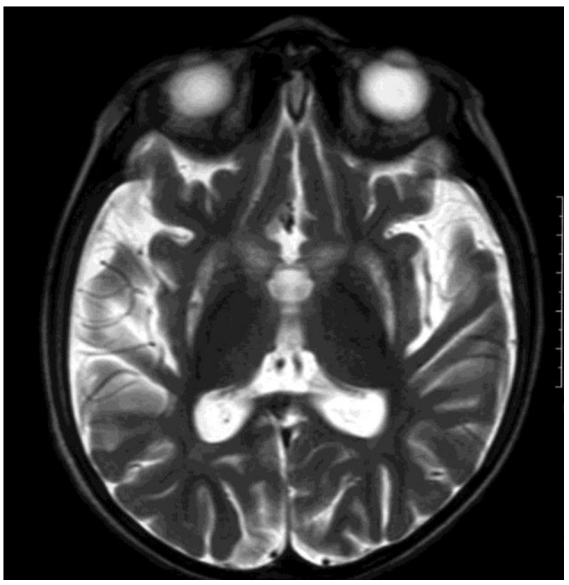

Fig. 3. Cranial magnetic resonance imaging of the second sibling.

Fig. 4. Facial appearance of the second sibling.

Brain magnetic resonance imaging at 20 months of showed hyperintensity of bilateral caudate nuclei, putamen, globus pallidus were seen on T2A weighted sequences, frontal horns of lateral ventricles were dilated due to volume loss of caudate nuclei. At 4 years 8 months of case (Fig. 3) MRS showed decreased n-acetylaspartate levels in basal ganglia due to neuronal loss, and elevated lactate levels in cerebral hemispheres.

At 25 months her growth parameters started to stagger and drop below 3 percentile; her weight was 8900 g (<3 p), height 79 cm (10 p) and head circumference was 44 cm. At 3 years of age she was able to sit without support, and could hold objects but was not able to transfer,

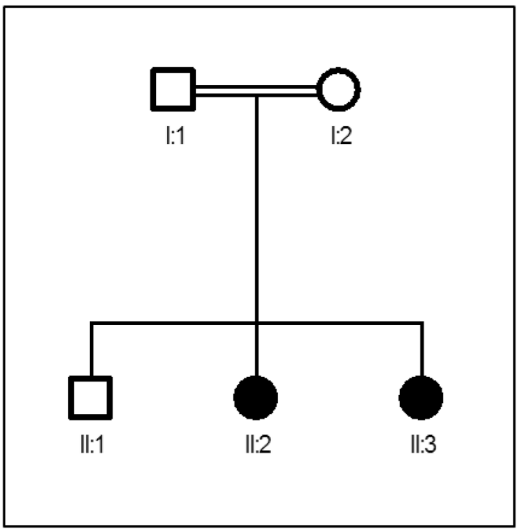

Fig. 5. The pedigree of the family with MEGDEL syndrome.

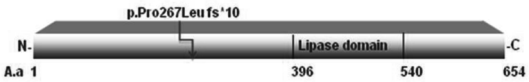

Fig. 6. Schematic representation of SERAC1 protein showing the position of novel mutation. At the protein level this deletion, p. Pro267Leu fs* 10 targets the lipase domain of protein.

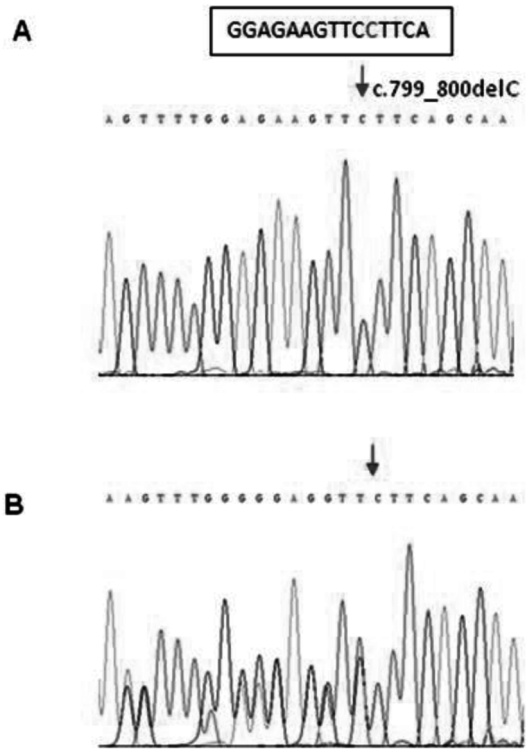

Fig. 7. Sequence chromatograms showing the novel deletion c.799_800delC (p.Pro267Leu fs*10) in SERAC1 gene in affected children (A, arrow), whereas the healthy parents and sibling were heterozygous for the mutation (B, arrow).

she had increased tone in all extremities, and showed no progress in language skills despite hearing aid. Over time she started to lose previously gained skills, around 4 years of age she lost head control, exhibited axial hypotonia, she had choreoatetosis, and could not hold objects. Her cognitive functions were compatible with moderate intellectual disability. Also her failure to thrive and microcephaly became more evident, weight 9 kg (<3 p), height 80 cm (<3 p), head circumference 44 cm. She was treated with baclofen and clonazepam for spasticity after 4 years of age

At 4 years 5 months of case 2 EEG showed disorganized background without epileptiform discharges. Echocardiography was normal. She presented with suspected seizures at 8 years 10 months, consisting of staring stiffening of the body for about 10-15 seconds during wakefulness. She also had nocturnal episodes with sudden eye opening, staring, right more than left sided convulsions and oral automatisms. On examination she had growth retardation and muscle wasting, spasticity with bilateral clonus, flexion contractures at knees and scoliosis, choeroatetoic hand movements and drooling; she was able to sit with support, and had severe intellectual disability. EEG at 9 years of age following onset of seizures, showed mild background slowing and multifocal epileptiform discharges. Follow up EEG at 10.5 years old, under treatment showed bianterior spikes brought by drowsiness and background slowing during wakefulness at 11 years. Brain stem auditory evoked potentials showed depressed Vth wave on the right, visual evoked responces were delayed bilaterally, electroretinogram was normal. She continued to have infrequent seizures sometimes provoked by febrile illness, and received levetiracetam, clonazepam, lamotrigine and clobazam for management of seizures starting from 9 years of age.

At 13 years she had a head circumference of 46 cm, dysmorphic features including triangular face, pointed chin and prominent ears (Fig. 4). She regards face but does not follow objects, fundoscopic examination showed pale optic dics, hypomimic, restricted lateral gaze (MLF signs), sits with support, no involuntary movements, normal deep tendon reflexes with down going toes, flexion contratures at

knees, elbows and hands. She suffers from several daily seizures with eye opening and clonic movements of arms. She required gastrostomy owing to swallowing dificulty, she had progressive spasticity and dystonia and became wheel chair bound.

Mutation Analysis

Peripheral blood samples were collected from all family members. Pedigree of the family was drawn by information obtained from members of the family (Fig. 5). DNA was extracted using iPrep PureLink gDNA blood Kit (Invitrogen). All coding exons and exon-intron boundaries of the *SERAC1 gene* were amplified using primer sets designed by Wortmann et al.[3] PCR was performed with 50 ng of genomic DNA in 25 μl reactions for 35 cycles. PCR fragments were purified with 96-well PCR filter plates (MinElute PCR purification kit, Qiagen Inc., Valencia, CA, USA) and mutation analysis was performed by direct sequencing of purified PCR products. Sequencing reactions were performed using the BigDye Terminator Cycle Sequencing kit (version 3.1) and analyzed on ABI 3130 automated DNA sequencer (Applied Biosystems, CA, USA). The c.799_800delC (p.Pro267Leu fs*10) mutation in *SERAC1* gene was found homozygously in two siblings (Fig. 6 and Fig. 7). Both parents are also heterozygous for the mutation.

Discussion

Here we present two siblings with 3-methylglutaconic acid and 3-methylglutaric aciduria. The clinical picture consists of microcephaly, growth retardation, dysmorphic features, severe sensorineural hearing loss, progressive spasticity, dystonia, and seizures, accompanied by basal ganglia involvement and degeneration consistent with leigh-like syndrome on MRI. Metabolic acidosis, mild hyperammonemia and lactic acidemia were present in the newborn period. The diagnosis of MEGDEL syndrome was confirmed in two siblings by showing homozygous frame shift mutation in SERAC1 gene.

Until today nearly 50 patients were diagnosed with MEGDEL syndrome. In literature, four unrelated girls with an encephalomyopathy associated with mildly and intermittently increased urinary 3-methylglutaconic aciduria were reported.[1,4] Three children were born of 3 nonconsanguineous Turkish parents, and the fourth child was born of unrelated Dutch parents. Furthermore, they reported 11 additional patients with MEGDEL, including 2 relatives of 1 of the Turkish patients reported by Wortmann et al.[1]

Eventually, genetic analysis of 15 individuals from 13 families with 3-methylglutaconic aciduria with deafness, encephalopathy, and Leigh-like syndrome resulted in identification of 14 different homozygous or compound heterozygous mutations in the *SERAC1* gene.[3] The first confirmative mutations in this gene were identified by application of exome sequencing in two affected individuals with the disease. Here we present is the second report of MEGDEL syndrome due to SERAC1 gene mutation following the report of Wortmann et al.[3] that describes novel mutation, its molecular effects and clinical correlation in the literature.

In 2012 Wortmann et al.[3] showed that SERAC gene mutations is responsible for the MEGDEL syndrome. *SERAC1gene* (Serin Active Site Containing 1) is encoding a 654 amino acid protein with a serine-lipase domain. This protein domain is a member of the PGAP-like protein domain family. It is not known about the cellular function of the protein but the information obtained from the presence of a conserved lipase domain having the consensus lipase motif GXSXG strongly suggests a function in lipid metabolism.[5] MEGDEL syndrome is a phospholipid remodeling disorder, but it is also classified as a defect in intracellular cholesterol trafficking.[3]

SERAC1 is a highly conserved, especially its lipase domain, protein present in all eukaryotes. SERAC1 is located at the contact sites between the ER and mitochondria. Fibroblasts taken from MEGDEL syndrome patients had low concentrations of phosphatidylglycerol–36:1, accumulation of phosphatidylglycerol 34:1, which indicate that SERAC1 has roles in catalyzing of remodeling of phosphatidylglycerol and producing phosphatidylglycerol–36:1 as involved in the transacylation-acylation reaction.[3]

Our patients showed typical clinical findings of the syndrome. Metabolic acidosis, increased levels of ammonia, lactate, hypoglycemia detected during newborn period. Brain magnetic resonance imagings showed hyperintensity

of bilateral caudate nuclei, putamen, globus pallidus seen on T2A weighted sequences, dilated frontal horns of lateral ventricles due to volume loss of caudate nuclei. MRS showed decreased n-acetylaspartate levels in basal ganglia due to neuronal loss, and elevated lactate levels in cerebral hemispheres. In our patients, first sibling had microcephaly. Microcephaly was reported for the first time recently, as a presenting feature in patients with MEGDEL syndrome.[6] This patient was also found carrying a new mutation with using exome sequencing. In addition 3-OH-isovaleric acid in urine was a new laboratory finding in our patients. Microcephaly and 3-OH isovaleric acid in urine were rare clinical and laboratory features associated with this syndrome that had been seen in our patients.

Sequencing analysis of *SERAC1 gene* in patients showed homozygous c.799_800delC (p.Pro267Leu fs*10) mutation in exon 9. The parents and healthy sibling were heterozygous carriers of the mutation and it was segregated within the family members (Fig. 2A-B). The mutation would result in the production of a truncated protein without the lipase domain.

Here we reported two siblings with MEGDEL syndome due to a novel mutation in *SERAC1* gene. *SERAC1* gene was selected as a candidate gene for mutation screening since the clinical pictures of our affected siblings are very compatible with reported patients with MEGDEL syndrome. In conclusion MEGDEL syndrome is a rare 3-methylglutaconic aciduria syndrome with typical clinical findings. Genotype phenotype correlation is not known today.

Acknowledgement

Patients were followed up at Hacettepe University, pediatric metabolism and neurology departments. The study supported by The Scientific and Technological Research Council of Turkey (TUBITAK).

REFERENCES

1. Wortmann S, Rodenburg RJ, Huizing M, et al. Association of 3-methylglutaconic aciduria with sensori-neural deafness, encephalopathy, and Leigh-like syndrome (MEGDEL association) in four patients with a disorder of the oxidative phosphorylation. Mol Genet Metab 2006; 88: 47-52.
2. Karkucinska-Wieckowska A, Lebiedzinska M, Jurkiewicz E, et al. Increased reactive oxygen species (ROS) production and low catalase level in fibroblasts of a girl with MEGDEL association (Leigh syndrome, deafness, 3-methylglutaconic aciduria). Folia Neuropathol 2011; 49: 56-63.
3. Wortmann SB, Vaz FM, Gardeitchik T, et al. Mutations in the phospholipid remodeling gene SERAC1 impair mitochondrial function and intracellular cholesterol trafficking and cause dystonia and deafness. Nat Genet 2012; 44: 797-802.
4. Wortmann SB, Rodenburg RJ, Jonckheere A, et al. Biochemical and genetic analysis of 3-methylglutaconic aciduria type IV: a diagnostic strategy. Brain 2009;132:136–146.
5. Derewenda ZS, Sharp AM. News from the interface: the molecular structures of triacylglyceride lipases. Trends Biochem Sci 1993; 18: 20-25.
6. Tort F, García-Silva MT, Ferrer-Cortès X, et al. Exome sequencing identifies a new mutation in SERAC1 in a patient with 3-methylglutaconic aciduria. Mol Genet Metab 2013; 110: 73-77.