THE MEDICAL BULLETIN OF
SISLI ETFAL HOSPITAL

DOI: 10.14744/SEMB.2021.01878
Med Bull Sisli Etfal Hosp 2022;56(1):154–160

Original Research

Curcumin Enhanced the Neomucosa Formation by Mediating the Antioxidation Mechanism in Rats

Nadir Adnan Hacim,[1] Ahmet Akbas,[2] Osman Bilgin Gulcicek,[2] Serhat Meric,[2] Ali Solmaz,[3] Erkan Yavuz,[2] Hakan Yigitbas,[2] Yigit Ulgen,[4] Gulcin Ercan,[2] Aysegul Kirankaya,[5] Atilla Celik[2]

[1]Department of General Surgery, Şişli Hamidiye Etfal Training and Research Hospital, Istanbul, Turkey
[2]Department of General Surgery, Bagcilar Training and Research Hospital, Istanbul, Turkey
[3]Department of General Surgery, Erdem Hospitals Group, Istanbul, Turkey
[4]Department of Pathology, Bagcilar Training and Research Hospital, Istanbul, Turkey
[5]Department of Biochemistry, Bagcilar Training and Research Hospital, Istanbul, Turkey

Abstract

Objectives: The purpose of the study was to examine the possible effects of curcumin on the formation of neomucosa in parietal peritoneum which was applied as a patch for terminal ileal defect in rats.

Methods: Sixteen male Wistar Hannover rats were split into two groups. The control group was injected with saline and curcumin (2 mL/kg/day, by gavage) was given to the experimental group. In both groups, amounts of 8-hydroxy-2′-deoxyguanosine (8-OHdG) and malondialdehyde (MDA), the activities of glutathione peroxidase and superoxide dismutase were determined in serum. The development of neomucosa formation was examined morphologically.

Results: Serum antioxidant levels and glutathione peroxidase activity in rats given curcumin were significantly higher than those of the control group ($p<0.05$). The levels of oxidative markers (MDA and 8-OHdG) in rats given curcumin were significantly lower than those of the control group ($p<0.05$). In the histopathological examination, 62.5% of rats in the curcumin group showed formation of neomucosa while 37.5% of control rats showed neomucosa.

Conclusion: The use of curcumin in rats with terminal ileal defect enhanced the formation of neomucosa by decreasing the oxidation level and increasing the antioxidation level. Curcumin may be used in the patients with short bowel syndrome to increase the absorption surface area.

Keywords: Curcumin, neomucosa, short bowel syndrome

Please cite this article as "Hacim NA, Akbas A, Gulcicek OB, Meric S, Solmaz A, Yavuz E, et al. Curcumin Enhanced the Neomucosa Formation by Mediating the Antioxidation Mechanism in Rats. Med Bull Sisli Etfal Hosp 2022;56(1):154–160".

Short bowel syndrome (SBS) is a disease described by the reduced length of the small intestines, causing a lack of absorption of fluids or nutrients necessary for the body from the small intestines.[1] SBS is usually seen in adulthood after surgical procedures that cause massive bowel resection. It may occur in childhood due to congenital reasons or in cases where massive bowel resection is performed early in life.[2] Patients with SBS require long-term parenteral nutrition due to digestive and absorption disorders. However, this situation still results in a considerable increase in the mortality and morbidity of the patient in the long term.[3-5] The intestinal ab-

Address for correspondence: Nadir Adnan Hacim, MD. Sisli Hamidiye Etfal Egitim ve Arastirma Hastanesi, Genel Cerrahi Klinigi, Istanbul, Turkey
Phone: +90 505 260 71 05 **E-mail:** adnanhcm@hotmail.com

Submitted Date: November 13, 2021 **Accepted Date:** December 21, 2021 **Available Online Date:** March 28, 2022

©Copyright 2022 by The Medical Bulletin of Sisli Etfal Hospital - Available online at www.sislietfaltip.org
OPEN ACCESS This is an open access article under the CC BY-NC license (http://creativecommons.org/licenses/by-nc/4.0/).

sorption and digestion can be successfully optimized by reconstructive operations of the remaining intestine and intestinal transplantation.[6,7] While all procedures are still experimental, the main goal of reconstructive operations is to slow bowel transit time and promote the formation of new intestinal mucosa, namely, neomucosa.

Studies on curcumin, which has a polyphenol structure, have shown that the curcumin has effects on some transcription factors, kinases, cytokines, enzymes, growth factors, and receptors.[8] In addition to its strong antioxidant, immunomodulatory, antimicrobial, anti-inflammatory, hypoglycemic, renoprotective, and hepatoprotective effects, it is a mucosal protector against mucosal injuries and increases healing, has anticancer properties.[8-12]

The serosal patch technique is used to enlarge the area of intestinal mucosa. The neomucosa should be developed to enlarge the absorbent surface, and therefore, some substances are used to act on this neomucosa.[13]

Since the curcumin has been suggested to have protective effects on the intestinal ischemia-reperfusion injury, in the present study, we aimed to examine the possible effects of curcumin on neomucosa formation in the parietal peritoneum, which was applied as a patch for terminal ileal defect in rats.

Methods

Animals

Sixteen Wistar Hannover male rats (300–500 g) were included in the study. They were kept in cages at room temperature (21±20° C) and humidity (60–70%) under conditions regulated by a 12 h light-dark schedule. All rats were fed ad libitum with standard pellet. Local Ethical Committee of University of Health Sciences approved the protocol of study (Project no: 2019-134).

Chemicals and Reagents

To obtain curcumin, a curcuminoid mixture (Sigma, C1386, St. Louis, MO, USA) was dissolved in corn oil at a concentration of 1 mg/mL and stored at 4° C used in dark glass vials.

Study Groups

Sixteen rats were randomly splitted into two groups (n=8). Group 1 was designated as the control group which was injected with saline following the procedure of enteroperitoneal anastomosis between the mucosal surface of parietal peritoneum and ileum (adherent to the abdominal wall). Group 2 was designated as experimental group and 2 mL/kg/day dose of curcumin was applied by gavage after introducing the same anastomosis procedure.

Surgical Procedure

Rats were anesthetized by an isoflurane (2% for maintenance and 5% for induction, Isoflurane; Baxter, Puerto Rico, USA). Under the sterile conditions, 3 cm midline abdominal incision was performed, and 1 cm longitudinal incision was performed in ileal region to establish a terminal ileal defect. The full-thickness defect of ileum patched with (anastomosis) peritoneum surface was closed with continuous 6.0 polypropylene sutures (Fig. 1). The effects of curcumin on anastomosis were determined by microscopic and biochemical analyzes. Biochemical analyses were performed by measuring serum oxidant and antioxidant values obtained from rats. Biochemical analyses of the serum stored at minus 20° C were performed within 3 days at the latest.

At the 14th days of procedure, each rat was euthanized under anesthesia, and the blood was collected by the cardiac puncture, centrifuged (3000 rpm for 10 min) to collect serum. It stored at −20°C for biochemical studies. Anastomotic part of terminal ileum and parietal peritoneum was resected after the midline laparotomy (Fig. 2), the tissues were washed with saline. They were fixed in 10% formaldehyde solution for the pathological evaluation.

Biochemical Analyses

After the macroscopic analyses, the amounts of 8-hydroxy-2'-deoksiguanozin (8-OHdG) and malondialdehyde (MDA) were measured to determine the oxidative damage. The enzyme activities of superoxide dismutase (SOD) and glutathione peroxidase (GPx) were measured to determine the serum antioxidant levels.

Plasma 8-OHdG level was measured using a highly sensitive enzyme-linked immunosorbent assay detection kit (Elabscience, Texas, USA).[14] Outcome was presented as ng/ml.

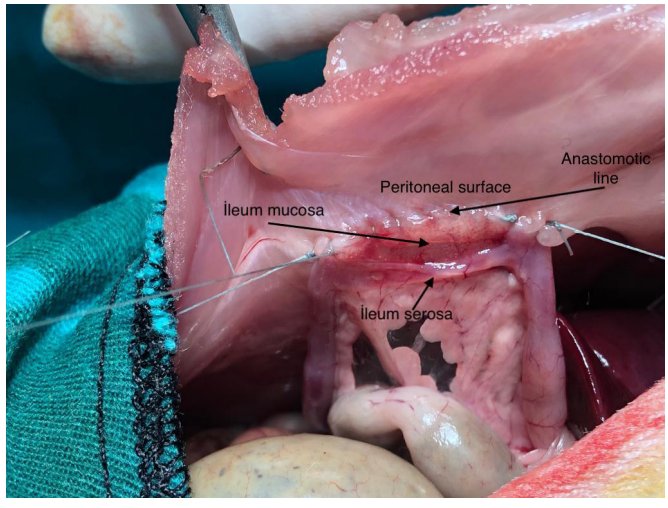

Figure 1. Surgical procedure; ileum patched with (anastomosis) peritoneum surface.

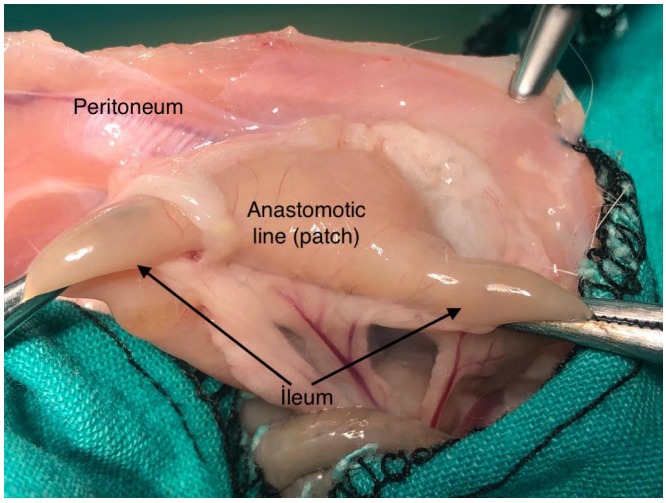

Figure 2. Appearance of anastomotic line on the post-operative 14th days.

The levels of MDA were measured in serum by a colorimetric method described by Yoshioka et al.,[15] in which a thiobarbituric acid reagent was used to generate a pink product under acidic conditions and to determine the outcom e at 532 nm as mmol MDA/L.

SOD activity was measured using a xanthine oxidase system described by Sun et al.,[16] in which nitroblue tetrazolium was used as an indicator. The outcome was presented as U/mL.

GPx activity was measured using the technique described by Matkovics et al.[17] at 37°C and 412 nm and the outcome was presented as U/L.

Histopathological Analysis

The anastomotic regions were dissected, and the tissues were fixed in 10% formaldehyde and underwent a routine histological process for paraffin embedding. The paraffin sections were obtained in 4 µm thickness and stained by hematoxylin-eosin to determine the presence of neomucosa formation. Alcian blue (pH: 2.5) staining was performed to examine the intestinal type mucin and Masson's trichrome staining was performed to examine the fibroblastic activity in the neomucosal region.

Statistical Analysis

Number Cruncher Statistical System 2007 Statistical Software program was used for all statistical analysis. Descriptive data were presented as the standard and mean deviation. The group comparison was performed by Mann–Whitney U-test. The qualitative data were compared by Fisher's exact test. The significance level was determined as 0.05.

Results

Biochemical Findings

The MDA level of the control group (0.40±0.13 mmol/L) was significantly higher than the level of the curcumin group (0.18±0.07 mmol/L) (p=0.03). The 8-OHdG value of the control group (1.85±0.06 ng/ml) was also higher than those of the curcumin group (1.47±0.21 ng/ml) (p=0.03). According to these results, the oxidative damage implied by MDA and 8-OHdG in rats treated with curcumin significantly reduced compared with the damage in the control group (p<0.05) (Table 1).

SOD activity measured in the rats treated with the curcumin (237.70±49.91 U/ml) was significantly higher than the activity measured in control rats (181.68±19.42 U/ml) (p=0.03). The GPx activity of the curcumin group (396.87±91.76 U/L) was significantly higher than the activity of the control group (183.16±48.37 U/L) (p=0.01). According to these results, the antioxidant activity in rats treated with the curcumin increased significantly compared with the activity in the control group (p<0.05) (Table 1).

Histopathological Findings

As presented in Figures 3 and 4, the intestinal neomucosa formation on the peritoneal surface appears to be significantly increased with the use of curcumin in rats compared to the control group. The villus height, surface area, mucosa thickness, and crypt depth were significantly higher in the curcumin group than those in the control group. The presence of goblet cells and mucin, granulation tissue, and fibroblastic activity was more prominent in the curcumin group. Ulceration and active chronic inflammatory cell infiltration were similar between the two groups.

As a result of the histopathological evaluation, the neomucosa formation was observed in 3 rats (37.5%) in the control group, while it was observed in 5 rats (62.5%) in the curcumin-treated group (Fig. 5). Formation of neomucosa was more frequent in the curcumin group compared with the control group without any significant difference (p>0.05) (Table 2).

Table 1. Comparison of the levels of SOD, GPx, MDA, and 8-OHdG measured in the rats of the control and curcumin groups

	Control group	Curcumin group	p
SOD (U/ml)	181.68±19.42	237.70±49.91	0.03
GPx (U/L)	183.16±48.37	396.87±91.76	0.01
MDA (nmol/L)	0.40±0.13	0.18±0.07	0.03
8-OHdG (ng/ml)	1.85±0.06	1.47±0.21	0.03

SOD: Serum antioxidant levels; GPx: Glutathione peroxidase; MDA: Malondialdehyde, 8-OHdG: 8-hydroxy-2'-deoksiguanozin.

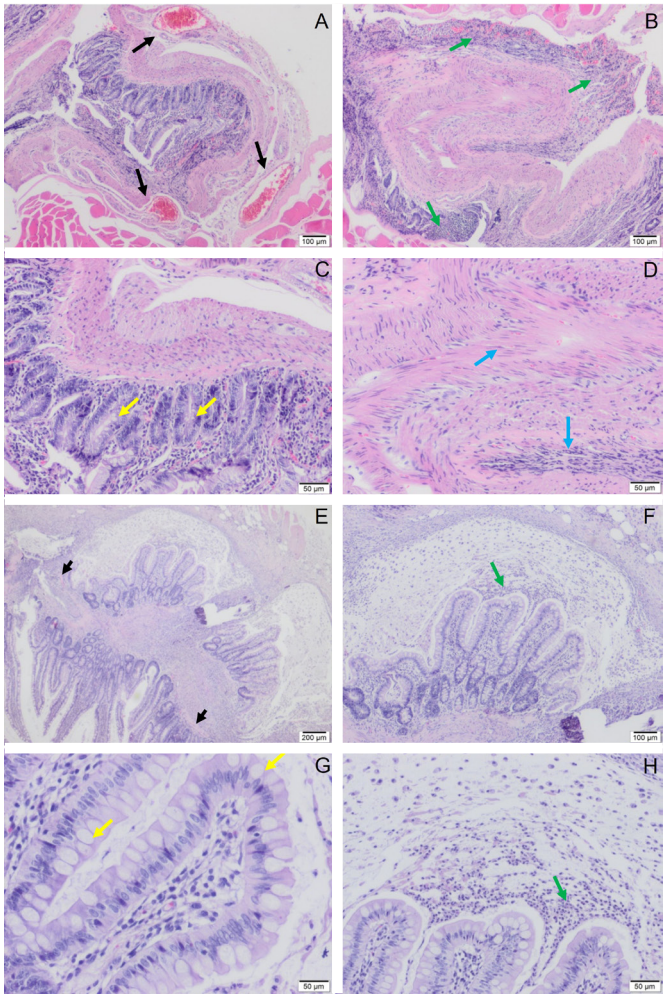

Figure 3. The histological micrographs of the formation of intestinal neomucosa on the peritoneal surface in the rats. **(a-d)** The control group (Scales: 100 µm for a and b; 50 µm for c and d). **(e-h)** The curcumin group (Scales: 200 µm for e; 100 µm for f; 50 µm for g and h). General view of the neomucosa showed vascularization in the submucosa (black arrow), granulation tissue formation (green arrow), glandular structures and goblet cells (blue arrow), and fibroblastic proliferating areas (yellow arrow). Hematoxylin-eosin staining).

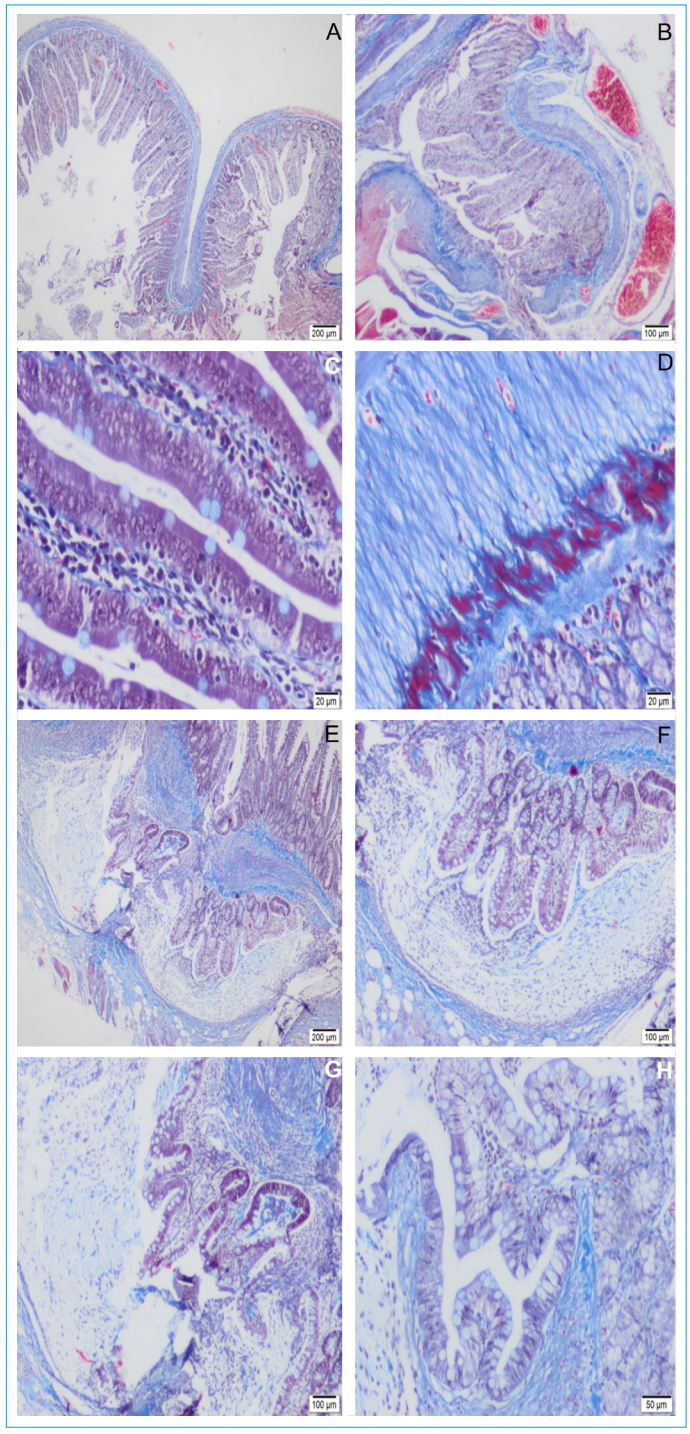

Figure 4. The histological micrographs of the formation of intestinal neomucosa on the peritoneal surface in the rats. **(a-d)** The control group (Scales: 200 µm for a; 100 µm for b; 20 µm for c and d). **(e-h)** The curcumin group (Scales: 200 µm for e; 100 µm for f and g; 50 µm for h). Masson trichrome staining.

Discussion

SBS is one of the common reasons of intestinal failure, which occurs after massive bowel resection. Pediatric SBS results from intussusception, aganglionosis, gastroschisis, small bowel atresia, volvulus, and necrotizing enterocolitis.[18-21] Adult SBS results from the strangulated bowel, trauma, ischemia, and Crohn's disease. In cases where intestinal absorption is impaired, dehydration, electrolyte disturbances, and even death may occur.[18] This condition is managed by a complex and multidisciplinary methodology including the parenteral nutrition and surgical treatment. A number of patients with SBS need a long-term parenteral nutrition which results in several complications including the catheter failure, life-threatening infections, metabolic complications such as venous thromboembolism and liver and kidney damage, and even finally organ failure.[4,19] The rat models are intensely used in the studies to develop a treatment which increase the intestinal absorption in SBS.[22] In

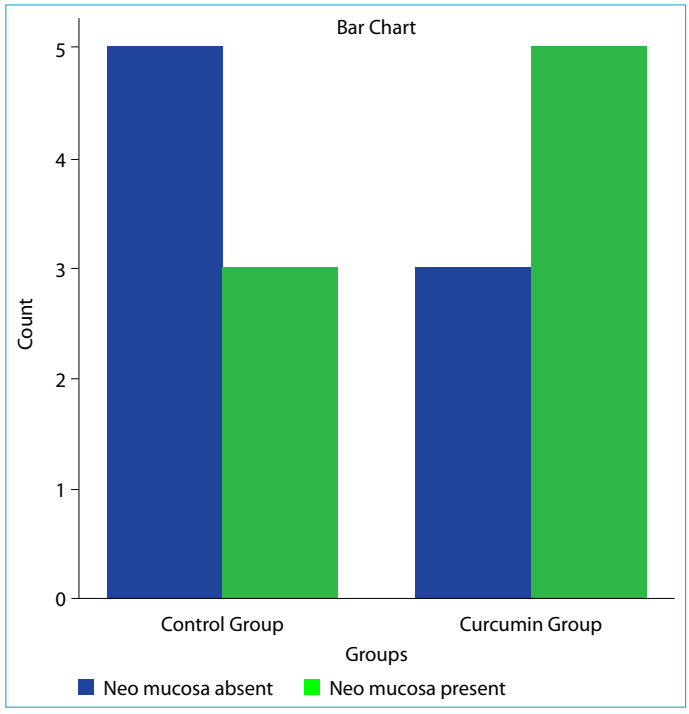

Figure 5. The graphical presentation of the frequency of neomucosa formation in the rats of control group and the curcumin-treated group.

Table 2. The frequency of rats showed the neomucosa formation

Neomucosa	Control group (%)	Curcumin group (%)	p
Absent	5 (62.5)	3 (37.5)	0.619
Present	3 (37.5)	5 (62.5)	

the present study, we examined the possible effects of curcumin on the formation of neomucosa in parietal peritoneum which was applied as a patch for terminal ileal defect in rats. We found that the serum antioxidant levels and GPx activity in rats given curcumin were significantly higher than those of control group. Moreover, levels of oxidative markers (MDA and 8-OHdG) in rats given curcumin were significantly lower than those of control group. Pathological examination revealed that 62.5% of rats in the curcumin group showed the formation of neomucosa while 37.5% of control rats showed neomucosa formation.

Today, the surgical procedures for SBS include the construction of intestinal valves or reversed intestinal segments, autologous reconstruction procedures consisting of growing mucosal surface area, colon interposition, intestinal transplantation, and lengthening bowel.[21] However, the success of these procedures is still controversial. The basic autologous intestinal reconstruction surgeries are non-transplant modalities including the serial transverse enteroplasty (STEP) and the longitudinal intestinal lengthening and tailoring (LILT) also called as Bianchi procedure. LILT and STEP procedures are both used to eliminate parenteral nutrition dependence, however, coming with some severe complications including the formation of bleeding and stricture leakage. Intestinal transplantation is the last choice for the treatment of SBS and should be performed by experienced surgeons at specialized clinics due to possibilities of severe complications. However, the worldwide morbidity and mortality rates of intestinal transplantation are still very high.[22]

The neomucosa used for serosal patching is an experimental method to grow new intestinal mucosa and enlargement of absorptive surface of intestinal mucosa. The regenerated intestinal mucosa is formed by the lateral ingrowth of adjacent mucosa which shows similar functions with the normal mucosa.[4] In the literature, several studies have employed the experimental models for growing the neomucosa using serosal patch technique. In these studies, the serosal surface of intestine, peritoneal, and colon surface has been utilized to establish a serosal patch.[2,7,23] Some reports have demonstrated that the glutamine can be used to increase the absorption surface area by helping the formation of neomucosa in SBS model.[4] In our study, we found that the curcumin treatment increased the formation of neomucosa in rats with terminal ileal defect probably by reducing the oxidative stress.

Curcumin carries several biological features including anti-inflammatory, antioxidant activities, and anticancer effects. Curcumin was also examined as a therapeutic agent selected for the treatment of wounds after the surgical procedures.[4] It was reported that the curcumin-treated wound tissues had a large number of infiltrating cells, such as neutrophils, fibroblasts, and macrophages, in comparison to the untreated wounds. All these cells are known to involve in granulation tissue formation, as the wound contraction proceeds and resistance increases, while the fibroblasts differentiate into myofibroblasts.[24,25] The granulation tissue is also formed during the neomucosa formation as observed in our study. The curcumin-treated rats showed more enlarged neomucosa and granulation tissue, angiogenetic areas, glandular structures producing mucins, and extensive clusters of fibroblasts compared to the control rats.

A strong inflammatory infiltration and high levels of reactive oxygen species (ROS) cause cytotoxicity in the tissues and accepted as an indicator of the presence of oxidative stress. Elimination of ROS is important in novel tissue formation.[26] Enzymatic (catalase, SOD, and GPx) and non-enzymatic (glutathione) antioxidants play an important role in the defense mechanism against the oxidative stress, by reducing or completely eliminating the effects of ROS, hence preventing the damage to cells and tissues.[27,28] In a study conducted on 18 mice with vitiligo disease,

as oxidative stress parameters, the catalase and SOD levels were found to be lower in vitiligo mice compared to mice in the control group. In the detailed evaluation, it was thought that oxidative stress was an important cause in the formation of the disease.[29] SOD, which is dimeric, is Cu/Zn dependent and is cultivated in different phases of wound healing but is more effective in the early stages of the inflammation phase. It has been shown to shorten the wound healing process when applied topically.[24,26,29,30] Some studies showed that their topical application significantly improved the damage caused by free radicals.[31-33] Therefore, the measurements of antioxidants including glutathione, SOD, and catalase in the granulation tissues are valuable since these antioxidants accelerate the process of wound healing by destroying the free radicals.[34] In our study, we found that curcumin accelerated healing by greatly reducing oxidative stress. At the same time, SOD and GPx levels were found to be higher in rats treated with curcumin compared to the control group, and the formation of neomucosa was more frequent.

Curcumin was shown to have a significant protective effect against free radicals and hence oxidative stress by acting as a scavenger of ROS. If ROS increases, the levels of MDA which is the end product of lipid peroxidation and of 8-OHdG which is a marker for the oxidative DNA damage increase.[35] Blood levels of MDA and 8-OHdG are important indicators of endogenous oxidative damage to DNA. Nakai et al. measured MDA and 8-OHdG in patients with psoriasis and atopic dermatitis and healthy individuals to evaluate the oxidative stress and found that the urinary 8-OHdG and MDA levels were higher in patients with psoriasis compared to the control group.[35] In another study, it was evaluated indirectly as an indicator of lipid peroxidation by the measurement of MDA.[36] Other study showed that a significant change in antioxidant profile accompanied by high MDA levels was attributed to impaired wound healing in immunocompromised rats.[34] The results of our study were in consistent to the literature. In our study, 8-OHdG and MDA levels, which show the oxidative stress level in rats treated with curcumin, were lower than the control group, and it was observed that curcumin enhanced the neomucosa formation in rats.

Conclusion

The use of curcumin in rats with terminal ileal defect enhanced the formation of neomucosa by decreasing the oxidation level and increasing the antioxidation level. Therefore, curcumin may be beneficial in patients undergoing enteroperitoneal anastomosis between mucosal surface of ileum and parietal peritoneum (adherent to abdominal wall) and may be effective in patients with SBS to increase the absorption surface area as an alternative to the complex treatment modalities which result in high morbidity and mortality rates. Considering the aforesaid effects of curcumin, the prospective randomized in vivo studies are required to be conducted for the clinical use of curcumin in SBS.

Disclosures

Ethics Committee Approval: Local Ethical Committee of University of Health Sciences approved the protocol of study (Project no: 2019-134).

Peer-review: Externally peer-reviewed.

Conflict of Interest: None declared.

Authorship Contributions: Concept – N.A.H., A.A., O.B.G.; Design – N.A.H., O.B.G.; Supervision – G.E., S.M.; Materials – N.A.H., A.S., E.Y., G.E.; Data collection &/or processing – N.A.H., O.B.G., H.Y., G.E.; Analysis and/or interpretation – N.A.H., A.K., Y.Ü.; Literature search – N.A.H., A.S., S.M.; Writing – N.A.H., A.A.; Critical review – A.C., O.B.G.

References

1. Jeppesen PB. New approaches to the treatments of short bowel syndrome-associated intestinal failure. Curr Opin Gastroenterol 2014;30:182–8.
2. Greig CJ, Oh PS, Gross ER, Cowles RA. Retracing our STEPs: Four decades of progress in intestinal lengthening procedures for short bowel syndrome. Am J Surg 2019;217:772–82.
3. Yang GT, Zhao HY, Kong Y, Sun NN, Dong AQ. Study of the effects of nesfatin-1 on gastric function in obese rats. World J Gastroenterol 2017;23:2940–7.
4. Gulcicek OB, Solmaz A, Yiğitbaş H, Ercetin C, Yavuz E, Ozdogan K, et al. Comparison of the effects of glutamine, curcumin, and nesfatin-1 on the gastric serosal surface neomucosa formation: an experimental rodent model. Gastroenterol Res Pract 2016;2016:2081962.
5. Yildiz BD. Where are we at with short bowel syndrome and small bowel transplant. World J Transplant 2012;2:95–103.
6. Kesseli S, Sudan D. Small bowel transplantation. Surg Clin North Am 2019;99:103–16.
7. Totonelli G, Tambucci R, Boscarelli A, Hermans D, Dall'Oglio L, Diamanti A, et al. Pediatric intestinal rehabilitation and transplantation registry: initial report from a European collaborative registry. Eur J Pediatr Surg 2018;28:75–80.
8. Kocaadam B, Şanlier N. Curcumin, an active component of turmeric (Curcuma longa), and its effects on health. Crit Rev Food Sci Nutr 2017;57:2889–95.
9. Roy S, Rhim JW. Antioxidant and antimicrobial poly (vinyl alcohol)-based films incorporated with grapefruit seed extract and curcumin. J Environ Chem Eng 2021;9:104694.
10. Boroumand N, Samarghandian S, Hashemy SI. Immunomodulatory, anti-inflammatory, and antioxidant effects of curcumin. J

HerbMed Pharmacol 2018;7:211–9.
11. Akar İ, İnce İ, Arici A, Benli İ, Aslan C, Şenol S, et al. The protective effect of curcumin on a spinal cord ischemia-reperfusion injury model. Ann Vasc Surg 2017;42:285–92.
12. Ng QX, Soh AYS, Loke W, Venkatanarayanan N, Lim DY, Yeo WS. A meta-analysis of the clinical use of curcumin for irritable bowel syndrome (IBS). J Clin Med 2018;7:298.
13. Millar AJ. Non-transplant surgery for short bowel syndrome. Pediatr Surg Int 2013;29:983–7.
14. Lee J, Lee M, Kim JU, Song KI, Choi YS, Cheong SS. Carvedilol reduces plasma 8-hydroxy-2'-deoxyguanosine in mild to moderate hypertension: a pilot study. Hypertension 2005;45:986–90.
15. Yoshioka T, Kawada K, Shimada T, Mori M. Lipid peroxidation in maternal and cord blood and protective mechanism against activated-oxygen toxicity in the blood. Am J Obstet Gynecol 1979;135:372–6.
16. Sun Y, Oberley LW, Li Y. A simple method for clinical assay of superoxide dismutase. Clin Chem 1988;34:497–500.
17. Matkovics B. Determination of enzyme activity in lipid peroxidation and glutathione pathways. Laboratoriumi Diagnosztika 1988;15:248–50.
18. Jeppesen PB. Gut hormones in the treatment of short-bowel syndrome and intestinal failure. Curr Opin Endocrinol Diabetes Obes 2015;22:14–20.
19. Jeppesen PB. New approaches to the treatments of short bowel syndrome-associated intestinal failure. Curr Opin Gastroenterol 2014;30:182–8.
20. Ekici U, Ferhatoğlu MF, Çitgez B, Uludağ M. Effects of the folk medicinal plant extract ankaferd bloodstopper on the healing of colon anastomosis: an experimental study in a rat model. Sisli Etfal Hastan Tip Bul 2019;53:154–9.
21. Sommovilla J, Warner BW. Surgical options to enhance intestinal function in patients with short bowel syndrome. Curr Opin Pediatr 2014;26:350–5.
22. Frongia G, Kessler M, Weih S, Nickkholgh A, Mehrabi A, Holland-Cunz S. Comparison of LILT and STEP procedures in children with short bowel syndrome -- a systematic review of the literature. J Pediatr Surg 2013;48:1794–805.
23. Freud E, Eshet R. Insights from animal models for growing intestinal neomucosa with serosal patching--a still untapped technique for the treatment of short bowel syndrome. Lab Anim 2001;35:180–7.
24. Altinel Y, Kose E, Karacaglar A, Demirgan S, Sozer V, Ozkaya G, et al. Systemic amelioration via curcumin in rats following splenectomy: lipid profile, endothelial and oxidative damage. J Invest Surg 2021;34:627–36.
25. Panchatcharam M, Miriyala S, Gayathri VS, Suguna L. Curcumin improves wound healing by modulating collagen and decreasing reactive oxygen species. Mol Cell Biochem 2006;290:87–96.
26. Shetty S, Udupa S, Udupa L. Evaluation of antioxidant and wound healing effects of alcoholic and aqueous extract of ocimum sanctum linn in rats. Evid Based Complement Alternat Med 2008;5:95–101.
27. Buyuklu M, Kandemir FM, Ozkaraca M, Set T, Bakirci EM, Topal E, et al. Benefical effects of lycopene against contrast medium-induced oxidative stress, inflammation, autophagy, and apoptosis in rat kidney. Hum Exp Toxicol 2015;34:487–96.
28. Kandemir F, Benzer F, Yildirim N, Ozdemir N. Compensatory effects of curcumin on cisplatin-induced toxicity in rabbit testis. J Med Plants Res 2011;5:456–61.
29. Jalel A, Yassine M, Hamdaoui MH. Oxidative stress in experimental vitiligo C57BL/6 mice. Indian J Dermatol 2009;54:221–4.
30. Odabasoglu F, Cakir A, Suleyman H, Aslan A, Bayir Y, Halici M, et al. Gastroprotective and antioxidant effects of usnic acid on indomethacin-induced gastric ulcer in rats. J Ethnopharmacol 2006;103:59–65.
31. Cinar AS, Sayin P, Celayir MF. Relationship between Gastric pH measurement and ıntra-abdominal pressure in patients undergoing laparoscopic surgery. Sisli Etfal Hastan Tip Bul 2020;54:463–8.
32. Parihar A, Parihar MS, Milner S, Bhat S. Oxidative stress and antioxidative mobilization in burn injury. Burns 2008;34:6–17.
33. Latha B, Babu M. The involvement of free radicals in burn injury: a review. Burns 2001;27:309–17.
34. Al-Khowaiter SS, Brahmania M, Kim E, Madden M, Harris A, Yoshida EM, et al. Clinical and endoscopic significance of bowel-wall thickening reported on abdominal computed tomographies in symptomatic patients with no history of gastrointestinal disease. Can Assoc Radiol J 2014;65:67–70.
35. Nakai K, Yoneda K, Maeda R, Munehiro A, Fujita N, Yokoi I, et al. Urinary biomarker of oxidative stress in patients with psoriasis vulgaris and atopic dermatitis. J Eur Acad Dermatol Venereol 2009;23:1405–8.
36. Pietta PG, Simonetti P, Gardana C, Cristoni S, Bramati L, Mauri PL. LC-APCI-MS/MS analysis of urinary 8-hydroxy-2'-deoxyguanosine. J Pharm Biomed Anal 2003;32:657–61.