THE MEDICAL BULLETIN OF
SISLI ETFAL HOSPITAL

DOI: 10.14744/SEMB.2022.82584
Med Bull Sisli Etfal Hosp 2022;56(2):256–261

Original Research

Intrathyroidal Parathyroid Adenomas in Primary Hyperparathyroidism: Clinical and Imaging Findings

Selda Gucek Haciyanli,[1] Serkan Karaisli,[1] Nezahat Erdogan,[2] Bulent Turgut,[3] Emine Ozlem Gur,[1] Mehmet Haciyanli[1]

[1]Department of General Surgery, Izmir Kâtip Celebi University Ataturk Training and Research Hospital, Izmir, Turkey
[2]Department of Radiology, Izmir Kâtip Celebi University Ataturk Training and Research Hospital, Izmir, Turkey
[3]Department of Nuclear Medicine, Izmir Kâtip Celebi University Ataturk Training and Research Hospital, Izmir, Turkey

Abstract

Objectives: Primary hyperparathyroidism (PHPT) is a common endocrine disease. Ectopic adenomas may cause a failed surgery which results in persistence or recurrence. Intrathyroidal parathyroid adenoma (ITPA) is a rare reason for PHPT and site of ectopia. Herein, we aimed to investigate the clinical and imaging features of patients with ITPAs and the effectiveness of radiological tools for localization at a tertiary reference center.

Methods: The files of 708 consecutive patients who underwent parathyroidectomy for PHPT in our department between January 2007 and December 2021 were investigated retrospectively. PHPT patients with ITPA were included in the study. Patients with missing data were excluded from the study. Clinicopathological features of the patients and radiological evaluation findings were investigated.

Results: Twenty-eight (28/708: 3.9%) patients were included in the study. The complete intrathyroidal gland and subcapsular parathyroid gland were observed in 8 (1.1%) and 20 (2.8%) patients, respectively. The ultrasound and parathyroid scintigraphy revealed the accurate localization of ITPA in 25 (89.3%) and 18 (64.3%) patients, respectively. Additional imaging modalities were applied for 10 patients in which conventional localization studies were discordant or inconclusive. ITPAs were most commonly found in the lower gland (n=20) localization. All patients had a successful parathyroidectomy and neither persistence nor recurrence was occurred in the study group.

Conclusion: The ITPAs are rare in PHPT. The ultrasound has a high diagnostic rate in experienced hands. The second-line imaging methods may be favorable in the presence of negative or discordant scans. The pre-operative localization studies can detect the ITPAs in most patients, so blind thyroidectomy should be avoided.

Keywords: Adenoma, hyperparathyroidism, intrathyroidal, parathyroidectomy, thyroid

Please cite this article as "Gucek Haciyanli S, Karaisli S, Erdogan N, Turgut B, Gur O, Haciyanli M. Intrathyroidal Parathyroid Adenomas in Primary Hyperparathyroidism: Clinical and Imaging Findings. Med Bull Sisli Etfal Hosp 2022;56(2):256–261".

Primary hyperparathyroidism (PHPT) is an endocrine disease that affects 0.1–0.7% of the general population[1] and parathyroidectomy is the only effective and definitive treatment choice for the disease. After the establishment of diagnosis of PHPT, the localization of the pathological parathyroid gland(s) should be investigated. Since the most common cause is a single gland adenoma, accurate pre-operative localization of the diseased gland

Address for correspondence: Selda Gucek Haciyanli, MD. Izmir Kâtip Celebi Universitesi Ataturk Egitim ve Arastirma Hastanesi, Genel Cerrahi Anabilim Dali, Izmir, Turkey
Phone: +90 232 244 44 44 **E-mail:** msgucek@hotmail.com

Submitted Date: March 24, 2022 **Accepted Date:** April 07, 2022 **Available Online Date:** June 28, 2022

©Copyright 2022 by The Medical Bulletin of Sisli Etfal Hospital - Available online at www.sislietfaltip.org
OPEN ACCESS This is an open access article under the CC BY-NC license (http://creativecommons.org/licenses/by-nc/4.0/).

improves surgical success and enables focused approaches in those patients.[2] The ultrasonography (US) and technetium-99m sestamibi scintigraphy (±single-photon emission computed tomography [SPECT]) are first-step imaging modalities to determine the accurate location of parathyroid adenoma.[3]

Ectopic adenomas may cause the failure of the surgery and consequently the persistent or recurrent disease.[3,4] Intrathyroidal or thyroid subcapsular area is one of the typical ectopic localizations of adenoma in patients with PHPT with an incidence between 0.5% and 4.3% in most studies[3,5] and a cause of failed exploration in a substantial proportion of patients having surgery unless preoperatively non-localized in imaging studies. The US and the sestamibi scintigraphy are the most commonly applied imaging modalities to detect an intrathyroidal parathyroid adenoma (ITPA) and a wide range of sensitivity and specificity rates has been reported in the current literature[2,3,6] mainly depending on the experience of the imaging and surgery departments. In addition, computed tomography (CT), magnetic resonance imaging (MRI), technetium-thallium scan, and selective venous blood sampling for parathormone and fine-needle aspiration biopsy have also been reported to be useful to identify an ITPA.[3,7]

Here, we aimed to investigate the clinicopathological features of PHPT patients with complete intrathyroidal or subcapsular parathyroid adenoma and the effectiveness of pre-operative localization studies in a tertiary referral center.

Methods

The data of 708 consecutive patients who underwent parathyroidectomy with the diagnosis of PHPT in General Surgery B Clinic of Izmir Kâtip Celebi University Ataturk Training and Research Hospital between January 2007 and December 2021 were investigated retrospectively. PHPT cases with complete intrathyroidal parathyroid glands in the final histopathological examination and cases with intraoperatively found subcapsular parathyroid glands were included in the study. Patients with missing file data were excluded from the study. Demographic and clinicopathological features of the patients and imaging findings were analyzed based on the hospital database and patient files.

All patients were evaluated with the pre-operative US by an experienced radiologist (N.E.) and sestamibi scintigraphy ± SPECT (sestamibi-SPECT) scan. Additional scanning studies were administered in patients with negative or discordant localization studies. Four-dimensional MRI (4D-MRI) and four-dimensional CT (4D-CT) were preferred as second-line localization methods in our center since 2009 and 2012, respectively.[8] US-guided aspiration and parathormone measurement in aspirate were used for confirmation of the parathyroid tissue when needed. Necessity or width of neck exploration and requirement of additional thyroidectomy were determined according to pre-operative localization studies. All surgical interventions were performed by an experienced endocrine surgery team. Intraoperative parathormone assays were routinely performed to confirm surgical success in all operations according to Miami criteria.[9] Intraoperative frozen section analysis of surgical specimens was done when necessary.

Ethics Committee approval was obtained from the Izmir Kâtip Celebi University Ethics Committee (Decision date: February 24, 2022, Decision no: 0054). This study was performed in accordance with the ethical standards as laid down in the 1964 Declaration of Helsinki and its later amendments or comparable ethical standards.

Statistical Analysis

SPSS version 22.0 (IBM Corp.; Armonk, NY, USA) was used for statistical analyzes. Mean±standard deviation, median, minimum value, maximum value, and frequencies were used for the variables.

Results

A total of 28 (28/708: 3.9%) patients who met the study criteria were included in the study. The complete intrathyroidal gland (Fig. 1) was observed in 8 (1.1%) patients and the subcapsular parathyroid gland was found in 20 (2.8%) patients. The mean age was calculated as 55.8±13.1 (32–78). All but one of the patients were women. Four (14.3%) patients had a previous parathyroidectomy due to PHPT. Two of the patients who underwent parathyroidectomy in our department in the past were diagnosed with persistent/recurrent PHPT (after 3 months and 5 years). The other two patients were referred to our department due to persistent PHPT after the initial operation performed in an external hospital.

The accurate localization of ITPA was detected in 25 (89.3%) patients by pre-operative US (Fig. 2) and 18 (64.3%) patients by sestamibi-SPECT (Fig. 3). A negative sestamibi-SPECT scan was seen in all three patients with the non-diagnostic US. Conventional localization studies were concordant in 18 (64.3%) patients (Table 1). Additional imaging modalities were applied for other 10 patients. The localization of the parathyroid gland was confirmed by four-dimensional MRI (4D-MRI) in three patients (Fig. 4) and four-dimensional CT (4D-CT) (Fig. 5) in two patients. In another patient (a persistent PHPT case), a choline/PET CT showed correct

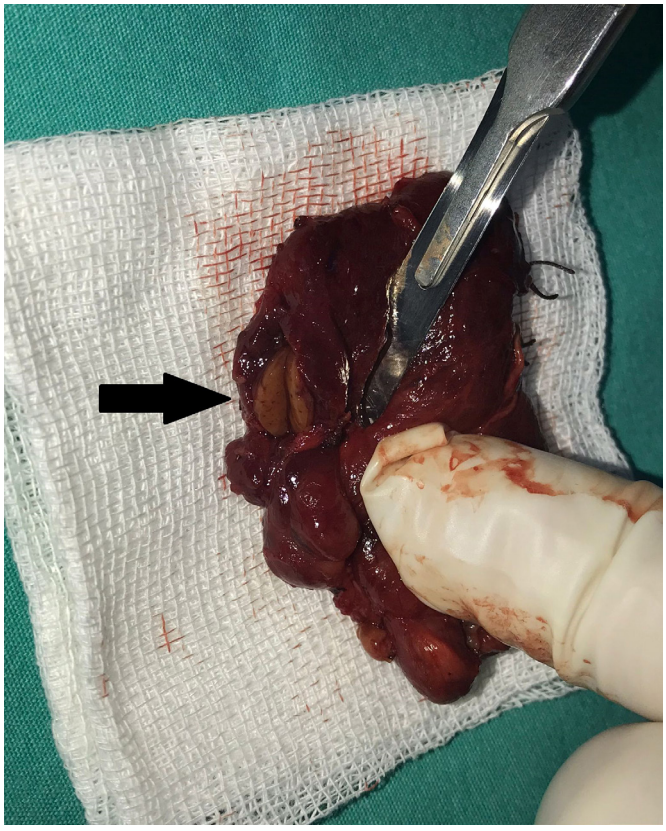

Figure 1. Macroscopic appearance of fresh surgical specimen of a 12 mm complete intrathyroidal parathyroid adenoma (arrow) in upper localization of the right thyroid lobe.

quadrant localization of parathyroid adenoma after negative 4D-CT and following negative selective venous blood sampling. When conventional imaging modalities were combined with additional imaging methods, accurate localization of the parathyroid gland was determined by at least two imaging methods in 23 (82.1%) patients.

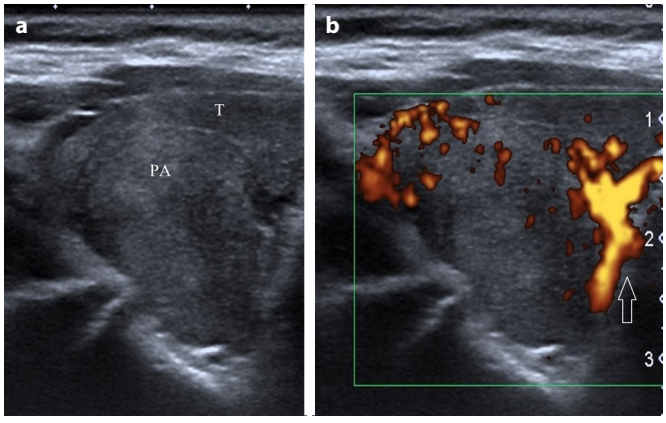

Figure 2. (a) Ultrasound image of a patient with complete intrathyroidal parathyroid adenoma (PA), surrounded with the right lobe of thyroid (T). **(b)** Color Doppler ultrasound of the same patient revealed a polar vessel (arrow) of adenoma.

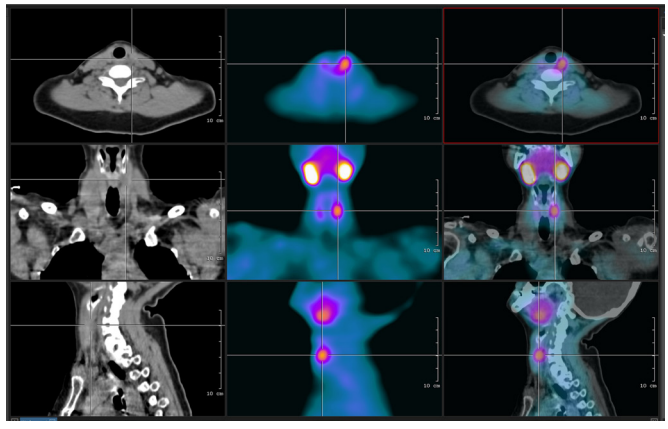

Figure 3. Sestamibi scintigraphy + single-photon emission computed tomography found the accurate localization of 15 mm diameter subcapsular adenoma on the left upper quadrant.

Other patients with discordant or suspicious imaging findings underwent unilateral or bilateral neck exploration and adenoma excision was succeeded in all. ITPAs were most commonly found in the right lower and left lower (n=10 for both) localization, and the mean adenoma diameter was calculated as 17±7.9 (7–35) mm. Histopathological examination of the parathyroid gland revealed hyperplasia in 2 (7.1%) patients, double adenoma in 1 (3.6%) patient, and a single adenoma in the other 25 (89.3%) patients. Frozen section analysis confirmed surgical success in all patients. Pre-incision and post-excision 10 min intraoperative PTH samples were collected and intraoperative PTH decreased sufficiently (between 57% and 99%) in all patients. Although, third blood samples were required during some of our parathyroidectomy procedures, we did not need it in the study group.

Table 1. Demographic and pre-operative clinical characteristics of the patients

	n (%)/mean±SD (min–max)
Localization	
Intrathyroidal	8 (28.6%)
Subcapsular	20 (71.4%)
Age	55.8±13.1 (32–78)
Gender	
Female	27 (96.4%)
Male	1 (3.6%)
Previous parathyroidectomy	
Yes	4 (14.3%)
No	24 (85.7%)
Pre-operative conventional localization studies	
Concordant	18 (64.3%)
Discordant	10 (35.7%)

Figure 4. Coronal section of the neck magnetic resonance imaging of a 9x6 mm subcapsular adenoma (arrow) showing mild diffusion restriction and located in the posterior-inferior region of the left lobe.

Thyroidectomy was performed in 50% of the study group. Hemithyroidectomy and total thyroidectomy were applied in 10 (35.7%) and 4 (14.3%) patients, respectively. Hemithyroidectomy on the side of the pathological gland was the preferred surgery for all patients with complete intrathyroidal parathyroid. In addition, contralateral hemithyroidectomy was added to the procedure in three patients due to accompanying thyroid disease in the contralateral lobe. Blind hemithyroidectomy or total thyroidectomy was not performed in any patients. In the histopathological examination of the ipsilateral thyroid lobe, incidental papillary microcarcinoma was found in 2 (14.3%) patients and benign thyroid disease was found in 12 (85.7%) patients.

Transient hypocalcemia was observed in 6 (21.4%) patients and these resolved in all patients in 3 months. Unintentional excision of the normal parathyroid gland was not performed in any of these patients. Among these six patients, four patients underwent a total thyroidectomy and one patient underwent hemithyroidectomy. Another one had a history of previous unsuccessful parathyroidectomy. The devascularization of the parathyroid glands secondary to width of dissection field may be the main reason of transient hypoparathyroidism. Patients with hemithyroidectomy did not require levothyroxine therapy. Any other complication or persistence or recurrence was not experienced in the study group (Table 2).

Figure 5. A 7 × 5 mm intrathyroidal parathyroid adenoma (arrow) located inferoposterior of the left thyroid lobe (T) with indistinguishable borders from the thyroid gland detected on computed tomography of the neck.

Table 2. Operative and histopathologic features of the patients

Parathyroid adenoma	
Right lower	10 (35.7%)
Right upper	3 (10.7%)
Left lower	10 (35.7%)
Left upper	5 (17.9%)
Diameter of parathyroid (mm)	17±7.9 (7–35)
Final parathyroid pathology	
Adenoma	25 (89.3%)
Double adenoma	1 (3.6%)
Hyperplasia	2 (7.1%)
Thyroidectomy	
No	14 (50%)
Hemithyroidectomy	10 (35.7%)
Total thyroidectomy	4 (14.3%)
Histopathology of resected ipsilateral thyroid lobe (n=14)	
Papillary microcarcinoma	2 (14.3%)
Nodular goiter	12 (85.7%)
Complication	
Transient hypocalcemia	6 (21.4%)
No	22 (78.6%)

Discussion

Intrathyroidal location is an important site for ectopic localization of parathyroid adenoma. The incidence of ITPA has been reported in a wide range between 0.5% and 22.6% in the current literature but many studies have found that true incidence is under 5%.[3] It can be completely intrathyroidal (i.e., embedded in thyroid tissue) or partial (i.e., subcapsular or partially embedded in thyroid tissue). The largest series consisting of 10,000 patients who underwent 1st time parathyroidectomy found a complete and partial ITPA prevalence of 0.7% and 1.2%, respectively.[5] However,

the incidence of ITPA in patients who underwent redo-operation due to persistence or recurrence was found up to 11%, and this is higher than that reported for patients who underwent 1st time parathyroidectomy.[4] In our series, the incidence of complete and partial ITPA was found 1.1% and 2.8%, respectively.

It is still controversial whether the superior or inferior parathyroid glands are more frequently intrathyroidal. Some authors reported that ITPA is mostly a superior parathyroid gland,[2] while others declared that inferior parathyroid glands are mainly affected[5,6] In the present study, ITPAs were mostly determined as inferior parathyroid glands.

The pre-operative precise localization of the ITPA is a pivotal role in a successful surgical outcome. Moreover, a majority of ITPAs could be diagnosed with pre-operative localization studies if performed by an experienced team. The US and the sestamibi scintigraphy are considered to be first-step imaging methods for localization in PHPT.[3] The sestamibi-SPECT is the main localization method for the diagnosis of ectopic parathyroid lesions due to high sensitivity. However, low specificity rate due to overlapping features with multinodular goiter and low contribution to sectional anatomy limits diagnostic strength.[6,10] The US has the advantages of low cost and specifying cervical anatomy very well. However, the differential diagnosis between ITPA and thyroid nodules may be a challenge, similar to that in the sestamibi-SPECT scan.[2,6] On the other hand, the accuracy of the US depends on the experience of radiologists. Bahar et al.[11] reported that US and sestamibi scan had a sensitivity of 67% and 75%, respectively. Roy et al.[12] reported that localization of ITPA was detected with a rate of 83% and 78% by US and scintigraphy, respectively. The US and sestamibi-SPECT detected ITPAs in 66.7% and 84.6% of the cases, respectively, in a recent study.[6] The combined accuracy of these two methods has been found between 81% and 92.3%, which is higher than US or scintigraphy alone.[6,12] In the present study, the diagnostic accuracy of US, sestamibi-SPECT, and combination of both was found 89.3%, 64.3%, and 89.3%, respectively. The high diagnostic success rate of the US in this study might be a result of all US scans being performed by the same radiologist who was highly experienced on neck US, especially on parathyroid imaging.

The differential diagnosis of ITPAs from thyroid nodules may be troublesome. The sonographic features of ITPAs were described by Zhao et al.[2] Most of the patients in their series had a well-defined, hypoechoic lesion on the US. In addition, they found a polar vessel of adenoma on color Doppler US in 92.3% of the patients. Our radiologist (N.E) evaluated some criteria which have been reported before[2,13,14] to make a differential diagnosis between ITPAs and thyroid nodules: (1) Absence of parathyroid tissue in anatomic localization, (2) hypervascularity and the presence of an intraglandular polar vessel, (3) more homogeneous hypoechoic pattern than the nodule, (4) absence of halo sign, and (5) well circumscribed lesion. Moreover, measurement of parathormone in fine-needle aspiration washout fluids in a few patients whose diagnosis was doubtful was done for confirmation.

Parathyroid scintigraphy alone may not determine the relation of adenoma and thyroid tissue, but a sestamibi-SPECT scan may reveal complete ITPA or subcapsular adenoma with the advantage of fusion of scintigraphy and CT. The nuclear medicine department of our hospital achieved to define complete ITPAs or subcapsular adenomas by this technic in some patients. Since the diagnosis of subcapsular parathyroid adenoma is more difficult, the accurate localization of the subcapsular parathyroid gland was confirmed by measuring parathormone in fine-needle aspiration washout fluids in some patients whose diagnosis was doubtful.

Other non-invasive diagnostic modalities, which are administered in the presence of negative or discordant first-step imaging, are CT and MRI; however, their diagnostic value for the determination of ITPA is not clear in the literature. Their diagnostic accuracy rates were reported as 0% and 25%, respectively.[7] Although invasive methods such as selective venous blood sampling and fine-needle aspiration biopsy have high sensitivity for ITPAs, they may cause adverse outcomes related to the intervention.[4,7,15] We found that 4D-CT and MRI had a sensitivity rate of 40% and 60%, respectively, in experienced hands. Their combination with conventional imaging methods provided more accurate information for adenoma localization.

In the past, hemi/total thyroidectomy was considered to be an appropriate surgical approach in the presence of a missing gland because if adenoma cannot be found during surgical exploration, adenoma was thought to be located in the thyroid gland.[2,7,11,16] On the contrary, blind thyroid lobectomy was reported to be rarely successful in the largest study in the prior literature: Goodman et al.[5] found that 77% of patients who underwent redo-operation for persistent PHPT had a history of lobectomy of which the majority were on the same side with parathyroid adenoma. They concluded that careful dissection of the tissue surrounding the thyroid, thyroidotomy, or meticulous dissection of the inferolateral side will help to find missing adenoma. We did not perform blind thyroidectomy in the study group (i.e., in the absence of any pre-operative suspicious imaging).

Intraoperative gamma probe and the US have high accuracy rates to identify ITPAs. The intraoperative US also con-

tributes to confirmation of complete resection of ITPA and prevents resection of the normal thyroid gland.[2,3] We performed ipsilateral hemithyroidectomy for all patients with complete intrathyroidal adenoma.

This study has some limitations including being conducted in a single surgery clinic, retrospective design, and small sample size.

Conclusion

The intrathyroidal and subcapsular regions are rare ectopic localizations of the parathyroid adenoma in PHPT. The US, one of the conventional localization studies, has a high diagnostic accuracy rate when performed by an experienced radiologist. The second-line imaging methods may contribute to the detection of accurate localization of ITPAs in the presence of negative or discordant scans. Since the pre-operative localization studies can reveal the ITPAs in the majority of patients in experienced centers, surgical success is high and blind thyroidectomy should be avoided.

Disclosures

Ethics Committee Approval: Ethics Committee approval was obtained from the Izmir Kâtip Celebi University Ethics Committee (Decision date: February 24, 2022, Decision no: 0054).

Peer-review: Externally peer-reviewed.

Conflict of Interest: None declared.

Authorship Contributions: Concept – S.G.H., S.K., M.H.; Design – S.K., N.E., M.H.; Supervision – S.G.H., N.E., B.T., E.O.G.; Materials – S.K., E.O.G., B.T.; Data collection &/or processing – S.G.H., N.E., M.H.; Analysis and/or interpretation – B.T., E.O.G., M.H.; Literature search – S.G.H., S.K., M.H.; Writing – S.K., E.O.G., M.H.; Critical review – S.G.H., N.E., M.H.

References

1. Nieciecki M, Cacko M, Królicki L. The role of ultrasound and nuclear medicine methods in the preoperative diagnostics of primary hyperparathyroidism. J Ultrason 2015;15:398–409.
2. Zhao W, Lu R, Yin L, Wei B, Jin M, Zhang C, et al. The value of preoperative and intraoperative ultrasound in the localization of ıntrathyroidal parathyroid adenomas. J Invest Surg 2022;35:752–7.
3. Ntelis S, Linos D. Prevalence, diagnostic imaging and treatment strategies of intrathyroid parathyroid adenomas in patients surgically treated for hyperparathyroidism: a review of the literature. Hellenic J Surg 2020;92:115–9.
4. Shen W, Düren M, Morita E, Higgins C, Duh QY, Siperstein AE, et al. Reoperation for persistent or recurrent primary hyperparathyroidism. Arch Surg 1996;131:861–7.
5. Goodman A, Politz D, Lopez J, Norman J. Intrathyroid parathyroid adenoma: incidence and location--the case against thyroid lobectomy. Otolaryngol Head Neck Surg 2011;144:867–71.
6. Ye T, Huang X, Xia Y, Ma L, Wang L, Lai X, et al. Usefulness of preoperative ultrasonographic localization for diagnosis of a rare disease: Intrathyroid parathyroid lesions. Medicine (Baltimore) 2018;97:e10999.
7. Mazeh H, Kouniavsky G, Schneider DF, Makris KI, Sippel RS, Dackiw AP, et al. Intrathyroidal parathyroid glands: small, but mighty (a Napoleon phenomenon). Surgery 2012;152:1193–200.
8. Gücek Haciyanli S, Acar N, Balli Ö, Erdoğan N, Haciyanli M. Selective venous sampling in primary hyperparathyroidism: Is it worth doing? Turk J Med Sci 2021 Oct 24 [Epub ahead of print], doi: 10.3906/sag-2108-151.
9. Irvin GL 3rd, Solorzano CC, Carneiro DM. Quick intraoperative parathyroid hormone assay: surgical adjunct to allow limited parathyroidectomy, improve success rate, and predict outcome. World J Surg 2004;28:1287–92.
10. Tublin ME, Pryma DA, Yim JH, Ogilvie JB, Mountz JM, Bencherif B, et al. Localization of parathyroid adenomas by sonography and technetium tc 99m sestamibi single-photon emission computed tomography before minimally invasive parathyroidectomy: are both studies really needed? J Ultrasound Med 2009;28:183–90.
11. Bahar G, Feinmesser R, Joshua BZ, Shpitzer T, Morgenstein S, Popovtzer A, et al. Hyperfunctioning intrathyroid parathyroid gland: a potential cause of failure in parathyroidectomy. Surgery 2006;139:821–6.
12. Roy M, Mazeh H, Chen H, Sippel RS. Incidence and localization of ectopic parathyroid adenomas in previously unexplored patients. World J Surg 2013;37:102–6.
13. Heller MT, Yip L, Tublin ME. Sonography of intrathyroid parathyroid adenomas: are there distinctive features that allow for preoperative identification? Eur J Radiol 2013;82:e22–7.
14. Abboud B, Sleilaty G, Rabaa L, Daher R, Abou Zeid H, Jabbour H, et al. Ultrasonography: highly accuracy technique for preoperative localization of parathyroid adenoma. Laryngoscope 2008;118:1574–8.
15. Norman J, Politz D, Browarsky I. Diagnostic aspiration of parathyroid adenomas causes severe fibrosis complicating surgery and final histologic diagnosis. Thyroid 2007;17:1251–5.
16. Herden U, Seiler CA, Candinas D, Schmid SW. Intrathyroid adenomas in primary hyperparathyroidism: are they frequent enough to guide surgical strategy? Surg Innov 2011;18:373–8.