Case Report/Olgu Sunumu

Spor Hekimliği Dergisi, 55(3):246-250;2020
Turkish Journal of Sports Medicine
DOI: 10.5152/tjsm.2020.184

Chronic Medial Collateral Ligament Sprain and Medial Collateral Ligament Bursitis of the Knee in a Female Soccer Player: A Case Report

Kadın Futbolcuda Dizin Kronik İç Yan Bağ Yaralanması ve İç Yan Bağ Bursiti: Olgu Sunumu

Ömer Serkan Kara, Gürhan Dönmez, Feza Korkusuz

Hacettepe University Medical Faculty, Department of Sports Medicine, Ankara, Turkey

ABSTRACT

Medial collateral ligament (MCL) injury is diagnosed with clinical history and physical examination. Chronic valgus instability develops more likely after severe (grade III) MCL injuries, but may also develop after repetitive low-grade injuries. Soccer players have a susceptibility to chronic symptoms in minor injuries due to repetitive kicking with the inside of the foot and lateral movements. MCL bursitis is a rare entity but should be considered in the differential diagnosis of medial knee pain. It can be diagnosed with findings of tenderness over the MCL at the joint line, without a history of mechanical symptoms.

An 18 years-old female soccer player presented with medial knee pain. She described a valgus strain injury on the right knee that occurred the day before. Physical examination showed tenderness along the MCL course. Valgus stress test was quite painful and there was (1+) valgus laxity. There wasn't any previous severe knee trauma. The patient diagnosed with acute MCL sprain. PRICE protocol and NSAID were started. Over the course of treatment, the patient's symptoms improved faster than expected. Reevaluation of the patient suggested that the patient's valgus laxity wasn't due to the acute trauma but chronic microtraumas. She returned to the sport at day 10.

In this case report, an elusive case of posttraumatic MCL bursitis in an 18-years-old female soccer player with valgus laxity due to chronic MCL sprain is described. It should be kept in mind that chronic MCL injury may cause increased laxity in soccer players. In the case of acute valgus injury, presence of laxity may be a confusing factor in physical examination.

Keywords: Medial collateral ligament bursitis, knee valgus injury, chronic medial collateral ligament sprain, soccer injury

ÖZ

İç yan bağ (İYB) yaralanmalarında tanı klinik öykü ve fizik muayene ile konur. Kronik valgus instabilitesi şiddetli İYB yaralanmalarından (3.derece) sonra ortaya çıkabileceği gibi tekrarlayan düşük dereceli yaralanmalar ile de gelişebilir. Futbolcularda tekrarlayan ayak içi şutlar ve yana hareketler ile kronik semptomlara yol açan düşük dereceli yaralanmalar görülebilir. İYB bursiti nadir görülen bir hastalıktır, ancak iç diz ağrısının ayırıcı tanısında düşünülmelidir. Mekanik semptomlar olmaksızın İYB üzerinde eklem çizgisi hizasında hassasiyet olması İYB bursitinin varlığını düşündürür. 18 yaşında bir kadın futbolcu iç diz ağrısı ile kliniğimize başvurdu. Önceki gün sağ dizi valgusa zorlanmıştı. Fizik muayenesinde İYB seyri boyunca hassasiyet saptandı. Valgus stres testi oldukça ağrılıydı ve valgus laksitesi (1+) vardı. Daha önce geçirilmiş ciddi diz yaralanma öyküsü yoktu. Hastaya akut İYB zedelenmesi tanısı kondu. "PRICE" protokolü ve NSAİİ başlandı. Tedavi sırasında semptomları beklenenden daha

Ö. S. Kara
0000-0003-4916-5212

G. Dönmez
0000-0001-6379-669X

F. Korkusuz
0000-0001-9486-3541

Geliş Tarihi/Date Received:
27.09.2019
Kabul Tarihi/Date Accepted:
02.01.2020
Yayın Tarihi/Published Online:
07.05.2020

Yazışma Adresi / Corresponding Author:
Ömer Serkan Kara
Hacettepe Üniversitesi, Tıp Fakültesi Spor Hekimliği Bölümü, Ankara, Turkey

E-mail:
omerserkankara@gmail.com

*©**2020** Türkiye Spor Hekimleri Derneği. Tüm hakları saklıdır.*

hızlı düzelen hasta yeniden değerlendirildi. Hastanın laksitesinin akut travma nedeniyle değil kronik tekrarlayan mikro travmalar nedeniyle olduğu anlaşıldı. Hasta 10 günde spora geri döndü. Kronik İYB zedelenmesi nedeniyle valgus laksitesi olan 18 yaşındaki kadın futbolcuda, travma sonrası İYB bursiti gelişmiştir. Kronik İYB hasarının futbolcularda artmış laksiteye neden olabileceğini akılda tutulmalıdır. Akut valgus hasarı durumunda, laksite varlığı fizik muayenede kafa karıştırıcı bir faktör olabilir.

Anahtar sözcükler: Medial kollateral bağ bursiti, diz valgus zorlanması, kronik medial kollateral bağ yaralanması, futbol yaralanması

Available at: http://journalofsportsmedicine.org and http://dx.doi.org/10.5152/tjsm.2020.184

Cite this article as: Kara OS, Donmez G, Korkusuz F. Chronic medial collateral ligament sprain and medial collateral ligament bursitis of knee in a female soccer player: A case report. *Turk J Sports Med*. 2020;55(3):246-50.

INTRODUCTION

The medial collateral ligament (MCL) is the most frequently injured ligament in the knee (1). MCL injury usually occurs due to an acute trauma that imposes valgus stress on the knee and (2) is one of the most common injuries in elite soccer (3). In a clinical setting, MCL bursitis, MCL sprain and meniscus tear may be difficult to differentiate (4). However, correct diagnosis is important to estimate the time to return to the previous level of activity and determine the subsequent rehabilitation protocol of the athlete. In this case, MCL bursitis is discussed as a problem in the differential diagnosis of acute MCL sprain in the setting of chronic MCL sprain. We point out the fact that MCL bursitis may occasionally be misdiagnosed as MCL sprain.

To the best of our knowledge, this is the first time in literature in which an elusive case of posttraumatic MCL bursitis in an 18-years-old female soccer player with valgus laxity due to chronic MCL sprain is described. Initially, the patient's history, symptoms and physical examination led us to diagnose with acute grade 2 MCL sprain and we started conservative treatment, accordingly. During the treatment, it came up that she had MCL bursitis superposed to chronic atraumatic MCL sprain due to repetitive forceful valgus stress. This case is worth sharing with our colleagues since valgus trauma to the knee is common in sports medicine practice. While making a differential diagnosis, team physicians should be aware of this confusing condition which we present in this case report.

CASE PRESENTATION

An 18 years-old female soccer player presented with medial knee pain and limping because of pain. Pain was increasing with movement. She described valgus strain injury to her right knee the day before. Trauma occurred when an opponent made a sliding tackle to the ball when she attempted to shoot the ball with the inside of the foot. The ball was stuck between the two players' feet. Her knee was placed at a 30-degree flexion when her kick was blocked; thus, it caused a valgus stress on the right knee.

The patient reported that the injured (right) side was her kicking leg, which was considered as the dominant leg. Physical examination revealed tenderness along the MCL course, most prominent at the level of the joint line, and mild tenderness at anterolateral portion of the tibial plateau and pes anserinus region. Ligamentous testing at 0° and 30° with valgus stress were quite painful and there was (1+) valgus laxity at the injured knee. There was moderate swelling and warm to the touch at the medial side of the knee, but no effusion or symptoms like locking, catching or giving way. Active knee motion was painfree up to 120^0 of flexion. Although her passive range of motion was full, it was painful after 120^0 of flexion. The adductor strength test revealed pain on the injured knee. She did not have ligamentous laxity and her Beighton score was zero. The remainder of the physical examination depicted nothing significant.

Standard weight-bearing anteroposterior (AP) view and 30° of flexion lateral view radiographs were obtained with no remarkable findings. An

MRI scan was performed 3 days after the trauma. MCL had a wavy appearance in addition to periligamentous and subcutaneous edema and distended fluid in MCL bursa (Fig. 1). X-rays of both knees were obtained while applying valgus stress test. The distance between medial femoral condyle and tibia was 0,97 cm at the injured side while it was 0,64 cm on the uninjured knee (Fig. 2).

Figure 1. PD-weighted coronal plane MR image of MCL bursitis (arrow). Wavy appearance of medial collateral ligament (arrowheads) suggests chronic MCL sprain. It is likely to be due to repetitive microtraumas.

NSAID was prescribed and PRICE protocol was applied for 10 days with the diagnosis of grade 2 MCL sprain. Hinged brace was applied to limit the mediolateral motion. Home exercise program was given twice Daily includind range-of-motion and isometric exercises. After achieving full pain-free ROM, she is referred to the physical therapy unit of our hospital for further rehabilitation.

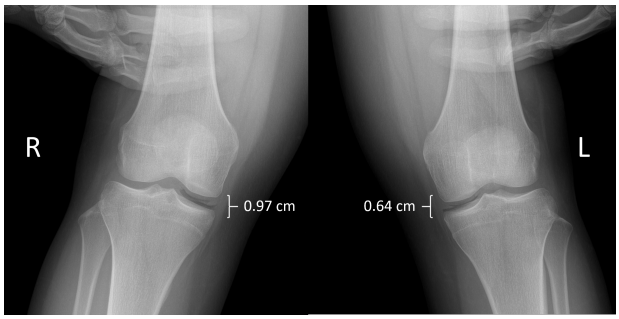

Figure 2. Valgus stress radiograph of the patient's injured knee (R) revealed 0,97 cm of distance between medial femoral condyle and tibia. The distance at the uninjured side (L) was 0,64 cm.

Medial knee pain and limping ceased on day 4. The assessment on this day revealed laxity (++) at full knee extension and $30^0$of knee flexion with mild pain on the affected leg. At this stage, we reviewed our diagnosis of 2nd grade of MCL sprain, as progression was far better than expected. Valgus test yielded mild pain but prominent laxity. MCL had a wavy appearance on MRI scan. These findings were remarkable signs of chronic MCL sprain. At the follow-up visit on day 7, it was observed that the swelling and tenderness were resolved and the patient was asymptomatic except for mild pain, with distinct laxity with the valgus stress test. Two days after, the valgus stress test still revealed (++) laxity with no pain.

The patient had been playing soccer for 8 years and had no history of serious knee trauma or treatment. The wavy appearance of the MCL in MRI scan and (++) laxity of the knee probably resulted from chronic MCL sprain due to repetitive microtrauma. The resolution of symptoms and returning to sport earlier than expected were supporting facts of the diagnosis.

DISCUSSION

Initially, our diagnosis was grade 2 MCL sprain, since she had laxity and pain on valgus stress test, tenderness over palpation, distended fluid in MCL bursa, periligamentous edema and wavy appearance of MCL fibers on MRI scan. Considering the knee laxity, the treatment was

planned according to grade 2 MCL sprain. The patient had a more pronounced laxity (++) in the follow-up examinations compared to the baseline evaluation (+). We attributed this to the suboptimal valgus stress test due to severe pain at the initial examination. Chronic MCL sprain may explain our patient's unilateral laxity at the dominant leg. It is possible that laxity may make MCL bursa predisposed to inflammation with acute valgus strain. In such cases, it is difficult to determine whether the laxity is caused by repetitive microtrauma or acute MCL sprain. Screening of MCL laxity by a team physician is thought to be helpful to determine the overuse injury of this ligament. By presenting this case, we aim to raise awareness of these kind of injuries, particularly in soccer players. The current literature on MCL bursitis consists of MRI studies of the general population and anatomic studies of several cadaveric specimens (4-7). Since there are only a few case reports regarding the athletes (8-10), this case may also be instructive for sports medicine practitioners.

MCL is the most commonly injured knee ligament in professional soccer with a rate of approximately 0.33 injuries per 1000 training hours (11, 12). An average lay-off from professional soccer is usually more than 3 weeks (12). MCL injuries are frequently related with contact traumas rather than non-contact ones. Most injuries are the result of a collision or a tackle with physical impact on the outside of the lower part of the thigh or the upper part of the lower leg (12). MCL injury can be reliably diagnosed by clinical history and physical examination. Patients usually describe a recent trauma on the lateral knee or a non-contact sensation of the knee "giving away" and "popping" while attempting to change direction rapidly. Physical examination may reveal a medial laxity to valgus stress and tenderness to palpation over the medial aspect of the knee (2). In our case, there was a history of trauma with valgus stress and physical examination was consistent with MCL sprain as cited. Besides acute sprains, MCL injuries may be subacute or chronic, as well (13). In the case of acute MCL sprain, the ligament often heals with non-operative management; however, up to 20% of the patients may have persistent symptoms (9, 14). Chronic valgus instability develops more likely after severe (grade 3) MCL injuries, but may also develop in repetitive low-grade injuries. Our patient did not have a history of acute trauma in the knee, which supports the diagnosis of chronic MCL sprain. Soccer players have greater susceptibility to chronic symptoms in lower grade injuries due to repetitive kicking with the inside of the foot and lateral movements (15). Furthermore, many low-grade MCL injuries likely go unreported (2). MRI findings of chronic injury to the MCL include thickening of the ligament, waviness of its fibers, or total discontinuity (13).

MCL bursitis was first described by Voshell et al. in 1943. The diagnosis was based on the findings of tenderness over the tibial collateral ligament at the joint line, without a history of mechanical symptoms (16). In MRI, MCL bursa is usually not seen in normal knees but becomes visible when fluid distends it, which confirms the diagnosis in the absence of laxity (6). On the other hand, fluid may be seen at MCL bursa in case of MCL tears, as well (17). In our case, the valgus stress test was positive and there was a wavy appearance at MCL in addition to periligamentous edema and fluid in MCL bursa in MRI, all of which led us to misdiagnose as acute MCL sprain.

In the literature, it is stated that MCL bursitis is misdiagnosed as a meniscus tear that may cause patients to undergo unnecessary arthroscopic examination (18). There are also studies about treatment with corticosteroid injections of chronic MCL bursitis in patients with osteoarthritis (5, 6, 11). Nevertheless, there are just a few case reports of young athletes (8-10). It is well known that bone spurs due to osteoarthritis of the medial compartment may predispose the inflammation of MCL bursa by causing friction (5). However, in young athletes, it is associated with an athletic activity such as tennis, running, cycling, swimming and horse riding (4). We additionally hypothesized that MCL laxity may be a predisposing factor for MCL bursitis, which is, to the best of our knowledge, a

first in the literature. Traditionally, the treatment of bursitis consists of training guidance, anti-inflammatory medication, intrabursal corticosteroid injections in resistant cases and occasionally, surgical removal of the inflamed bursa (19). However, our case was an acute traumatic MCL bursitis and this bursal inflammation was simply treated with topical NSAIDs.

CONCLUSION

Chronic MCL injury may cause increased valgus laxity in soccer players and may be asymptomatic in terms of pain. This laxity may be a consequence of chronic valgus load on the knee due to kicking actions, especially in soccer players. In case of acute valgus injury, this laxity may be a confusing factor, because as it can lead a misdiagnosis of grade 2-3 MCL sprain, which usually neccessitates a longer recovery time than MCL bursitis. This may result in unnecessary time-loss for a player. Therefore, regular screening of MCL laxities of the players by the team physicians can help to eliminate possible misdiagnoses which may lead to planning of inappropriate treatment protocols.

Acknowledgements

The authors have no conflicts of interest to declare.

Informed Consent

Informed consent was obtained and the rights of the patient was protected.

Conflict of Interest

The authors declared no conflicts of interest with respect to the authorship and/or publication of this article.

REFERENCES

1. Duffy PS, Miyamoto RG. Management of medial collateral ligament injuries in the knee: an update and review. *Phys Sportsmed.* 2010;38(2):48-54.
2. Andrews K, Lu A, McKean L, Ebraheim N. Review: Medial collateral ligament injuries. *J Orthop*. 2017;14(4):550-4.
3. Ekstrand J, Hagglund M, Walden M. Injury incidence and injury patterns in professional soccer: the UEFA injury study. *Br J Sports Med*. 2011;45(7):553-8.
4. Kerlan RK, Glousman RE. Tibial collateral ligament bursitis. *Am J Sports Med.* 1988;16(4):344-6.
5. Lee JK, Yao L. Tibial collateral ligament bursa: MR imaging. *Radiology.* 1991;178(3):855-7.
6. De Maeseneer M, Shahabpour M, Van Roy F, et al. MR Imaging of the Medial Collateral Ligament Bursa. *AJR Am J Roentgenol.* 2001;177(4):911-7.
7. Liu F, Yue B, Gadikota HR, et al. Morphology of the medial collateral ligament of the knee. *J Orthop Surg Res.* 2010;5:69
8. Barclay C, Springgay G, van Beek EJ, et al. Medial collateral ligament bursitis in a 12-year-old girl. *Arthroscopy.* 2005;21(6):759.
9. Corten K, Vandenneucker H, Van Lauwe J, et al. Chronic Posttraumatic Bursitis of the Medial Collateral Ligament: Surgical Treatment in 2 High-Level Professional Athletes. *Am J Sports Med.* 2009;37(3):610-3.
10. Johar SK. Medial Knee Pain in a Runner: A Case Report. *Sports Health*. 2010;2(4):318-20.
11. Bollen S. Epidemiology of knee injuries: diagnosis and triage. *Br J Sports Med.* 2000;34(3):227-8
12. Lundblad M, Walden M, Magnusson H, et al. The UEFA injury study: 11-year data concerning 346 MCL injuries and time to return to play. *Br J Sports Med.* 2013;47(12):759-62.
13. Schein A, Matcuk G, Patel D, et al. Structure and function, injury, pathology, and treatment of the medial collateral ligament of the knee. *Emerg Radiol.* 2012;19(6):489-98.
14. Holden DL, Eggert AW, Butler JE. The nonoperative treatment of grade I and II medial collateral ligament injuries to the knee. *Am J Sports Med.* 1983;11(5):340-4.
15. Gifford PB, Haddad FS. Managing Chronic Medial Collateral Injuries. In: Musahl V, Karlsson J, Krutsch W, Mandelbaum BR, Espregueira-Mendes J, d'Hooghe P, editors. Return to Play in Soccer: An Evidence-based Approach. Berlin, Heidelberg: Springer Berlin Heidelberg; 2018. p. 525-33.
16. Brantigan OC, Voshell AF. The tibial collateral ligament: its function, its bursae, and its relation to the medial meniscus. *JBJS.* 1943;25(1):121-31.
17. Schweitzer ME, Tran D, Deely DM, et al. Medial collateral ligament injuries: evaluation of multiple signs, prevalence and location of associated bone bruises, and assessment with MR imaging *Radiology.* 1995;194(3):825-9.
18. Nur H, Aytekin A, Gilgil E. Medial collateral ligament bursitis in a patient with knee osteoarthritis. *J Back Musculoskelet Rehabil.* 2018;31(4):589-91.
19. Engebretsen L, Muellner T, Laprade R, et al. Knee In: Kjaer M, Krogsgaard, Magnusson P, Engebretsen L, Roos H, Takala T and Woo SLY, editors. *Textbook of Sports Medicine Basic science and clinical aspects of sports injury and physical activity.* 1st Ed. Wiley-Blackwell 2003. p. 561-615.