Available online at www.medicinescience.org

ORIGINAL ARTICLE

Medicine Science International Medical Journal

Medicine Science 2021;10(4):1097-102

Evaluation of cerebral microbleeds in patients using rivaroxaban for cardioembolism prophylaxis in non-valvular atrial fibrillation

Sukru Sahin[1], Ali Haydar Baykan[1], Ali Zeynel Abidin Tak[2]

[1]Adiyaman Education and Training Hospital, Department of Radiology, Adiyaman, Turkey
[2]Adiyaman Education and Training Hospital, Department of Neurology, Adiyaman, Turkey

Received 18 February 2021; Accepted 09 May 2021
Available online 15.08.2021 with doi: 10.5455/medscience.2021.02.052

Copyright@Author(s) - Available online at www.medicinescience.org
Content of this journal is licensed under a Creative Commons Attribution-NonCommercial 4.0 International License.

Abstract

Cerebral microbleeds (CMBs) are associated with an increased risk of ischemic and particularly hemorrhagic stroke and are considered a marker of cerebrovascular disease in cranial magnetic resonance imaging (MRI). Rivaroxaban is a new-generation oral anticoagulant and a direct inhibitor of Factor Xa. In this study, we aimed to evaluate the frequency of CMBs in patients using rivaroxaban to prevent cardiac embolism in non-valvular atrial fibrillation. Seventy-four patients using rivaroxaban and 64 controls were included in the study. The group using rivaroxaban had been using medication for at least 6 months. Susceptibility Weighted Angiography (SWAN) sequence was taken from all participants in a 1.5 Tesla MR device to detect CMBs. In the rivaroxaban group, the frequency of CMBs was significantly higher than the control group (p= 0.028), and it increased with the increasing duration of rivaroxaban use (p=0.005). Also, in the rivaroxaban group, there was the frequency of CMBs in specific areas such as the frontal lobe, basal ganglia, and thalamus compared with the control group participants. Since it is known that presence of CMBs increase the risk of stroke, we conclude that caution should be taken in patients who are on rivaroxaban for prophylaxis of cardiac thromboembolism. However, we also believe that this finding needs to be confirmed in studies including larger patient series.

Keywords: Cerebral microbleeds, magnetic resonance imaging, atrial fibrillation, rivaroxaban, stroke

Introduction

Cerebral microbleeds (CMBs) detected in cranial magnetic resonance imaging (MRI) studies are due to the accumulation of hemosiderin formed as the breakdown product of the blood which leaked from small vessels . The CMBs were first described in the 1990s with the development of the gradient echo (GRE) T2 sequence in MRI technology. Typically, they appear as small, round, hypointense, black lesions of less than 5-10 mm in diameter in basal ganglia or cortico-subcortical regions. The prevalence of CMBs increases with age, and they can be detected in approximately 5-15% of the healthy adult population [1, 2]. It is known that CMBs increase the risk of initial and recurrent strokes, particularly those that are hemorrhagic [1]. As per previously published reports, approximately one-third of ischemic strokes and 50-80% of hemorrhagic strokes are associated with CMBs.

***Corresponding Author:** Sukru Sahin, Adiyaman Education and Training Hospital, Department of Radiology, Adiyaman, Turkey
E-mail: sukrumirza@gmail.com

The GRE sequence is an MRI method for detecting intracranial paramagnetic blood breakdown products. In this method, bleeding sites are identified as lesions showing significant signal loss due to the magnetic susceptibility effect. On the other hand, susceptibility-weighted angiography (SWAN) is a new technique; it is a high-resolution 3D multi-echo gradient echo sequence [3]. This method is more sensitive than GRE in the detection of CMBs [4].

Atrial fibrillation (AF) is a common type of arrhythmia known to significantly increase the risk of cardiogenic cerebral embolism [5]. There are two types of atrial fibrillation based on etiology: valvular AF and non-valvular AF (NVAF). The former type includes mitral stenosis and prosthetic mitral valves, while the latter type includes hyperthyroidism and hypertension [6].

While vitamin K antagonists are frequently used in patients with valvular AF, new-generation oral anticoagulants (i.e., non-vitamin K antagonist oral anticoagulants) are often prescribed in patients with NVAF. It is known that valvular AF is associated with a 17-fold, and NVAF is associated with a 5-fold increased risk of ischemic stroke. Previous studies showed that the incidence of CMBs is significantly higher in patients with AF than those

without AF, and the presence of CMBs is associated with an increased risk of stroke and subsequent mortality in the former patient group [2]. A meta-analysis showed that patients with CMB who undergo thrombolysis due to acute ischemic stroke had a higher risk of symptomatic intracranial bleeding [7]. Detection of CMBs cannot be considered as a contraindication for thrombolytic treatment based on these data; however, further research should be done on this topic.

Rivaroxaban is a specially developed oral anticoagulant with a rapid onset of action [8]. It is a direct inhibitor of Factor Xa and it does not require routine international normalized ratio (INR) monitoring. In patients with AF, rivaroxaban is not inferior to warfarin in preventing stroke or systemic embolism [9]. In this case-control study, we aimed to evaluate CMBs' frequency in patients with NVAF who are using rivaroxaban for the prevention of cardiogenic embolism.

Materials and Methods

This study compared the patients with NVAF who were on rivaroxaban for prophylaxis and a control group of healthy individuals in terms of CMBs detected cranial MRI. Patients diagnosed with NVAF and prescribed rivaroxaban by the cardiology clinic of Adıyaman Education and Research Hospital between October 2017 and April 2019 were included in this study. These study group patients underwent SWAN for the detection of potential CMBs. On the other hand, healthy adults referred to our hospital's neuroradiology department for undergoing cranial MRI for check-up purposes within the study period constituted the control group. Since SWAN protocol is routinely added to the cranial MRI scans in our center, all control group participants also underwent SWAN. The demographic characteristics (age, gender) of all patients and controls were analyzed. Patients with amyloid angiopathy, multiple sclerosis, Parkinson's disease, uncontrolled hypertension, diabetes mellitus, ischemic or hemorrhagic stroke, transient ischemic attack, Alzheimer's disease, history of brain surgery, and malignancies were omitted (Figure 1). Patients with MRI findings such as developmental venous anomalies and dural calcifications were not excluded; however, these benign conditions were not evaluated within this study. All MRI scans were reviewed by two radiologists, both with more than ten years experience in neuroradiology. Ethics approval was obtained from Adıyaman University Non-Interventional Clinical Research Ethics Board with the number of 2017/6-11.

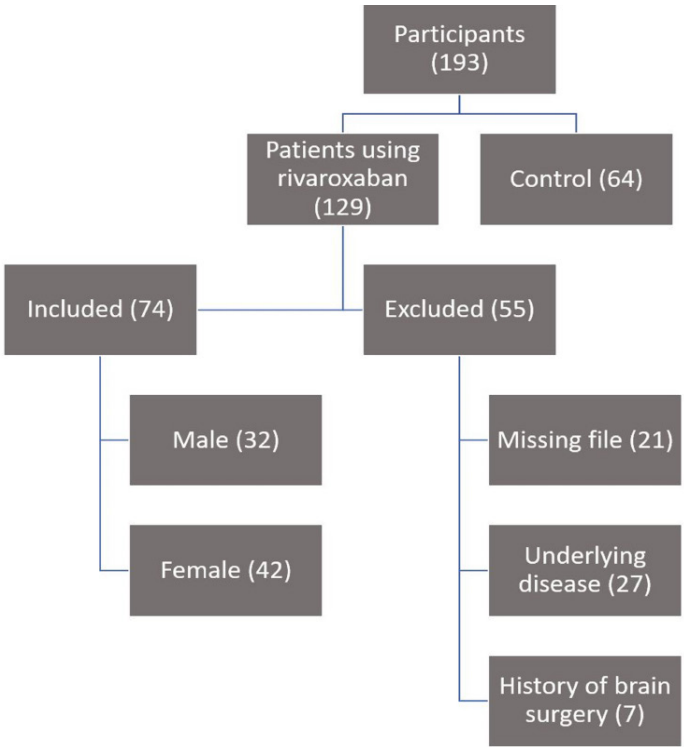

Figure 1. The flowchart of the study

MRI protocol

All MRI procedures were performed using a 1.5T system (Signa Explorer; GE Healthcare) with a head coil. The radiological images were evaluated on a dedicated workstation (AW Volume Share) by obtaining 3D axial images (TR, minimum; TE, 50 ms; FOV, 240x90 mm; thickness, 2.6 mm; GAP, 0 mm; slice, 50; flip angle, 25; matrix, 448x384 mm). Round areas within the brain parenchyma, showing a signal loss of less than 10 mm, were interpreted as CMBs. The CMBs and calcifications appear as hypointense lesions in axial SWAN images. Lesions with hyperintense halos in coronal reformatted images were accepted as CMBs. Patients in the study group were classified as per absence, presence, and number of CMBs: Absent, single (1), mild (2-4), moderate (5-7), and severe (8 or more).

We also classified the CMBs according to the depth of their foci: The CMBs within the cerebral cortex were categorized as

"cortical", those located deeper than 1 cm from the cortex as "deep white matter" and those between these two regions as "subcortical" (Figure 2). We also classified CMBs based on their anatomical localization as frontal, parietal, temporal, occipital lobe CMBs, cerebellar CMBs, and CMBs located at the thalamus and basal ganglia.

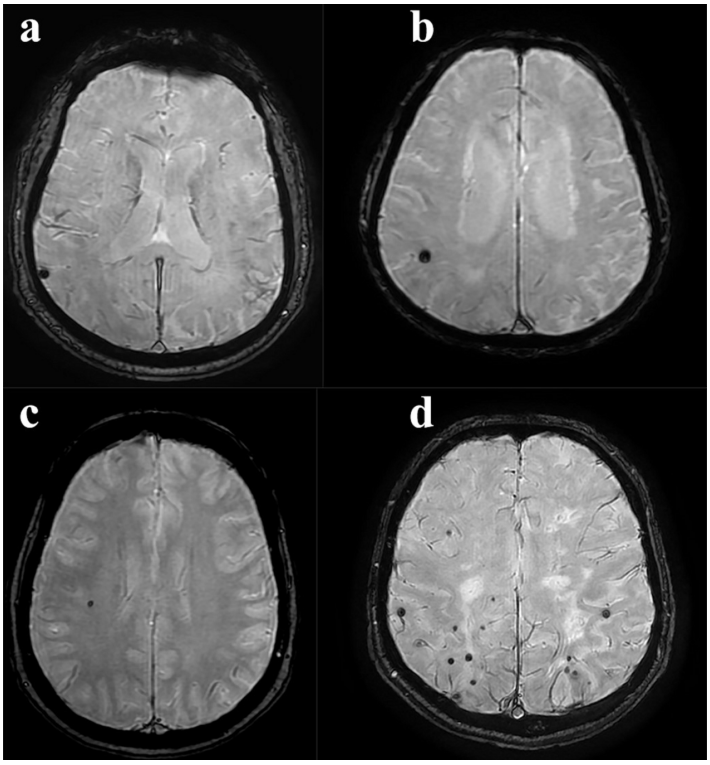

Figure 2. In SWAN (Susceptibility Weighted Angiography); cortical (a), subcortical (b), deep white matter (c) localized microhemorrhages are observed as round signal loss areas. Cerebral microbleeds in four different cases. Also note the large number of dispersed CMB foci (d)

Statistical method

Statistical analysis was performed using SPSS program version 17.0. The suitability of the variables for normal distribution was examined by histogram graphs and the Kolmogorov-Smirnov test. Means, standard deviations, and median values were used in descriptive analyses. A Chi-square test was used for comparison of the categorical variables. The Mann-Whitney U test was employed to evaluate non-normally distributed (non-parametric) variables between the groups. The agreement between the two raters was examined using Cohen's kappa coefficient. In cases where the p-value was less than 0.05, the results were considered statistically significant.

Results

In total, 138 individuals participated in this study. Seventy-four patients using rivaroxaban constituted the study (i.e., rivaroxaban) group, while 64 healthy controls participated in the control group. Two groups were similar in terms of demographic data (Table 1). The mean age of the participants was 62.41±13.40 years. In the rivaroxaban group, the mean age was 60.99±13.59 years, and there were 32 (43.24%) males and 42 (56.76%) females. The mean age of the control group patients was 64.05±13.10 years. This group consisted of 29 (45.31%) males and 35 (54.69%) females. While there were 22 (29.7%) patients with CMB in the study group, there were 9 (14.1%) cases with CMB in the control group (p=0.028). The mean duration of rivaroxaban use was 17.46±13.56 months. In the rivaroxaban group, the frequency of CMBs was significantly higher than the control group (p= 0.028), and it increased with the increasing duration of rivaroxaban use (p=0.005) (Tables 2 and 3). Minimum and maximum sizes of CMBs were 1 and 7 mm, respectively.

Table 1. Information on the patients' age, duration of rivaroxaban use, and size of CMBs

	Mean	Standard deviation	Median
Age (years)	62.41	±13.40	64.00
Duration of rivaroxaban use (months)	17.46	±13.56	14.50
Minimum size (mm)	1.86	±.67	1.60
Maximum size (mm)	3.47	±1.57	3.00

Table 2. Relationship between rivaroxaban use and CMBs incidence

CMBs	Rivaroxaban	Control	P
Present (N) (%)	22 (29.7)	9 (14.1)	0.028
Absent (N) (%)	52 (70.3)	55 (85.9)	

CMBs: Cerebral microbleeds. The chi-square test was used

Table 3. Relationship between duration of rivaroxaban use and CMBs incidence

	Months			
	0-6	**7-12**	**13-58**	**P**
CMBs absent f (%)	20 (38.5%)	11 (21.2%)	21 (40.4%)	0.005
CMBs present f (%)	2 (9.1%)	2 (9.1%)	18 (81.8%)	

CMBs: Cerebral microbleeds. The chi-square test was used

In the rivaroxaban group, the number of CMBs was significantly higher in the frontal lobe, basal ganglia, and thalamus compared with the control group participants (Table 4). There was no significant difference between the two groups in terms of microbleeds at the other sites. In the rivaroxaban group, more microbleeds were detected in deep white matter ($p<0.05$) (Table 5). Analysis of the relationship of patient gender with other parameters including age, duration of rivaroxaban use, and CMB size revealed that the mean size of CMBs was significantly higher in men (4.46±1.81 mm) than women (2.92±1.12) ($p=0.013$). The agreement between two observers (i.e., neuroradiologists) was also examined. Observer 1 reported CMBs in 31 individuals; observer 2 agreed with observer 1 in 29 cases. Accordingly, CMB was reported to be absent in 107 individuals by Observer 1 and 109 individuals by Observer 2 (Table 6). The inter-observer agreement and the kappa coefficient were calculated as 98.55% and 0.957, respectively. These findings showed that the inter-observer agreement was excellent ($p= 0.001$).

Table 4. Anatomical localization of CMBs

Localization	Rivaroxaban		Control		P
	n	%	n	%	
Frontal	12	27.2	4	21.0	0.046
Parietal	5	11.3	2	10.5	0.257
Temporal	9	20.4	4	21.0	0.166
Occipital	2	4.5	3	15.8	0.655
Cerebellum	5	11.3	4	21.0	0.739
BG and Th	10	22.7	1	5.3	0.007
Brain stem	1	2.3	1	5.2	1.000

BG: Basal ganglion; Th: Thalamus. The chi-square test was used

Table 5. Depth localization of CMBs

Localization	Rivaroxaban		Control		P
	n	%	n	%	
Cortical	4	19	2	22.2	0.667
Subcortical	9	42.8	6	66.6	0.439
Deep white matter	8	38	1	11.1	0.020

The chi-square test was used

Table 6. Data on the participants' gender, group, and observer evaluation concerning CMBs

		n	%
Gender	**Male**	61	(44.20)
	Female	77	(55.80)
Drug use	**Rivaroxaban**	74	(53.62)
	Control	64	(46.38)
Number of CMBs	**Single**	12	(38.71)
	2-4	12	(38.71)
	5-7	2	(6.45)
	8 or more	5	(16.13)
Observer 1	**CMB present**	31	(22.46)
	No CMB	107	(77.54)
Observer 2	**CMB present**	29	(21.01)
	No CMB	109	(78.99)

CMBs: Cerebral microbleeds

Discussion

Our findings showed that CMB incidence was significantly higher in patients with NVAF who were using rivaroxaban compared with the control group. There was also a significant correlation between the duration of rivaroxaban use and the incidence of CMBs. It was reported that patients with NVAF and CMB who suffered from ischemic stroke had higher rates of cardiovascular and stroke-related mortality than those without CMBs [10]. In clinical practice guidelines, CMB is not accepted as a contraindication for starting and maintaining prophylactic antithrombotic therapy in patients with NVAF [11]. Since our study indicated that the rate and size of CMBs were higher in patients with NVAF who are on prophylactic antithrombotic treatment with rivaroxaban, it can be hypothesized that these patients may be under increased risk of a cerebral hemorrhage. Since the duration of rivaroxaban use

correlated with the rate of CMB, it can also be postulated that these patients may face the risk of a cerebral hemorrhage in the long-term rather than after short term use.

The CMBs are commonly located in the cortico-subcortical regions of the brain, and they more frequently affect deep brain regions such as basal ganglia, thalamus, and brainstem [12]. Similarly, in our study, we found a higher rate of CMBs in the basal ganglia and thalamus.

Non-valvular atrial fibrillation is an important risk factor for cardiogenic embolism [13]. The clinical symptoms of cardiogenic embolism tend to be more severe than the other subtypes of ischemic stroke. Non-vitamin K antagonist oral anticoagulants (NOACs) are not inferior to warfarin in preventing stroke [14]. These 'direct' oral anticoagulants are associated with lower stroke and death risks in patients with NVAF. Although the increased risk of hemorrhagic stroke in patients with CMBs raises concerns regarding the use of antithrombotic agents by the patients with NVAF, it has been reported that patients on warfarin have a higher risk of deep or infratentorial CMBs [15]. It was recently found that CMBs increased the risk of both ischemic stroke and intracerebral hemorrhage [16, 17]. A meta-analysis showed that the risk of recurrent stroke was 2.2 times higher in patients with CMBs [18]. It was also stated that CMB increased the risk of hemorrhagic transformation and was an independent risk factor for transient ischemic attack (TIA) or a new ischemic stroke after TIA [12, 19, 20]. In a pooled analysis of 1460 patients with intracranial hemorrhage (ICH) and 3817 cases with ischemic stroke or TIA, the authors reported that CMBs were more common in those with ICH, regardless of the premorbid use of antithrombotic agents [21]. In this study, the risk of ICH did not differ with the antithrombotic regimen used. In contrast, a longitudinal study showed that the use of warfarin in stroke patients with at least three CMBs was associated with an increased incidence of deep ICH [22]. In a study that patients who had experienced an ischemic stroke due to NVAF, the prevalence of CMBs was 31% [23]. Approximately 97% of these patients were discharged with a warfarin prescription. After 2.5 years of follow-up, the overall mortality rate was calculated as 34.9%. The mortality rate was higher in patients with CMBs than those without CMBs (41.9 vs.31.8%) in this cohort. These authors also noted that the presence of at least five CMBs was independently associated with all-cause mortality, as well as ischemic stroke-related mortality. Besides, another research reported that patients with strict lobar CMBs had a higher risk of hemorrhagic stroke-related mortality [10].

Non–vitamin K antagonist oral anticoagulants are associated with a lower risk of ICH than warfarin [24]. However, to date, only limited data are available on this topic. A recent study included 69 patients with AF who underwent cranial MRI and compared them according to the antiplatelet regimen used for one year [25]. Among the study group patients, 23 were on NOACs, 21 on warfarin, 9 on warfarin plus an antiplatelet agent, 9 solely on an antiplatelet agent, and 7 on antithrombotic medication. These authors reported that new-onset CMBs occurred in 13% of the patients. While no new CMBs were detected in the NOAC or antiplatelet groups, 5 (23.8%) patients in the warfarin, 3 (33.3%) patients in the warfarin plus antiplatelet agent and 1 (14.2%) patient in the non-antiplatelet group developed a new-onset CMB. To the best of our knowledge, literature regarding the impact of CMBs on thromboembolic event prevention methods in NVAF patients is scarce. Further research is needed to assess the benefit of cranial MRI performed with SWAN protocol for predicting the risk of ICH in patients with CMB who are on warfarin or NOACs.

Little is known about the incidence of CMBs and risk factors for the development of new CMBs [26]. There are studies regarding the prevalence of CMBs in patients with Parkinson's disease, ICH, and dementia, which revealed variable results [27, 28]. New-onset CMBs have also been reported in patients treated with intravenous thrombolysis or warfarin [29, 30].

Our study has some limitations which need to be considered while evaluating its findings. First, our sample size was relatively small. Second, the CMBs' diagnosis and characterization were based on a single MRI scan; it would be better to reassess the patients with a post-follow up MRI scan. This approach could both lower the risk of misdiagnosis and give information regarding the progress of the CMBs in patients with this diagnosis. Third, this study did not compare the risk of CMB in patients on rivaroxaban with the risk of patients who are using other antithrombotic medications with the same indication. Our study period was not long enough to comment on the risk of stroke in patients diagnosed with CMB.

Our findings are not strong enough to conclude that rivaroxaban or any other antithrombotic medication should be avoided in patients with NVAF. However, they indicate that rivaroxaban increases the incidence of CMBs in these patients. Since it is widely accepted that CMBs are associated with increased risk of stroke, we suggest that it would be wise to assess the NVAF patients with cranial MRI scans before initiating and during rivaroxaban treatment. We recommend that the clinician should take caution in terms of increased stroke risk if the cranial MRI scan reveals CMBs.

Conflict of interests
The authors declare that they have no competing interests.

Financial Disclosure
All authors declare no financial support.

Ethical approval
Ethics approval was obtained from Adıyaman University Non-Interventional Clinical Research Ethics Board with the number of 2017/6-11.)

References

1. Wobith M, Mayer C, Belke M, et al. Predictors of new cerebral microbleeds in patients with antiplatelet drug therapy. J Stroke Cerebrovasc Dis. 2016;25:1671-7.
2. Wang J, Zhang J, Shen Y, et al. The safety of antithrombotic therapy in patients with cerebral microbleeds and cardiogenic cerebral embolism due to nonvalvular atrial fibrillation. BMC Cardiovasc Disord. 2019;19:77.
3. Xia Z, Li Y, Wang H, editors. The application of T2 Star Weighted Angiography (SWAN) in hypoxic-ischemic encephalopathy. Proc ISMRM; 2011.
4. Docampo J, Gonzalez N, Bravo F, et al. Susceptibility-weighted angiography of intracranial blood products and calcifications compared to gradient echo sequence. Neuroradiol J. 2013;26:493-500.
5. Cope S, Clemens A, Hammès F, et al. Critical appraisal of network meta-analyses evaluating the efficacy and safety of new oral anticoagulants in atrial fibrillation stroke prevention trials. Value in Health. 2015;18:234-49.
6. Fauchier L, Philippart R, Clementy N, et al. How to define valvular atrial fibrillation? Arch Cardiovasc Dis. 2015;108:530-9.

7. Charidimou A, Shoamanesh A, Wilson D, et al. Cerebral microbleeds and postthrombolysis intracerebral hemorrhage risk Updated meta-analysis. Neurology. 2015;85:927-4.

8. Perzborn E, Roehrig S, Straub A, et al. Rivaroxaban: A new oral factor Xa inhibitor. Arterioscler Thromb Vasc Biol. 2010;30:376-81.

9. Ezekowitz MD, Nagarakanti R, Noack H, et al. Comparison of dabigatran and warfarin in patients with atrial fibrillation and valvular heart disease: The RE-LY Trial (Randomized Evaluation of Long-Term Anticoagulant Therapy). Circulation. 2016;134:589-98.

10. Song T-J, Kim J, Song D, et al. Association of cerebral microbleeds with mortality in stroke patients having atrial fibrillation. Neurology. 2014;83:1308-15.

11. Powers WJ, Rabinstein AA, Ackerson T, et al. 2018 guidelines for the early management of patients with acute ischemic stroke: a guideline for healthcare professionals from the American Heart Association/American Stroke Association. Stroke. 2018;49:e46-e99.

12. Poels MM, Vernooij MW, Ikram MA, et al. Prevalence and risk factors of cerebral microbleeds: an update of the Rotterdam scan study. Stroke. 2010;41:S103-S6.

13. Dogliotti A, Paolasso E, Giugliano RP. Current and new oral antithrombotics in non-valvular atrial fibrillation: a network meta-analysis of 79 808 patients. Heart. 2014;100:396-405.

14. Yu AY, Malo S, Svenson LW, et al. Temporal trends in the use and comparative effectiveness of direct oral anticoagulant agents versus warfarin for nonvalvular atrial fibrillation: A Canadian population-based study. 2017;6:e007129.

15. Akoudad S, Portegies ML, Koudstaal PJ, et al. Cerebral microbleeds are associated with an increased risk of stroke: The Rotterdam Study. Circulation. 2015;132:509-16.

16. Akoudad S, Darweesh SK, Leening MJ, et al. Use of coumarin anticoagulants and cerebral microbleeds in the general population. Stroke. 2014;45:3436-9.

17. Bokura H, Saika R, Yamaguchi T, et al. Microbleeds are associated with subsequent hemorrhagic and ischemic stroke in healthy elderly individuals. Stroke. 2011;42:1867-71.

18. Charidimou A, Kakar P, Fox Z, et al. Cerebral microbleeds and recurrent stroke risk: systematic review and meta-analysis of prospective ischemic stroke and transient ischemic attack cohorts. Stroke. 2013;44:995-1001.

19. Potigumjon A, Watcharakorn A, Dharmasaroja PA. Prevalence of cerebral microbleeds in Thai patients with ischemic stroke. J Neurosci Rural Pract. 2017;8:216.

20. Soo YO, Siu DY, Abrigo J, et al. Risk of intracerebral hemorrhage in patients with cerebral microbleeds undergoing endovascular intervention. Stroke. 2012;43:1532-6.

21. Lovelock CE, Cordonnier C, Naka H, et al. Antithrombotic drug use, cerebral microbleeds, and intracerebral hemorrhage: A systematic review of published and unpublished studies. Stroke. 2010;41:1222-8.

22. Imaizumi T, Inamura S, Kohama I, et al. Antithrombotic drug uses and deep intracerebral hemorrhages in stroke patients with deep cerebral microbleeds. J Stroke Cerebrovasc Dis. 2013;22:869-75.

23. Lioutas VA, Goyal N, Katsanos AH, et al. Microbleed prevalence and burden in anticoagulant-associated intracerebral bleed. Ann Clin Transl Neurol. 2019;6:1546-51.

24. Ruff CT, Giugliano RP, Braunwald E, et al. Comparison of the efficacy and safety of new oral anticoagulants with warfarin in patients with atrial fibrillation: A meta-analysis of randomised trials. The Lancet. 2014;383:955-62.

25. Saito T, Kawamura Y, Sato N, et al. Non-vitamin k antagonist oral anticoagulants do not increase cerebral microbleeds. J Stroke Cerebrovasc Dis. 2015;24:1373-7.

26. Goos J, Henneman W, Sluimer J, et al. Incidence of cerebral microbleeds: A longitudinal study in a memory clinic population. Neurology. 2010;74:1954-60.

27. Yamashiro K, Tanaka R, Hoshino Y, et al. The prevalence and risk factors of cerebral microbleeds in patients with Parkinson's disease. Parkinsonism Relat Disord. 2015;21:1076-81.

28. Shams S, Martola J, Granberg T, et al. Cerebral microbleeds: Different prevalence, topography, and risk factors depending on dementia diagnosis—the Karolinska Imaging Dementia Study. AJNR Am J Neuroradiol. 2015;36:661-6.

29. Braemswig TB, Villringer K, Turc G, et al. Predictors of new remote cerebral microbleeds after IV thrombolysis for ischemic stroke. Neurology. 2019;92:e630-e8.

30. Orken DN, Uysal E, Timer E, et al. New cerebral microbleeds in ischemic stroke patients on warfarin treatment: Two-year follow-up. Clin Neurol Neurosurg. 2013;115:1682-5.