Available online at www.medicinescience.org

ORIGINAL ARTICLE

Medicine Science 2022;11(1):259-66

Medicine Science International Medical Journal

Comparison of the healing effects of activated protein c and triiodothyronine replacements in the late period of experimental sepsis

Celil Ugurlu[1], Bahadir Kulah[2], Ata Turker Arikok[3], Bulent Koca[1], Hakan Kulacoglu[4]

[1]Tokat Gaziosmanpasa University, Department of General Surgery, Tokat, Turkey
[2]Yildirim Beyazit Training and Research Hospital, Department of General Surgery Ankara, Turkey
[3]Yildirim Beyazit Training and Research Hospital, Department of General Pathology, Ankara, Turkey
[4]Ankara Lokman Hekim University, Department of General Surgery, Ankara, Turkey

Received 29 September 2021; Accepted 31 October 2021
Available online 05.02.2022 with doi: 10.5455/medscience.2021.09.321

Copyright@Author(s) - Available online at www.medicinescience.org
Content of this journal is licensed under a Creative Commons Attribution-NonCommercial 4.0 International License.

Abstract

Sepsis is one of the most serious problems in intensive care units due to its high morbidity and mortality. Objective of the study to compare the healing effects of Activated Protein C and Tri-Iodothyronine in the late period of experimental sepsis. Twenty-four Wistar Albino male rats were divided into 4 groups, including the control group, septic group, Activated Protein C (APC), and Tri-Iodothyronine (T3) treatment groups. Leukocyte, thrombocyte, IL-1, IL-6, TNF-α, and antithrombin-III levels were investigated. Histopathological evaluation was performed by taking the liver, lung and intestinal tissue samples. The APC and T3 replacement groups were compared with the septic rat group, and it was observed that they preserved thrombocyte levels and antithrombin III levels, suppressed interleukin levels, and limited the effects of inflammatory responses in the liver, intestine and lung tissue. Leukocyte levels were found to be significantly higher in the T3 replacement group than in the septic group, while there was no significant difference between the APC group and the septic group. Our study showed that both activated protein C and Tri-iodothyronine can be effective in the host's response to infection in the late period of sepsis, alone and in a single dose.

Keywords: Sepsis, activated protein C, tri-iodothyronine, cecal ligation and puncture, proinflammatory cytokines, antithrombin III

Introduction

Sepsis is a condition that may lead to death because of shock and multiple organ dysfunction syndromes (MODS) by causing hemodynamic changes that are closely related to the body's immune, inflammation and coagulation systems due to the response to infection [1]. Despite the increase in our knowledge about sepsis pathophysiology recently, an increase has been observed in the incidence of sepsis.

Recent studies on sepsis have provided important data in terms of physiopathological mechanisms. These studies have made significant contributions to clarify the varying clinical spectra of sepsis with clear criteria and shaping the clinical picture of the host's response to infection. Thus, it has been possible to determine new targets in the treatment approaches of sepsis [2]. Hemodynamic and metabolic changes caused by sepsis in the host are divided into two periods: the early hyperdynamic phase within the first 6-20 hours and the late hypodynamic phase after 20 hours [3]. A specific therapeutic agent that can provide the expected effect on the pathophysiological changes that are effective in the process of sepsis starting from local infection and progressing to MODS has not yet been found.The fact that the occurrence of adrenal insufficiency has been shown in late-stage sepsis has once again brought up the use of corticosteroids in re-treatment. Meanwhile, the demonstration of activation of the inflammatory and coagulation cascades in sepsis has strengthened the possibility of Active Protein C being effective. In many previous experimental and clinical studies, it was suggested

***Corresponding Author:** Celil Ugurlu, Tokat Gaziosmanpasa University, Department of General Surgery, Tokat, Turkey
E-mail: basri_celil@hotmail.com

that Activated Protein C and corticosteroids decreased mortality [4,5]. However, since multiple mechanisms affect the host's systemic inflammatory response in sepsis, the results obtained in experimental studies are not reflected in clinical outcomes [6].

Euthyroid sick syndrome develops in sepsis, and it is thought that significant improvements can be achieved in the cellular and humoral immunity of the host with tri-iodothyronine replacement [7].

In our study, we performed the cecal ligation and puncture (CLP) experimental model, which is widely accepted to experimentally mimic intra-abdominal sepsis due to intestinal perforations, as a cause of severe morbidity and mortality [8].

Considering the effectiveness of sepsis to activate coagulation and inflammatory cascades, we evaluated the parameters including hemoglobin, hematocrit, thrombocyte, leukocyte levels, TNF-α, IL-1, IL-6, and antithrombin III levels to identify the sepsis occurrence and the comparison of therapeutic effects.

Firstly, we compared the replacement groups with the other groups (control and septic) in terms of free T3 levels to reveal the euthyroid sick syndrome due to sepsis. Later, we examined the pathological changes caused by sepsis in the intestinal, lung, and liver tissue of our study groups and compared them to each other in terms of these histopathological changes.

Eventually, we compared the healing and therapeutic effects of Activated Protein C (Xigris) and Tri-Iodothyronine (Thyrotardin Inject) in the late stage of polymicrobial sepsis in light of the parameters mentioned above.

Materials and Methods

This experimental study was conducted in the experimental research laboratory, following ethics committee approval of Ankara Dışkapı Yıldırım Beyazıt Training and Research Hospital was obtained (DAEK-22/11).

Twenty-four male adult Wistar-Albino rats weighing approximately 280-340 g were used in the study. The subjects were kept in a room (22-24 °C, 70-75% humidity) having daylight for 12 hours and a ventilation system for one week before the experiment. They were fed with standard rat food and tap water.

The subjects included in the study were marked and randomly divided into 4 groups as Control, CLP, Activated protein C (APC) treatment groups and Tri-Iodothyronine replacement group (T3).

Anesthesia

Surgery, injections and blood sampling in all subjects were performed under intramuscular anesthesia of 50mg/kg ketamine hydrochloride (Ketalar®) and 10mg/kg xylazine hydrochloride (ROMPUN®).

Surgical Technique

After shaving the abdominal areas of rats, they were cleaned with betadine to provide asepsis antisepsis conditions and surgical interventions were performed using sterile sets.

Groups

1. The Control Group: Only a 1.5 cm midline abdominal incision was made in the rats in this group. The cecum was observed and returned to the abdomen after it was understood that it was intact. The abdominal wall was closed.

2. The CLP Group: A 1.5 cm midline incision was applied to this group of rats, which we defined as the septic rat group. The cecum was taken out and tied with 4/0 silk so as not to interfere with intestinal continuity. The cecum was punctured in two separate places with the help of a 21-gauge injector needle as described using the Wichterman method. After the cecum was squeezed out, and some feces were released, and the cecum was returned to the abdomen as it was. The abdominal wall was closed.

3. The APC group: In this group, cecal ligation and puncture were applied to the rats as in the CLP group. 6 hours after this procedure, Drotrecogin Alfa (Xigris®, Lilly) at a dose of 100 µg/kg were administered intraperitoneally to the rats.

4. The T3 replacement group: Tri-Iodothyronine (Thyrotardin® Inject N Henning, Berlin GMBH, Germany) at a dose of 0.4 µg/100g was administered to the rats in this group 6 hours after the CLP process.

After surgical procedures and replacement treatments were applied, 4 ml of warmed saline was administered subcutaneously to the rats. Wounds were covered with Terramycin pomade. All rats were prepared following the asepsis antisepsis conditions for sampling after anesthesia was provided at the 24th hour.

Sampling for hemavet at the 24th hour

By opening the old incision line and expanding it to include the chest cavity, 5-7 ml of blood sample was taken from the intracardiac left ventricular cavity. 2 cc of the blood taken was placed in hemogram tubes containing 180 µl EDTA and sent to the Ankara Training and Research Hospital Hematology Laboratory. Hemoglobin, hematocrit, leukocyte, thrombocyte and erythrocyte levels were measured with a Beckman Coulter LH-780 model device.

Sampling for ANTITHROMBIN III, IL-1, IL-6, TNF-α level at the 24th hour

4 ml of intracardially-taken blood sample was transferred to biochemistry tubes containing citrate. Blood samples were separated into serum by centrifugation at 4000 rpm for 10 minutes. Serum samples were placed in Eppendorf tubes and stored at -80 °C until the day of analysis.

The serum TNF-α level was studied with a TNF-α rat Platinum ELISA kit. The serum IL-6 level was studied with an IL-6 rat Platinum ELISA kit. The serum IL-1 level was studied with an IL-1 rat Platinum ELISA kit. The serum AT3 level was studied with an AT3 rat ELISA kit.

Tissue samples at the 24th hour

After blood samples were taken, the liver, lung, and small intestine tissue sampling process of the rats were started. Tissue samples of

the left liver lobe left lung lobe, approximately 1.5 cm of the small intestine from the terminal ileum was taken standard from all rat groups and transferred to bottles containing 10% formaldehyde. Paraffin blocks were prepared in the laboratories of the Pathology Clinic II of Dışkapı Yıldırım Beyazıt Training and Research Hospital and stained with hematoxylin eosin. They were evaluated by a pathologist who has no awareness of the experimental groups.

Statistical Analysis

The data were evaluated using the SPSS 17.0 statistical program. Using SPSS, the data of all 4 study groups were evaluated with the Tukey post hoc test by using analysis of variance (ANOVA) method, and a p-value of <0.05 was considered statistically significant. The results were also compared with the LSD Benfoni test results. The values found to be significant between the groups were also verified by comparing them with the results of the non-parametric tests (Man Whitney U and Kruskal Wallis test results).

Results

T3 Levels

We measured the free T3 levels in our study groups to clarify whether euthyroid sick syndrome developed at the 24th hour after CLP (Figure 1). In the statistical comparisons made with the Tukey post hoc test, the free T3 levels in the control group were found to be significantly higher than the septic and APC groups (p<0.002, p<0.02, respectively), while they did not differ significantly from the free T3 levels in the T3 replacement group. The T3 levels of the T3 group were significantly higher than the T3 levels of the septic and APC groups (p<0.001, p<0.001, respectively).

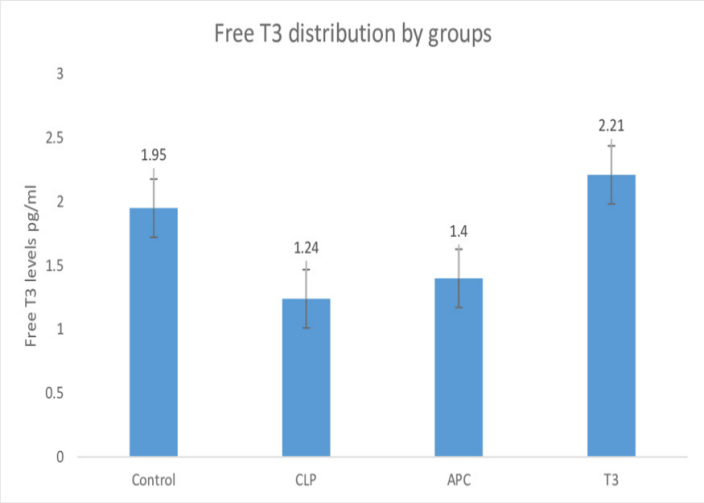

Figure 1. Columns show the late phase (24 h) T3 concentrations for each group

Leukocyte levels

The leukocyte levels were examined in the blood samples taken at the 24th hour and the mean leukocyte levels were measured (Figure 2). The leukocyte levels of the control group and T3 group were significantly higher than the leukocyte levels of the septic group and APC group (p<0.001, p<0.001, p<0.001, and p<0.001, respectively).

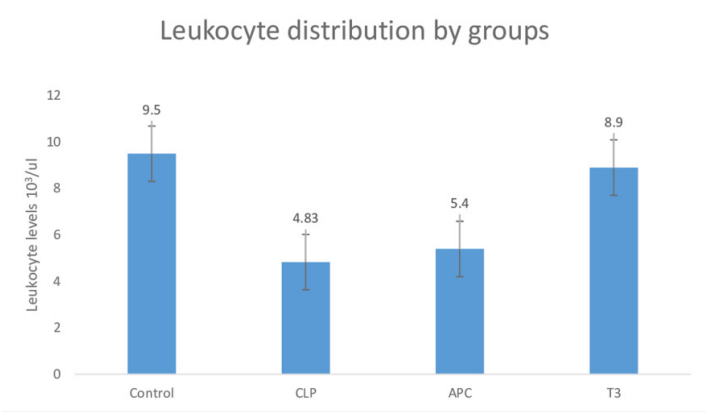

Figure 2. Columns show the late phase (24 h) Leukocyte concentrations for each group

Platelet Levels

The average platelet levels in the groups at the 24th hour were measured (Figure 3). When the intergroup levels were compared with the LSD Benfoni test, the platelet levels in the control group were significantly higher than the platelet levels of the septic, APC, and T3 groups (p<0.001, p<0.001, and p<0.001, respectively). Platelet levels of the APC and T3 groups were also significantly higher than the platelet levels of the septic group. There was no significant difference between platelet levels in the APC and T3 groups.

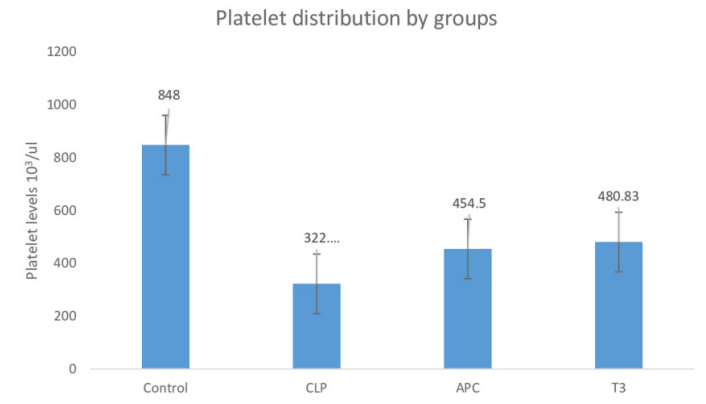

Figure 3. Columns show the late phase (24 h) Platelet concentrations for each group

IL-1 Levels

The average levels of IL-1 in the groups at the 24th hour were measured (Figure 4). The comparison of IL-1 levels of the control group, APC, and T3 groups made with the Tukey post hoc test revealed that IL-1 levels were significantly lower than those of the septic group (p<0.001, p<0.001, p<0.001, respectively).

IL-6 Levels

The average IL-6 levels in the groups at the 24th hour were found to be 184.55 pg/ml in the control group, 278.35 pg/ml in the septic group, 204.90 pg/ml in the APC group, and 200.19 pg/ml in the T3 group, respectively. The comparison of the IL-6 levels of the control group, APC, and T3 groups made with the Tukey post hoc

test revealed that IL-1 levels were significantly lower than those of the septic group (p<0.001, p<0.001, p<0.001, respectively).

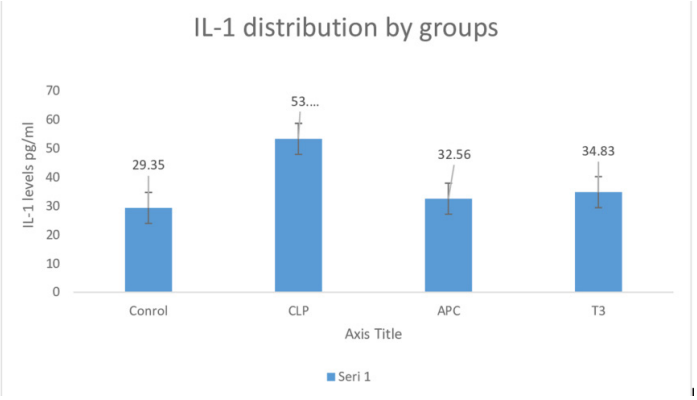

Figure 4. Columns show the late phase (24 h) IL-1 concentrations for each group

TNF-α Levels

When the average TNF-α levels in the groups were examined, the TNF-α levels were found to be 48.30 pg/ml in the control group, 55.10 pg/ml in the septic group, 49.18 pg/ml in the APC group, and 48.93 pg/ml in the T3 group. The comparison of the TNF-α levels of the control group, APC, and T3 groups made with the Tukey post hoc test revealed that the TNF-α levels were significantly lower than those of the septic group (p<0.001, p<0.001, p<0.001, respectively).

ATIII Levels

The average AT III levels in the groups at the 24th hour were measured (Figure 5). The comparison of AT III levels of the control group, APC, and T3 groups made with the Tukey post hoc test revealed that AT III levels were significantly higher than those of the septic group (p<0.001, p<0.002, p<0.001, respectively).

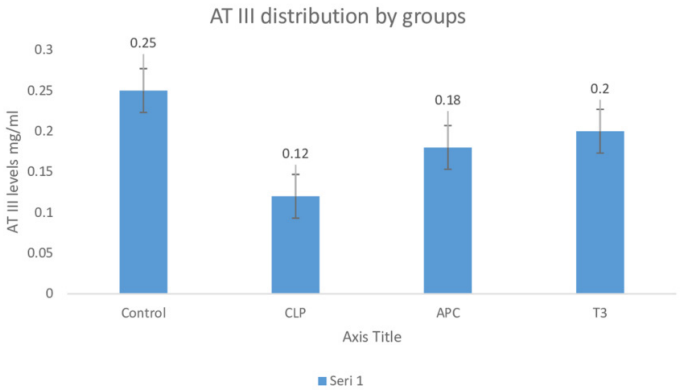

Figure 5. Columns show the late phase (24 h) AT III concentrations for each group

Histopathological Examination Results

Lung tissue taken from all groups at the 24th hour was divided into ten different sections and examined histopathologically. Severe hemorrhage, significant leukocyte infiltration, and a significant increase in alveolar thickness were observed in the septic group compared to the other groups (Figure 6). There was mild hemorrhage in all rats in the APC group, mild leukocyte infiltration in 5 rats (83.3%), and a slight increase in alveolar thickness in another 5 rats (83.3%). In the T3 group, two rats (33%) had a moderate hemorrhage, and the others had a mild hemorrhage. Mild leukocyte infiltration and a slight increase in alveolar thickness were observed in all rats in the T3 group.

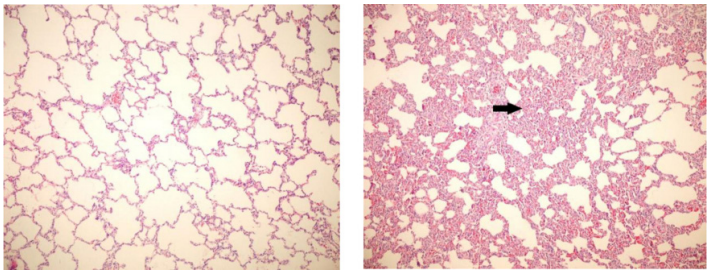

Figure 6. First image shows normal lung tissue and the second image shows infiltrated lung tissue by PMN, 10X, Hematoxylin and Eosin (H&E

Histopathological examination of liver tissue revealed significantly increased sinusoidal dilatation, sinusoidal hyperemia, and focal necrosis in septic group rats compared to the other groups (Figure 7). Of the APC group rats, 5 (80%) had mild sinusoidal dilatation around the central vein, and 4 (64%) had mild sinusoidal hyperemia. The focal necrosis focus was not observed in any APC group rat. Of the T3 group rats, 3 (50%) had mild sinusoidal dilatation around the central vein, and 3 (50%) had mild sinusoidal hyperemia. Focal necrosis foci were not observed in any rat in the T3 group.

Histopathological examination of the intestinal tissue samples taken 24 hours after CLP revealed total villous atrophy in 3 (50%), and subtotal villous atrophy in 3 (50%) of the rats in the septic group (Figure 8). Villous atrophy was not observed in the control group rats. Subtotal villous atrophy was observed in 2 (33%) of APC group rats. Subtotal villous atrophy was observed in 2 (33%) of the T3 group rats.

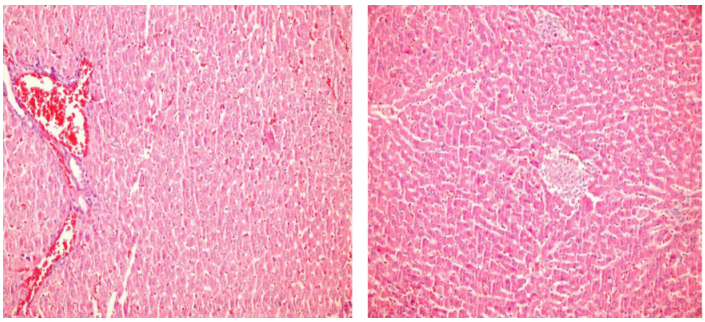

Figure 7. First image shows normal liver tissue and the second one shows congested liver tissue, 20X, Hematoxylin and Eosin (H&E)

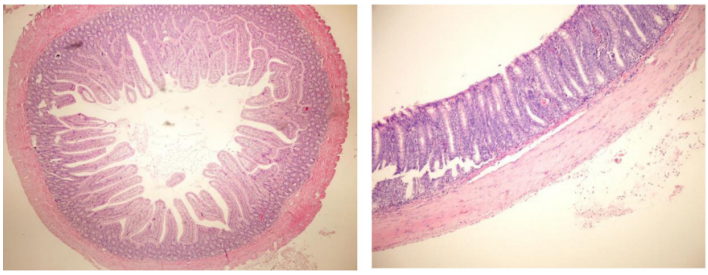

Figure 8. First image shows normal intestine tissue 10X and the second image shows total villous atrophy, 20X, Hematoxylin and Eosin (H&E)

Discussion

In our study, we performed the CLP model, known as have many similar findings of sepsis developing in humans [8]. Many studies have shown that the polymicrobial sepsis model created with CLP develops in 2 phases: the hyperdynamic phase in which cardiac output and organ perfusion increase in the first 2-10 hours, and the hypodynamic late phase, in which tissue perfusion decreases after 20 hours [9].

Recent studies have focused on sepsis indicated that inflammation and activation of coagulation cascades and dysfunction in endothelial cells as the most important physiopathological changes leading to organ failure. The most critical step of these is deterioration in endothelial functions. Endothelial tissue is considerably more vulnerable to septic insult, septic insult leads to permeability increases in the endothelium because of the release of proinflammatory cytokines such as IL-1, IL-6, and TNF-α within 6 hours [10].

An important point here is that excessive release of inflammatory mediators due to activation of the inflammatory cascade causes endothelial damage, thus the chain mechanisms such as hypercoagulability, microvascular thrombus formation, disseminated intravascular coagulation accelerate the process leading to organ failure [11].

Our study showed that there was no significant difference between the septic group, control group, APC group, and T3 replacement group in terms of hemoglobin and hematocrit values.

Thrombocytopenia is an important finding of acute DIC and is associated with bleeding and excessive thrombin production. Although the production of thrombocytes from the bone marrow increases in severe thrombocytopenia, the life span of these platelets is short [12,13]. We observed that the leukocyte levels of the septic group were significantly lower than those of the control group and T3 group and that they were also lower than normal in the activated protein C replacement group. We observed that the platelet levels of the septic group rats were significantly lower than those of the control group, T3 replacement group, and activated protein C replacement group rats.

Many studies emphasize that the healing effects of activated protein C on leukocyte and platelet levels are based on its anti-inflammatory and antithrombotic properties [14]. In a study in which activated protein C was applied, it was found that the mortality rate for any reason decreased by 19.4% relatively and 6.1% absolutely in 28 days in severe sepsis cases with the application of activated drotrecogin alpha [15]. In a study by Vincent et al in 2005, the 28th-day mortality rate in patients with sepsis was given activated protein C was found to be 25.3% [16].

Activation of the hypothalamopituitary adrenal axis has been blamed for developing euthyroid sick syndrome in patients with sepsis. It develops in the early period of sepsis and is characterized by a decrease in serum-free T3 levels [17]. The T4 hormone is converted into T3 hormone in peripheral tissues by the effect of 5'deiodinase enzyme. The activity of this enzyme is impaired in sepsis and T4-T3 conversion is impaired in peripheral tissues. Moreover, proinflammatory cytokines such as IL-6 and TNF-α disrupt the thyroid hormone balance by inhibiting the 5'monodeiodinase enzyme [18]. The fact that free T3 hormone was found to be significantly lower in septic patients than in non-septic patients suggested that T3 hormone replacement has beneficial effects for treating sepsis [19]. In our study, we experimentally observed that euthyroid sick syndrome developed at the 24th hour in the late period of sepsis. Free T3 levels were found to be significantly higher in the rats in the T3 replacement group than in those in the APC group and the Septic group. There was no significant difference between the free T3 hormones of the control group and the group that was administered T3. It is mentioned in the literature that the T3 hormone replacement has a mortality-reducing effect in the experimental sepsis model with tri-iodothyronine replacement [19]. Thyroid hormones play an active role in cellular immunity. The increase in di-iodotyrosine levels, a breakdown product of serum T4 hormone metabolism, is the determinant of leukocyte activation in cases of severe infection and sepsis [20]. In our study, leukocyte levels of T3 group rats were found to be significantly higher than the septic group rats, and no significant difference was found compared with the control group. This result is consistent with the literature findings emphasizing the effect of thyroid hormones on cellular immunity and leukocyte functions.

Sepsis, which causes endothelial damage, increases the tendency to coagulation by activating the coagulation cascade with the release of the endothelial tissue factor. As a result, it can progress to organ failure by causing the development of microvascular thrombosis and DIC in tissues [21,22]. A decrease in protein C and antithrombin III levels is accepted as a prognostic indicator for determining the severity of sepsis. Especially, a serious decrease in Antithrombin III levels is a negative prognostic factor in terms of going into septic shock [23].

Antithrombin functions as a physiological anticoagulant, and its anti-inflammatory effect is also mentioned [24]. Replacing the reduced AT III is important in terms of mortality and protection of organ functions. Fourrier et al. administered AT III to 34 patients who developed septic shock and DIC in a randomized, double-blind, placebo-controlled study. While the plasma AT III levels decreased in the untreated group, they remained normal in the treatment group [25]. Although Warren et al. measured AT III levels below normal levels in sepsis; they could not show a positive effect of replacement therapy on survival [26]. Chapital et al. suggested that triiodothyronine had a healing effect on antithrombin III levels in sepsis [23]. Antithrombin is an important determinant in the diagnosis of DIC, and a decrease in AT III level is observed when DIC develops [27]. In a study conducted with pediatric patients with severe sepsis, it was shown that antithrombin III levels increased with activated protein C treatment [27].

In our study, we noted that there was a significant decrease in Antithrombin III levels in the septic group. We showed that APC group and T3 group rats to which we applied replacement therapy had a significantly higher level of Antithrombin III than the septic group rats in compliance with the literature findings. This increase in the AT III level can be explained by the removal of the suppressive effect of cytokines on natural anticoagulant mechanisms AT III, protein C and TFPI by APC and T3 that we used in the treatment.

Activated protein C regulates inflammation and coagulation systems by inhibiting the production of pro-inflammatory cytokines such as IL-1 in sepsis [28]. Thyroid hormones play an active role in

cellular immunity and humoral immunity. It has been shown that there are serious impairments in humoral and cellular immunity in patients with hypothyroidism [29]. In our study, we found that IL-1, IL-6, and TNF-α levels were significantly lower in rats that received activated protein C treatment and tri-iodothyronine replacement compared to the rats in the septic group. These results are consistent with the literature.

Microvascular obstruction and vasoconstriction are characterized by leukocyte aggregation, endothelial edema, decreased erythrocyte compliance and thrombosis. These developments result in serious damage, especially in the liver, lung and intestinal tissues [11]. It is stated that the main cause of organ failure is deterioration in liver functions. Since Kupffer cells in the liver constitute 90% of macrophages belonging to the reticuloendothelial system, the cytokines that will be released by the activation of these macrophages have serious effects on the systemic response to sepsis [30]. The development responsible for liver dysfunction is the decrease in portal vein flow in parallel with the decrease in the mesentery blood flow and thus the decrease in the perfusion of hepatocytes [30].

In our experimental model, the histopathological examinations of liver tissue in the septic group showed significant sinusoidal dilatation, sinusoidal hyperemia and necrosis compared with the control group, the activated protein C group, and the T3 replacement group. In the histopathological examination of rats in the control group, activated protein C replacement group, and T3 replacement group, no necrosis was observed in the liver tissue. We observed that there was no significant difference between histopathological examinations of the rats that received activated protein C replacement and T3 replacement and the control group in terms of sinusoidal dilatation and hyperemia in the liver tissue. We observed that activated protein C and tri-iodothyronine had significant healing effects on histopathological changes in the liver in the late period of sepsis.

We believe that tri-iodothyronine provides its healing effects in liver tissue samples by adaptation to oxidative stress it creates in hepatocytes. Tri-Iodothyronine replacement therapy activates the Mitochondrial Glycerophosphate Cytochrome-c Reductase enzyme responsible for regeneration in rat livers [31]. We can explain the healing effects of activated protein C in the liver with its lowering inflammatory cytokines, protecting endothelial integrity by reducing leukocyte adhesion and vascular permeability, and preventing apoptosis [32].

Acute respiratory distress syndrome (ARDS) and acute lung injury are considered two of the most important developmental stages of multiorgan failure caused by sepsis and subsequent mortality. Approximately 20-40% of patients with sepsis develop ARDS [33]. Histopathological changes in the lung due to sepsis are associated with the sequestration of inflammatory cells, complement activation, changes in cell membrane permeability, decreases in surfactant production, and the development of microvascular thrombosis. These physiopathological events impair lung functions with a decrease in lung compliance and an increase in the development of pulmonary shunts that cause severe hypoxia [33]. Neutrophil sequestration, an increased production of cytokines such as TNF-α, and local pulmonary chemokines have been reported to be responsible for the histopathological changes in the lung in experimental polymicrobial sepsis. NF-κB has been shown as another mediator responsible for acute lung injury [34].

In our experimental model, we observed severe hemorrhage in the lungs, severe leukocyte infiltration, and a marked increase in alveolar thickness in the septic group. We observed that the histopathological changes were significantly limited in the lung tissue samples of rats that received activated protein C and tri-iodothyronine replacement.

It is possible to explain the protective effects of Tri-iodothyronine on the lung with its ability to mitigate the reducing effect of surfactant production caused by sepsis, its ability to reduce the inflammatory response, and its ability to increase lung compliance [35]. Similarly, Dulchavsky et al. also stated that Tri-Iodothyronine replacement affected decreasing the increase in oxygen demand caused by sepsis and preventing septic damage in the lung tissue [36]. As stated in publications related to activated protein C in the literature, it seems possible to explain these protective effects with its anti-inflammatory properties inhibiting neutrophil activation and the production of inflammatory cytokines [11]. Another mechanism of the healing effects of activated protein C is probably through Nuclear Factor Kappa B (NF-κB). Because NF-B has been shown to be an important component in the immune response of the host's endothelium and monocytes to sepsis, and it has been stated that activated protein C plays an important role in the modulation of NF-κB [5].

Recent studies have shown that the role played by the intestinal tissue in sepsis is not only associated with inflammatory cytokine production. The relationship between intestinal tissue and liver Kupffer cells plays a critical role in the systemic response to sepsis. Kupffer cells are the major source of proinflammatory cytokines [30]. After the disruption of the intestinal barrier, bacterial and endotoxin translocation has an important place in the progress to organ failure. The intestinal barrier constitutes 80% of humoral immunity and 50% of cellular immunity. Polymicrobial sepsis activates the release of cytokines such as TNF-α and IL-6 from intestinal epithelial cells, and scientific studies have proven that both cytokines play an important role in the host's systemic inflammatory response [30].

Histopathological examination of intestinal tissue samples in the septic group in our study revealed that the total villous atrophy was 50% and subtotal villous atrophy was 50%. We found histopathological data indicating that the villi were better protected in rats receiving activated protein C and T3 replacement. Subtotal villous atrophy was observed in 33% of rats receiving tri-iodothyronine replacement and 33% of rats receiving activated protein C replacement, while total villous atrophy was not observed at all. Observation of significant positive changes in the intestinal tissue in rats receiving activated protein C and Tri-iodothyronine replacement was consistent with the literature findings. In a study by Zhi-Li Yang et al., it was shown that Tri-Iodothyronine replacement in the experimental polymicrobial sepsis model significantly reduced intestinal permeability in the intestinal tissue and protected the intestinal tissue against possible structural and functional damage due to sepsis, but they stated that further studies were needed on the protective mechanism [37]. The possible mechanism appears to be that Tri-Iodothyronine increases the synthesis of protective substances in intestinal epithelial cells and increases the resistance of the intestinal epithelium to oxidative

stress. Other literature data supporting this view are the studies that show a decrease in hypothyroid hormone levels, atrophy in intestinal epithelial cells, a decrease in mucosal DNA and protein content [37]. It has been proven that Activated Protein C prevents endothelial damage, suppresses inflammatory cytokine release, regulates microvascular circulation, and prevents apoptosis, and consequently prevents organ damage [27].

Conclusion

Considering our current data, we believe that a single dose of Tri-Iodothyronine replacement is at least as effective as Activated Protein C in limiting the damage in the intestinal tissue, liver, and lung tissue caused by the combined activation of inflammatory and coagulation cascades in experimental sepsis and that it can be a safe and cheap option in treatment. However, further studies with different parameters are needed to have the last word.

Conflict of interests
The authors declare that they have no competing interests.

Financial Disclosure
All authors declare no financial support.

Ethical approval
This experimental study was conducted in the experimental research laboratory, following ethics committee approval of Ankara Dışkapı Yıldırım Beyazıt Training and Research Hospital was obtained (DAEK-22/11).

References

1. Salomão R, Ferreira BL, Salomão MC, et al. Sepsis: evolving concepts and challenges. Braz J Med Biol Res. 2019;52:e8595.
2. Singer M, Deutschman CS, Seymour CW, et al. The Third International Consensus Definitions for Sepsis and Septic Shock (Sepsis-3). JAMA. 2016;315:801–10.
3. Yang S, Koo DJ, Chaudry IH, Wang P. The important role of the gut in initiating the hyperdynamic response during early sepsis. Journal of Surgical Research. 2000; 89:31-7.
4. Prigent H, Maxime V, Annane D. Science review: mechanisms of impaired adrenal function in sepsis and molecular actions of glucocorticoids. Crit Care. 2004;8:243- 52
5. Bernard GR, Vincent JL, Laterre PF et al. Efficacy and safety of recombinant human activated protein C for severe sepsis. N Engl J Med. 2001;344:699-709.
6. O'Brien JM Jr, Abraham E. New Approaches To The Treatment of Sepsis. Clin Chest Med. 2003;24:521-48.
7. İnan M, Koyuncu A, Aydın C, et al. Thyroid hormone supplementation in sepsis: An experimental study. Surgery Today. 2003;33:24-29.
8. Pareker SJ, Watkins PE. Experimental models of gram negative sepsis. B J Surg. 2001;88:22-30.
9. Wang P, Zhou M, Cioffi WG, et al. Is Prostacyclin Responsible For Producing The Hyperdynamic Response During Early Sepsis. Crit Care Med. 2000;28:1534-39
10. Vallet B. Bench-to-bedside review: endothelial cell dysfunction in severe sepsis: a role in organ dysfunction? Crit Care. 2003;7:130-8.
11. Dixon B. The Role of Microvascular Thrombosis in Sepsis. Anesthesia and Intensive Care. 2004;32:619-29.
12. Dellinger P. Inflammation and coagulation: implications for the septic patient. Clin Infect Dis. 2003;36:1259-65.
13. Bedet A, Razazi K, Boissier F, et al. Mechanisms of Thrombocytopenia During Septic Shock: A Multiplex Cluster Analysis of Endogenous Sepsis Mediators. Shock. 2018;49:641-8.
14. Favory R, Poissy J, Alves I, et al. Activated protein C improves macrovascular and microvascular reactivity in human severe sepsis and septic shock. Shock. 2013;40512-18.
15. Dhainaut JF, Laterre PF, Janes JM, et al. Drotrecogin alfa (activated) in the treatment of severe sepsis patients with multiple-organ dysfunction: data from the PROWESS trial. Intensive Care Med. 2003;29:894-903.
16. Vincent JL, Bernard GR, Beale R, et al. Drotrecogin alfa (activated) treatment in severe sepsis from the global open-label trial ENHANCE: further evidence for survival and safety and implications for early treatment. Crit Care Med. 2005;33:2266-77.
17. Fontes KN, Cabanelas A, Bloise FF, et al. Differential regulation of thyroid hormone metabolism target genes during non-thyroidal [corrected] illness syndrome triggered by fasting or sepsis in adult mice. Front Physiol. 2017;8:828.
18. Kim JG, Shin H, Kim W, et al. The value of decreased thyroid hormone for predicting mortality in adult septic patients: a systematic review and meta-analysis. Sci Rep. 2018;8:14137.
19. Todd SR, Sim V, Moore LJ, et al. The identification of thyroid dysfunction in surgical sepsis. J Trauma Acute Care Surg. 2012;73:1457-60.
20. Shankar-Hari M, Harrison DA, Rubenfeld GD, Rowan K. Epidemiology of sepsis and septic shock in critical care units: comparison between sepsis-2 and sepsis-3 populations using a national critical care database. Br J Anaesth. 2017;119:626-36.
21. Dolmatova EV, Wang K, Mandavilli R, Griendling KK. The effects of sepsis on endothelium and clinical implications. Cardiovasc Res. 2021;117:60-73.
22. Hoppensteadt D, Tsuruta K, Hirman J, et al. Dysregulation of inflammatory and hemostatic markers in sepsis and suspected disseminated intravascular coagulation. Clin Appl Thromb Hemost. 2015;21:120-7.
23. Chapital AD, Hendrick SR, Lloyd L, Pieper D. The effects of triiodothyronine augmentation on antithrombin III levels in sepsis. Am Surg. 2001;67:253–55.
24. Jackson SP, Darbousset R, Schoenwaelder SM. Thromboinflammation: challenges of therapeutically targeting coagulation and other host defense mechanisms. Blood. 2019;133:906-18.
25. Fourrier F, Chopin C, Goudemand J, et al. Septic shock, multiple organ failure, and disseminated intravascular coagulation. Compared patterns of antithrombin III, protein C, and protein S deficiencies. Chest. 1992;101:816-23.
26. Warren BL, Eid A, Singer P, et al. High Dose Antithrombin III in severe sepsis. a randomized controlled trial. JAMA. 2001;286:1869-78.
27. Lehmann C, Scheibe R, Schade M, et al. Effects of activated protein C on the mesentericmicrocirculation and cytokine release during experimental endotoxemia, Can J Anesth. 2008;55:3:155–62.
28. Dhainaut JF, Yan SB, Joyce DE, et al. Treatment effects of drotrecogin alfa (activated) in patients with severe sepsis with or without overt disseminated intravascular coagulation. J Thromb Haemost. 2004;2:1924-33.
29. Fontes KN, Cabanelas A, Bloise FF, et al. Differential regulation of thyroid hormone metabolism target genes during non-thyroidal [corrected] illness syndrome triggered by fasting or sepsis in adult mice. Front Physiol. 2017;25;8:828.
30. Ding LA, Li JS, Li YS, et al. Intestinal barrier damage caused by trauma and lipopolysaccharide. World J Gastroenterol. 2004;10:2373–8.
31. Lotkova H. Activation Of Mitochondrial Glycerophosphate Cytochrome C Reductase In Regenerating Rat Liver By Triiodothyronine. Physiol Res. 2001;50:3336.
32. Messaris E, Betrosian AP, Memos N, et al. Administration of human protein C improves survival in an experimental model of sepsis Critical Care Med. 2010;38:1:209-16.
33. Mercer-Jones MA, Heinzelmann M, Peyton JC, et al. The pulmonary inflammatory response to experimental fecal peritonitis: relative roles of tumor necrosis factor-alpha and endotoxin. Inflammation. 1997;21:401–17.

34. Browder W, Ha T, Chuanfu L, et al. Early activation of pulmonary nuclear factor kappaB and nuclear factor interleukin-6 in polymicrobial sepsis. J Trauma. 1999;46:590–6.

35. Raafat AM, Franko AP, Zafar R, et al. Effect of Thyroid Hormone (T3)-responsive changes in surfactant apoproteins on surfactant function during sepsis. J Trauma Injury. 1997;42:803-9.

36. Dulchavsky SA, Hendrick SR, Dutta S. Pulmonary biophysical effects of triiodothyronine augmentation during sepsis-induced hypothyroidism. J Trauma. 1993;35:104-8.

37. Yang ZL, Yang LY, Huang GW, Liu HL. Tri-iodothyronine supplement protects gut barrier in septic rats. World J Gastroenterol. 2003;9:347–50.