Kafkas Univ Vet Fak Derg
25 (5): 717-720, 2019
DOI: 10.9775/kvfd.2018.21606

Kafkas Universitesi Veteriner Fakultesi Dergisi
ISSN: 1300-6045 e-ISSN: 1309-2251
Journal Home-Page: http://vetdergikafkas.org
Online Submission: http://submit.vetdergikafkas.org

Case Report

Dog Massacre with Pesticide for Theft: Methomyl Poisoning [1]

Özgür ÖZDEMİR [1,a] Mehmet Burak ATEŞ [1,b] Mustafa ORTATATLI [1,c] Funda TERZİ [2]
Tülay AVCI [3] Fatih HATİPOĞLU [1,d] Mustafa Kemal ÇİFTÇİ [1]

[1] *This case report was presented as a poster at The International Conference on Science, Ecology and Technology, 25-28 August, 2015, Vienna, Austria*
[1] Selcuk University, Faculty of Veterinary Medicine, Department of Pathology, TR-42130 Konya - TURKEY
[2] Kastamonu University, Faculty of Veterinary Medicine, Department of Pathology, TR-37200 Kastamonu - TURKEY
[3] Veterinary Control Institute, Department of Toxicology, TR-42080 Konya - TURKEY
[a] ORCID: 0000-0002-1595-0557; [b] ORCID: 0000-0003-1297-426X; [c] ORCID:0000-0002-3713-813X; [d] ORCID:0000-0002-0103-5868

Article Code: KVFD-2018-21606 Received: 20.12.2018 Accepted: 25.03.2019 Published Online: 26.03.2019

How to Cite This Article

Özdemir Ö, Ateş MB, Ortatatli M, Terzi F, Avci T, Hatipoğlu F, Çiftçi MK: Dog massacre with pesticide for theft: methomyl poisoning. *Kafkas Univ Vet Fak Derg,* 25 (5): 717-720, 2019. DOI: 10.9775/kvfd.2018.21606

Abstract

In this case report, acute methomyl poisoning in dogs is described by pathological and toxicological findings for the first time in Turkey. Five of the thirty stray dogs that were found dead within 1-2 days after eating the foodstuffs in an industrial area in Konya were necropsied. Grossly, undigested pieces of chicken meat with a mild insecticidal smell in stomach of all dogs were found and toxicological analysis by GC-MS revealed toxic levels of methomyl in the stomach contents (15.7-17.8 ppm) and, intestines, livers and kidneys (1.2-2.9 ppm) also. In addition, histopathologically degenerative and necrotic changes were observed in liver, brain, lung, kidneys and gastrointestinal system mucosa. Postmortem and histopathological examinations and toxicological analyses revealed that deaths were related to methomyl poisoning and it has been subsequently learned from the police officers and printed media that this poison had been deliberately infected to dog food for the purpose of theft committed in the industrial area. Publishing these intentional poisoning events, we have wanted to draw attention to that more serious measures and statutory regulations should be taken by governments about animal rights.

Keywords: *Methomyl poisoning, Histopathology, Toxicology, Dog massacre, Intentional poisoning*

Hırsızlık İçin Tarım İlacıyla Köpek Katliamı: Metomil Zehirlenmesi

Öz

Bu olgu sunumunda, Türkiye'de ilk kez köpeklerde akut metomil zehirlenmesi patolojik ve toksikolojik bulgularıyla tanımlanmıştır. Konya'daki bir sanayi bölgesinde, yemlerini yedikten sonraki 1-2 gün içerisinde ölü olarak bulunan 30 adet sokak köpeğinden 5 tanesine nekropsi yapılmıştır. Nekropside köpeklerin midelerinde hafif insektisit kokusu içeren sindirilmemiş tavuk parçalarına rastlanılmış olup, GC-MS cihazıyla yapılan toksikolojik analiz sonucu mide içeriğinde (15,7-17.8 ppm) ve ayrıca bağırsaklar, karaciğer ve böbreklerde (1.2-2.9 ppm) toksik düzeyde metomil tespit edilmiştir. Ayrıca histopatolojik olarak karaciğer, beyin, akciğer, kalp, böbrek ve gastrointestinal sistem mukozalarında dejeneratif değişikler gözlenmiştir. Postmortem ve histopatolojik bulgular ile toksikolojik analizler neticesinde ölümlerin metomil zehirlenmesine bağlı olarak şekillendiği ortaya konulmuş olup, daha sonra adli makamlar ile yazılı basından alınan bilgilerden bu zehirin köpek yiyeceklerine bölgede gerçekleştirilen hırsızlık amacıyla kasten bulaştırıldığı öğrenilmiştir. Bu kasıtlı zehirlenme vakası ile, hükümetler tarafından hayvan hakları konusunda daha ciddi ve yasal önlemlerin alınması gerektiğine dikkat çekilmek istenilmiştir.

Anahtar sözcükler: *Metomil zehirlenmesi, Histopatoloji, Toksikoloji, Köpek katliamı, Kasıtlı zehirleme*

INTRODUCTION

Methomyl is a carbamate insecticide active ingredient that is widely used in agricultural applications and animal shelters against insects all over the world [1,2]. Absorption of methomyl may be from skin, respiratory tract or gastro-intestinal tract. It is highly toxic to birds and mammals when taken orally and shows its effect by inhibiting the enzyme Acetylcholinesterase (AChE). Acetylcholine is one of the most important neurotransmitter substances involved in the autonomic and somatic nervous system. Acetylcholine activates muscles by acting in the chemical pathway of nerve impulses at neuromuscular junctions. This neuro-transmitter substance is destroyed by the AChE enzyme after nerve stimulation. The inhibition of AChE in methomyl poisoning results in a toxicity table in which cholinergic symptoms are predominant due to the accumulation of acetylcholine at neuromuscular junctions and nerve

İletişim (Correspondence)
+90 332 2232734
mehmetburakates@selcuk.edu.tr

synapses [2-4]. Methomyl is classified in Class Ib as a highly toxic substance by World Health Organization (WHO) [5,6]. Methomyl oral LD50 is 17-24 mg/kg in rats, 10 mg/kg in mice, and 15 mg/kg in guinea pigs. In dogs, it has been reported that 10-20 mg/kg oral dose may lead to death [7]. Methomyl was found to be less detected in organs and tissues, although it was found to be high in the blood after oral administration [8-10].

Pathological and toxicological data related to methomyl poisoning are very limited in field of veterinary medicine and there is no published data in Turkey although there may be probably similar poisoning incidents. Therefore, the aim of this study is to present the results of macroscopic and histopathological findings along with toxicological analysis on methomyl poisoning, to assist in taking rapid diagnostic and preventive measures and to promote the sensitivity to the subject such deliberate poisonings.

CASE HISTORY

In this case presented, 30 street dogs were found dead in the next 1-2 days after having eaten their food in the nutrition centers built for the feeding of stray animals in Konya Industry area in Turkey. Five of them were brought to Selcuk University, Faculty of Veterinary Medicine, Pathology Laboratory for the investigation of the cause of deaths. After taking the relevant records, systemic necropsies were performed. Organ samples and gastro-intestinal contents were taken for histopathological and toxicological examinations.

For histopathological examination, tissue samples taken from gastrointestinal tracts, liver, kidney, lung, heart, and brain were fixed in 10% form-aldehyde solution for one day and then routine tissue follow-up procedures were performed. Five µm thick sections were obtained from the tissues embedded in paraffin blocks and stained with hematoxylin-eosin (HxE). Prepared slides were examined under light microscope (Olympus BX51, Tokyo, Japan). For toxicological analyses, stomach and intestinal contents, liver and kidney samples were examined by GC-MS device at Konya Veterinary Control Institute.

At necropsy, macroscopic findings were the same in all dogs. Grossly, serosanguinous fluids in the thorax and abdominal cavity, and undigested chicken meat and bone fragments *(Fig. 1A)* with a mild insecticidal smell in the stomachs were found. It was observed that the liver was pale yellow, swollen and easily fragilable. Semi-clotted blood in the left ventricle and endocardial hemorrhages were noted in the heart *(Fig.1B-C)*. There was edema in the lungs, and the kidneys were pale. In the brain meninges, mattening and hyperemia were determined. In addition, postmortal clotting deficiency of blood in the vessels were observed in two of the dogs.

In histopathological examination, severe and diffuse vacuolar degeneration of hepatocytes and congestion in the liver *(Fig. 2A-B)*, hyperemia and tubular degeneration in kidneys *(Fig. 2C)*, hyperemia, edema and perivascular hemorrhage in the brain *(Fig. 2D)*, epithelial necrosis in stomach *(Fig. 2E)* and congestion and alveolar edema in lung *(Fig. 2F)* were determined.

According to the toxicological analysis by GC-MS, methomyl was found as 15.7 to 17.8 ppm in stomach contents, 4.5 ppm in the intestinal contents, 2.25 to 2.90 ppm in livers and 1.2-1.5 ppm in kidneys of 5 dogs.

DISCUSSION

Intentional or accidental toxications are very important reasons in animal and human deaths. In a study, incidence of domestic carnivorous poisoning in Italy between 1996 and 2003 was 40% (260 cases) of all agricultural drug poisoning cases (650 cases) originating from insecticides in dogs and 32% of them were carbamate insecticides, and that the dogs were mostly affected by carbamates (39 cases), especially by methomyl [9]. In another retrospective study in Italy by Caloni et al.[11], it was reported that dogs accounted for 71.1% of all 304 cases of domestic animal poisonings between 2011 and 2013. In addition, insecticides (40.8%) are mostly important ones among

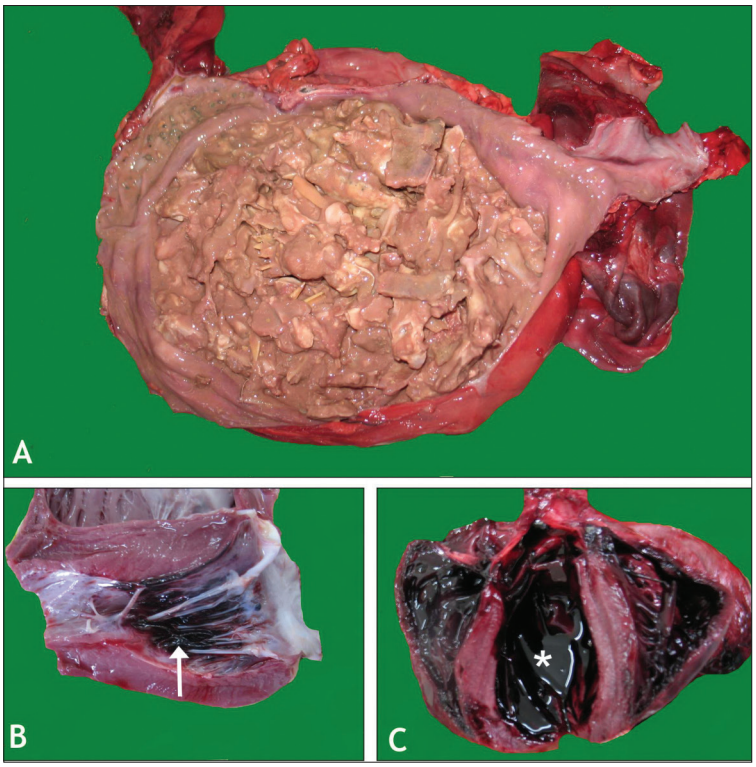

Fig 1. A) Undigested pieces of chicken in stomach, **B)** Endocardial haemorrhages *(arrow)*, **C)** Semi-clotted blood in ventricle *(asterisk)*

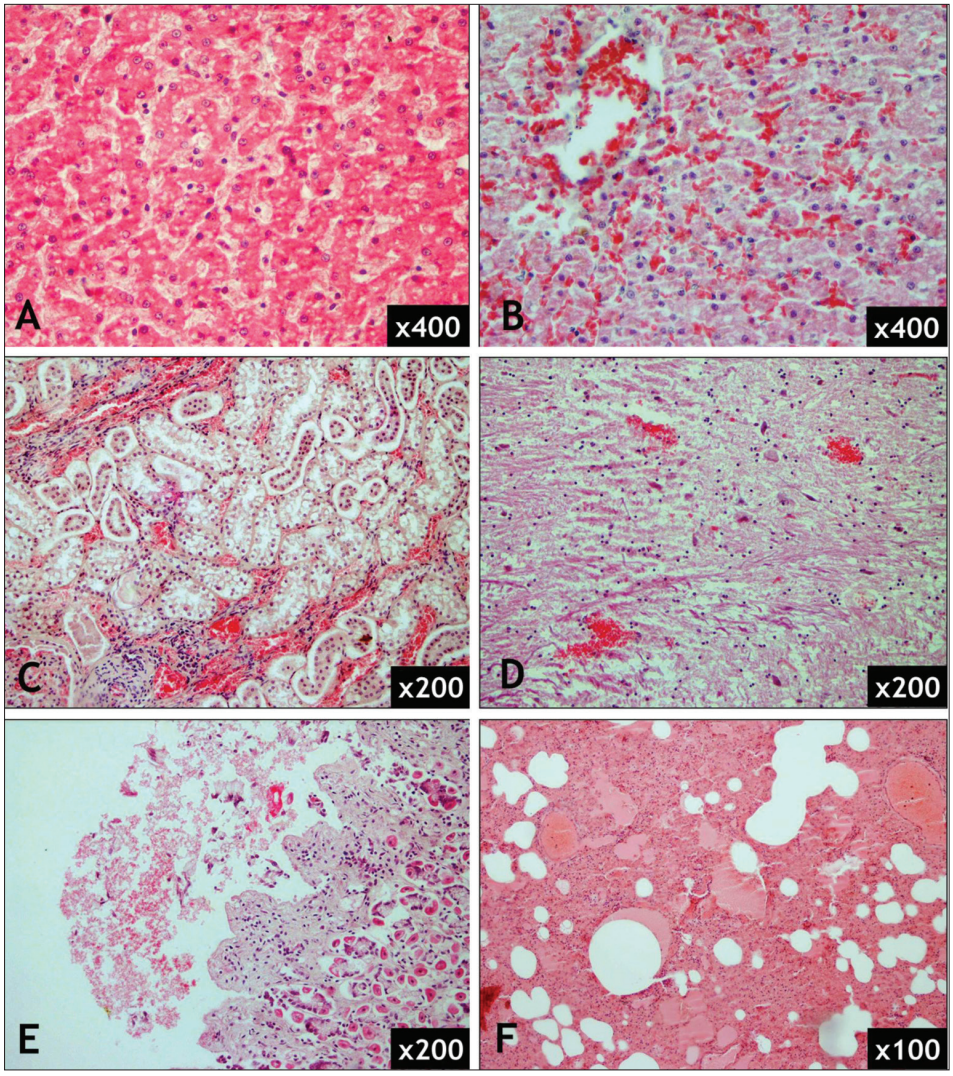

Fig 2. A-B) Vacuolar degeneration of hepatocytes and congestion in the liver, **C)** Hyperemia and tubular degeneration in kidneys, **D)** Perivascular hemorrhage in the brain, **E)** Epithelial necrosis in stomach, **F)** Hyperemia and alveolar edema in lung (H&E)

pesticide poisoning events and methomyl is the most common insecticide seen in both dog and cat poisoning cases. In another study conducted by Martinez-Haro et al.[12] in Spain, 260 cases of intentional or accidental poisoning were dealt with. According to this study, it was reported that most of the recorded animal poisonings in Spain originated from insecticides (66.1%) and that all methomyl poisoning cases were made intentionally.

In these studies where numerical data related to intoxication in domestic carnivores were given, it has been shown that dogs are more exposed to intoxication cases and methomyl has been highly effective on dogs. In addition, it was emphasized that methomyl has used intensively in intentional poisonings. In this case report by supporting data above, the presence of methomyl-induced toxicity in 30 dogs simultaneously and rapid deaths of them point out that the dogs are highly sensitive to methomyl. At the same time, deliberately administration of this poisoning by thieves, because they perceive street or guard dogs as threats, helps to explain why dogs are more likely to be exposed to such poisoning cases. In addition, it is thought that methomyl active substance preparations are used extensively in poisoning cases due to the fact that they are easily obtained without supervision in anywhere and that their effect is acute.

In an experimental study conducted by Radad et al.[13], rats were given methomyl (2 mg/kg) three times a week for three months and histopathologically liver, kidney, lung, testis, and spleen were significantly affected. In another study performed in rats, degenerative changes were observed in the brains of the methomyl-administered groups (10 mg/kg, 2 mg/kg) compared to the control groups [14]. In a study of dog poisoning cases in Macedonia in 2007-2017, it was reported that the most important necropsy findings in methomyl poisoning events were inflammatory changes in the gastrointestinal tract and histopathologically the most affected organs were the kidney, stomach, intestine, and lung [15].

There are very limited studies describing, macroscopic and microscopic findings related to the methomyl toxicity encountered in dogs. Most of the methomyl poisonings cases are to be toxicoepidemiological. Therefore, the pathological

data in our cases are important. Pulmonary edema and congestion detected macroscopically and microscopically are thought to be caused by increased permeability of the pulmonary capillary membranes with bradycardia as a result of inhibition of acetylcholinesterase enzyme by the methomyl. The presence of semi-clotted blood in the left ventricle of the heart suggests that methomyl may cause blood clotting disorder. In addition, it has been reported that hemorrhages of various tissues in carbamate insecticide poisonings may be the result of convulsions. In our cases, the occurrence of hemorrhages in the endocardium and especially in the brains may also be the result of damage to the vascular endothelium by methomyl as well as convulsions.

Vacuolar degeneration of hepatocytes in the liver and tubular degeneration in the kidney may be attributed to the toxic degenerative effect of methomyl on these organs. In addition, although excessive cholinergic stimulation in the parasympathetic nervous system causes hypermotility in the gastrointestinal tract, the presence of undigested food in the stomach may be the result of sudden death by the acute toxic effect of methomyl. When all these findings are evaluated, macroscopic and histopathological lesions for methomyl toxication are important and revealing the pathogenesis of death. In addition, generally the crime scene where intentional toxications were carried out is not extensively investigated on the spot and the chain of inquiry usually starts with the necropsy and the records taken. In the present case, because of the suspicion of poisoning thanks to the results of systemic necropsy of the dogs, toxicological samples were taken. Eventually, the damages caused by methomyl, which was also toxicologically determined, to the organs were shown histopathologically, too.

There is no the data on the amount of toxic methomyl present in the organs and gastrointestinal contents of dogs. Therefore, the amounts of methomyl detected in our case (15.7 to 17.8 ppm in stomach contents, 4.5 ppm in the intestinal contents, 2.25 to 2.90 ppm in livers and 1.2-1.5 ppm in kidneys) could not be compared with other fatal cases. However, these data can provide valuable research opportunities for the determination of methomyl fatal levels in dogs. It is also possible that the amount of methomyl given orally with food may be much higher at first.

In conclusion in this case, it was revealed that deaths were due to methomyl intoxication in the light of postmortem findings, histopathological investigations and toxicological results. In addition, according to the information received later from the police officers and the printed media, it was confirmed that these poisonings were intentionally carried out in this industrial area for theft.

In this study, the pathological and toxicological aspects of methomyl poisoning in dogs were investigated for the first time in Turkey. As with other toxicoepidemiological studies [9,11,12], it was found that especially stray dogs or security dogs are more exposed to intentional poisonings. Methomyl is preferred in intentional poisonings since it is cheap and can be easily supplied without any supervision in Turkey, and has a high and rapid fatal effect. The case findings may provide a wider knowledge of the causes and types of poisoning in animals, assist the veterinarians in making a diagnosis and help both the animal owners and the concerned persons from taking preventive measures. With this case presentation, it has been drawn attention to that more stronger legal regulations should be taken by governments in access and abuse of such toxic drugs and about animal rights.

REFERENCES

1. Van Scoy AR, Yue M, Deng X, Tjeerdema RS: Environmental fate and toxicology of methomyl. *Rev Environ Contam Toxicol,* 222, 93-109, 2013. DOI: 10.1007/978-1-4614-4717-7_3

2. Vale A, Lotti M: Organophosphorus and carbamate insecticide poisoning. **In,** Lotti M, Bleecker ML (Eds): Handbook of Clinical Neurologyed., 149-168, Elsevier, 2015. DOI: 10.1016/B978-0-444-62627-1.00010-X

3. Yurdakök-Dikmen B, Tekin K, Tırpan MB, Daşkın A, Filazi A: *In vitro* toxicity of some pesticides on goat and dog spermatozoa. *Kafkas Univ Vet Fak Derg,* 23 (2): 297-303, 2017. DOI: 10.9775/kvfd.2016.16501

4. Hamzah DJ, Abo-Ktifa MA, Rasheed SS, Faris BH: Toxopathological study of methamyl effect on the Rock Pigeons (Culumba Livia Gaddi). *Bas J Vet Res,* 14 (1): 124-134, 2015.

5. WHO: The WHO recommended classification of pesticides by hazard and guidelines to classification 2009. 2009. https://www.who.int/ipcs/publications/pesticides_hazard_2009.pdf; *Accessed:* 07.12.2018.

6. Caloni F, Cortinovis C, Rivolta M, Davanzo F: Animal poisoning in Italy: 10 years of epidemiological data from the Poison Control Centre of Milan. *Vet Rec,* 170 (16): 415, 2012. DOI: 10.1136/vr.100210

7. Kaplan AM, Sherman H: Toxicity studies with methyl N-[[(methylamino) carbonyl]oxy]-ethanimidothioate. *Toxicol Appl Pharmacol,* 40 (1): 1-17, 1977. DOI: 10.1016/0041-008X(77)90110-7

8. Hopper K, Aldrich J, Haskins SC: The recognition and treatment of the intermediate syndrome of organophosphate poisoning in a dog. *J Vet Emerg Crit Car,* 12 (2): 99-103, 2002. DOI: 10.1046/j.1435-6935.2002.00008.x

9. Albo AG, Nebbia C: Incidence of poisonings in domestic carnivores in Italy. *Vet Res Commun,* 28 (Suppl. 1): 83-88, 2004. DOI: 10.1023/b:verc.0000045383.84386.77

10. FAO/WHO: Pesticide residues in food report of the 2001 joint FAO/WHO meeting of experts.2001.http://www.fao.org/fileadmin/templates/agphome/documents/Pests_Pesticides/JMPR/Reports_1991-2006/REPORT2001.pdf; *Accessed:* 07.12.2018.

11. Caloni F, Cortinovis C, Rivolta M, Davanzo F: Suspected poisoning of domestic animals by pesticides. *Sci Total Environ,* 539, 331-336, 2016. DOI: 10.1016/j.scitotenv.2015.09.005

12. Martinez-Haro M, Mateo R, Guitart R, Soler-Rodriguez F, Perez-Lopez M, Maria-Mojica P, Garcia-Fernandez AJ: Relationship of the toxicity of pesticide formulations and their commercial restrictions with the frequency of animal poisonings. *Ecotoxicol Environ Saf,* 69 (3): 396-402, 2008. DOI: 10.1016/j.ecoenv.2007.05.006

13. Radad K, Hashim A, El-Sharqawy EEG, El-Din Youssef MS: Histopathological effects of methomyl on sprague-dawley rats after repeated application. *Bulg J Vet Med,* 12 (2): 149-157, 2009.

14. Radad K, Mostafa AH, Youssef MS: Neuropathologic effects of methomyl on sprague-dawley rats. *Assiut Vet Med J,* 55 (123): 180-190, 2009.

15. Gjurovski I, Dovenska M, Janevski A, Ristoski T: Poisoning of dogs in the Republic of Macedonia - Pathomorphological changes and the impact on animal welfare. *Mac Vet Rev,* 41 (2): 203-207, 2018. DOI: 10.2478/macvetrev-2018-0014