Kafkas Universitesi Veteriner Fakultesi Dergisi
ISSN: 1300-6045 e-ISSN: 1309-2251
Journal Home-Page: http://vetdergikafkas.org

Kafkas Univ Vet Fak Derg
27 (6): 699-706, 2021
DOI: 10.9775/kvfd.2021.26135

Research Article

Protective and Therapeutic Effect of Quercetin in Hepatotoxicity Induced by Sepsis in Rats

Mevlüt DOĞUKAN [1,a (*)] Murat BIÇAKCIOĞLU [2,b] Mehmet DURAN [1,c]
Zümrüt DOĞAN [3,d] Bilge AYDIN TÜRK [4,f] Öznur ULUDAĞ [1,e]

[1] Anesthesiology and Reanimation Department, Adiyaman University Faculty of Medicine, TR-02100 Adiyaman - TURKEY
[2] Anesthesiology and Reanimation Department, Balıkesir University Faculty of Medicine, TR-10010 Balıkesir - TURKEY
[3] Anatomy Department, Adiyaman University Faculty of Medicine, TR-02100 Adiyaman - TURKEY
[4] Pathology Department, Adiyaman University Faculty of Medicine, TR-02100 Adiyaman - TURKEY
ORCIDs: [a] 0000-0002-4890-758X; [b] 0000-0001-9101-6857; [c] 0000-0001-7568-3537; [d] 0000-0001-7131-2317; [e] 0000-0003-1592-1040
[f] 0000-0002-6017-5836

Article ID: KVFD-2021-26135 Received: 12.06.2021 Accepted: 10.11.2021 Published Online: 16.11.2021

Abstract

Septicemia caused by Gram-negative bacteria is an infection associated with liver dysfunction. Quercetin is a natural flavonoid found in vegetables and fruits and has anti-inflammatory, antioxidant, cytoprotective and antiallergic properties. This research aims to investigate the effects of quercetin on the liver against tissue damage due to sepsis-induced oxidative stress. Thirty-two male rats were used in the study. The animals were randomly divided into 5 groups. Quercetin was dissolved in 20 mg/kg of olive oil daily for 15 days and given through oral gavage. The cecal-ligation sepsis model was applied to the group 3 and group 4. In histopathological evaluation; inflammation involving moderate neutrophils and lymphocytes was observed in most portal areas in the group where sepsis was created (Group 3). In the sepsis group administered quercetin (Group 4) only a few portal areas had a milder inflammation with fewer neutrophils than the sepsis group. There was a significant difference between group 3, 4, and all other groups in ALT and AST values. A significant difference was observed between group 3, 4 and other groups in terms of tissue MDA, GSH levels. It was concluded that quercetin, a powerful antioxidant, can reduce liver damage caused by sepsis and has the potential to be used to help treat sepsis.

Keywords: *Quercetin, Sepsis, Hepatotoxicity, Rat*

Sıçanlarda Sepsisin Neden Olduğu Hepatotoksisitede Kuersetin'in Koruyucu ve Terapötik Etkisi

Öz

Gram negatif bakterilerin yol açtığı septisemi, karaciğer fonksiyon bozukluğu ile ilişkili bir enfeksiyondur. Kuersetin, sebzeler ve meyvelerde bulunan doğal bir flavonoid olup antienflamatuar, antioksidan, sitoprotektif ve antialerjik etkilidir. Bu araştırmanın amacı sepsis kaynaklı oksidatif stress sonucu olaşan doku hasarına karşı kuersetinin karaciğer üzerine etkilerini araştırmaktır. Çalışmada 32 erkek sıçan kullanıldı. Hayvanlar randomize olarak 5 gruba ayrıldı. Kursetin, 15 gün boyunca, günlük 20 mg/kg zeytinyağı içerisinde çözülerek oral gavaj ile verildi. Çekal ligasyonlu sepsis modeli grup 3 ve 4'e uygulandı. Histopatolojik değerlendirmede sepsis oluşturulan grupta (Grup 3) portal alanların çoğunda orta derecede nötrofilleri ve lenfositleri içeren inflamasyon izlendi. Kuarsetin uygulanan sepsis grubunda (Grup 4) sadece birkaç portal alanda sepsis grubuna göre daha az nötrofil içeren daha hafif bir inflamasyon mevcuttu. ALT ve AST değerlerinde grup 3, 4 ile diğer tüm gruplar arasında anlamlı farklılık vardı. Doku MDA, GSH Düzeyleri açısından grup 3, 4 ile diğer gruplar arasında anlamlı olarak farklılık gözlendi. Güçlü bir antioksidan olan kuersetinin sepsisin neden olduğu karaciğer hasarını azaltabileceği ve sepsis tedavisine yardımcı olarak kullanılma potansiyeline sahip olacağı sonucuna varıldı.

Anahtar sözcükler: *Kuersetin, Sepsis, Hepatotoksisite, Rat*

Introduction

Sepsis is a serious health problem that progresses with a deep systemic inflammatory response to infection and requires intensive care treatment [1]. Because of high mortality and morbidity rates, clinicians have difficulty in coping with patients with sepsis. Severe septic shock, tissue damage, multi-organ dysfunction, and death are common in sepsis [1,2].

How to cite this article?

Doğukan M, Bıçakçıoğlu M, Duran M, Doğan Z, Aydın Türk B, Uludağ Ö: Protective and therapeutic effect of quercetin in hepatotoxicity induced by sepsis in rats. *Kafkas Univ Vet Fak Derg,* 27 (6): 699-706, 2021.
DOI: 10.9775/kvfd.2021.26135

(*) Corresponding Author

Tel: +90 416 2231690 Cellular phone: +90 505 253 6441 Fax: +90 416 223 1693
E-mail: drmevlud@hotmail.com (M. Doğukan)

This article is licensed under a Creative Commons Attribution-NonCommercial 4.0 International License (CC BY-NC 4.0)

Septicemia caused by Gram-negative bacteria is a dangerous infection associated with the frequency of liver dysfunction. Severe and acute hepatotoxicity is probably due to the intense release of endotoxin into the systemic circulation after the death of bacteria. The direct toxic effect of endotoxin is probably due to the increased production of reactive oxygen intermediates such as oxygen-peroxides and nitric oxide [2,3]. Quercetin is a natural flavonoid found in vegetables and fruits. It is known to have anti-inflammatory, antioxidant, free radical scavenging, cytoprotective, and antiallergic action [4]. Liver damage caused by sepsis is a common pathology in the clinic and its treatment is of absolute importance to the physician and patient. Although Wichterman et al.[5] described the sepsis model with using cecal ligation in rats in 1980, it has also been applied to mice and sheep. It is frequently preferred because of creation a clinical picture similar to the sepsis model in humans. We also used this model in our study. For this reason, we aimed to use quercetin, which has a high antioxidant capacity, as a preservative and treatment against tissue damage due to oxidative stress caused by sepsis.

Material and Methods

Ethical Approval

The study protocol was approved by the Local Ethics Committee for Animal Experiments of Adiyaman University, Turkey (Approval no: ADYU-HADYEK: 2019-045)

Animal Sampling

In the study, thirty-two male Spraque Dawley rats, weighing about 280-300 g were used. The animals were randomly divided into 5 groups *(Table 1)*. Rats were housed in a room with a controlled heating (22±2°C) and lighting (12 h dark/light), and fed a diet of feed and water *ad libitum*.

The rats were randomly divided into five groups. The groups were as follows:

Group 1 (Control): Intragastric saline was administered in doses of 1.5 mL (n=6).

Group 2 (Sham Surgery): A surgical incision was made and 1.5 mL of olive oil was given in an intragastric way (since quercetin dissolves in oil, n=6).

Group 3 (Sepsis): The sepsis model was created using the cecal ligation and drilling method.

Group 4 (Sepsis and Quercetin): Quercetin was intragastrically administered at a dose of 20 mg/kg from 15 days before the surgical procedure until the end of the experiment and a sepsis model was created simultaneously with Group 3 (n=7).

Group 5 (Quercetin): Quercetin was intragastrically administered at a dose of 20 mg/kg from 15 days before the surgical procedure until the end of the experiment (n=5).

Table 1. *Blood Parameters of the study groups*

Parameters	Group (n)	Mean±SD	P
ALT (U/L)	Group 1 (6)	41.83±15.14	.001
	Group 2 (6)	42.83±11.44	
	Group 3 (7)	**149±97.82**	
	Group 4 (7)	**86.43±21.61**	
	Group 5 (5)	44±13.51	
AST (U/L)	Group 1 (6)	121.67±19.77	.001
	Group 2 (6)	170.33±27.95	
	Group 3 (7)	**740.43±299.51**	
	Group 4 (7)	**672.57±196.83**	
	Group 5 (5)	107±20.99	
LDH (U/L)	Group 1 (6)	712.67±100.28	.001
	Group 2 (6)	1525.5±495.39	
	Group 3 (7)	**1963.29±1203.18**	
	Group 4 (7)	**2243.29±424.01**	
	Group 5 (5)	768.6±197.35	
GGT (U/L)	Group 1 (6)	8.17±4.88	.38
	Group 2 (6)	6±1.1	
	Group 3 (7)	8.14±4.95	
	Group 4 (7)	5.14±1.21	
	Group 5 (5)	6.4±1.14	
CRP (mg/dL)	Group 1 (6)	0.15±0.07	.45
	Group 2 (6)	0.13±0.03	
	Group 3 (7)	0.15±0.06	
	Group 4 (7)	0.18±0.07	
	Group 5 (5)	0.13±0.03	

No statistically significantdifference between the Group 3 and Group 4 (P>0.05)

Quercetin Application: Quercetin (quercetin dihydrate, 97%, CAS: 6151-25-3; Alfa Aesar, Germany) was dissolved in 20 mg/kg of olive oil daily and given with oral gavage for 15 days [6].

The Cecal Ligation and Drilling Method: Ketamine HCl 70 mg/kg (Ketalar; Eczacıbaşı, İstanbul, Turkey) and xylazine HCl 20 mg/kg (Rompun 2%; Bayer Türk İlaç Ltd. Şti.) were intraperitoneally administered to all rats to be operated on the 16th day of the study under aseptic conditions under the supervision of a veterinarian. The cecum was exposed and connected distally through the ileocecal valve. It was drilled twice with an 18G needle from the antimesenteric edge. The skin, muscle, and peritoneum were closed by suture, the animal was given subcutaneous fluid supplements according to its weight [7]. One day after the sepsis procedure, 70 mg/kg of ketamine hydrochloride and 20 mg/kg of xylazine hydrochloride were administered to rats under aseptic conditions, and blood and tissue samples were taken. All animals were sacrificed under anesthesia at the end of the study.

Blood Analysis

Blood samples were drawn at the end of the procedure. They were transferred to EDTA tubes and centrifuged at 3000 rpm for 5 min. The plasma was then kept in the freezer (-20°C). Blood urea nitrogen (BUN), creatinine, alanine

aminotransferase (ALT), aspartate aminotransferase (AST), lactate dehydrogenase (LDH), and c-reactive protein (CRP) were analyzed [8].

Preparation of Tissue Homogenates

After the liver tissue was washed with physiological saline solution at +4°C, divided into small sections in accordance with cold chain principles, then put in Eppendorf tubes and stored at -80°C until assayed. Tissue homogenates for malondialdehyde (MDA) in tissue samples were prepared in a cold environment using a homogenizer in 0.15 M KCl (10%, w/v) [9].

Biochemical Evaluation

Analysis of malondialdehyde (MDA) level; Tissue MDA concentration as a lipid peroxidation marker was analyzed according to the thiobarbituric acid reaction (TBARS) method defined by Beuge and Aust [10]. Liver tissue was centrifuged after being homogenized in 10% trichloro-acetic acid. After mixing the superficial liquid part with 0.67% thiobutyric acid in equal volume, it was cooled and centrifuged after being incubated in boiling water for 15 min at 90°C. Tissue MDA concentrations were measured under 532 nm absorbance and expressed as nmol/g tissue.

Analysis of glutathione peroxidase (GSH) level; It was determined according to the method described by Ellman [11]. The glutathione in the analysis tube reacted with 5.5′-ditiyobis 2-nitrobenzoic acid and gave yellow-greenish color, and the light intensity of this color was measured in 410 nm wavelength by a spectro-photometer and the amount of reduced glutathione was determined.

Histopathological Procedure

The extracted liver tissue was fixed in 10% formaldehyde for histopathological examinations. The fixed tissues were subjected to a routine histological tissue follow-up procedure. The tissues followed up were turned into paraffin blocks. Sections with a thickness of 5 µm were taken from the blocks for histopathological examination. The resulting sections were stained with hematoxylane-Eozin (HE). The stained sections were histologically evaluated under an Olympus BX53 microscope (Olympus Corporation, 2014, Hamburg). The evaluation took into account necrosis in the liver, fibrosis, inflammatory cell infiltration in portal areas, dilatation in sinusoids, and congestion in vascular structures [12].

Statistical Analysis

Statistical analysis was performed with SPSS 15.0 for Windows (SPSS Inc.). The one-sample Kolmogorov-Smirnov test was used to determine whether the data were distributed normally. Groups were compared using the One-way ANOVA or the Kruskal Wallis H test whichever one is appropriate. As a result of these analyses, the groups which were found significant were compared using Tukey's multiple range test or pairwise Mann Whitney U test (Bonferroni correction was applied for which p-values <0.005 (i.e., and 0.05/10 comparisons)). The results were reported as mean±SD or median (min-max). A p-value <0.05 was considered statistically significant.

Results

ALT, AST, GGT, LDH, and CRP Values

While there was a significant difference between Group 3 and Group 4, and all other groups in ALT and AST values, there was no statistically significant difference between Group 3 and Group 4. While the increase in LDH values in Groups 2, 3, and 4 was statistically significantly different from other groups, there was no significant difference among these three groups. When GGT and CRP values were compared between the groups, no intergroup differences were observed. All blood values, intergroup comparison, and P values are presented in *Table 1*.

Fig 1. The graphic of MDA levels

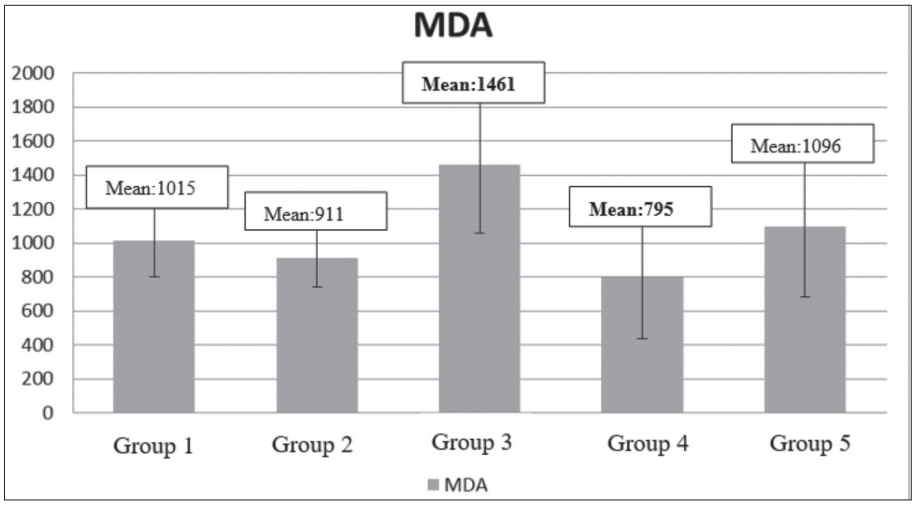

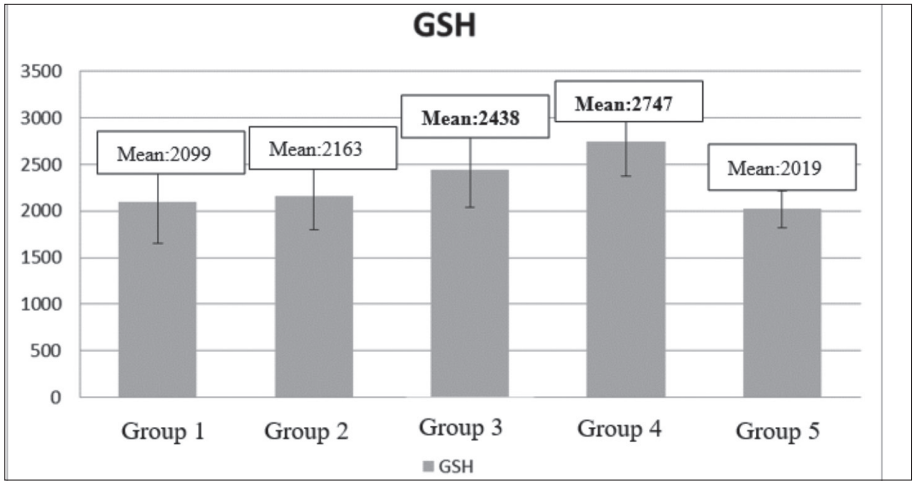

Fig 2. The graphic of GSH Levels

Fig 3. Sham group (Group 2) central veins are dilated, portal fields have normal appearance (HE X100)

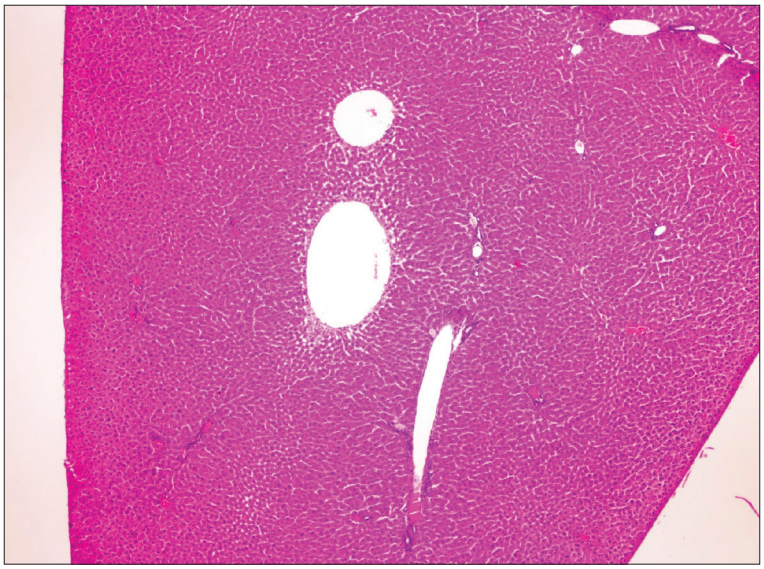

Tissue MDA and, GSH Levels

While the MDA values were not statistically significant among Group 1, 2, and 5, there was a significant difference between Group 3 and 4 and between the Group 3, 4, and other Groups (P=0.011) *(Fig. 1)*.

While GSH values were not statistically significant between the Group 1, 2, and 5, there was a significant difference between the Group 3 and 4 and between the Group 3, 4, and other Groups (P=0.012) *(Fig. 2)*.

Histopathological Findings

In terms of the histopathological findings, no structural changes, fibrosis or necrosis were observed in the liver in any of the groups. No abnormal histopathological changes were found in the Control (Group 1) and Sham (Group 2) groups *(Fig. 3)*. In the group where sepsis was created (Group 3), inflammation involving moderate neutrophils and lymphocytes was observed slightly in most of the portal areas *(Fig. 4)*. There was a slight expansion of sinusoids. Dilatation and congestion were observed in central veins, and slight expansion in some portal areas *(Fig. 5)*. In the sepsis group which was administered quercetin (Group 4); only a few portal areas had a milder inflammation with fewer neutrophils than that of in the sepsis group. Dilatation and congestion were observed in the central veins. There was a slight expansion of sinusoids *(Fig. 6)*. In the quercetin group, sinusoids had a pronounced dilated appearance. Milder lymphocytic infiltration was present in the portal areas and no neutrophils were observed. Dilatation was present in the veins in the portal areas *(Fig. 7)*.

Discussion

Sepsis is a disease with an uncontrolled inflammatory response. It rapidly progresses and has a high mortality rate [13]. More than 19 million people worldwide are affected by sepsis every year. Half of the patients who survive and are discharged after sepsis recover, one-third die within a year, and one-sixth have serious permanent damage [14]. The liver has a key role during sepsis. Bacterial clearanceis necessary for the regulation of immune defenses during

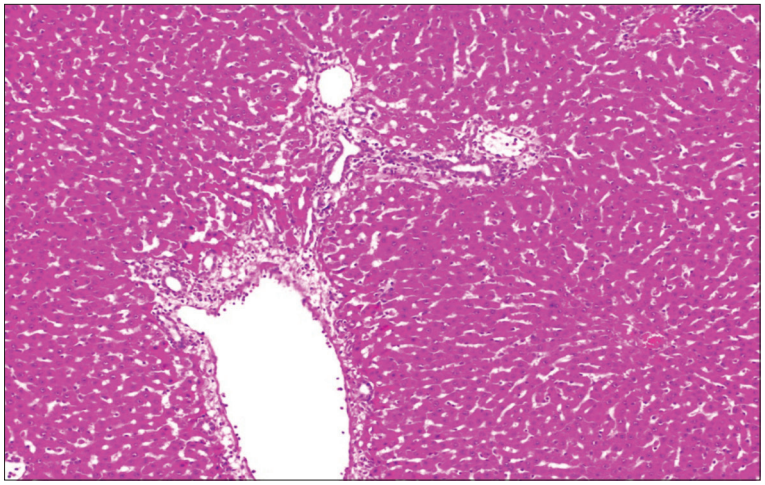

Fig 4. Chronic active inflammation and dilated vascular structure in the portal area of the sepsis group (Group 3) (HE X100)

Fig 5. Neutrophil presence in the portal area of the sepsis group (Group 3) (HE X200)

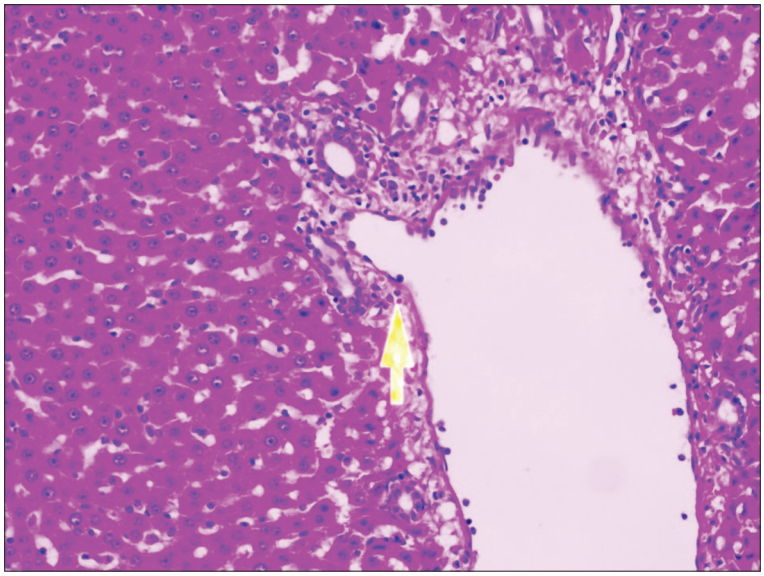

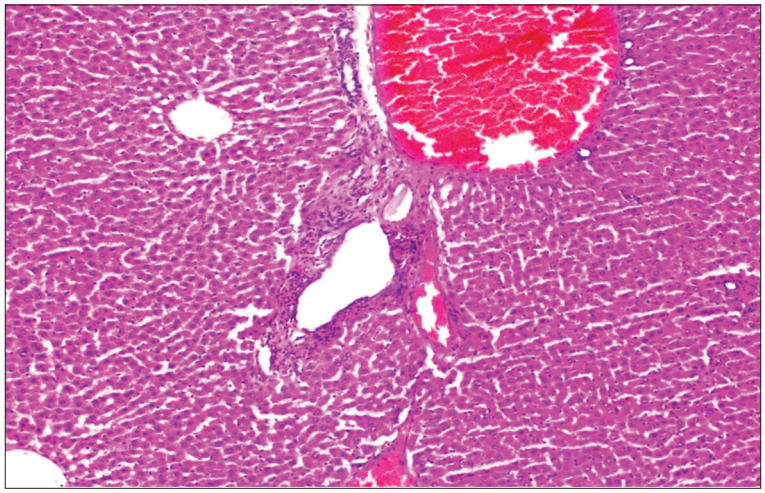

Fig 6. Mild inflammation and dilated congested vascular structure in the portal area of the quercetin-sepsis group (Group 4) (HE X100)

systemic infections through mechanisms such as the production of acute-phase protein/cytokines and metabolic adaptation to inflammation. The liver is also a target for sepsis-related damage in critical patients, including hypoxic hepatitis due to ischemia and shock, cholestasis due to altered bile metabolism, hepatocellular damage due to drug toxicity or excessive inflammation, as well as different pathologies such as secondary sclerosing cholangitis. Therefore, hepatic dysfunction can significantly adversely affect the prognosis of sepsis [15]. Treatments

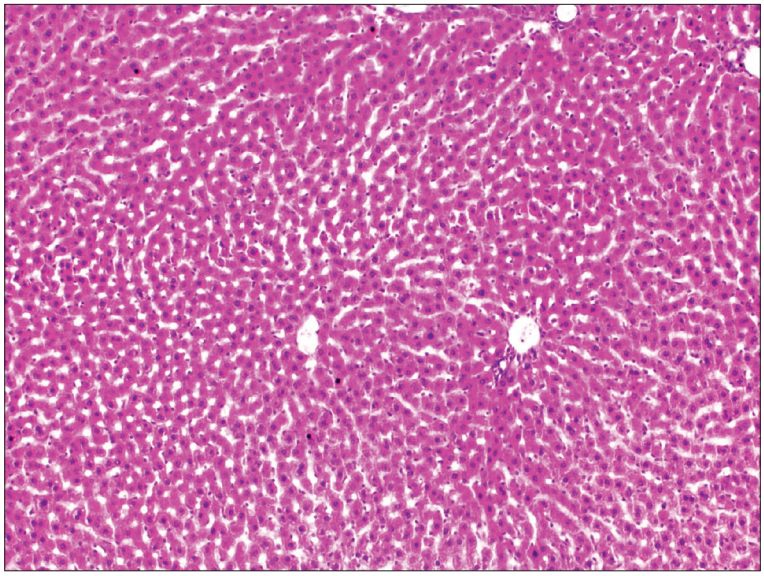

Fig 7. Normal liver structure in the quercetin group (Group 5), portal area and central vein (HE X 100)

for sepsis focus on macro circulatory failures, such as decreased artery mean pressure and heart rate. However, increasing evidence suggests that impaired oxygen consumption of the cell can play an important role in the pathogenesis of sepsis. Therefore, it has given rise to the idea that treatments aimed at providing redox hemostasis can be useful in the management of sepsis [16]. No study existing that shows the clear efficacy of Vitamin C, as an antioxidant especially in sepsis [17]. Quercetin is a flavonoid with strong antioxidant activity. It is abundant in fruits and vegetables such as cabbage, onions, red grapes, apples, and broccoli in nature, as well as tea and red wine. It has been shown to prevent various diseases such as osteoporosis, some cancers, and lung and cardiovascular diseases [18]. Quercetin has been shown to have protective effects against LPS-induced tissue damage and septic shock by improving inflammatory response in animal models [19].

In our study, we examined the effects of quercetin at a dose of 20 mg/kg for 15 days on liver damage caused by sepsis. A significant increase took place in ALT, AST, and LDH values of the sepsis-generated groups. Although these values were lower in the sepsis group (Group 4) administered quercetin, the difference was not statistically significant. ALT and AST values are commonly used to detect liver damage [20]. Wei et al.[21] found that ALT and AST values are significantly lower in the group administered quercetin in their study, in which they demonstrated the protective effect of quercetin against liver damage caused by triptolide. Ma et al.[22] showed that quercetin prevented liver damage caused by CCl_4. The study examined the efficacy of quercetin at a dose of 40 and 80 mg/kg/day through oral gavage. They recorded decreases in ALT and AST values in both doses, more pronounced at the dose of 80 mg/kg/day. Peng et al.[23] intraperitoneally administered quercetin at doses of 25 mg/kg/day, 50 mg/kg/day, and 100 mg/kg/day for 6 days against lipopolysaccharide/D-galactosamine induced liver damage and found that it was protective in a dose-dependent manner. In the study, they observed that ALT and AST values decreased as the dose of quercetin increased. In their study, Yousef et al.[24] reported that quercetin could improve this condition by lowering the increased ALT, AST, and LDH values in liver damage. Although we observed a decrease in ALT and AST values thanks to quercetin in our study, we did not find this decrease significant. This was either related to the number of subjects or the dose of quercetin we used.

We observed that histological changes were milder in the quercetin-sepsis group (Group 4) than in the sepsis group (Group 3). The heaviest histological changes were observed in the sepsis group (Group 3). In their study where experimental cirrhosis was created with carbon tetrachloride in rats, Pavanato et al.[25] found quercetin was effective against liver damage and said that it positively prevented histological changes. Wei et al.[21] reported liver damage and necrosis due to triptolide by quercetin. Kanter administered quercetin at a dose of 15mg/kg/day for 4 weeks to rats on which bile duct ligation was performed and reported the protective effect of quercetin against cholestatic liver damage [26]. Histologically, he followed up the bile duct proliferation and fibrosis, mononuclear cell infiltration, neutrophil infiltration, dilatation changes in portal areas and observed that quercetin reduced these histological changes, and associated this result with the potential antioxidant effect of quercetin.

In our study, we found tissue MDA values significantly higher in the sepsis group (Group 3) than in all other groups. The quercetin-administered sepsis group had the highest GSH values, which was statistically significant. On the other hand, this group (Group4) had the lowest MDA value. This suggested two outcomes. The first was oxidative damage caused by sepsis, and the second was that this oxidative damage was effectively prevented by quercetin. Quercetin also inhibits macrophage-induced early

and late proinflammational cytokines in infection and is predicted to play a role in the pathogenesis of sepsis of mitochondrial dysfunction through oxidative stress [19,27,28]. As reported by Chang et al.[19] quercetin significantly reduced the TNF-α and IL-1β levels in macrophages and inhibited the phosphorylations of KB kinase (IKKs), Akt and c-Jun N-terminal kinase (JNK) inhibitors, induced by LPS. Quercetin causes a significant reduction in the phosphorylation and degradation of the κBα (IκBα) inhibitor, as well as a significant reduction in the nuclear level of nuclear factor-B (NF-κB). However, these effects are observed in the acute application of quercetin, but not observed in the chronic application. Kukongviriyapan et al.[29] showed the beneficial effect of quercetin on the mitigation of oxidative stress and vascular dysfunction against endotoxin-induced shock in mice.

Although it seems possible that quercetin, a powerful antioxidant, can reduce liver damage caused by sepsis, it is obvious that it alone is not enough to treat sepsis. But it has the potential to be an adjuvant therapy for sepsis.

Availability of Data and Materials

The datasets during and/or analyzed during the current study available from the corresponding author on reasonable request.

Funding Support

There is no funding source.

Conflict of Interest

The authors report no conflicts of interest. The authors alone are responsible for the content and writing of paper.

Author Contributions

MD, MB and MD the present study, conducted this experiment, and wrote this manuscript. ZD and MB collected and analyzed data. ZD and ÖU made laboratory measurements. BAT applied the histopathological examination of the study. All authors contributed to the critical revision of the manuscript and have read and approved the final version.

References

1. Gerin F, Sener U, Erman H, Yilmaz A, Aydin B, Armutcu F, Gurel A: The effects of quercetin on acute lung injury and biomarkers of inflammation and oxidative stress in the rat model of sepsis. *Inflammation,* 39, 700-705, 2016. DOI: 10.1007/s10753-015-0296-9

2. Huang R, Zhong T, Wu H: Quercetin protects against lipopolysaccharide-induced acute lung injury in rats through suppression of inflammation and oxidative stress. *Arch Med Sci,* 11 (2): 427-432, 2015. DOI: 10.5114/aoms.2015.50975

3. Çenesiz S: The role of oxidant and antioxidant parameters in the infectious diseases: A systematic literature review. *Kafkas Univ Vet Fak Derg,* 26 (6): 849-858, 2020. DOI: 10.9775/kvfd.2020.24618

4. Xu D, Hu MJ, Wang YQ, Cui YL: Antioxidant activities of quercetin and its complexes for medicinal application. *Molecules*, 24 (6): 1123, 2019. DOI: 10.3390/molecules24061123

5. Wichterman KA, Baue AE, Chaudry IH: Sepsis and septic shock-a review of laboratory models and a proposal. *J Surg Res,* 29, 189-201, 1980. DOI: 10.1016/0022-4804(80)90037-2

6. Dogan Z, Cetin A, Elibol E, Vardi N, Turkoz Y: Effects of ciprofloxacin and quercetin on fetal brain development: A biochemical and histopathological study. *J Matern Fetal Neonatal Med,* 32, 1783-1791, 2019. DOI: 10.1080/14767058.2017.1418222

7. Uchiyama M, Mihara M: Determination of malonaldehyde precursor in tissue by thiobarbituric acid test. *Anal Biochem,* 86, 271-278, 1978. DOI: 10.1016/0003-2697(78)90342-1

8. Kumru S, Godekmerdan A, Kutlu S, Ozcan Z: Correlation of maternal serum high-sensitive C-reactive protein levels with biochemical and clinical parameters in preeclampsia. *Eur J Obstet Gynecol Reprod Biol,* 124 (2): 164-167, 2006. DOI: 10.1016/j.ejogrb.2005.05.007

9. Uraz S, Tahan V, Aygun C, Eren F, Unluguzel G, Yuksel M, Senturk O, Avsar E, Haklar G, Celikel C, Hulagu S, Tozun N: Role of ursodeoxycholic acid in prevention of methotrexate-induced liver toxicity. *Dig Dis Sci*, 53, 1071-1077, 2008. DOI: 10.1007/s10620-007-9949-3

10. Buege JA, Aust SD: Microsomal lipid peroxidation. *Methods Enzymol,* 52, 302-310, 1978. DOI: 10.1016/s0076-6879(78)52032-6

11. Elman GL: Tissue sulphydryl groups. *Arch Biochem Biophys,* 82 (1): 70-77, 1959. DOI: 10.1016/0003-9861(59)90090-6

12. Yener Z, Celik I, Ilhan F, Bal R: Effects of Urtica dioica L. seed on lipid peroxidation, antioxidants and liver pathology in aflatoxin-induced tissue injury in rats. *Food Chem Toxicol*, 47 (2): 418-424. 2009. DOI: 10.1016/j.fct.2008.11.031

13. Wang Z, Chen V, Li Y, Zhang S, Lou H, Lu X, Fan X: Reduning injection and its effective constituent luteoloside protect against sepsis partly via inhibition of HMGB1/TLR4/NF-κB/MAPKs signaling pathways. *J Ethnopharmacol,* 270, 113783, 2021. DOI: 10.1016/j.jep.2021.113783

14. Prescott HC, Angus DC: Enhancing recovery from sepsis: A review. *JAMA,* 319 (1): 62-75, 2018. DOI: 10.1001/jama.2017.17687

15. Strnad P, Tacke F, Koch A, Trautwein C: Liver-guardian, modifier and target of sepsis. *Nat Rev Gastroenterol Hepatol*, 14 (1): 55-66, 2017. DOI: 10.1038/nrgastro.2016.168

16. Mantzarlis K, Tsolaki V, Zakynthinos E: Role of oxidative stress and mitochondrial dysfunction in sepsis and potential therapies. *Oxid Med Cell Longev*, 2017, 5985209, 2017. DOI: 10.1155/2017/5985209

17. Kuhn SO, Meissner K, Mayes LM, Bartels K: Vitamin C in sepsis. *Curr Opin Anaesthesiol,* 31 (1): 55-60, 2018. DOI: 10.1097/ACO.0000000000000549

18. Marunaka Y, Marunaka R, Sun H, Yamamoto T, Kanamura N, Inui T, Taruno A: Actions of quercetin, a polyphenol, on blood pressure. *Molecules,* 22 (2): 209, 2017. DOI: 10.3390/molecules22020209

19. Chang YC, Tsai MH, Sheu WHH, Hsieh SC, Chiang AN: The therapeutic potential and mechanisms of action of quercetin in relation to lipopolysaccharide-induced sepsis in vitro and in vivo. *PLoS One*, 8 (11): e80744, 2013. DOI: 10.1371/journal.pone.0080744

20. Morovvati H, Armand N: Assessment of changes in serum concentrations of liver function (ALT, ALP, AST, LDH, GGT) after the intake of Narcissus Bulbs. *J Fasa Univ Med Sci*, 9, 1736-1742, 2019.

21. Wei CB, Tao K, Jiang R, Zhou LD, Zang OH, Yuan CS: Quercetin protects mouse liver against triptolide-induced hepatic injury by restoring Th17/Treg balance through Tim-3 and TLR4-MyD88-NF-κB pathway. *Int Immunopharmacol,* 53, 73-82, 2017. DOI: 10.1016/j.intimp.2017.09.026

22. Ma JQ, Li Z, Xie WR, Liu CM, Liu SS: Quercetin protects mouse liver against CCl_4-induced inflammation by the TLR2/4 and MAPK/NF-κB pathway. *Int Immunopharmacol*, 28 (1): 531-539, 2015. DOI: 10.1016/j.intimp.2015.06.036

23. Peng Z, Gong X, Yang Y, Huang L, Zhang Q, Zhang P, Wan R, Zhang B: Hepatoprotective effect of quercetin against LPS/D-GalN induced acute liver injury in mice by inhibiting the IKK/NF-κB and MAPK signal

pathways. *Int Immunopharmacol*, 52, 281-289, 2017. DOI: 10.1016/j.intimp.2017.09.022

24. Yousef MI, Omar SAM, El-Guendi MI, Abdelmegid LA: Potential protective effects of quercetin and curcumin on paracetamol-induced histological changes, oxidative stress, impaired liver and kidney functions and haematotoxicity in rat. *Food Chem Toxicol*, 48 (11): 3246-3261, 2010. DOI: 10.1016/j.fct.2010.08.034

25. Pavanato A, Tuñón MJ, Sánchez-Campos S, Marroni CA, Llesuy S, González-Gallego J, Marroni N: Effects of quercetin on liver damage in rats with carbon tetrachloride-induced cirrhosis. *Dig Dis Sci*, 48, 824-829, 2003. DOI: 10.1023/a:1022869716643

26. Kanter M: Protective effect of quercetin on liver damage induced by biliary obstruction in rats. *J Mol Histol,* 41 (6): 395-402, 2010. DOI: 10.1007/s10735-010-9301-7

27. Prauchner CA: Oxidative stress in sepsis: Pathophysiological implications justifying antioxidant co-therapy. *Burns*, 43 (3): 471-485, 2017. DOI: 10.1016/j.burns.2016.09.023

28. Nagar H, Piao S, Kim CS: Role of mitochondrial oxidative stress in sepsis. *Acute Crit Care,* 33 (2): 65-72, 2018. DOI: 10.4266/acc.2018.00157

29. Kukongviriyapan U, Sompamit K, Pannangpetch P, Kukongviriyapan V, Donpunha W: Preventive and therapeutic effects of quercetin on lipopolysaccharide-induced oxidative stress and vascular dysfunction in mice. *Can J Physiol Pharmacol*, 90 (10): 1345-1353, 2012. DOI: 10.1139/y2012-101