Journal of Istanbul University Faculty of Dentistry
Volume: 48, Number: 3 Pages: 37-51, 2014

ORIGINAL RESEARCH

KI-67 AND CYCLOOXYGENASE-2 EXPRESSIONS IN ODONTOGENIC KERATOCYSTS, DENTAL FOLLICLE AND AMELOBLASTOMA-AN IMMUNOHISTOCHEMICAL STUDY

Odontojen Keratokistler, Dental Foliküller ve Ameloblastomalarda Cyclooxygenase-2 ve Ki67'nin İmmunohistokimyasal Yöntemle Araştırılması

Çiğdem ÖZÇAMUR-GÜNEŞ[1], Vakur OLGAÇ[2], Merva SOLUK-TEKKEŞİN[2], Banu GÜRKAN KÖSEOĞLU[3]

Received: 13/05/2014
Accepted:01/08/2014

ABSTRACT

Purpose: Ki-67 and COX-2 are two markers which are commonly used to assess tumor proliferation. The aims of this study were to evaluate and compare the presence of Ki-67 and COX-2 in odontogenic keratocyst (OKC), radicular cyst (RC), ameloblastoma (AML) and dental follicle (DF) in order to determine proliferative potentials of such lesions.

Materials and Methods: This study has been conducted on 80 samples obtained from non-smoking, healthy subjects diagnosed as having either OKC, RC, AML or DF. 20 samples obtained from healthy mucosa served as controls. Slides prepared from paraffin-embedded sections were immunohistochemically stained for Ki-67 and COX-2 expressions.

Results: Ki-67 and COX-2 expressions in the OKC and AML groups were found to be significantly higher than those observed in the RC, DF and healthy mucosa groups ($p < 0.005$ for each).

Conclusion: High levels of Ki-67 and COX-2 staining in OKC and AML can be considered as the indicators of high proliferation tendency and mitotic activity. These markers could provide valuable tools for the treatment process when they are available for widespread use to detect cases that have significant relapse potential and aggressive behavior.

Keywords: *Odontogenic cysts, ameloblastoma, dental follicle, Ki-67, COX-2*

ÖZ

Amaç: Ki-67 ve COX-2, tümör proliferasyonunu değerlendirmek için yaygın olarak kullanılan iki belirteçtir. Bu çalışmanın amacı radiküler kist, keratokist, ameloblastoma ve tam gömük yirmi yaş dişlerinin dental folikülündeki Ki-67 ve COX-2 expresyonlarını değerlendirmek ve sağlıklı dokularla karşılaştırmaktır.

Gereç ve Yöntem: Bu çalışma sistemik hastalığı bulunmayan, sigara ve ilaç kullanmayan 80 hastadan elde edilen odontojenik keratokist, ameloblastoma, radikuler kist ve dental folikul örnekleri üzerinde yapılmıştır. Sağlıklı mukozalardan alınan 20 adet örnek kontrol grubu olarak değerlendirilmiştir. Hazırlanan kesitlerde Ki-67 ve COX-2 expresyonu immunohistokimyasal yöntemlerle boyanarak araştırılmıştır.

Bulgular: Odontojenik keratokist ve ameloblastoma gruplarındaki Ki-67 ve COX-2 ekspresyonları radiküler kist, dental folikül ve sağlıklı mukoza gruplarına göre anlamlı derecede yüksek bulunmuştur (her biri için $p < 0.005$).

Sonuç: Keratokist ve ameloblastomada yüksek bulunan Ki-67 ve COX-2 değerleri bu lezyonların proliferasyon eğilimlerinin ve belirgin mitotik aktivitelerinin göstergesi olarak kabul edilebilirler. Bu belirteçler, yüksek nüks eğilimi olan ve agresif özellik gösterebilecek olguların saptanmasında yaygın olarak kullanıldığında tedavi sürecine belirgin katkıları olacaktır.

Anahtar kelimeler: *Odontojenik kistler, ameloblastoma, dental folikül, Ki-67, COX-2*

[1] Dentist
[2] Department of Tumor Pathology Institute of Oncology Istanbul University
[3] Department of Oral and Maxillofacial Surgery Faculty of Dentistry Istanbul University

Introduction

The cysts of the maxilla, mandible and peri-oral tissues differ significantly in terms of incidence, clinical behavior, histological architecture as well as treatment concepts (1). Cysts arising from the remnants of the odontogenic epithelium are classified as "odontogenic", whereas those stemming from the epithelial rests of the embryologic fusion process are termed "non-odontogenic" (2). Although being classified as an odontogenic cyst, odontogenic keratocyst (OKC) has distinctive features from other members of this sub-group, such as demonstrating aggressive clinical characteristics, high recurrence rates and particularly, the presence of parakeratotic type OKCs in Nevoid Basal Cell Carcinoma Syndrome (NBCCS) which is also known as Gorlin-Goltz syndrome (3). Accordingly, OKC has been extensively studied in the past but controversial issues still exist. In 2005, Head and Neck Study group of World Health Organization has reclassified this lesion as an odontogenic tumor and has suggested the name "Keratocystic Odontogenic Tumor" (3, 4). However, many oral pathologists do not agree with this term and no international consensus could be reached. On the other hand a member of odontogenic cyst group, the radicular cyst (RC), which is often described as periapical or apical periodontal cyst, is the most common cystic lesion found in the jaw bones since it represents more than 75% of all cases. 7% to 54% of the periapical radiolucent lesions are diagnosed as radicular cysts (2). Inflammatory reaction in the apical region usually triggers the formation of apical granuloma. Inflammatory cell products stimulates Malassez epithelial remnants and this epithelial proliferation results in cyst formation. Ameloblastoma (AML) is the most common epithelial odontogenic tumor that bears significant clinical importance. This lesion may arise from the remnants of dental lamina and enamel organ, cells of the basal layer of oral mucosa and the odontogenic cyst epithelium (5). Dental follicle (DF) also contains epithelial structures which are potential sources for cysts of odontogenic origin as well as benign or malignant odontogenic tumors. Odontogenic epithelial structures usually give rise to dentigerous cysts. OKC, AML, chronic non-specific inflammatory lesions and epidermoid carcinoma are pathological lesions which may also be related to the DF (3-10).

Since Ki-67 expression can be detected in all proliferating cells, these molecules are often used in research studies that investigate the growth characteristics of different cell types (7). Ki-67 antigen has been found in breast, prostate and lung cancer lesions as well as in lymphoma and it was suggested as an independent prognostic marker of tumor proliferation (11-19). Recent epidemiological studies have shown low incidence of gastrointestinal cancers in patients with rheumatoid arthritis who routinely use non-steroidal anti-inflammatory drugs (NSAID) (20-23). NSAID are potential inhibitors of cyclooxygenase (COX) enzyme by blocking prostaglandin synthesis. These findings provided background for further research that focus on the possible relation of COX enzyme with cancer development and COX-2 enzyme, which appears as a result of COX isoform stimulation, has attracted attention as an area of potential research. A number of studies have detected significant increase in COX-2 expression particularly in colorectal cancer, as well as stomach, esophagus, breast, prostate and head and neck carcinomas (24-34).

The purposes of this study are to correlate local aggressive behaviors of OKC,

RC, AML and DR with Ki-67 and COX-2 expressions, to determine proliferation potentials of these lesions and to evaluate the efficiency of the proliferation markers in detecting possible malignant tendencies.

Materials and Methods

Population characteristics

80 (40 males and 40 females, age range: 17 to 60 years) non-smoking subjects with no history of previous medication in the last two months including antibiotics and/or NSAIDs were enrolled in this study. Their medical histories were non-contributory. Clinical and radiological examinations of the participants revealed either fully impacted third molar teeth, radiolucent or radiopaque lesions in the maxilla or mandible. Informed consent forms were signed by all patients prior to surgery and ethical approval was obtained from the local board. All patients were operated under local anesthesia. Following standard surgical preparation, appropriate incision techniques were selected depending on the size and location of the lesions, which were later enucleated according to routine surgical guidelines. All operating sites were closed with primary sutures and these were removed seven days later. Healing was uneventful in all patients. All specimens were processed for histological observation and were diagnosed either as OKC, RC, AML or DF. The study groups consisted of 20 patients in each of OKC, RC, AML and DF from fully impacted third molar teeth groups. The control group included 20 samples which were harvested from healthy mucosa.

Immunohistochemical Staining

Five micrometer sections were deparaffinized and rehydrated through graded alcohol series. Slides were immersed in citrate buffer solution (Citrate Buffer, Thermo Scientific®, United States) and placed in a commercial microwave oven for antigen retrieval for 20 minutes. Specimens were left for cooling in room temperature and then washed with phosphate buffered saline solution for five minutes. Endogen peroxidase activity was blocked by incubating with 3% hydrogen peroxide. Slides were washed with distilled water and placed in phosphate buffered saline solution for five minutes. To prevent non-specific staining, slides were treated with blockage solution for 15 minutes (Super Block, Scytek Laboratories®, United States). 6 ml primary antibodies of Ki-67 (PRM325AA, BioCare®, United States) and COX-2 (PRM306AA, BioCare®, United States) were applied to the specimens which were later incubated for 60 minutes. After washing with distilled water and phosphate buffered solution for five minutes, the specimens were incubated with linking reagent for 25 minutes (Anti-Polyvalent Biotinylated Antibody, Scytek Laboratories®, United States). Staining was visualized by AEC chromogen (AEC chromogen/substrate kit, Scytek Laboratories®, United States) and sections were counter-stained using Mayer Hematoxylin.

Light microscopy evaluation

Red granular shaped staining in the cytoplasm was considered positive. Positive and negative staining cells were counted at X 400 magnification by including all the epithelial layers. All data were collected using AnalySIS FIVE® digital imaging software (Olympus Soft Imaging Solutions GmBH, Münster, Germany). A total of 500 cells were counted in each slide by adding the number of the positive and negative stained cells together in five consecutive regions. All data were converted and expressed as percentage (%) of staining.

Statistical analysis

All statistical analysis was performed using SPSS® software version 19.0 (Statistical Package for Social Sciences, IBM Corp., Armonk, USA). The data was first evaluated using descriptive analysis such as mean, standard deviation and median. Column graphs were employed to represent the average effects of the groups. Kruskal–Wallis one-way analysis of variance by ranks test was used to compare the medians of the OKC, AML, RC, DF and healthy mucosa. The results were evaluated in a confidence interval of 95 % and p values (p1) less than 0.05 were considered as statistically significant. When such difference was detected, Mann-Whitney U test with Bonferroni correction was applied to compare sub-groups separately. Since there were five groups and ten possible pairwise comparisons; the new level of significance was calculated as 0. 05/10=0.005 (p2).

Results

This study has been conducted on 100 samples obtained from 80 patients who had been diagnosed as having DF, RC, OKC, AML and healthy mucosa samples. Age and Gender distributions of the study participants are presented in Table 1.

Table 1. Age and gender distributions of the participants in the study groups.

Group (n=20)	Gender	Mean age	Minimum age	Maximum age
Radicular cyst	8♂,12♀	29,5	15	51
Odontogenic Keratocyst	9♂,11♀	46,5	22	59
Ameloblastoma	9♂,11♀	31,2	16	60
Dental Follicle	13♂,7♀	26,5	16	58

Although no statistical difference was observed for Ki-67 staining between cells of the OKC and AML groups (p=0. 043), Ki-67 expression in OKC was found to be significantly higher than RC (p=0. 001), DF (p=0. 000) and healthy mucosa groups (p=0. 000). Similarly, the number of cells positively stained for Ki-67 in AML group was significantly higher than the RC (p=0. 011), DF (p=0. 000) and healthy mucosa groups (p=0. 000) (Figure 1). Epithelium of the RC group stained significantly higher than the DF group but no difference was observed between RC and healthy mucosa groups (p=0. 000) (Table 2, Table 3).

Figure 1-a

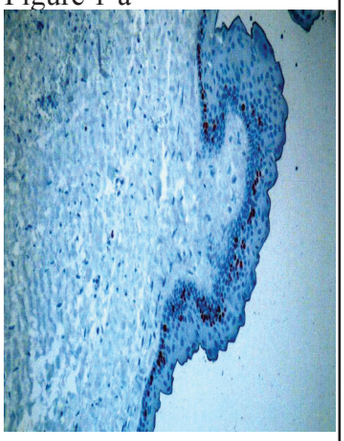

Figure 1-b

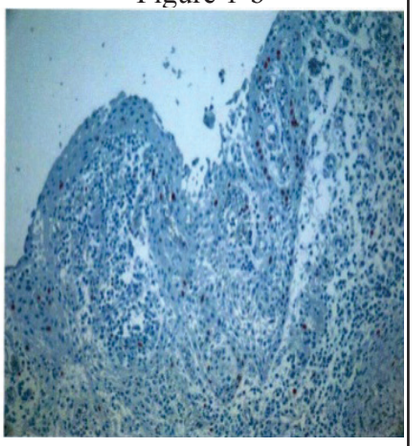

Figure 1-c

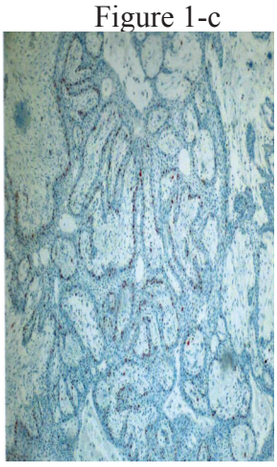

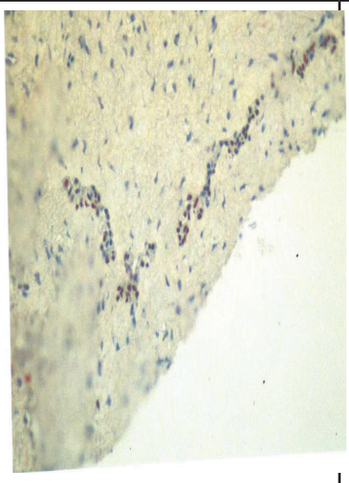

Figure 1-d

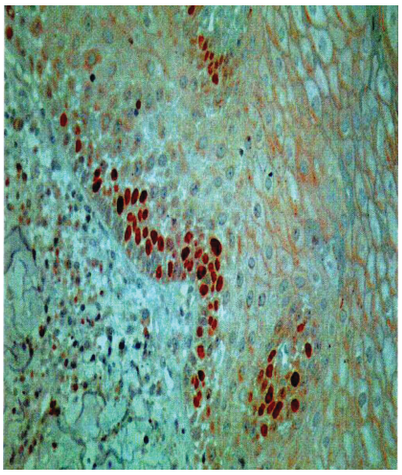

Figure 1-e

Figure1:

1-a: Ki67 positive cells in the basal layer of OKC (Ki67x200).

1-b: : Small number of Ki67 cells in the lining epithelium of the RC (Ki67x200)

1-c: Ki67 positive ameloblast-like cells in the plexiform type AML. (Ki67x200)

1-d: Ki67 positive cells in the primitive epithelium of the DF.(Ki67x400)

1-e: Ki67 positive cells in the basal layer of the samples taken from healthy mucosa (Ki67x400)

Figure 1. Ki67 expression.

Table 2. The results of Ki-67 staining.

#	OKC	Ameloblastoma	Radicular cyst	Dental follicle	Healthy mucosa
1	5.00%	1.00%	1.00%	0.20%	0.50%
2	3.00%	2.00%	0.00%	0.40%	0.20%
3	2.00%	1.00%	1.00%	0.30%	1.50%
4	6.30%	1.50%	1.50%	0.10%	0.50%
5	1.00%	2.00%	0.00%	0.20%	0.50%
6	5.00%	1.00%	0.50%	0.20%	1.50%
7	6.00%	2.00%	1.50%	0.30%	0.30%
8	1.50%	2.00%	1.50%	0.10%	0.50%
9	4.50%	1.50%	0.00%	0.30%	1.00%
10	3.50%	2.00%	3.00%	0.20%	0.50%
11	1.00%	1.50%	1.00%	0.50%	0.50%
12	2.00%	2.00%	1.50%	0.20%	0.20%
13	3.00%	2.00%	2.00%	0.20%	1.50%
14	2.00%	1.50%	0.00%	0.20%	0.50%
15	0.00%	2.00%	0.50%	0.20%	0.50%
16	5.00%	1.50%	1.00%	0.30%	1.50%
17	1.00%	0.50%	1.50%	0.30%	0.30%
18	1.00%	2.00%	2.00%	0.40%	0.50%
19	2.50%	1.50%	0.00%	0.30%	1.00%
20	1.50%	1.00%	1.00%	0.40%	0.50%
Mean	2.84%	1.58 %	1.03%	0.27%	0.70%
St. deviation	1.87%	0.47%	0.82%	0.10%	0.47%
Median	1.87%	1.50%	1.00%	0.25%	0.50%

Table 3. Pairwise comparisons for Ki-67 staining.

Number	Compared groups	P-values
1	OKC - Ameloblastoma	0.043
2	OKC - Radicular cyst	*0.001
3	OKC - Dental follicle	*0.000
4	OKC - Healthy mucosa	*0.000
5	Ameloblastoma - Radicular cyst	0.011
6	Ameloblastoma - Dental follicle	*0.000
7	Ameloblastoma - Healthy mucosa	*0.000
8	Radicular cyst - Dental follicle	0.007
9	Radicular cyst - Healthy mucosa	0.350
10	Dental follicle - Healthy mucosa	*0.000

** Difference is significant at p_1 and p_2 levels.*

There were no significant differences in the number of positively stained cells for COX-2 between the OKC and AML groups (p=0. 231). However, significantly higher number of COX-2 positive cells in OKC group were observed when compared to RC (p=0. 000), DF (p=0. 000) and healthy mucosa specimens (p=0. 000). Cells from AML group showed higher expression of COX-2 since the number of COX-2 positive cells were higher than those of the RC (p=0. 000), DF (p=0. 000) and healthy mucosa groups (p=0. 000) (Figure 2). The differences in COX-2 staining between RC, DF and healthy mucosa were not significant (Table 4, Table 5).

Table 4. COX-2 data sheet.

Number	OKC	Ameloblastoma	Radicular cyst	Dental follicle	Healthy mucosa
1	59.80%	60.95%	50.46%	52.66%	52.32%
2	48.00%	45.54%	42.04%	55.55%	54.82%
3	62.50%	52.80%	41.67%	44.73%	41.17%
4	65.50%	52.30%	47.72%	40.00%	37.01%
5	61.08%	64.22%	44.44%	49.43%	38.96%
6	61.59%	54.23%	40.57%	49.06%	37.76%
7	61.33%	57.08%	43.97%	46.37%	38.16%
8	52.06%	45.69%	42.50%	41.33%	57.72%
9	51.61%	47.95%	44.44%	57.40%	34.32%
10	60.61%	55.55%	41.10%	57.30%	38.37%
11	56.10%	52.41%	47.06%	31.51%	32.78%
12	58.18%	58.94%	50.00%	38.67%	52.38%
13	54.70%	53.68%	38.98%	38.93%	34.48%
14	58.42%	56.19%	41.77%	38.38%	38.86%
15	44.81%	48.58%	41.67%	43.17%	42.53%
16	50.89%	46.99%	47.45%	38.41%	42.23%
17	50.38%	51.25%	40.22%	38.53%	40.18%
18	53.75%	60.19%	46.21%	36.75%	48.91%
19	53.69%	45.54%	40.00%	36.47%	46.34%
20	45.13%	53.22%	40.85%	41.63%	40.93%
Mean	55.51%	53.17%	43.66%	43.81%	42.51%
St. Deviation	5.94%	5.43%	3.43%	7.49%	7.19%
Median	55.40%	53.01%	42.27%	41.48%	40.56%

Table 5. Pairwise comparisons for COX-2 staining.

Number	Compared groups	p-values
1	OKC - Ameloblastoma	0.231
2	OKC - Radicular cyst	*0.000
3	OKC - Dental follicle	*0.000
4	OKC - Healthy mucosa	*0.000
5	Ameloblastoma - Radicular cyst	0.000
6	Ameloblastoma - Dental follicle	*0.000
7	Ameloblastoma - Healthy mucosa	*0.000
8	Radicular cyst - Dental follicle	0.414
9	Radicular cyst - Healthy mucosa	0.157
10	Dental follicle - Healthy mucosa	0.512

** Difference is significant at p_1 and p_2 levels.*

Figure 2-a	Figure 2-b	Figure 2-c
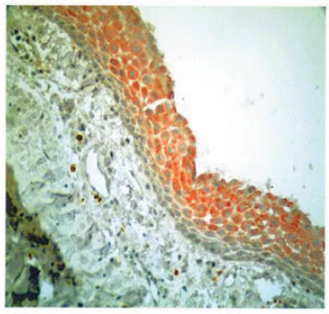	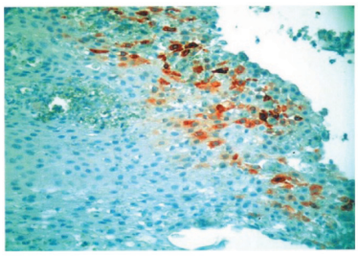	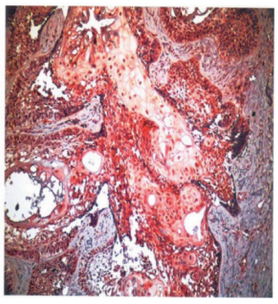
Figure 2-d	Figure 2-e	Figure 2-a: Widely distributed, diffuse COX-2 positive cells in the epithelium of parakeratotic odontogenic cyst (COX-2x400). 2-b: Dispersed epithelial cells showing strong staining for COX-2 in a sample taken from a RC (COX-2x400). 2-c: Extensive COX-2 expression in a AML sample presenting signs of acanthomatous metaplasia (COX-2x200). 2-d: Primitive odontogenic epithelium cells that were stained positive for COX-2 in a DF sample (COX-2x400). 2-e: Homogenous distribution of COX-2 positive cells in healthy mucosal samples (COX-2x400).
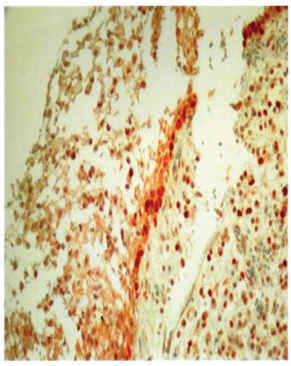	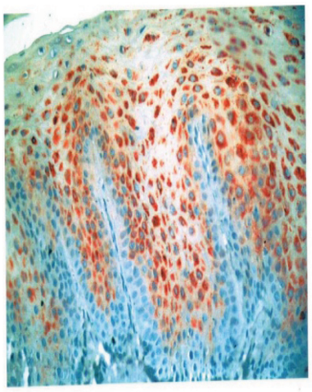	

Figure 2. COX-2 expressions.

Discussion

The removal of impacted third molars is one of the most frequently performed procedures in the field of oral and maxillofacial surgery. The components of the follicle surrounding the impacted teeth represent the characteristics of stem cells and have been examined by many authors. Previous studies which were limited to the microscopic investigation are now being transferred to the level of genetic research, as a result of technological advancement. Clinical research projects that focus on the neoplastic changes stemming from follicular cells have become an area of specific interest, gradually replacing inconclusive case reports such as infection, cyst and carcinomas arising from these tissues.

Yıldırım et al. (35), who had examined histological changes in the dental follicles surrounding 120 impacted third molar teeth extracted from 115 patients, reported that 23 % of the specimens showed significant changes in the cellular content. Of these specimens, 14.1 % were classified as dentigerous cyst, 6.9 % as calcifying odontogenic cyst and 2.5 % as OKC. Their findings did not reveal any significant relation between gender and histological diagnosis. On the other hand, authors indicated that the impacted teeth in mesioangular and vertical positions are more likely to be related with follicular pathologies. Koçak et al. (36) have found a fibromyxoma, an OKC, two radicular cysts and 46 partial follicular cyst in a series of 50 cases. Rakprasitkul (37) investigated the pericoronal tissues obtained from 68 mandibular and 36 maxillary impacted teeth in patients whose ages ranged from 13 to 63. 41.35 % of the lesions have been classified as normal-healthy DF, whereas 58.65 % have been described as DF with pathological changes. Curran et al. (38), who had followed up 2146 cases with DF for six years, have found pathological changes in 28.4 %. Although the dentigerous cyst has been reported as the most frequent diagnosis, they have also found evidence of carcinoma in 0.23 % of the lesions. Mesgarzadeh et al. (39) examined 185 DF with no evidence of radiological pathology in 170 patients. 38 % of the patients were later found to have dentigerous cyst and 5.8 % to have AML. 4 % of the remaining lesions were classified as sulfur granules, 3 % as foreign body granulation tissue and hyperplastic non-keratinized squamous epithelium. The authors suggested higher incidence of DF in patients between second and third decades. In addition, the number of males with DF pathology was reported to be higher and the lesions were more frequent in the mandible.

Edamatsu et al. (40) investigated immunohistochemical expression of blc-2 and single stranded DNA (ssDNA) in pericoronal tissues; 80 DF and 27 dentigerous cysts and later cross-checked their findings with Ki-67 immunoreactivity. The percentage of ssDNA and Ki-67 positive cells were found to be higher in DF with inflammatory changes when compared to DF without inflammation. Gadbail et al. (41) examined the true proliferation activity in 36 OKC, 30 dentigerous cyst, 30 RC and 12 healthy mucosal samples using p53 expression, Ki-67 labeling index and AgNOR methods. They found significantly high correlation between AgNOR number and Ki-67 labeling in OKC specimens. Higher proliferation index found in OKC when compared to RC, dentigerous cyst and healthy mucosa has been associated with higher intrinsic proliferation potential of OKC, which might also provide an explanation for the local aggressive behavior of the same lesion. Authors detected significantly

higher Ki-67 labeling index in the suprabasal layers than the basal components in OKC and, since the highest proliferation activity was also found in suprabasal layers, they indicated that such changes might represent an epithelial differentiation similar to the epithelial irregularities seen in dysplastic squamous epithelium or the presence of preamelobastic changes in the cells of basal layer. Since the number of cells labelled positive for Ki-67 was low in suprabasal layers but higher in basal parts of RC, they proposed a possible relation between the intensity of the inflammation and positive Ki-67 labelling. In addition, the increase in the Ki-67 labeling index of the healthy mucosa when compared to RC and dentigerous cyst, has been associated with the dynamic tissue characteristics of the oral tissues. Kolar et al. (42) performed an immunohistochemical analysis of 57 OKCs (18 with NBCCS, 39 primary lesions), 10 dentigerous cysts, 29 RCs and 11 non-specific odontogenic cysts. Ki-67 expression in sporadic OKC was found to be higher than that of OKC associated with syndromes and Ki-67 staining in other groups was observed to be weaker than OKCs. Slootweg (43) investigated p53 and Ki-67 reactions in OKC, RC, AML, dentigerous cyst and odontojenic carcinoma. They reported that the Ki-67 positive staining was considerably higher in OKC when compared to dentigerous cyst and RC. High intensity of the positive cells has been detected in the suprabasal layer of the OKC group, in contrast to the RC group in which the positive cells have been mostly accumulated to the basal layer. Authors have suggested that the Ki-67 and p53 expressions might be helpful in evaluating the proliferation potentials of odontogenic carcinoma and OKC. Kurokawa et al. (44) who examined the presence of Ki-67 and p53 expressions in 62 cases (age range: 37 to 89 years) diagnosed immunohistochemically as oral squamous cell carcinoma, have stated that these markers might provide an important diagnostic advantage in grading the potential of malignancy in these lesions. Similary, Myoung et al. (45), compared the survival rates of 113 oral squamous cell carcinoma patients with their Ki-67 expressions. They concluded that the patients with higher Ki-67 expressions could have lower survival rates and they interpreted this finding as a significant evidence of the influence of Ki-67 in tumor prognosis.

Our findings have shown that the Ki-67 expression in OKC epithelium was more intense than other groups and more Ki-67 positive stained cells have been observed in the AML group when compared to RC group. Apart from the epithelium, maximum staining in the connective tissue cells has been found in RC. Intense staining of Ki-67 in the connective tissue cells of RC could be related to the chronic proliferative inflammation and its stimulating effects. On the other hand, DF group had the minimum percentage of staining, probably because of the latency of the cellular elements that require a proliferative stimulus in this group.

The role of COX-2 in the various steps of carcinogenesis has been previously studied by several investigators. COX-2 stimulates the prostoglandin synthesis which increases the proliferating activity of the neoplastic cells and inhibits the apoptosis. This process has been shown to lead to the proliferation of tumor cells that increase its potential of invasion (22, 23, 26, 30, 46-54). van Nes JG et al. (49), performed COX-2 immunohistochemical staining of the specimens obtained from surgically treated breast cancer patients between 1985 and 1994. 88 % of the tumors have stained positively for COX-2. Khodeir

et al.(48) examined 42 prostatic lesions consisting of 15 carcinoma, 10 neoplasia and 17 benign hyperplasia. COX-2 expressions in carcinoma, neoplasia and hyperplasia were reported as 97.6 %, 50 % and 23.5 %, respectively. Authors have emphasized the role of COX-2 in the detection and prognosis of prostate carcinoma and neoplasia. Li et al. (31) evaluated COX-2 expression in 9 healthy and 137 ovarian cancer (83 primary, 57 metastatic tumors) samples. In tumor tissues, COX-2 expression was found to be 70.8 % and metastatic cases presented significantly higher rates of COX-2 staining. Tsai et al. (55) analyzed COX-2 expression in 30 immunohistochemically diagnosed RC and classified the specimens based on the presence of inflammation. Their findings showed significantly higher staining rates for RC group and more importantly, RC with high inflammatory cellular content could be strongly stained for COX-2 when compared to lesions with low grade of inflammation. Accordingly, the authors stated that the COX-2 expression might have a role in the RC pathogenesis. Mendes et al. (56) investigated the possible correlation of COX-2 expression with p53 and Ki-67 markers in OKC.

They used COX-2, p53 and Ki-67 monoclonal antibodies on 20 biopsy specimens diagnosed as OKC and classified the molecular expressions under weak, mild and strong categories. All specimens demonstrated mild to strong staining for COX-2, 15 specimens (75 %) showed strong staining for p53 and 18 samples (90 %) strong staining for Ki-67. However, there was no statistically relevant difference between the expressions of COX-2, Ki-67, and p53. The results of this study and the current knowledge of the overall role known to be played by COX-2 in tumorigenesis, suggested that COX-2 may be an important marker involved in the biological behavior of the OKC. Consistent with aforementioned articles, in our study, OKC which is the most aggressive lesion with significant tendency to relapse, demonstrated the highest percentages of COX-2 expression followed by AML, DF and RC. High inflammatory cellular content in DF specimens may have contributed to the presence of COX-2 expression in this group.

Conclusion

The findings of our research suggest that Ki-67 and COX-2 expressions in controversial entities such as OKC and AML can be higher than RC, DF and healthy mucosa samples. The early detection of the high proliferative activity and possible aggressive characteristics of such lesions may provide a possible molecular basis for the distinction of their clinical behavior which will have a significant impact in their prognosis.

References

1. Regezzi JA, Sciubba JJ, Jordan RCK. Oral pathology: clinical pathologic correlations. 5th ed., Philadelphia: Saunders, 2008.
2. Neville BW, Damm DD, Allen CM, Bouquot JE. Oral and maxillofacial pathology. 3th ed., Missouri: Saunders Elsevier, 2009.
3. Philipsen HP. Keratocystic odontogenic tumour. In: Barnes L, Eveson JW, Reichart P, Sinransky D. (Ed.) Head and neck tumours, WHO classification of tumours. 5th ed., Lyon: IARC Pres, 2005, p.306-7.
4. Bhargava D, Deshpande A, Pogrel MA. Keratocystic odontogenic tumour (KCOT) - a cyst to a tumour. Oral and Maxillofac Surg 2012;16(2):163-70.

5. Ledesma-Montes C, Mosqueda-Taylor A, Carlos-Bregni R, de Leon ER, Palma-Guzman JM, Paez-Valencia C, Meneses-Garcia A. Ameloblastomas: a regional Latin-American multicentric study. Oral Dis 2007;13(3):303-7.
6. Al-Khateeb TH, Bataineh AB. Pathology associated with impacted mandibular third molars in group of Jordanians. J Oral Maxillofac Surg 2006;64(11):1598-602.
7. Adelsperger J, Campbell JH, Coates DB, Summerlin DJ, Tomich CE. Early soft tissue pathosis associated with impacted third molars without pericoronal radiolucency. Oral Surg Oral Med Oral Pathol Oral Radiol Endod 2000;89(4):402-6.
8. Baykul T, Saglam AA, Aydin U, Basak K. Incidence of cystic changes of in radiographically normal impacted lower third molar follicles. Oral Surg Oral Med Oral Pathol Oral Radiol Endod 2005;99(5):542-5.
9. Adeyemo WL. Do pathologies associated with impacted lower third molars justify prophylactic removal? A critical review of the literature. Oral Surg Oral Med Oral Pathol Oral Radiol Endod 2006;102(4):448-52.
10. Cabbar F, Güler N, Comunoğlu N, Sençift K, Cöloğlu S. Determination of potential cellular proliferation in the odontogenic epithelia of the dental follicle of the asymptomatic impacted third molars. J Oral Maxillofac Surg 2008;66(10):2004-11.
11. Kanan S, Chandran GJ, Pillai KR, Mathew B, Sujathan K, Nalinakumary KR, Nair MK. Expression of p53 in leukoplakia and squamous cell carcinoma of the oral mucosa: correlation with expression of Kİ67. Clin Mol Pathol 1996;49(3):170-5.
12. Kausch I, Jiang H, Ewerdwalbesloh N, Doehn C, Krüger S, Sczakiel G, Jocham D. Inhibition of Ki-67 in a renal cell carcinoma severe combined immunodeficiency disease mouse model is associated with induction of apoptosis and tumour growth inhibition. BJU Int 2005;95(3):416-20.
13. Bantis A, Giannopoulos A, Gonidi M, Liossi A, Aggelonidou E, Petrakakou E, Athanassiades P, Athanassiadou P. Expression of pl20, Ki-67 and PCNA as proliferation biomarkers in imprint smears of prostate carcinoma and their prognostic value. Cytopathology 2004;15(1):25-31.
14. Cristopher G. Immunhistochemisty of non-Hodgkin lymphoma. In: David D (Ed.) Diagnostic immunhistochemistry. 2nd ed., China: Churchill Livingstone Elseiver, 2006.
15. Hayashi H, Ogawa N, Ishiwa N, Yazawa T, Inayama Y, Ito T, Kitamura H. High cyclin E and low p27/Kipl expressions are potentially poor prognostic factors in lung adenocarcinoma patients. Lung Cancer 2001;34(1):59-65.
16. Jarzabek K, Koda M, Kozlowski L, Mittre H, Sulkowski S, Kottler ML, Wolczynski S. Distinct mRNA, protein expression patterns and distribution of oestrogen receptors a and b in human primary breast cancer: correlation with proliferation marker Ki67 and clinicopathological factors. European J Cancer 2005;41(18):2924-34.
17. Nguyen VN, Mirejovsky P, Mirejovsky T, Melinova L, Mandys V. Expression of cyclin Dl, Ki-67 and PCNA in non-small cell lung cancer: prognostic significance and comparison with p53 and bcl-2. Acta Histochem 2000;102(3):323-38.

18. Stanton KJ, Sidner RA, Miller GA, Cummings OW, Schmidt CM, Howard TJ, Wiebke EA. Analysis of Ki-67 antigen expression, DNA proliferative fraction, and survival in resected cancer of the pancreas. Am J Surg 2003;186(5):486-92.
19. Wiesener B, Hauser-Kronberger CE, Zipperer E, Dietze O, Menzel C, Hacker GW. p34cdc2 in invasive breast cancer: relationship to DNA content, Ki67 index and c-erbB-2 expression. Histopathology 1998;33(6):522-30.
20. Morsczeck C, Götz W, Schierholz J, Zeilhofer F, Kühn U, Möhl C, Sippel C, Hoffmann KH. Isolation of precursor cells (PCs) from human dental follicle of wisdom teeth. Matrix Biol 2005;24(2):155-65.
21. Dubois RN, Abramson SB, Crofford L, Gupta RA, Simon LS, Van de Putte LB, Lipsky PE. Cyclooxygenase in biology and disease. FASEB J 1998;12(12):1063-73.
22. Meric JB, Rottey S, Olaussen K, Soria JC, Khayat D, Rixe O, Spano JP. Cyclooxygenase-2 as a target for anticancer drug development. Crit Rev Oncol Hematol 2006;59(1):51-64.
23. Zha S, Yegnasubramanian V, Nelson WG, Isaacs WB, De Marzo AM. Cyclooxygenases in cancer: progress and perspective. Cancer Lett 2004;215(1):1-20.
24. Castealo JE, Bart RD 3rd, DiPerna CA, Sievers EM, Bremner RM. Lung cancer and cyclooxygenase-2. Ann Thorac Surg 2003;76(4):1327-35.
25. Davies GL. Cyclooxygenase-2 and chemoprevention of breast cancer. J Steroid Biochem Mol Biol 2003;86(3-5):495-9.
26. Hussain T, Gupta S, Mukhtar H. Cyclooxygenase-2 and prostate carcinogenesis. Cancer Lett 2003;191(2):125-35.
27. Manchana T, Triratanachat S, Sirisabya N, Vasuratna A, Termrungruanglert W, Tresukosol D. Prevalence and prognostic significance of COX-2 expression in stage IB cervical cancer. Gynecol Oncol 2006;100(3):556-60.
28. Itoh S, Matsui K, Furuta I, Takano Y. Immunhistochemical study on overexpression of cyclooxygenase-2 in squamous cell carcinoma of the oral cavity: its importance as a prognostic predictor. Oral Oncol 2003;39(8):829-35.
29. Kanekura T, Higashi Y, Kanzaki T. Inhibitory effects of 9-cis-retinoic acid and pyrrolidinedithiocarbamate on cyclooxygenase(COX)-2 expression and cell growth in human skin squamous carcinoma cells. Cancer Lett 2000;161(2):177-83.
30. Kawai N, Tsujii M, Tsuji S. Cyclooxygenase and colon cancer. Prostaglandins Other Lipid Mediat 2002;68-69:187-96.
31. Li S, Miner K, Fannin R, Carl Barrett J, Davis BJ. Cyclooxygenase-1 and 2 in normal and malignant human ovarian epithelium. Gynecol Oncol 2004;92(2):622-7.
32. Masunaga R, Kohno H, Dhar DK, Ohno S, Shibakita M, Kinugasa S, Yoshimura H, Tachibana M, Kubota H, Nagasue N. Cyclooxygenase-2 expression correlates with tumor neovascularization and prognosis in human colorectal carcinoma patients. Clin Cancer Res 2000;6(10):4064-8.
33. Miyata Y, Koga S, Kanda S, Nishikido M, Hayashi T, Kanetake H. Expression of cyclooxygenase-2 in renal cell carcinoma: correlation with tumor cell

proliferation, apoptosis, angiogenesis, expressions of matrix metalloproteinase-2, and survival. Clin Cancer Res 2003;9(5):1741-9.

34. Nozoe T, Ezaki T, Kabashima A, Baba H, Maehara Y. Significance of immunohistochemical expression of cyclooxygenase-2 in squamous cell carcinoma of the esophagus. Am J Surg 2005;189(1):110-5.
35. Yildirim G, Ataoğlu H, Mihmanli A, Kiziloğlu D, Avunduk MC. Pathologic changes in soft tissues associated with asymptomatic impacted third molars. Oral Surg Oral Med Oral Pathol Oral Radiol Endod 2008;106(1):14-8.
36. Koçak H, Timoçin N, Öz F, Uraz S. Gömük alt akıl dişi çevre dokularının histopatolojik ve immunohistokimyasal değerlendirilmesi. İstanbul Üniv Diş Hek Fak Derg 1994;28(1):83-6.
37. Rakprasitkul S. Pathologic changes in the pericoronal tissues of unerupted third molars. Quintessence Int 2001;32(8):633-8.
38. Curran AE, Damm DD, Drummond JF. Pathologically significant pericoronal lesions in adults: histopathologic evaluation. J Oral Maxillofac Surg 2002;60(6):613-7.
39. Mesgarzadeh AH, Esmailzadeh H, Abdolrahimi M, Shahamfar M. Pathosis associated with radiographically normal follicular tissues in third molar impactions: a clinicopathological study. Indian J Dent Res 2008;19(3):208-12.
40. Edamatsu M, Kumamoto H, Ooya K, Echigo S. Apoptosis-related factors in the epithelial components of dental follicles and dentigerous cysts associated with impacted third molars of the mandible. Oral Surg Oral Med Oral Pathol Oral Radiol Endod 2005;99(1):17-23.
41. Gadbail AR, Chaudhary M, Patil S, Gawande M. Actual proliferating index and p53 protein expression as prognostic marker in odontogenic cysts. Oral Dis 2009;15(7):490-8.
42. Kolár Z, Geierová M, Bouchal J, Pazdera J, Zboril V, Tvrdy P. Immunohistochemical analysis of the biological potential of odontogenic keratocysts. J Oral Pathol Med 2006;35(2):75-80.
43. Slootweg PJ. p53 protein and Ki-67 reactivity in epithelial odontogenic lesions. An immunohistochemical study. J Oral Pathol Med 1995;24(9):393-7.
44. Kurokawa H, Zhang M, Matsumoto S, Yamashita Y, Tanaka T, Tomoyose T, Takano H, Funaki K, Fukuyama H, Takahashi T, Sakoda S. The relationship of the histologic grade at the deep invasive front and the expression of Ki-67 antigen and p53 protein in oral squamous cell carcinoma. J Oral Pathol Med 2005;34(10):602-7.
45. Myoung H, Kim MJ, Lee JH, Ok YJ, Paeng JY, Yun PY. Correlation of proliferative markers (Ki-67 and PCNA) with survival and lymph node metastasis in oral squamous cell carcinoma: a clinical and histopathological analysis of 113 patients. Int J Oral Maxillofac Surg 2006;35(11):1005-10.
46. Lin DT, Subbaramaiah K, Shah JP, Dannenberg AJ, Boyle JO. Cylooxygenase-2: a novel molecular target for the prevention and treatment of head and neck cancer. Head Neck 2002;24(8):792-9.
47. Mohan S, Epstein JB. Carcinogenesis and cyclooxygenase: the potential role of COX-2 inhibition in upper aerodigestive tract cancer. Oral Oncol 2003;39(6):537-46.
48. Khodeir MM, Mahmoud SA, Gabal SM, Abou-Sriea MA. Cyclooxygenase-2

Cancer Res 2009;2(1):33-9.

49. van Nes JG, de Kruijf EM, Faratian D, van de Velde CJ, Putter H, Falconer C, Smit VT, Kay C, van de Vijver MJ, Kuppen PJ, Bartlett JM. COX-2 expression in prognosis and in prediction to endocrine therapy in early breast cancer patients. Breast Cancer Res Treat 2011;125(3):671-85.
50. Gallo O, Masini E, Bianchi B, Bruschini L, Paglierani M, Franchi A. Prognostic significance of cyclooxygenase-2 pathway and angiogenesis in head and neck squamous cell carcinoma. Hum Pathol 2002;33(7):708-14.
51. Tang DW, Lin SC, Chang KW, Chi CW, Chang CS, Liu TY. Elevated expression of cyclooxygenase (COX)-2 in oral squamous cell carcinoma-evidence for COX-2 induction by areca quid ingredients in oral keratinocytes. J Oral Pathol Med 2003;32(9):522-9.
52. Sugihara I, Yoshida M, Shigenobu T, Takagi H, Maruyama K, Takeuchi N, Toda M, Inoue M, Nakada H. Different progression of tumor xenografts between mucin-producing and mucin-non-producing mammary adenocarcinoma-bearing mice. Cancer Res 2006;66(12):6175-82.
53. Kelley DJ, Mestre JR, Subbaramaiah K, Sacks PG, Schantz SP, Tanabe T, Inoue H, Ramonetti JT, Dannenberg AJ. Benzo[a] pyrene up-regulates cyclooxygenase-2 gene expression in oral epithelial cells. Carcinogenesis 1997;18(4):795-9.
54. Weng MW, Hsiao YM, Chen CJ, Wang JP, Chen WC, Ko JL. Benzo(a)pyrene diol epoxide up-regulates COX-2 expression through NF-kappaB in rat astrocytes. Toxicol Lett 2004;151(2):345-55.
55. Tsai CH, Huang FM, Yang LC, Chou MY, Chang YC. Immunohistochemical localization of cyclooxygenase-2 in radicular cyst. Int Endod J 2002;35(10):854-8.
56. Mendes RA, Carvalho JF, van der Waal I. A comparative immunohistochemical analysis of COX-2, p53, and Ki-67 expression in keratocystic odontogenic tumors. Oral Surg Oral Med Oral Pathol Oral Radiol Endod 2011;lll(3):333-9.

Corresponding Author:
Çiğdem ÖZÇAMUR GÜNEŞ
Radix Ağız Diş Sağlığı Merkezi
34860 Kartal/İstanbul
Phone:0530 245 05 60
e-mail:cigdemozcamurgunes@hotmail.com