JCEI /
Journal of Clinical and Experimental Investigations

2013; 4 (3): 383-386
doi: 10.5799/ahinjs.01.2013.03.0309

CASE REPORT / OLGU SUNUMU

Morganella morganii in sinonasal region: A rare case report

Sinonazal bölgede Morganella morganii: Nadir bir olgu sunumu

Haşmet Yazıcı[1], Sedat Doğan[1], İlknur Haberal Can[2], Yusuf Baygit[3], Alicem Tekin[4]

ABSTRACT

Morganella morganii is a gram negative pathogen and may cause potentially lethal disease especially in patients with underlying or immunosuppressive disease. It is commonly found in long-term urinary catheter used and immune system deficiency patients as nosocomial disease. Involving other systems such as skin, skeletal system and central nervous system can be seen too. Sporadic occurrence is rare and can be seen in any system by various causes like AIDS, snake bites and poisoning. In this case we present sporadic *Morganella morganii* infection on sinonasal region with the presence of sinusitis, sino-cutaneous fistula, preseptal cellulitis and hard palate defect on 58 year old male diabetic patient. Microbiological assessment from open wound and sinuses were reported as *Morganella morganii*. To our knowledge, this is the first case of sino-nasal *Morganella morganii* infection with sino-cutaneous fistula, preseptal cellulitis and maxillofacial bone destruction. *J Clin Exp Invest 2013; 4 (3): 383-386*

Key words: Morganella Morganii, sino-nasal fistula, preseptal cellulitis, bone destruction

ÖZET

Morganella morganii, özellikle immunsupresif, uzun dönem idrar yolu kateteri kullanan kişilerde ölümcül hastalıklara yol açabilen Gram-negatif fırsatçı bir patojendir. Sıklıkla üriner sistem enfeksiyonlarına yol açmasına rağmen kas-iskelet sistemi, santral sinir sistemi ve cilt enfeksiyonlarına da sebep olabilmektedir. Sporadik enfeksiyon olguları nadir olmakla birlikte AİDS, zehirlenmeler ve yılan ısırmaları ile birlikte görülebilmektedir. Sino-kutanöz fistül, preseptal selülit ve oro-maksiller fistül gelişimi görülen, 58 yaşındaki diabetik erkek hastada yapılan tetkikler sonucu M morganii enfeksiyonu saptandı. Hastaya fronto-etmoidektomi ve mediyal maksillektomi yapıldı. İki hafta uygulanan medikal tedavi sonucu genel durumu düzeldi. Bu olgu, araştırmalarımıza göre sinonazal bölgede ilk kez görülen *M. morganii* enfeksiyonu olup tanı, tedavi ve klinik yönleriyle tartışılmıştır.

Anahtar kelimeler: Morganella morganii, sinonazal fistül, preseptal selülit, kemik defekti

INTRODUCTION

Morganella morganii is a member of Proteae which is included in *Enterobacteriaceae* family [1]. *M. morganii* is a Gram-negative opportunistic bacillus which is usually found in the environment and in the intestinal tracts of humans, mammals, and reptiles as normal flora. It has two subgroups named morganii and sibonii. They can cause wound infections, urinary infections usually on patient who have urolithiasis, pneumonia, skeletal infections and central nervous system disease [2-4]. Appropriate antibiotic therapy is important for the best treatment of the disease. Usually they are naturally resistant to many beta-lactam antibiotics and may be resistant to ceftazidime and other third generation cephalosporins, but they are susceptible to cefepime, imipenem, meropenem, piperacillin, aminoglycosides, and fluoroquinolones. Improper antibiotic therapy may lead to delay on diagnosis and it is a predisposing factor for infection process. In uncomplicated cases mono therapy is usually enough. Combination therapy with two antibiotics (based on susceptibility of organism) is preferred for complicated cases and immune compromised patients. Surgical therapy is indicated for treating underlying disease.

CASE

A fifty eight-year-old male diabetic patient attended ear-nose-throat clinic with complaints of purulent drainage, hyperemia and swelling on the right side

[1] *Mardin General Hospital, Department of Ear-Nose-Throat Diseases, Mardin, Turkey*
[2] *Fulya Acıbadem Private Hospital, Department of Ear-Nose-Throat Diseases, İstanbul, Turkey*
[3] *Mardin Park Private Hospital, Department of Ear-Nose-Throat Diseases, Mardin, Turkey*
[4] *Dicle University, Regional Blood Center, Microbiology Laboratory, Diyarbakır, Turkey*

Correspondence: Yusuf Baygit,
Mardin Park Private Hospital, Department of Ear-Nose-Throat Diseases, Mardin, Turkey Email: baygit1@yahoo.com
Received: 15.08.2012, Accepted: 23.03.2013
Copyright © JCEI / Journal of Clinical and Experimental Investigations 2013, All rights reserved

of face (Figure 1). Patient had received ten days of amoxicillin-clavulanic acid therapy. Leukocytosis and hyperglycemia were detected on laboratory investigation. Dark colored granulation tissue was seen with anterior rhinoscopy. On CT scan there were mucosal thicknesses on right maxillary, ethmoid, sphenoid and frontal sinuses (Figure 2). Furthermore erosive abscess formation with a size of 3x1.5 cm on periorbital area and inflammatory thickness on optic nerve and retro-orbital fat tissue were detected. There was no intracranial involvement. Endoscopic sinus surgery was performed. Right middle concha was necrotic and adhered to septum. Nasal cavity was full of dark colored granulation tissue and lamina papyracea was eroded. There were fistulas at the base of maxillary sinus opening into oral cavity and at the anterior part of maxillary sinus. Fronto-maxilla-ethmoidectomy and medial maxillectomy were performed. All granulation tissue was removed and send for microbiological assessment.

Figure 1. Patient's picture

In microbiology laboratory, the granulation tissue specimen was inoculated onto 5% sheep blood agar and Eosin-Methylen Blue agar (EMB) (Merck KGaA, Darmstadt, Germany) media plates. Then, these media plates were aerobically incubated at 35 ± 2°C for 18-24 hours. Identification of Gram-negative isolate was performed by using conventional methods. Antimicrobial susceptibility testing of isolate was determined by measuring the diameter of inhibition zone around the antibiotic discs with using the Kirby-Bauer's disc diffusion method according to the Clinical and Laboratory Standards Institute susceptibility interpretive breakpoints [5]. Escherichia coli ATCC 25922 reference strain was used for the quality control of antimicrobial susceptibility testing. *M. morganii* was observed on cultures taken from granulation tissue.

Meticulous insulin therapy for regulation of diabetes and I.V. meronem 3x1 gr, amikacin 1x1 gr for 15 days, amphotericin B 1x50 mg were started. Fistulized wound was healed by daily surgical debridement and dressing with riphocin and acid borique solution. After two week sino-cutaneous fistula healed. Preseptal cellulite and sinusitis regressed and general condition of patient improved. However diabetic control couldn't be obtained and patient was referred to endocrine service. During follow up period patient's blood glucose control couldn't be obtained and after 13 days patient died from sepsis.

DISCUSSION

Morganella is a Gram-negative opportunistic bacillus which is a member of *Enterobacteriaceae* family [1]. In 1906, Morgan described a non-lactose-fermenting organism as a different pathogen while studying the etiology of summer infantile diarrhea [6]. After then, in 1919 Winslow named this pathogen as Bacillus morganii for the production of indole and the fermentation of carbonhydrates and non-ability of liquefaction of gelatin [7]. For a long time, Morganella was known as a type of Proteus and called as Proteus morganii. In 1978 Brenner et al. and in 1985 Farmer et al. showed that Morganella is a different organism from Proteus [8]. Identification of *M. morganii* is made by recovery of small, oxidase-negative, catalase and indole positive Gram-negative rod on 5% sheep blood agar or EMB agar. *M. morganii* ferments glucose and mannose but not lactose. *M. morganii* is motile, facultative anaerobic and non-encapsulated, and it hydrolyzes urea and reduces nitrates.

Immunosuppressive treatment, poison contamination, history of surgery, advanced age, urolithiasis, improper antibiotic therapy and AIDS are the risk factors for M. morganii infections [9]. Most common clinical presentations are wound infection and urinary tract infection [2]. Furthermore M. morganii can cause perinatal infections, late-onset neonatal infections, fatal necrotizing fasciitis, skeletal infections and central nervous system infections [3,4]. In this case, presence of DM and improper antibiotic therapy were the risk factors that we found for M. morganii infection. There were sinusitis and bone defects at anterior, inferior part of maxilla and lamina papyracea. In the literature, no bone defect caused by Morganella infection was reported in sinonasal region.

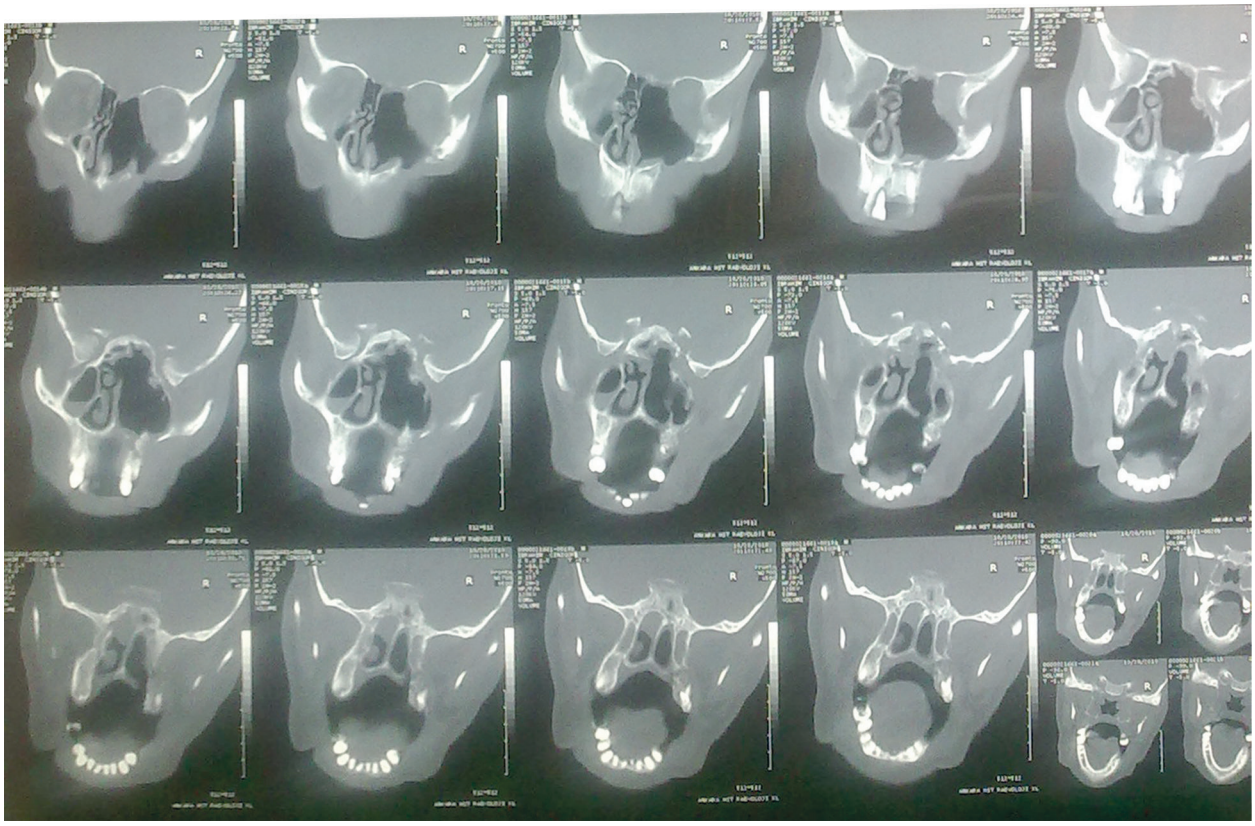

Figure 2. Preoperative Computed Tomography image

Treatment should be done by medically and surgically if needed. First of all, due to the opportunistic character of M. morganii, underlying disease must be treated. Uncomplicated and early diagnosed infections can be treated with mono antibiotic therapy. Choice of antibiotic treatment is very important because improper antibiotic therapy is a risk factor for development of M. morganii infection [9]. Naturally M. morganii is resistant to penicillin, ampicillin, ampicillin-sulbactam, oxacillin, first and second-generation cephalosporins, by chromosomally encoded AmpC beta-lactamases and possesses the ability to develop resistance upon exposure to broad-spectrum cephalosporins [10]. Most strains are naturally susceptible to piperacillin, ticarcillin, mezlocillin, third- and fourth-generation cephalosporins, carbapenems, aztreonam, fluoroquinolones, aminoglycosides, and chloramphenicol. In case of abscess formation, cutaneous open wound or concurrent disease (chronic sinusitis, sino-cutenous fistula and abscess formation on periorbicular tissue) surgery should be done.

In conclusion, M. morganii is a rare opportunistic pathogen which could cause serious diseases. This infection must be treated with multidisciplinary approach. To our knowledge this is the first case in sinonasal region with uncommon features of this infection like bone destruction, sino-cutaneous fistula and preseptal cellulitis.

REFERENCES

1. O'Hara CM, Brenner FW, Miller JM. Classification, identification and clinical significance *of Proteus, Providencia* and *Morganella*. Clin Microbiol Rev 2000;13:534-546.
2. Tucci V, Isenberg HD. Hospital cluster epidemic with *Morganella morganii*. J Clin Microbiol 1981;14:563-566.
3. Jorge MT, Ribeiro LA, da Silva ML, et al. Microbiological studies of abscesses complicating Bothrops snakebite in humans: a prospective study. Toxicon 1994;32:743-748.
4. Abdalla J, Saad M, Samnani I, et al. Central nervous system infection caused by *Morganella morganii*. Am J Med Sci 2006;331:44-47.
5. Clinical and Laboratory Standards Institute. Performance standards for antimicrobial susceptibility testing; Twenty-second Informational Supplement. Document M100-S22. Wayne, PA 2012.
6. Morgan H de R. Report XCV. Upon the bacteriology of the summer diarrhea of infants. Br Med J 1906;1:908-912.

7. Winslow CEA, Kligler IJ, Rothberg W. Studies on the classification of the colon-typhoid group of bacteria with special reference to their fermentative reactions. J Bacteriol 1919;4:429-503.
8. Brenner DJ, Farmer JJ III, Fanning GR, et al. Deoxyribonucleic acid relatedness of *Proteus* and *Providencia* species. Int J Syst Bacteriol 1978;28:269-282.
9. McDermott C, Mylotte JM. Morganella morganii: epidemiology of bacteremic disease. Infect Control 1984;5:131-137.
10. Biedenbach DJ, Jones RN, Erwin ME. Interpretive accuracy of the disk diffusion method for testing newer orally administered cephalosporins against *Morganella morganii*. J Clin Microbiol 1993;31:2828-2830.