Congenital Insensitivity to Pain with Anhidrosis (CIPA) Manifested with Chronic Osteomyelitis; A Case Report

Kronik Osteomyelitle Birlikte Görülen Anhidrozlu Doğumsal Ağrı Duyarsızlığı: Olgu Sunumu

Doğumsal Ağrı Duyarsızlığı / Congenital Insensitivity to Pain

Fatih Kucukdurmaz[1], Yunus Imren[1], Vedat Uruc[2], Cengiz Sen[1]
[1]Orthopaedics & Traumatology Department, Bezmialem Vakif University, Istanbul,
[2]Orthopaedics & Traumatology Department, Acibadem Kayseri Hospital, Kayseri, Turkey

Bu olgu, 31 Ekim - 5 Kasım 2011 tarihleri arasında Antalya'da düzenlenen 22. Türk Ulusal Ortopedi ve Travmatoloji Kongresi'nde poster bildirisi olarak sunulmuştur.

Özet

Kronik osteomyelit çocuklarda çok nadir görülen bir durumdur. Herediter duyusal ve otonomik nöropati tiplerinden biri olan anhidrozla birliktelik gösteren doğumsal ağrı duyarsızlığı da sinir sisteminin otozomal resesif geçişli çok nadir bir hastalığıdır. Ağrı duyarsızlığı, anhidroza bağlı ateş, tekrarlayan kırıklar, kronik osteomyelit, mental retardasyon, kendine zarar verme eğilimi, yara ülserleri görülebilir. Bu sunumda ağrı duyarsızlığı, sağ uyluk alt ucunda kronik osteomyelit, bilateral korneal opasite ve mental geriliği olan 10 yaşında bir erkek çocuğunu takdim etmekteyiz.

Anahtar Kelimeler

Osteomyelit; Ağrı Duyarsızlığı; Mental Retardasyon; Keratit

Abstract

Chronic osteomyelitis is a very rare entity among children. Also congenital insensitivity to pain with anhidrosis (CIPA) is a very rare autosomal-recessive disease of the nervous system which is one of the hereditary sensory and autonomic neuropathies (HSAN). Loss of pain, fever due to anhidrosis, recurrent fractures, chronic osteomyelitis, mental retardation, self mutilation, wound ulcers can be seen. We present a 10-year-old boy with loss of generalized pain sensation, chronic osteomyelitis on his right distal femur, bilateral corneal opacities, and decreased mental capacity.

Keywords

Osteomyelitis; Insensitivity to Pain; Mental Retardation; Keratitis

DOI: 10.4328/JCAM.912 Received: 02.02.2012 Accepted: 20.02.2012 Printed: 01.03.2015 J Clin Anal Med 2015;6(2): 230-2
Corresponding Author: Yunus Imren, Bezmialem Vakif University, Faculty of Medicine, Orthopaedics & Traumatology Department, Vatan Cad. Fatih, 34093, Istanbul, Turkey. E-Mail: yunusimren@yahoo.com

Introduction

Congenital insensitivity to pain with anhidrosis (CIPA) or hereditary sensory and autonomic neuropathy type IV (HSAN IV) is a rare autosomal recessive disorder featuring recurrent fever episodes, inability to sweat, absent response to noxious stimuli, self mutilating behavior and mental retardation. In CIPA, injuries and infections of the extremities, non-healing fractures with prominent periosteal reactions and exuberant callus, self-mutilation due to lack of pain sensation, fever secondary to anhidrosis or infections, mental retardation, and loss of unmyelinated and diminished small myelinated fibers are known features [1,2]. Additionally several ocular manifestations such as superficial punctate keratopathy, diminished tear break-up time, corneal opacity, corneal ulcer, and infectious keratitis have been reported [3,4]. Infections and scarring around oral structures and keratoderma palmo-plantaris are other features [1,2]. We present a 10-year-old boy with loss of generalized pain sensation, chronic osteomyelitis in his right distal femur, bilateral corneal opacities, and decreased mental capacity.

Case Report

A 10-year-old Caucasian boy was admitted to our outpatient clinic with the complaint of swelling in the right thigh and high fever.

The patient had received initial diagnosis of CIPA when he was 3 years old. There were recurrent fever episodes, painless, inability to sweat, corneal opacities and mental retardation at first diagnosis. His diagnosis of CIPA was confirmed using genetic and dermal studies.

The family firstly recognized a swelling around his knee joint when he was 4 years old. Since it was painless he did not complain about it. His parents admitted to a university hospital when high fever started related with preexisting knee swelling. He underwent a knee debridement and intravenous antibiotic treatment with the diagnosis of septic arthritis and had a second operation three weeks later because of recurrence at his right knee and spread of infection to his right femur metaphysis. Then he experienced several operations on his right knee and thigh until his index admission. He also had dystrophic nails although he had healthy permanent teeth in admission, and premature loss of his deciduous teeth around 3 years of age was reported by his family. Bilateral central corneal opacities suggested previous neurotrophic keratitis. He was attending to a rehabilitation center for mentally retarded children.

On physical examination, his thigh was edematous but nontender which enabled him walking free of pain. His right thigh was 10 cm shorter than the left one. He had a limping gait because of the limb length discrepancy. There were several wound scars on his all extremities. The widest circumference of his right thigh was 47 cm, whereas it was 26 cm in his left thigh [Figure 1]. His thigh was warm in palpation and fluctuation was felt but there was not any discharge. His fever was measured 39 C°. Laboratory tests showed that Hb: 8,4 , wbc:20000, sedimentation: 90, CRP:50. Radiological examination of the lower extremities showed shortening, deformation, and sequestrum in the distal part of his right femur and thickening in the proximal part of the tibia [Figure 2,3]. This suggested an acute attack of chronic osteomyelitis in his right distal femur. We performed an open debridement, irrigation and postoperatively six weeks intravenous teicoplanin antibiotherapy due to intraoperative culture result which was noted as methicillin resistant Staphylococcus aureus colonization. He has not any wound discharge in the last postoperative six months and radiographic control view did not yield any major difference [Figure 4].

Figure 1. Preoperative view.

Figure 2. Preoperative AP radiography of right femur.

Figure 3. Preoperative Coronal CT views.

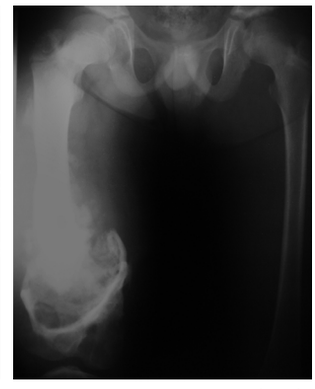

Figure 4. Postoperative 6 month radiography of right femur.

Discussion

Congenital insensitivity to pain is a rare condition which may affect various tracts in the peripheral nervous system. It was first described in 1846 by Leplat [5]. There is an indifference to painful stimuli, and in most patients the autonomic nervous system is affected [5]. The condition has therefore been described as hereditary sensory and autonomic neuropathy (HSAN) with various subtypes [5]. Among several classification systems, more widely accepted ones were proposed by Pinsky and DiGeorge in 1966 and more recently by Dyck in 1984 who divided these neuropathies into five types [6]. Our case was HSAN type 4. Type IV, also known as congenital insensitivity to pain with anhidrosis, is a severe form presenting at infancy. In addition to musculoskeletal problems, patients suffer from anhidrosis, defective control of temperature, mental retardation and severe behavioral disturbances.

Some publications also include familial cases [7]. 4-year-old sister of our case with CIPA had also painless ulna fracture, neurotrophic keratitis and generalized loss of pain sensation.

Various clinical presentations of CIPA have been reported in the current literature. Bar-On et al. [5] have described three clinical orthopedic presentations: type A, in which multiple infections occurred; type B, with fractures, growth disturbances and avascular necrosis; and type C, with Charcot arthropathies and joint dislocations, as well as fractures and infections. Our CIPA case manifested with chronic osteomyelitis in the distal femur. Additionally, we determined loss of generalized pain sensation; bilateral corneal opacities caused by neurotrophic keratitis, dystrophic nails and decreased mental capacity that's compatible with type A presentation.

The hallmark was multiple infections which usually started as infected decubitus ulcers either on weight-bearing areas in the feet or as infected bursitis around the knees or elbows, progressing to chronic osteomyelitis or septic arthritis. First complaint of our case was swelling of the knee which progressed to osteomyelitis.

The diagnosis was complicated by concomitant infections at multiple sites as well as defective temperature control masking systemic manifestations. We could not detect any concomitant infection in our case. History, physical examination, laboratory and radiological tests were useful for diagnosis.

One of the major problems in these patients is the differentiation between fractures and infections. Both will usually present at an advanced stage with local swelling and warmth. Due to lack of normal interpretation of painful stimuli, these patients continue to be the victims for several musculoskeletal injuries. Radiographs may show early formation of callus. Body temperature is not a reliable indicator, and the ESR and level of C-reactive protein are commonly elevated because of concomitant infections at other sites. Aspiration and cultures should therefore be obtained before undertaking radical debridement to prevent unnecessary surgery and damage to the growth plate [5,7].

Our case had also undergone several operations due to osteomyelitis from his right limb. As a result of these operations, because of distal femoral epiphysial arrest, shortening was obvious in his right limb. We have not any information whether he really needed these operations. We consider that aspiration and cultures are necessary for correct diagnosis, and once the diagnosis of infection has been clearly established, debridement should be as wide as possible to have local infection control. We must keep in mind that aggressive surgery will lead to damage in these cases.

In their study, Schulman et al. [2] reported recurrent non-healing fractures with prominent periosteal reactions and exuberant callus in 20 CIPA cases. They found osteomyelitis with massive rapid bony destruction nearly in half of their patients which is uncommon in children [8]. Likely, our case had a chronic osteomyelitis in his right distal femur, most probably due to preexisting septic arthritis of his right knee. He also had anemia of chronic disease because of chronic osteomyelitis. Schulman and colleagues also showed absorption of the distal phalanges (acro-osteolysis) in all of their cases. But, we did not see any sign of acro-osteolysis in this boy.

As a result, interpretation of pain is crucial in maintaining physical integrity. CIPA may have various clinical presentations even in the members of a same family. In most reports, relevant departments usually handled the cases according to their point of views. As CIPA may affect various organ systems in its course, management requires a multidisciplinary approach.

Constent

Written informed consent was obtained from the parents of the patient for publication of this case report and any accompanying images.

Competing interests

The authors declare that they have no competing interests.

References

1. Sztriha L, Lestringant GG, Hertecant J, Frossard PM, Masouye I. Congenital insensitivity to pain with anhidrosis. Pediatr Neurol 2001;25:63-6.
2. Schulman H, Tsodikow V, Einhorn M, Levy Y, Shorer Z, Hertzanu Y. Congenital insensitivity to pain with anhidrosis (CIPA): the spectrum of radiological findings. Pediatr Radiol 2001;31:701-5.
3. Theodorou SD, Klimentopoulou AE, Papalouka E. Congenital insensitivity to pain with anhidrosis. Report of a case and review of the literature. Acta Orthop Belg 2000;66:137-45.
4. Amano S, Fukuoka S, Usui T, Honda N, Ideta R, Ochiai M, et al. Ocular manifestations of congenital insensitivity to pain with anhidrosis. Am J Ophthalmol 2006;141(3):472-7.
5. Bar-On E, Weigl D, Parvari R, Katz K, Weitz R, Steinberg T. Congenital insensitivity to pain. Orthopaedic manifestations. J Bone Joint Surg Br 2002;84(2):252-7.
6. Marik I, Kuklik M, Kuklikova D, Kozlowsk K. Hereditary sensory and autonomic neuropathy type IV orthopaedic complications. J Pediatr Orthop B 2009;18(3):138-40.
7. Pavone L, Huttenlocher P, Siciliano L, Micali G, Rizzo R, Anastasi M, et al. Two brothers with a variant of hereditary sensory neuropathy. Neuropediatrics 1992;23(2):92-5.
8. Unal VS, Dayican A, Demirel M, Portakal S, Ozkan G, Ucaner A. Selection of treatment modalities in children with chronic osteomyelitis. Acta Orthop Traumatol Turc 2006;40:56-61.