Computed Tomography Findings in Traumatic Fractures of Thoracic and Lumbar Vertebrae

Torasik ve Lumbar Vertebraların Travmatik Kırıklarında Bilgisayarlı Tomografi Bulguları

CT in Traumatic Fractures of Vertebrae

Ümit Yaşar Ayaz[1], Meriç Tüzün[2], Sevin Ayaz[3], Mehmet Akif Teber[4], Baki Hekimoğlu[2]
[1]Department of Radiology, Mersin Women's and Children's Hospital, Mersin,
[2]Department of Radiology, Dışkapı Yıldırım Beyazıt Training and Research Hospital, Ankara,
[3]Department of Nuclear Medicine, Mersin State Hospital, Mersin,
[4]Department of Radiology, Turgut Özal University Faculty of Medicine, Ankara, Turkey

Özet

Amaç: Aksiyel bilgisayarlı tomografi (BT) görüntülerini kullanarak torasik ve lumbar vertebraların major travmatik kırıklarının ayırımını yapmayı amaçladık. Gereç ve Yöntem: Bu retrospektif çalışmada, sadece kompresyon ve/veya patlama kırıklarını içeren akut torasik ve lumbar omurga zedelenmesi tanısı konan 14 olgunun (dokuz erkek, beş kadın) aksiyel BT görüntüleri değerlendirildi. Denis sınıflaması kullanıldı. Bulgular: Olguların %64.3'ünde (n=9/14) kırıklar düşme sonucunda gerçekleşmiş olup olguların %35.7'sinde (n=5/14) kırık nedeni trafik kazası olarak bildirildi. Olguların %78.6'sında (n=11/14) fizik bakıda omurilik/sinir kökü zedelenmesi bulgusu saptanamadı ve olguların 21.4%'ünde (n=3/14) omurilik/sinir kökü zedelenmesi bulgusu mevcuttu. Kırık saptanan vertebraların %86.7'sı (n=13/15) lumbar vertebra ve %13.3'ü (n=2/15) torasik vertebra idi. Torakolomber bileşke (T11-L2), kompresyon ve patlama kırıklarının en sık görüldüğü bölge (73.3%, n=11/15) olup, L1 en sık tutulan vertebra idi (53.3%, n=8/15). Kompresyon ve patlama kırıkları vertebraların sırasıyla %53.3'ünde (n=8/15) ve %46.7'sinde (n=7/15) gösterildi. Patlama kırıklarının %71.4'inde (n=5/7), kemik parçalarının spinal kanala doğru yer değiştirmesi (retropulsiyon) gösterilmiş olup retropulsiyonu olan olguların %60'ında (n=3/5) ciddi nörolojik hasar mevcuttu. Tartışma: Travmatik vertebra kırıklarının 2/3'ünden fazlası torakolomber bileşkede (T11-L2) saptandı. Aksiyel BT görüntüleri torasik ve lumbar vertebraların kompresyon ve patlama kırıklarını ayırt etmede etkindir.

Anahtar Kelimeler

Omurga Kırıkları; Tomografi, X-Ray Bilgisayarlı; Çoklu Travma; Lumbar Vertebra

Abstract

Aim: We aimed to differentiate major traumatic fractures of thoracic and lumbar vertebrae by using axial computed tomography (CT) images. Material and Method: Axial CT images of 14 patients (nine males, five females) who were diagnosed to have acute thoracic and lumbar spinal injuries, including only compression and/or burst fractures, were evaluated in this retrospective study. Denis classification was used. Results: In 64.3% (n=9/14) of the patients fractures occurred as the result of a fall and in 35.7% (n=5/14) of the patients the reason for the fracture was reported to be a traffic accident. In 78.6% (n=11/14) of the patients, no signs of spinal cord/nerve root injury could be detected at physical examination and in 21.4% (n=3/14) of the patients there were signs of spinal cord/nerve root injury. Of the fractured vertebrae, 86.7% (n=13/15) were lumbar and 13.3% (n=2/15) were thoracic. The thoracolumbar junction (T11-L2) was the most frequent site (73.3%, n=11/15) for compression and burst fractures, L1 being the most frequently involved vertebra (53.3%, n=8/15). Compression and burst fractures were demonstrated in 53.3% (n=8/15) and 46.7% (n=7/15) of the vertebrae, respectively. In 71.4% (n=5/7) of the burst fractures, displacement of bony fragments into the spinal canal (retropulsion) were demonstrated and in 60% (n=3/5) of the patients with retropulsion, serious neurological deficits were present. Discussion: More than 2/3 of the traumatic vertebral fractures were detected in the thoracolumbar junction (T11-L2). Axial CT images are effective in differentiating compression and burst fractures of thoracic and lumbar vertebrae.

Keywords

Spinal Fractures; Tomography, X-Ray Computed; Multiple Trauma; Lumbar Vertebrae

DOI: 10.4328/JCAM.4669 Received: 30.05.2016 Accepted: 15.06.2016 Printed: 01.11.2016 J Clin Anal Med 2016;7(6): 844-7
Corresponding Author: Ümit Yaşar Ayaz, Department of Radiology, Mersin Women's and Children's Hospital, Mersin, Turkey.
T.: +90 3242230701-5102 GSM: +905377639442 F.: +90 3242230722 E-Mail: umityasarayaz@yahoo.com

Introduction

Though non-accidental reasons for thoracolumbar spine fractures such as seizures are reported [1,2], traffic accidents and falls which result in rapid deceleration are the main causes of thoracolumbar vertebral fractures [3]. Among several classifications which have been proposed for spinal injuries, such as Holdsworth classification [4] or AO classification [5], Denis classification was reported as the most commonly used [6]. Denis [7] classified acute thoracolumbar spinal injuries according to his "three column theory" in which anterior and middle columns include the anterior and posterior parts of annulus fibrosis-corpus vertebra, respectively [8]. Thus, major spinal injuries are classified into four different categories as compression fractures, burst fractures, seat-belt-type injuries, and fracture dislocations, whereas minor injuries included fractures of transverse process, spinal process, articular process, and pars interarticularis [7]. By using axial computed tomography (CT) images, we aimed to differentiate and classify major traumatic injuries/fractures of thoracic and lumbar vertebrae according to Denis classification, which has been used as a practical and common classification system since its introduction.

Material and Method

Study population

Between November 2001 and June 2002, axial CT images of 19 consecutive acute trauma patients with vertebral fractures were evaluated and 14 of them (nine males, five females) diagnosed as having at least one acute thoracic or lumbar spinal injury, and including only compression and/or burst fractures, were studied in this retrospective study. Five patients without vertebral corpus fractures, presenting with only fractures of transverse process or spinous process were excluded. The mean age of the patients was 37.9 ± 17.3 years (range, 14–70 years). Descriptive and percentage information about the patients is provided in Table 1. All of the procedures were performed according to the World Medical Association Declaration of Helsinki (revised in 2000, Edinburgh). All of the patients or close relatives were informed about the CT examination procedures, and informed consent was obtained from them.

Table 1. Descriptive and percentage information about the patients.

Gender	Males	Females
Frequency	9/14	5/14
Percentage (%)	64.3%	35.7%
Age (Mean±Standard Deviation)	34.6±15.3 years	43.8±20.9 years

Table 2. Distribution of compression and burst fractures of thoracic and lumbar vertebrae.

Affected vertebra	Frequency of compression fractures	Frequency of burst fractures
T7	6.7% (n=1/15)	
T12		6.7% (n=1/15)
L1	33.3% (n=5/15)	20% (n=3/15)
L2	6.7% (n=1/15)	6.7% (n=1/15)
L4	6.7% (n=1/15)	6.7% (n=1/15)
L5	6.7% (n=1/15)	

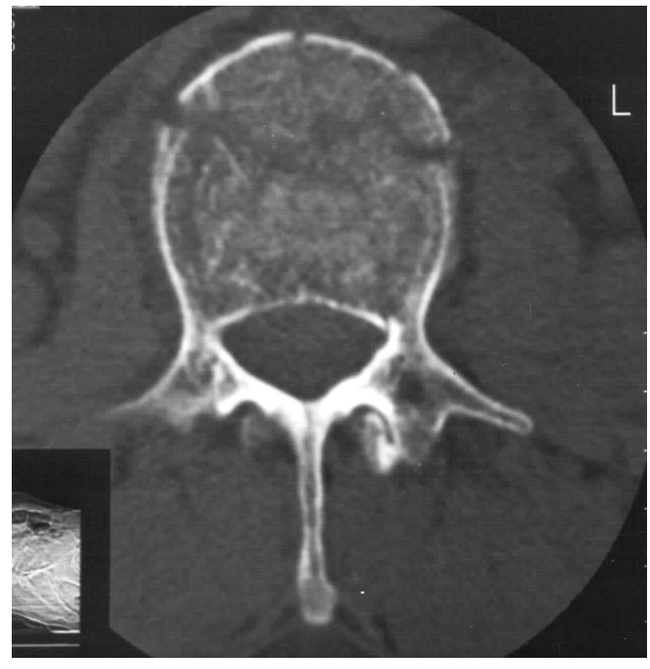

Figure 1. Axial CT image of a 56-year-old man with compression fracture of L2 vertebra. There was no neurological deficit.

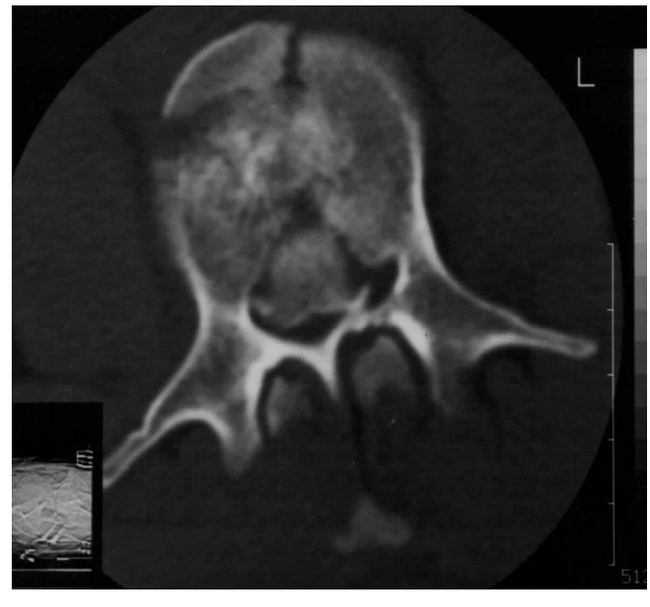

Figure 2. Axial CT image of a 23-year-old man with burst fracture of L2 vertebra. The patient was paraplegic due to the retropulsed bone fragments which severely narrowed the spinal canal.

CT protocol and image interpretation

A compression fracture was defined as a fracture of the anterior column with an intact middle column, whereas fracture of both the anterior and middle columns was accepted as a burst fracture [8]. The thoracolumbar junction was defined as the transitional zone between relatively rigid and mobile parts of the spine which included T11-12 and L1-2 vertebrae [9]. The CT images were obtained with a W1000 SR CT scanner (Hitachi Medical Corp., Tokyo, Japan) without intravenous administration of iodinated contrast media, using the following parameters: tube voltage, 120 kVp; maximum tube current, 150 mA; beam collimation (slice thickness), 5.0 mm; slice interval 5.0-7.5 mm; scan time, 1.9 s and matrix, 512x512. Bone window settings with window width of +1700 HU and window level of +500 HU were used. CT images were evaluated by readers with

more than 15 years of experience in image interpretation, by consensus. Denis classification was used to classify major traumatic injuries/fractures of thoracic and lumbar vertebrae.

Data analysis

The mean age of the patients, the percentages, and the number of patients and fractured vertebrae were obtained. All analyses were done with SPSS software (version 16.0; SPSS Inc; Chicago, IL, USA).

Results

In 64.3% (n=9/14) of the patients, fractures occurred as the result of a fall and in 35.7% (5/14) of the patients, the reason was a traffic accident. In 78.6% (n=11/14) of the patients, no signs of spinal cord/nerve root injury could be detected at physical examination, however in 21.4% (n=3/14) of the patients there were signs of severe spinal cord injury (paraplegia, anesthesia of lower extremities). Fractures of single vertebra were detected in 93% (n=13/14) of the patients and fractures of multiple vertebrae (L1 and L5) were detected in 7% (n=1/14) of the patients. Of the fractured vertebrae, 86.7% (n=13/15) were lumbar and 13.3% (n=2/15) of them were thoracic. The thoracolumbar junction (T11-L2) was the most frequent site (73.3%, n=11/15) for compression and burst fractures, L1 being the most frequently involved vertebra (53.3%, n=8/15) (Table 2). Compression fractures were demonstrated in 53.3% (n=8/15) of the vertebrae (Fig. 1), with no extension of the fracture to the posterior one-third of the vertebral body and to the posterior spinal elements. Burst fractures were detected in 46.7% (n=7/15) of the vertebrae, with an increase in interpedincular distance. In 71.4% (n=5/7) of the burst fractures, the displacement of bony fragments into the spinal canal were demonstrated (Fig. 2) and 60% (n=3/5) of these patients with retropulsed bone fragments had serious neurological deficits. In 28.6% (n=4/14) of the patients, major injuries were associated with minor injuries (fractures of the spinous process and/or lamina).

Discussion

Spinal fractures, particularly those of thoracolumbar vertebrae are among the major causes of morbidity in multiple trauma. The thoracolumbar region is the most frequent site for compression and burst fractures which occur primarily as a result of anterior flexion and by axial load, respectively [3,7,10]. This is due to its being a transitional region between a more rigid upper part and a relatively mobile lower part of the spine [9]. In our study, a majority of the vertebral fractures occured in the thoracolumbar area. Neurological deficits develop in up to 40% of thoracolumbar fractures [9]. In their study including 139 patients with thoracolumbar burst fractures, Fontijne et al. [11] found a significant correlation between the presence of neurological deficit and the degree of spinal canal stenosis. Likewise in our study, a majority of the patients with retropulsed fractures had severe neurological deficits including paraparesis, paraplegia, and anesthesia.

Though various imaging methods such as [18F]-2-fluoro-2-deoxy-D-glucose positron emission tomography [12] and magnetic resonance imaging [13–15] were used to evaluate the fractures of the spine, CT has been in use as the main diagnostic tool for the diagnosis of vertebral fractures for more than three decades [3, 16, 17]. In our study CT was sufficient to differentiate compression and burst fractures. We could evaluate the spinal canal in detail, whether it was intact or not and we could also clearly demonstrate the presence of any retropulsed bone fragment narrowing the spinal canal. In many studies, CT was found to be superior to plain radiographs in the evaluation of burst and compression fractures [10]. Unlike plain radiography, patients do not need to change position during CT examination [16]; patient stabilization is crucial in cases of multiple trauma. In our study, CT helped maintain the stability of the patients which also reduced the need for plain radiography. In multiple trauma patients, CT can also demonstrate other types of injuries such as acetabular fractures [18] or solid organ laceration and intraabdominal hemorrhage [19].

Since its introduction, multidetector CT (MDCT) was shown to help the evaluation of the thoracolumbar spine accurately in diagnosis and classification of its fractures [17]. Due to the retrospective design of the present study, we could not use MDCT which would have better demonstrated the lesions by providing sagittal and coronal reformations of the images [17]. This can be accepted as the major limitation of our study, though we confidently differentiated compression and burst fractures using axial images. Because of the small number of patients, we could not demonstrate other types of major spinal injuries including seat-belt-type injuries and fracture dislocations that Denis [7] proposed, which is another limitation of our study.

In conclusion, more than 2/3 of the traumatic vertebral fractures occurred in the thoracolumbar junction (T11-L2). Axial CT images were effective in diagnosing compression and burst fractures of thoracic and lumbar vertebrae and in differentiating these fracture types. Further multicentric studies with larger patient groups and with different causes of trauma will help us better understand the mechanism and epidemiology of thoracolumbar spine fractures which will be useful in taking measures to prevent them. Despite the risks of ionizing radiation [20–22], it seems that CT is going to maintain its major role in the imaging of the vertebral fractures of multiple trauma patients.

Competing interests

The authors declare that they have no competing interests.

References

1. Sharma A, Avery L, Novelline R. Seizure-induced lumbar burst fracture associated with conus medullaris-cauda equina compression. Diagn Interv Radiol 2011;17(3):199–204.
2. Youssef JA, McCullen GM, Brown CC. Seizure-induced lumbar burst fracture. Spine 1995;20:1301–3.
3. Shuman WP, Rogers JV, Sickler ME, et al. Thoracolumbar burst fractures: CT dimensions of the spinal canal relative to postsurgical improvement. American Journal of Roentgenology AJR 1985;145(2):337–41.
4. Holdsworth FW. Fractures, dislocations, and fracture-dislocations of the spine. J Bone Joint Surg Br 1963;45(1):6–20.
5. Magerl F, Aebi M, Gertzbein SD, Harms J, Nazarian S. A comprehensive classification of thoracic and lumbar injuries. Eur Spine J 1994;3(4):184–201.
6. Aebi M. Classification of thoracolumbar fractures and dislocations. Eur Spine J 2010;19(Suppl 1): 2–7.
7. Denis F. The three column spine and its significance in the classification of acute thoracolumbar spinal injuries. Spine (Phila Pa 1976) 1983;8(8):817–31.
8. Denis F. Spinal instability as defined by the three-column spine concept in acute spinal trauma. Clin Orthop Research 1984;189:65–76.
9. Dahnert W. Radiology Review Manual. 6th ed. Philadelphia, Lippincott Williams and Wilkins 2007:212.

10. Ergüven A, Bulut S, Işık AO, Arslan M. Torakal ve lomber omurların patlama kırıklarında bilgisayarlı tomografi. Acta Orthop Traumatol Turc 1996;30:294–8.
11. Fontijne WPJ, De Klerk LWL, Braakman R, Stijnen T, Tanghe HLJ, Steenbeek R, Van Linge B. CT scan prediction of neurological deficit in thoracolumbar burst fractures. J Bone Joint Surg 1992;74(5):683–5.
12. Bredella MA, Essary B, Torriani M, Ouellette HA, Palmer WE. Use of FDG-PET in differentiating benign from malignant compression fractures. Skeletal Radiol 2008;37(5):405–13.
13. Masala S, Chiaravalloti A, Calabria E, Taglieri A, Simonetti G. Thoraco-lumbar traumatic vertebral fractures augmentation by osteo-conductive and osteo-inductive bone substitute containing Strontium-Hydroxyapatite (Sr-HA): our experience. EPOS; 2015; Vienna, Austria. DOI: 10.1594/ecr2015/C-1602.
14. Salgado Á, Pizones J, Sánchez-Mariscal F, Álvarez P, Zúñiga L, Izquierdo E. MRI reliability in classifying thoracolumbar fractures according to AO classification. Orthopedics 2013;36(1):e75-e78. doi: 10.3928/01477447-20121217-22.
15. Öndül S, Durmuş M. Travmatik omur kırıklarında iki seviye balon kifoplasti uygulaması. J Clin Anal Med 2012;3(1):26–9.
16. McAfee PC, Yuan HA, Fredrickson BE, Lubicky JP. The value of computed tomography in thoracolumbar fractures. An analysis of one hundred consecutive cases and a new classification. J Bone Joint Surg Am 1983;65(4):461–73.
17. Roos JE, Hilfiker P, Platz A, et al. MDCT in emergency radiology: is a standardized chest or abdominal protocol sufficient for evaluation of thoracic and lumbar spine trauma? American Journal of Roentgenology AJR 2004;183(4):959–68.
18. Ayaz ÜY, Dilli A, Tüzün ÖM, Hekimoğlu B. Travmatik asetabulum kırıklarında bilgisayarlı tomografi bulguları. Yeni Tıp Derg 2010;27(4):216–20.
19. Soto JA, Anderson SW: Multidetector CT of blunt abdominal trauma. Radiology 2012;265(3):678–93.
20. Miglioretti DL, Johnson E, Williams A, Greenlee RT, Weinmann S, Solberg LI, et al. The use of computed tomography in pediatrics and the associated radiation exposure and estimated cancer risk. JAMA pediatrics 2013;167(8):700–7.
21. Strauss KJ, Goske MJ, Kaste SC. Bulas D, Frush DP, Butler P, et al. Image gently: ten steps you can take to optimize image quality and lower CT dose for pediatric patients. American Journal of Roentgenology AJR 2010;194(4):868–73.
22. Brenner DJ, Hricak H. Radiation exposure from medical imaging: time to regulate?. JAMA 2010;304(2):208–9.

How to cite this article:
Ayaz ÜY, Tüzün M, Ayaz S, Teber MA, Hekimoğlu B. Computed Tomography Findings in Traumatic Fractures of Thoracic and Lumbar Vertebrae. J Clin Anal Med 2016;7(6): 844-7.