Journal of Applied Biological Sciences 1 (3): 97-106, 2007

Light and Electron Microscopic Examinations in the Hippocampus of the Rat Brain Following PTZ-Induced Epileptic Seizures

Melda YARDIMOGLU[1*] Gul ILBAY[2] Sibel KOKTURK[3] Funda Durmaz ONAR[4] Deniz SAHIN[2]
Faruk ALKAN[3] Hakki DALCIK[1]

[1] Department of Histology&Embryology, Faculty of Medicine, Kocaeli University, 41380, Kocaeli, TÜRKİYE
[2] Department of Physiology, Faculty of Medicine, Kocaeli University, 41380, Kocaeli, TÜRKİYE
[3] Department of Histology& Embryology, Cerrahpaşa Faculty of Medicine, İstanbul University, 34098, İstanbul, TÜRKİYE
[4] Department of Histology& Embryology, İstanbul Faculty of Medicine, 34390, İstanbul University, İstanbul, TÜRKİYE

[*] Corresponding Author
e-mail: docdrmelda@yahoo.com

Received: 10 February 2007
Accepted: 20 March 2007

Abstract

The aim of this work was to evaluate hippocampal neurons in the rat brain after single and repetetive seizures induced by pentyleneterazol (PTZ) administration at light- and electron-microscopically. Acute- and chronic-PTZ groups of male Wistar albino rats were given PTZ intraperitoneal injection (i.p.), and the age-matched rats in control group were injected with normal saline. We determined contributions of apoptosis and necrosis to neuronal damage in Nissl-stained- and ultrathin-sections. Necrotic neurons were observed in PTZ-treated groups, especially in the chronic-PTZ group. Histological changes were perikaryal swelling, chromatolysis and decreasing of Nissl in the necrotic neurons. Necrotic and apoptotic neurons of the hippocampus were observed ultrastructurally in the PTZ groups. These findings demonstrated a significant decrease in the number of hippocampal neurons in the chronic-PTZ group. It is clear that in the hippocampal regions repeated PTZ-induced seizures of the rats cause neuronal damage and neuronal loss.

Key words: Pentylenetetrazol (PTZ), Epileptic seizures, Neuronal injury, Electron microscopy (EM), Nissl staining, Rat hippocampus.

Abbreviatios: PTZ, pentylenetetrazol; EM, electron microscopy; kainic acid, (KA); lithium-pilocarpine, (LiPC); HS, hippocampal sclerosis; GABA, Gamma-aminobutyric acid; CNS, central nervous system; GER, granuler endoplasmic reticulum= rER, rough endoplasmic reticulum; DNA, deoksiribonucleic acid; RNA, ribonucleic acid; SE, status epilepticus; CA1, cornu ammons 1; CA2, cornu ammons 2; CA3, cornu ammons 3; GD, gyrus dentatus; DGC, dentate granule cells; MF, mossy fibers.

INTRODUCTION

The epilepsy effects more than 50 million people worldwide. It can effect all age groups and it may be the result of acute or chronic cerebral illness. Epileptic seizures begin simultaneously and several histopathological changes occur in both cerebral hemispheres. Important advances have been made in the diagnosis and treatment of seizures [1]. In epilepsy, several pathological changes typically occur in the brain, including neuronal loss, gliosis [2,3], dendritic spine degeneration [4] and abnormal synaptic reorganization [5-8]. These changes lead to abnormally increased excitability and synchronization, and eventually to the occurrence of spontaneous seizures [9-11].

It has been studied the effect of kainic acid (KA), a potent neuroexcitatory and neurotoxic analogue of glutamate, in the rat using a variety of light- and electron-microscopic techniques. The commonly affected areas include the olfactory cortex, amygdaloid complex, hippocampus, and related parts of the thalamus and neocortex [12]. Acute treatment with 30mg/kg KA did not produce major death of mouse hippocampal neurons, indicating that concentrations were not cytotoxic. Taken together, investigators' results provide new insights in the activation of several kinase-pathways implicated in cytoskeletal alterations that are a common feature of neurodegenerative diseases [13]. Sankar et al. [14] evaluated of the type of cell injury resulting from lithium-pilocarpine (LiPC) status epilepticus (SE) ultrasturucturally.

Limbic system comprises of the brain which are important for memory, emotions and cognitive functions [15]. Hippocampus is important component of this system and it is widely accepted that it plays an essential role in memory. The hippocampus is a part of the brain located inside the temporal lobe. It forms a part of the limbic system and plays a part in memory and spatial navigation. It is known that the damage to the hippocampus can also result from oxygen starvation (anoxia) and encephalitis. Reductions in neuronal cell number were indicative of an abnormal development. The developmental structural abnormalities in the hippocampus may contribute to the cognitive impairments which result from isolation rearing in rats [16].

However, our understanding of the cellular and molecular mechanisms underlying epilepsy remains still incomplete. A systemic administration of pentylenetetrazol (PTZ), an antagonist of GABA (Gamma-aminobutyric acid) receptor ion channel binding site was shown to cause generalized epilepsy in an animal model [17]. Kindling is a model of epilepsy and epileptogenesis. Repeated application of subconvulsive doses

of central nervous system (CNS) stimulants like PTZ [18] once every 24 to 48 hours over a period of time is also known to induce a permanent change in the epileptogenic sensitivity of the forebrain structures [19]. PTZ-induced seizure in rats, a relevant model of human absence and of generalized tonic-clonic epilepsy [20, 21]. So, in the present study, we also planned to examine hippocampal neurons in rat brain after the PTZ-induced epileptic seizures light and electron microscopically.

MATERIALS AND METHODS

Animals and seizure induction

Adult male Wistar albino rats were used in this study. All animals were raised in-house with a 12 hour light: 12 hour dark cycle, in a temperature-controlled environment (22±1 °C), with food and water available ad libitum. After experimental procedures were conducted in accordance with the Guidelines of Animal Experimentation of Faculty of Medicine in Kocaeli University. Twentyone rats were randomized divided into three equal number groups: 1- control group; 2-acute-PTZ group; 3-chronic-PTZ group. In the acute-PTZ group, 55 mg/kg PTZ (Sigma Chemical Cooperation) was injected intraperitoneally (i.p.) to the rats and observed epileptic activity. The animals were sacrificed 1hour later by transcardial perfusion with 0,9 % saline solution, followed by perfusion with 4% paraformaldehyde in 0.1 M phosphate buffer, under ether anesthesia. Fixed brains were removed and post-fixed overnight in the same fixative. In the chronic-PTZ group, 55mg/kg PTZ was given i.p. on alternate days for six times and seizure activity was observed. After the last injection on the sixth day, procedure was used as in the case of the acute-PTZ group. For the control group all procedures were repeated except saline injection instead of PTZ.

Histology and Light Microscopy

Fixed brains were embedded in paraffin and 5-µm sections were prepared with a microtom (Leica SM2000R, Germany). Serial paraffin sections were deparaffinized and stained with Cresyl Fast Violet (CFV) for Nissl staining and then these sections were examined by light microscope (BX50F-3; Olympus, Tokyo, Japan).

Histology and Transmission Electron Microscopy (EM)

After perfusion, hippocampi were microdissected from each rat and were post-fixed in 2% Osmium tetraoxide at 0.1 M, pH 7.4 phosphate buffer at 48C° for 1 hour, and stained with uranyl acetate during 2 hour. Later the sections were flat-embedded in Durcupan. Semi-thin (1µm) sections were first stained with CFV and screened. Hippocampal regions were selected, and ultrathin sections were cut and placed on single-hole grids. After staining with uranyl acetate and lead citrate, the sections were examined by EM (Zeiss EM-9S).

Statistical Analysis

The number of cells was quantified in $765x10^2$ μm^2 fields (counting frame) of hippocampal regions of rat brains with the X40 objective (Olympus) using a grid for determination of the sampling volume via Cavalieri method [22]. In the seven slices through hippocampus, number of neurons were examined among the acute-PTZ treated, chronic-PTZ treated and the control brains according to unbiased counting methods. The number of neurons were counted in CA1, CA3 and Gyrus dentatus (GD) regions. The mean value and S.D. were calculated in the control and PTZ-induced groups. The data were statistically analyzed using the SPSS statistical software package. All groups were compared using ANOVA. Values were expressed as the mean ± standard error (SEM).

RESULTS

Dose of 55 mg/kg PTZ induced generalised tonic-clonic seizures in acute and chronic PTZ groups. After PTZ injections, seizures started with the clonus of the facial and the forelimb muscles; seizures continued with the neck and tail extensions, loss of straightening reflex with tonic flexion-extention, wild running and usually with extented clonic activities.

Nissl substance was stained with CFV to evaluate the morphology of neurons. Normal neuronal view was observed in the hippocampal regions from the control group by light microscope; the nucleus was large in size with dispersed chromatin and prominent nucleoli and neuroplasm was basophilic due to extensive rRNA. CFV, for identifying the Nisll substance (GER) as dark blue material, revealed a granular appearance; nuclear DNA had a similar staining properties. Neurons of CA1, CA3 and GD regions from the control group appeared to be normal (Fig 1a, b, c).

A few necrotic neurons from the acute-PTZ group were seen in CA1 and CA3 regions (Fig. 2a, b). There was not significant difference between the number of CA1 and CA3 neurons in the acute-PTZ group and control group (Table 1). Necrotic neurons were seen extensively in GD region of the acute-PTZ group (Fig. 2c). There was significant difference between the number of GD neurons in the acute-PTZ group and that of control group ($p<0.001$; Table 1).

CFV showed a decreased Nissl of hippocampal neurons in the chronic-PTZ group compared to the control group. There was

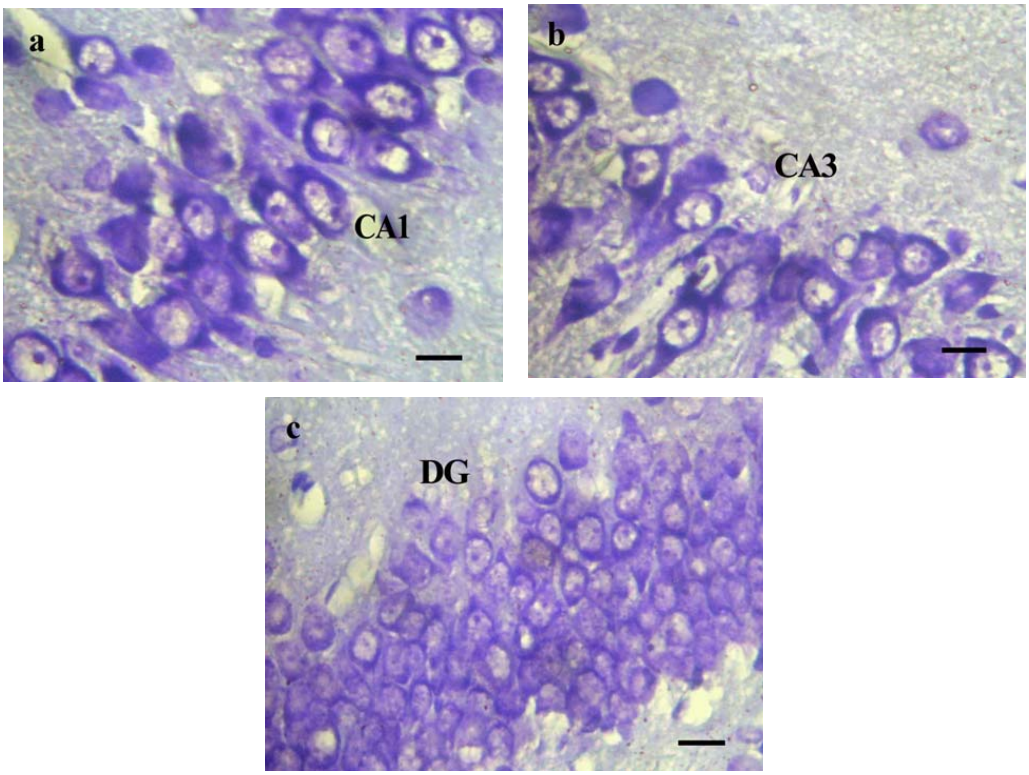

Figure 1. Photomicrographs of Nissl-stained hippocampal regions, CA1(a), CA3 (b) and DG (c) in the control group.

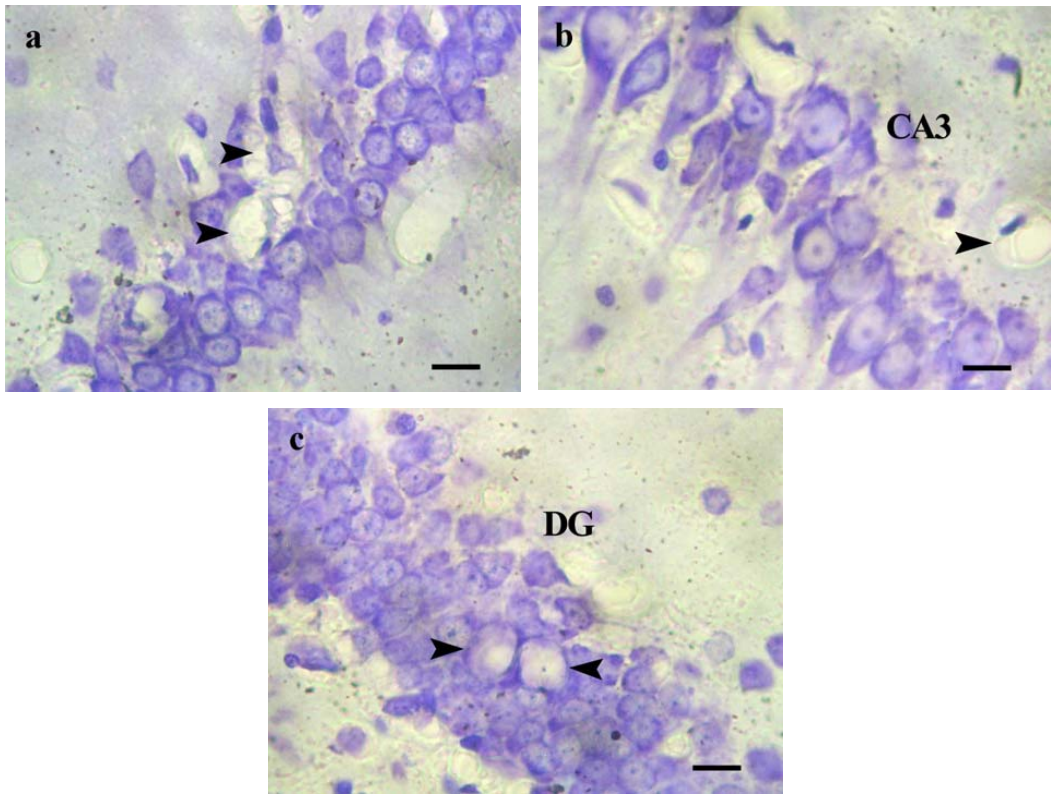

Figure 2. Photomicrographs of Nissl-stained hippocampal regions, CA1(a), CA3 (b) and DG (c) in the acute-PTZ group. Neuronal loss and thinned, sparsely staining and a breach of staining ware seen in the CA3 pyramidal cell layer (arrows in).

a characteristic view of neuronal damage in light microscopic analysis of hippocampus in the chronic-PTZ groups. In this group, both necrotic and apoptotic neurons were observed in the CA1 region (Fig. 3a). Necrotic histological changes were as follows; perikaryal swelling, chromatolysis and decreasing of Nissl. Apoptotic histological changes were perikaryal shrinking and dark nucleus. There was significant difference between the numbers of CA1 neurons in the chronic-PTZ group and that of control group ($p<0.001$; Table 1). Neuronal loss were observed with resultant narrowing, sparse staining and a breach of continuity of staining in the CA1 region from the chronic-PTZ group (Fig. 3b). In the CA3 region of chronic-PTZ group, both a few necrotic and apoptotic neurons were observed (Fig. 3c).

Table 1. Number of neurons in the hippocampal regions of the control, acute- and chronic-PTZ group. Neurons were counted in the $765x10^2$ μm^2 fields of coronal sections (* $p< 0.001$).

Groups	CA1	CA3	DG
Control group	126.43±1 9.321	70.571±48 .938	208.14±14 .276
Acute-PTZ group	120±18.5 56	66.714±46 .804	192.43±19 .025*
Chronic-PTZ group	84.162±7 .7766*	58.286±40 .211	121.43±12 .843*

There was no significant difference between the numbers of CA3 neurons from the experimental groups and that of control group (Table 1). In the chronic-PTZ group, both necrotic and apoptotic neurons were observed extensively in the GD region (Fig. 3d). There was significant difference between the number of GD neurons in the chronic-PTZ group and control group ($p<0.001$; Table 1).

Hippocampal CA1 sections were examined to evaluate transmission EM in all groups. The ultrastructural appearance of the cytoplasmic organelles and nuclear components of CA1 neurons was normal in the control group (Fig. 4a). Necrotic neurons were seen rarely in CA1 region of the acute-PTZ group at lower magnification. Necrotic degenerative changes were deformation of nuclear and perikaryal outlines, dilatation of the cistarnae of endoplasmic reticulum at higher magnification (Fig. 4b). In the chronic-PTZ group both necrotic and apoptotic neurons were observed in the CA1 region at lower magnification. EM revealed that dying neurons at the CA1 region showed an apoptotic cells with the regularly shaped, round clumps of condensed chromatin with preservation of nuclear membrane continuity, and cell body shrinkage (Fig. 4c). This feature could be distinguished from the signs of necrosis in CA1, including over swelling, cytolysis, and pyknotic nucleus with irregular contour of the chromatin (Fig. 4b). These types of necrotic cells were observed in hippocampus of the chronic-PTZ group.

DISCUSSION

In this study, systemic injections of 55 mg/kg PTZ produced a high incidence of convulsions, and wild running. Yonekawa et al. [23] have studied **r**elationship between PTZ-induced seizures and brain PTZ levels in mice. PTZ is often used in experimental models of epilepsy. In their study examined this relationship and

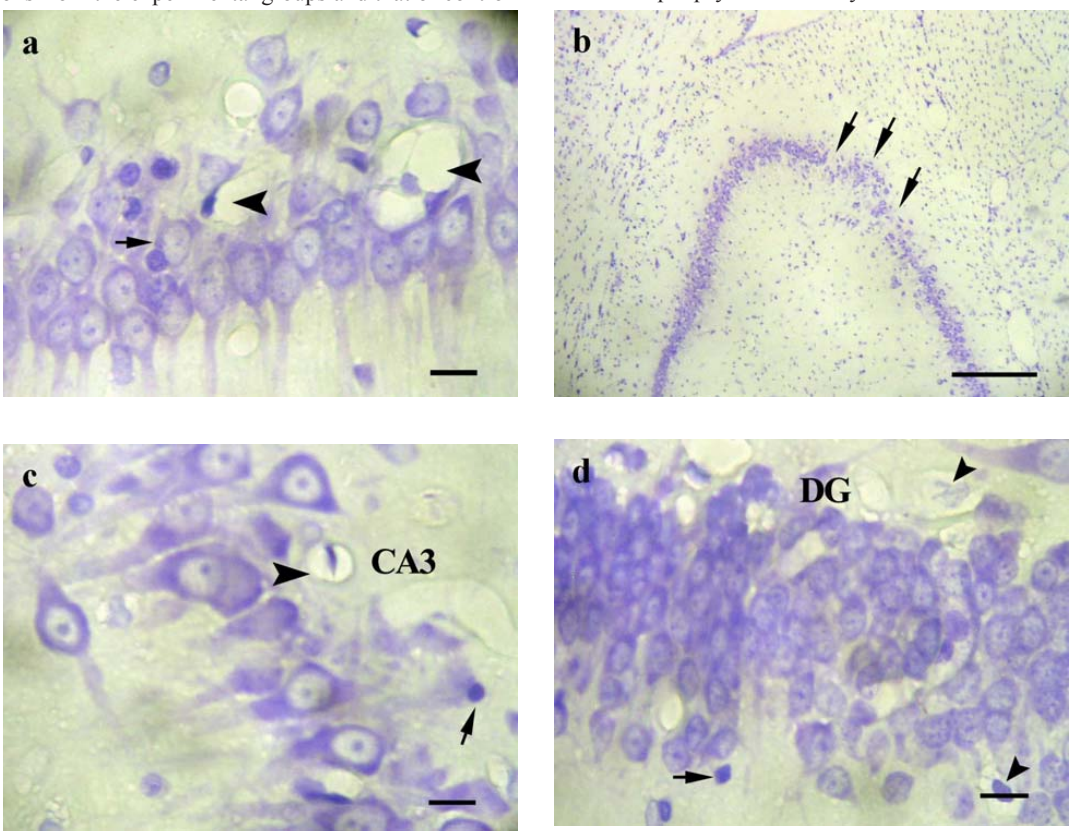

Figure 3. Photomicrographs of Nissl-stained hippocampal regions, CA1(a), CA3 (b) and DG (c) in the chronic-PTZ group. Neuronal loss and thinned, sparsely staining and breach of staining are seen in the CA3 pyramidal cell layer (arrows in).

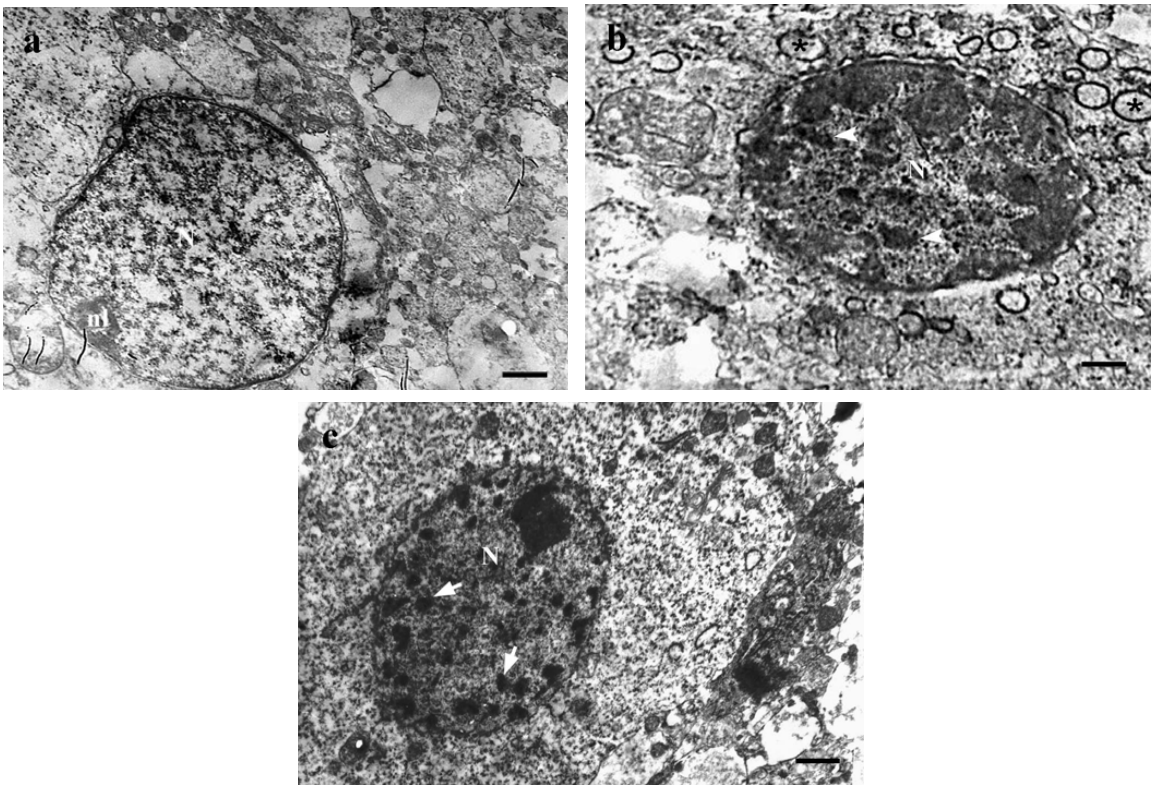

Figure 4. Electron micrographs of hippocampal neurons in the control (a), acute- (b) and chronic-PTZ (c) groups. In a normal CA1 pyramidal neuron of control group, Nucleus (N) is euchromatic and exhibiting normal cytoplasmic features (a). Necrotic features (b), i.e., numerous small vacuoles throughout the cytoplasm as well as disruption of plasma membrane and a pyknotic nucleus with irregular contour of the chromatin clumps (arrowheads in) were seen the acute-PTZ group (b). In the chronic-PTZ group, CA1 neuron displayed apoptotic-like features such as chromatin condensation into a few round clumps (arrows in) and condensation of a relatively intact cytoplasm with preservation of plasma membrane (c)

determined how different routes of PTZ administration affected brain PTZ uptake and seizure development. The critical brain PTZ level for onset of clonus ranged from 20 to 50 microg/g. This dose of PTZ was same with our experimental porcesses.

Seizures activity is associated with neuronal damage. Both necrotic and apoptotic forms of cell death contribute to brain damage in the PTZ-induced epilepsy model. One of the most common stains used for nervous system tissues is CFV method, which binds very strongly to the RNA in the neuron's GER (rER), since it's a basic stain [24, 25]. Therefore, CFV is a specific stain to show the GER in the neurons. It imparts a light violet color to the GER. This stain gives a diffused coloration when the GER is less and spread out, and imparts a granular appearance when the GER is abundant [26]. Perikaryal injury in cytoplasmic swelling and degranulation of ribosomes from the GER. This loss of RNA is seen as disappearance of cytoplasmic basophilia which is called chromatolysis. Necrotic and apoptotic neurons were observed in the chronic-PTZ treated group. Necrosis was observed extensively in the brains of the chronic-PTZ animals.

Nadler et al. [27] have used intraventricular injections of KA to destroy the hippocampal CA3-CA4 cells, thus denervating the inner third of the molecular layer of the fascia dentata and stratum radiatum and stratum oriens of area CA1. Their results showed a preferential ordering in the reinnervation of dentate granule cells (DGCs) which was not readily explained by proximity to the degenerating fibers and also that removal of CA3-CA4-derived innervation more readily elicits translaminar growth in the fascia dentata than in area CA1. These results might be relevant to clinical situations in which neurons of the hippocampal end-blade were lost. Nadler et al. [28] have studied that degeneration of hippocampal CA3 pyramidal cells was investigated by light- and electron-microscopy after intraventricular injection of the potent convulsant, KA. EM revealed evidence of pyramidal cell degeneration within one hour. The earliest degenerative changes were confined to the cell body and proximal dendritic shafts. These included an increased incidence of lysosomal structures, deformation of the perikaryal and nuclear outlines, some increase in back ground electron density, and dilation of the cisternae of the endoplasmic reticulum accompanied by detachment of polyribosomes. Within the next few hours the pyramidal cells atrophied and became electron dense. Then these cells became electron lucent once more as ribosomes disappeared and their membranes and organelles broke up and disintegrated. The dendritic spines and the initial portion of the dendritic shaft became electron dense within four hours and degenerated rapidly, whereas the intermediate segment of the dendrites swelled moderately and became more electron lucent. . We also a few necrotic neurons from the acute-PTZ group were seen in the CA3 regions. Our findings were similar to Nadler et al. [28]. We also observed necrotic degenerative changes including the deformation of nuclear and perikaryal outlines, dilatation of the cistarnae of endoplasmic reticulum in the acute-PTZ group. In the chronic-

PTZ group, both a few necrotic and apoptotic neurons were observed in the CA3 regions. But we did not determined significant difference in the number of neurons in the CA3 region in the acute- and chronic-PTZ groups.

Schwob et al. [12] have studied the effect of systemic and intracerebral injections of KA, a potent neuroexcitatory and neurotoxic analogue of glutamate, in the rat using a variety of light- and electron-microscopic techniques. The initial neuropathological reactions include dendritic and glial dilatations in discrete areas of the neuropil; affected neuronal somata either appear swollen and pale, or are shrunken with dark cytoplasm. In the most severely affected areas, the lesion progresses to severe disruption of the neuropil. The commonly affected areas include the olfactory cortex, amygdaloid complex, hippocampus, and related parts of the thalamus and neocortex. Intracerebral injections of 2–6 nmol produce extensive neuronal damage in distant structures, as well as at the injection site. The pattern of distant damage varies with the site of the injection and appears to reflect axonal connections between the affected areas near the injection and the distant areas of damage. Injections into the posterior part of the olfactory cortex which involve the entorhinal cortex (EC) tend to produce severe degeneration in field CA1 of the hippocampus, although field CA3 is more severely damaged following intraventricular, intrahippocampal or intrastriatal injections.

Du et al. [29] have obtained specimens EC during the surgical treatment of intractable partial seizures and were studied by light microscopy in Nissl-stained sections. A distinct loss of neurons was observed in the anterior portion of the medial EC in the absence of apparent damage to temporal neocortical gyri. These observations provided neuropathological evidence for an involvement of the EC in temporal lobe epilepsy (TLE). Since the EC occupies a pivotal position in gating hippocampal input and output, their results further support previous suggestions that dysfunction of this region may contribute, either independently or in concert with Ammon's horn sclerosis, to epileptogenesis in humans. Du et al. [30] have examined the EC in three established rat models of epilepsy using Nissl staining. Adult male rats were either electrically stimulated in the ventral hippocampus for 90 minute or injected with KA or LiPC. At 24 hour, all animals that had exhibited a bout of acute SE showed a consistent pattern of neuronal loss in the EC in Nissl-stained sections. We also determined neuronal loss in hippocampal GD at 24 hours in Nissl stained sections of the acute-PTZ group. Du et al. [30] have also seen an identical pattern of nerve cell loss in the EC of rats killed 4 weeks following the treatments. This lesion was completely prevented by an injection of diazepam and pentobarbital, given one hour after KA administration. Taken together, these experiments indicated that prolonged seizures caused a preferential neuronal loss in layer III of the medial EC and that this lesion might be related to a pathological elevation of intracellular calcium ion concentrations.

Isokawa [4] has determined that dendritic degeneration was a common pathology in TLE and its animal models. In the study of the rat pilocarpine model, visualization of dendrites of the hippocampal DGCs by biocytin revealed a generalized spine loss immediately after the acute seizure induced by pilocarpine. The present finding suggests that initial acute seizures do not cause permanent damages in dendrites and spines of DGCs; instead, dendritic spines were dynamically maintained in the course of the establishment and maintenance of spontaneous seizures. Local dendritic spine degeneration, detected later in the chronic phase of epilepsy, was likely to have a separate cause from initial acute insults. We also detected both apoptotic and necrotic neurons ultrastructurally.

Eid et al. [31] have been studied in the animals also develop hyperexcitability of the EC and the hippocampal region CA1. Pathologically swollen dendrites and electron-dense neuronal profiles were present in the lesioned sector as well. The majority of the electron-dense profiles was identified as degenerating dendritic spines that were closely apposed to strongly glutamate-immunopositive axon terminals. These findings might be of relevance for the genesis and spread of temporal lobe seizures. Clinical, radiologic, and experimental evidence indicated that the EC region might be linked to the pathophysiology of hippocampal sclerosis (HS) in patients with TLE [29,32, 33].

Morphological analysis of hippocampal formation after pilocarpine-induced SE showed increased glucose utilization in most brain regions including hippocampus during the period of continuous seizure activity [34] and an extensive loss of neurons within the hilar area of the GD [6, 35], as well as loss of interneurons in CA1, CA3 and hilus [35]. In our study we also determined a significant neuronal loss in CA1 region of the chronic-PTZ group compared with the control group. We determined significant difference between the numbers of CA1 neurons in the chronic-PTZ group and control group ($p<0.001$; Table I).

Chandler et al. [36] have observed that loss of interneurons could undoubtedly contribute to a decrease in GABA release. Several neurotransmitters, also including GABA, modulate glutamate release at synapses between hippocampal mossy fibers (MFs) and CA3 pyramidal neurons. Hilar mossy cells loss directly resulted in granule cell hyperexcitability [37, 38]. Impaired GABAergic inhibition might contribute to the development of hyperexcitability in epilepsy. Thus, decrease of GABA which an inhibitory neurotransmitter leaded to remove sinaptic inhibition on epileptic neurons and leaded to epilepsy seizures by making neurons easily exitable. Heterotopic granule cells exhibit features often have been observed in epileptic tissue. Granule cell dispersion in the GD, similar to that seen in human epileptic hippocampi has also been observed in animal models of epilepsy, e.g., after KA injection into the dorsal hippocampus [39, 40] and in the pilocarpine model.

The distribution of granule cells in the GD of the hippocampal formation has been studied in control autopsy and TLE specimens. Results contributed to the altered circuitry of the hippocampal formation in TLE [41] and Houser [42] stated that the neuronal loss and synaptic reorganization in TLE. It has remained unclear whether the appearance of heterotopic granule cells is related to granule cell loss in the epileptic hippocampus. Granule cell dispersion has not been observed when cell loss is minimal [43]. We also determined decreased number of neurons in GD region in the acute- and the chronic-PTZ groups.There was significant difference between the number of GD neurons in the acute- and chronic-PTZ group ($p<0.001$).

Brevard et al. [21] have stated that GD was twice as active as other hippocampal areas but peaked just before seizure onset in the PTZ-induced seizure in rats. Neurons in this area might contribute to the neural network controlling the initiation of generalized tonic-clonic seizure. Some studies have also been shown that MFs were decreased in epilepsy. It is suggested that sprouting of MFs or their axon collaterals has occurred in hippocampal epilepsy and that the reorganized fibers contain at least one of the neuropeptides that are normally present in this system. Such fibers could form recurrent excitatory circuits and contribute to synchronous firing and epileptiform activity, as suggested in studies of experimental models of epilepsy [44]. Hippocampal MFs represented a major input from DGCs to the hippocampal CA3 field. They exhibit several forms of presynaptic modulation of transmitter release, including marked short-term [45] and long-term [46] use-dependent plasticity. They are sensitive to several neurotransmitters that depress transmitter release, including glutamate [47] , GABA [48, 49], and peptides [50] acting on metabotropic receptors. MF transmission might be under such profound modulation because hippocampal principal cells are highly vulnerable to excitotoxicity [51]. Nevertheless, these modulatory mechanisms could break down: excessive activity in the DG can spread into the hippocampus and can result in neuronal loss that resembles similar to that seen after KA administration [52, 53]. An anatomic and neurobiologic study revealed functional abnormalities in the GD of epileptic KA-treated rats; however, lateral inhibition persists, suggesting that vulnerable hilar neurons were not necessary for generating lateral inhibition in the GD [54, 55]. Histological and quantitative stereological techniques were used to estimate numbers of neurons per GD of various classes and to estimate the extent of granule cell axon reorganization along the septotemporal axis of the hippocampus in control rats and epileptic KA-treated rats. Findings from the GD of epileptic KA-treated rats were strikingly similar to those reported for human TLE, and it was suggested that neuron loss and axon reorganization in the temporal hippocampus might be important in epileptogenesis [56]. Failure of modulation of MF transmission might also contributed to the delayed development of spontaneous seizures [36]**.** In their study, Sloviter et al. [57] in chronically epileptic rats demonstrated that DGCs were maximally hyperexitabl immediately after SE, prior to MF sprouting, and that synaptic reorganization following KA-induced injury was temporally associated with GABA (A) receptor-dependent granule cell hyper-inhibition rather than a hypothesized progressive hyperexitability. Mortazavi et al. [58] have revealed that neuronal loss in the CA1 area and increased MF sprouting in the GD were similar to what was observed in human epilepsy. These results indicated that PTZ kindling provides a useful model of postseizure dysfunction, which can serve as a screen for potential treatments for those cognitive, emotional, and neuropathological deficits that resemble those symptoms observed in human epilepsy.

In our study, hippocampal CA1 sections were examined in transmission EM samples of the control and PTZ-induced animals. According to ultrastructural appearance of the neuroplasm and nucleus, we determined that repeated-PTZ injections caused both necrotic and apoptotic neuronal death in CA1 region of hippocampus in the chronic-PTZ group. A few dying neurons were seen in the apoptotic morphology as described by Portera-Cailliau et al. [59, 60], in the PTZ-induced groups. This feature could be distinguished from the signs of necrosis in CA1, including overt swelling, cytolysis, and pyknotic nucleus with irregular contour of the chromatin. In the another study [61] showed that cell loss was relatively uniform after ibotenic acid injections into areas CA1 and CA3 and variable after colchicine injections into GD. CA1 and CA3 lesions appeared mostly localized to those relative subregions, and DG lesions appeared highly localized to the GD. Pavlova et al. [62] have suggested that, in PTZ kindling model, oxidative damage of neurons resulting in neurodegeneration in hippocampus was not directly related to the convulsive activity. PTZ-kindling in rats has been induced moderate neuronal cell loss in hippocampal fields CA1-4, and DG. They have suggested that PTZ-kindling might be a suitable model to study the mechanisms of seizure-induced neuronal death. Neuron death in the hippocampus is also accompanied by increases in oxidative stress, this also being independent of the external manifestations of brain seizure activity.

CONCLUSION

While necrotic neurons of CA1 and CA3 regions were rarely seen, these cells were observed extensively in GD region in the acute-PTZ group. There was significant difference between the number of GD neurons in the acute-PTZ group and that of control group ($p<0.001$). CFV showed a decreased Nissl of the hippocampal neurons in the chronic-PTZ group compared to the control group. In the chronic-PTZ group, both necrotic and apoptotic neurons were observed in the CA1 region. There was significant difference between the numbers of CA1 neurons in the chronic-PTZ group and that of control group ($p<0.001$). In the chronic-PTZ group, both necrotic and apoptotic neurons were observed in the GD region extensively. There was significant difference between the number of GD neurons in the control and chronic-PTZ group ($p<0.001$). According to the ultrastructural appearance of the cytoplasmic organelles and nuclear components of CA1 regions a few necrotic neurons was seen in the acute-PTZ group. Both necrotic and apoptotic neurons of the CA1 region were observed in the chronic-PTZ group. EM revealed that dying neurons at the CA1 region showed an apoptotic cells. These types of necrotic cells were observed in hippocampus of the chronic-PTZ group. The outcome of continuation of epilepsia seizures in the chronic-PTZ group was loss of hippocampal neurons with the decrease of GD and CA1 neurons. These finding might be result of excitocytotoxic sensitivity of these neurons especially. A decreasing in the numbers of CA1 neurons was determined only in the chronic-PTZ group. However, PTZ injections cause a decreasing of GD neurons in both acute- and chronic-PTZ groups. Our results showed that chronic-PTZ seizures cause neuronal degeneration and neuronal loss of hippocampus.

Acknowledments

This work was supported by a Grant from the Scientific Research Fund of Kocaeli University (Project # 1999/09), Turkey

REFERENCES

[1]. Benbadis SR. 2001. Epileptic seizures and syndromes. *Neurology Clinical*, 19:251-270.

[2]. Penfield, W. 1929. The mechanisms of cicatricial contraction in the brain. *Brain,* 50, 499–517.

[3]. Steward, O., Torre, E. R., Tomasulo, R., & Lothman, E. 1991. Neuronal activity up-regulates astroglial gene expression. *Proceedings of the National Academy of Sciences*, USA 88(15):6819– 6823.

[4]. Isokowa M. 1998. Remodeling dendritic spines in the rat pilocarpine model of temporal lobe epilepsy. *Neuroscience Letter*, 18;258(2), 73-6.

[5]. Babb, TL, Kupfer, WR, Pretorius, JK, Crandall, PH & Levesque, MF.1991. Synaptic reorganization by mossy fibers in human epileptic fascia dentata. *Neuroscience* 42: 351-363.

[6]. Mello LEAM, Cavalheiro EA, Tan AM, Kupfer WR, Pretorius JK, Babb TL & Finch DM. 1993. Circuit mechanisms of seizures in the pilocarpine model of chronic epilepsy: cell loss and mossy fiber sprouting. *Epilepsia,* 34:985-995.

[7]. Leite JP, Babb TL, Pretorius JK, Kulhman PA, Yeoman KM & Mathern GW. 1996. Neuronal loss, mossy fiber sprouting, and interictal spikes after intrahippocampal kainate in developing rats. *Epilepsy Research*, 26, 219-231.

[8]. Xiang-ming Zha, Steven H. Green & Michael E. Dailey. 2005. Regulation of hippocampal synapse remodeling by epileptiform activity. *Molecular and Cellular Neuroscence*, 29 494–506.

[9]. Cavalheiro AE, Leite JP, Bortolotto ZA, Turski WA, Ikonomidou C & Turski L. 1991. Long-term effects of pilocarpine in rats: structural damage of the brain triggers kindling and spontaneous recurrent seizures. *Epilepsia*, 32: 778-782

[10]. Isokawa M. & Mello LEAM. 1991. NMDA receptor-mediated excitability in dendritically deformed dentate granule cells in pilocarpine-treated rats. *Neuroscience Letter*, 129, 69-73.

[11]. Bothwell, S., Meredith, G.E., Phillips, J., Staunton, H., Doherty, C., Grigorenko, E., Glazier, S., Deadwyler, S.A., O'Donovan, C.A. & Farrell, M. 2001. Neuronal hypertrophy in the neocortex of patients with temporal lobe epilepsy. *The Journal of Neuroscience*, 21, 4789–4800.

[12]. Schwob JE, Fuller T, Price JL & Olney JW. 1980. Widespread patterns of neuronal damage following systemic or intracerebral injections of kainic acid: a histological study. *Neuroscience,* 5:991-1014

[13]. Crespo-Biel N, Canudas AM, Camins A, Pallas M. 2006. Kainate induces AKT, ERK and cdk5/GSK3beta pathway deregulation, phosphorylates tau protein in mouse hippocampus. *Neurochem Int.* Nov 18; [Epub ahead of print].

[14]. Sankar R, Shin D, Liu H, Wasterlain C & Mazarati A. 2002. Epileptogenesis during development:injury, circuit recruitment and plasticity. Epilepsia, 43(Suppl. 5):47-53.

[15]. Wen HT, Rhoton AL Jr, de Oliveira E, Cardoso AC, Tedeschi H, Baccanelli M, Marino R Jr. 1999. Microsurgical anatomy and its vascular relationships as applied to amygdalohippocampectomy. *Neurosurgery,* (45):549-591. [41].

[16]. Bianchi M, Fone KF, Azmi N, Heidbreder CA, Hagan JJ, Marsden CA. 2006. Isolation rearing induces recognition memory deficits accompanied by cytoskeletal alterations in rat hippocampus. Eur J Neurosci. 20; [Epub ahead of print]

[17]. Ahmed MM, Arif M, Chikuma T, Kato T. 2005. Pentylenetetrazol-induced seizures affect the levels of prolyl oligopeptidase, thimet oligopeptidase and glial proteins in rat brain regions, and attenuation by MK-801 pretreatment. Neurochem Int. 47(4):248-59.

[18]. Corda MG, Orlandi M, Lecca D, Giorgi O. 1992. Decrease in GABAergic function induced by pentylenetetrazol kindling in rats:antagonism by MK-801. *J Pharmacol Exp Ther* 262:792-800.

[19]. Khanna, Bhalla S, Verma V, Sharma KK. 2000. Modulatory Effectes of Nifedipine and Nimodipine in Experimental Convulsions. *Indian Journal of Pharmacology* 2000; 32: 347-352.

[20]. Commission on Classification and Terminology of the International League against Epilepsy (ILE). 1989. Proposal for revised classification of epilepsies and epileptic syndromes. *Epilepsia,* 30(4):389-399.

[21]. Brevard ME, Kulkarni P, King JA, Ferris CF. 2006. Imaging the neural substrates involved in the genesis of pentylenetetrazol-induced seizures. Epilepsia. 2006 Apr;47(4):745-54

[22]. Michel RP & Cruz-Orive LM. 1988. Application of the Cavalieri principle and vertical sections method to lung: estimation of volume and pleural surface area. J Microsc, 150(Pt 2):117-36.

[23]. Yonekawa WD, Kupferberg HJ & Woodbury DM. 1980. Relationship between pentylenetetrazol-induced seizures and brain pentylenetetrazol levels in mice. The Journal of Pharmacology and Experimental Therapeutics, 214, (3):589-593.

[24]. Chan K and Lowe J: Techniques in neuropathology. Chapter: 18, Edited by: Bancroft JD and Gamble M. *Theory and Practice of Histological Techniques*.(5 th ed). Churchill Livingstone. New York, Edinburgh, London, Madrid, Melbourne, San Francisco, Tokyo.2002; 374-75.

[25]. Damjanov I. Histopathology. A color atlas and textbook. Chapter 19. Nervous system. International edition. Williams and Wilkins, 1996; pp. 459-490.

[26]. Young, B. & Health, J.W. Nervous Tissue. *Wheaters functional histology-A text and color atlas.* Churchill Livingstone London. 2000; pp.116-143.

[27]. Nadler JV, Perry BW & Cotman CW. 1980a. Selective reinnervation of hippocampal area CA1 and the fascia dentata after destruction of CA3-CA4 afferents with kainic acid. *Brain Research,* 182, 1–9.

[28]. Nadler JV, Perry BW, Gentry C, Cotman CW. 1980b. Degeneration of hippocampal CA3 pyramidal cells induced by intraventricular kainic acid. *J Comp Neurol*. 15;192(2):333-59.

[29]. Du F, Whetsell Jr WO, Abou-Khalil B, Blumenkopf B, Lothman EW & Schwarcz R. 1993. Preferential neuronal loss in layer III of the entorhinal cortex in patients with temporal lobe epilepsy. *Epilepsy Research,*16, 223-233.

[30]. Du F, Eid T, Lothman EW, Köhler C & Schwarcz R. 1995. Preferential neuronal loss in layer III of the medial entorhinal cortex in rat models of temporal lobe epilepsy. *The Journal of Neuroscience,* 15, 6301-6313.

[31]. Eid T, Schwarcz R & Ottersen OP. 1999. Ultrastructure and immunocytochemical distribution of GABA in layer III of the rat medial entorhinal cortex following aminooxyacetic acid-induced seizures. *Experimental Brain Research,*125, 463-475.

[32]. Du F & Schwarcz R. 1992. Aminooxyacetic acid causes selective neuronal loss in layer III of the rat medial entorhinal cortex. *Neuroscience Letter,* 147, 185-188

[33]. Dawodu S. & Thom Maria. 2005. Quantitative neuropathology of the entorhinal cortex region in patients with hippocampal sclerosis and temporal lobe epilepsy. *Epilepsy*, 46(1), 23-30.

[34]. Clifford DB, Olney JW, Maniotis A, Collins RC & Zorumski CF. 1987. The functional anatomy and pathology of lithium-pilocarpine and high-dose pilocarpine seizures. *Neuroscience,* 23, 953-968.

[35]. Cavalheiro AE. 1995. The pilocarpine model of epilepsy. *Italy Journal of Neurological Sciences*, 16, 33-37.

[36]. Chandler KE, Alessandra P. Princivalle, Ruth Fabian-Fine, Norman G. Bowery, Dimitri M. Kullmann & Matthew C. Walker. 2003. Plasticity of $GABA_B$ Receptor-Mediated Heterosynaptic Interactions at Mossy Fibers After Status Epilepticus. *The Journal of Neuroscience*, 23(36), 11382-11391.

[37]. Toth Z, Hollrigel GS, Gorcs T & Soltesz I. 1997. Instantaneous perturbation of dentate interneuronal networks by a pressure wave-transient delivered to the neocortex. *The Journal of Neuroscience*, 17:8106-8117

[38]. Santhakumar V, Ratzliff AD, Jeng J, Toth K & Soltesz I. 2001. Long-term hyperexcitability in the hippocampus after experimental head trauma. *Annals of Neurology*, 50, 708-717.

[39]. Cavalheiro EA, Riche D & Le Gal La Salle G. 1982. Long-term effcts of intrahippocampal kainic acid injection in rats: a method for inducing spontaneous recurrent seizures. *Electroencephalography and Clinical Neurophysiology,* 53,581-589

[40]. Ben-Ari Y. 1985. Limbic seizures and brain damage produced by kainic acid: Mechanisms and relevance to human temporal lobe epilepsy. *Neuroscience,* 14, 375–403.

[41]. Houser CR. 1990. Granule cell dispersion in the dentate gyrus of humans with temporal lobe epilepsy. *Brain Res.* 10, 535(2):195-204

[42]. Houser CR. 1999. Neuronal loss and synaptic reorganization in temporal lobe epilepsy. *Advances in neurology*, 79, 743-761.

[43]. Lurton D, Sundstrom L, Brana C, Bloch B & Rougier A. 1997. Possible mechanisms inducing granule cell dispersion in humans with temporal lobe epilepsy. *Epilepsy Research*, 26, 351-361.

[44]. Houser, CR, Miyashiro, JE, Swartz, BE, Walsh, GO, Rich, JR & Delgado-Escueta, AV. 1990. Altered patterns of dynorphin immunoreactivity suggest mossy fiber reorganization in human hippocampal epilepsy. *The Journal of Neuroscience,*1:267-282.

[45]. Salin PA, Scanziani M, Malenka RC & Nicoll RA. 1996. Distinct short-term plasticity at two excitatory synapses in the hippocampus. *Proceedings of the National Academy of Sciences*, USA 93, 13304-13309.

[46]. Harris EW & Cotman CW. 1986. Long-term potentiation of guinea pig mossy fiber responses is not blocked by *N*-methyl-D-aspartate antagonists. *Neuroscience Letter*, 70, 132-137.

[47]. Kamiya H, Shinozaki H & Yamamoto C. 1996. Activation of metabotropic glutamate receptor type 2/3 suppresses transmission at rat hippocampal mossy fibre synapses. *The Journal of Physiology (London),* 493: 447-455.

[48]. Min MY, Rusakov DA & Kullmann DM. 1998. Activation of AMPA, kainate, and metabotropic receptors at hippocampal mossy fiber synapses: role of glutamate diffusion. *Neuron*, 21, 561-570.

[49]. Vogt KE & Nicoll RA. 1999. Glutamate and gamma-aminobutyric acid mediate a heterosynaptic depression at mossy fiber synapses in the hippocampus. *Proceedings of the National Academy of Sciences,* USA 96, 1118-1122.

[50]. Weisskopf MG, Zalutsky RA & Nicoll RA. 1993. The opioid peptide dynorphin mediates heterosynaptic depression of hippocampal mossy fibre synapses and modulates long-term potentiation. *Nature,* 365, 188.

[51]. Meldrum BS. 1993. Excitotoxicity and selective neuronal loss in epilepsy. *Brain Pathology*, 3:405-412.

[52]. Sloviter RS. 1987. Decreased hippocampal inhibition and a selective loss of interneurons in experimental epilepsy. *Science*, 235:73-76.

[53]. Sloviter RS. 1991. Feedforward and feedback inhibition of hippocampal principal cell activity evoked by perforant path stimulation: GABA-mediated mechanisms that regulate excitability in vivo. *Hippocampus.* 1(1):31-40.

[54]. Buckmaster PS & Dudek FE. 1997a. Network properties of the dentate gyrus in epileptic rats with hilar neuron loss and granule cell axon reorganization. *Journal of Neurophysiology,* 77, 2685–2696.

[55]. Buckmaster PS & Dudek FE. 1997b. Neuron loss, granule cell reorganization, and functional changes in the dentate gyrus of epileptic kainatetreated rats. *Journal of Comparative Neurology*, 385– 404.

[56]. Buckmaster PS, Jongen-Relo AL. 1999. Highly specific neuron loss preserves lateral inhibitory circuits in the dentate gyrus of kainate-induced epileptic rats. *The Journal of Neuroscience*, 1999; 19: 9519-9529.

[57]. Sloviter RS, Zappone CA, Harvey BD, Frotscher M. 2006. Kainic acid-induced recurrent mossy fiber innervation of dentate gyrus inhibitory interneurons: possible anatomical substrate of granule cell hyper-inhibition in chronically epileptic rats. J Comp Neurol. 20;494(6):944-60.

[58]. Mortazavi F, Ericson M, Story D, Hulce VD, Dunbar GL. 2005. Spatial learning deficits and emotional impairments in pentylenetetrazole-kindled rats. Epilepsy Behav. 7(4):629-38. Epub, 24.

[59]. Portera-Cailliau C, Price DL, Martin LJ. 1997. Excitotoxic neuronal death in the immature brain is an apoptosis-necrosis morphological continuum. *J Comp Neurol.* 3; 378(1):70-87

[60]. Portera-Cailliau C, Price DL, Martin LJ. 1997. Non-NMDA and NMDA receptor-mediated excitotoxic neuronal deaths in adult brain are morphologically distinct: further evidence for an apoptosis-necrosis continuum. J Comp Neurol. 378(1):88-104.

[61]. Jerman TS, Kesner RP, Lee I, Berman RF. 2005. Patterns of hippocampal cell loss based on subregional lesions of the hippocampus. *Brain Research* 1065:1 – 7.

[62]. Pavlova TV, Yakovlev AA, Stepanichev MIu, Guliaeva NV. 2006. Pentylenetetrazol Kindling in Rats: Is Neurodegeneration Associated with Manifestations of Convulsive Activity? *Neuroscience and Behavioral Physiology*, 36(7):741-48.