J Turgut Ozal Med Cent 2017;24(1):69-71
CASE REPORT DOI: 10.5455/jtomc.2016.06.074

A Forgotten reason of dysphagia "Forestier syndrome"

Serhat Yaslikaya[1], Ahmet Kizilay[2]

[1]Kanuni Sultan Süleyman Education and Research Hospital Department of Otorhinolaryngology, İstanbul, Turkey
[2]İnönü University Faculty of Medicine Department of Otorhinolaryngology, Malatya, Turkey

Abstract
Forestier syndrome or diffuse idiopathic skeletal hyperostosis is a chronic disease characterized by diffuse formation of osteophytes on the spine that increase with age and occur as a result of enchondral ossification of paravertebral ligaments and muscles. The exact etiology of disease is not known. It is more common in males and usually it occurs over sixty-five years of age. Stiffness, limitation of movement, and spinal pain is seen frequently in patients. Foreign body sensation in the throat, odynophagia, disphagia, hoarseness, stridor, obstructive sleep apnea, and otalgia can be found according to location and size of the pathology. Exact diagnosis can be reached with radiological imaging methods. In early stage and symptomatic cases, physiotherapy, training, and medical treatment may be sufficient. In patients with advanced disease who do not benefit from these treatments, surgery can be performed.

Keywords: Osteophyte; Cervical; Odynophagia; Physiotherapy.

INTRODUCTION

Forestier syndrome or diffuse idiopathic skeletal hyperostosis (DISH) is a chronic disease characterized by diffuse formation of osteophytes on the spine that occur as the result of enchondral ossification of paravertebral ligaments and muscles and increases with aging. Firstly it has been described by Forestier and Rotes-Querol in 1950 (1). In 1975, this disease was named as DISH by Resnick and this definition is often used today (2). However apart from these definitions, different definitions are also available such as spondylosis hyperostotica, spondylitis ossificans ligamentosa, senile ankylosing hyperostosis (3). The exact etiology of disease is unknown. Usually paraspinal ligaments and especially anterior longitudinal ligaments are affected (4). It is more common in males and it occurs 5-10% over sixty-five years of age. Most commonly thoracic vertebrae afterward lumbar vertebrae, and cervical vertebrae are affected (5). Spinal pain, and stiffness, limitation of movement is seen frequently in patients but they can be diagnosed with coincidental with no symptoms also. Dysphagia has been reported in 28% of patients with Forestier syndrome and it is thought to be associated with cervical osteophytes (6). Foreign body sensation in the throat, odynophagia, dysphagia, hoarseness, stridor, obstructive sleep apnea, and otalgia can be found according to location and size of the pathology (7).

In our work, a case with complaints of throat pain, and dysphagia which was diagnosed with Forestier syndrome is presented.

Received: 12.07.2016
Accepted: 09.08.2016

Corresponding Author
Serhat Yaslıkaya
Kanuni Sultan Süleyman Education and Research Hospital Department of Otorhinolaryngology, İstanbul, Turkey.
E-mail: dr.yaslikaya@gmail.com

CASE REPORT

A 85 year-old male patient admitted to our clinic with complaints of throat pain, foreign body sensation in the throat, and difficulty in swallowing that continued for three months. From the endoscopic examination of the patient, the nasal cavities, nasopharynx, and oropharynx were seen regular, but in hypopharynx and larynx examination, on the midline a submucosal tumor like pathology which is occurring from postcricoid area and extending to superior part of the arytenoid cartilages and narrowing the entrance of larynx was detected (figure 1).

There were no pathologic findings in the neck examination of the patient. A magnetic resonance imaging (MRI) of the neck was performed to distinguish whether the pathology was a tumor or not. In the MRI on sagittal plane, especially between the anterior parts of the C3-C6 vertebrae, degenerative and osteophytic changes which are showing bridging were seen. Formation of osteophyte that extended to the anterior

2017;24(1):69-71
DOI:10.5455/jtomc.2016.06.074

part and causing pressure on the pharynx was prominent especially at C5 level (figure2).

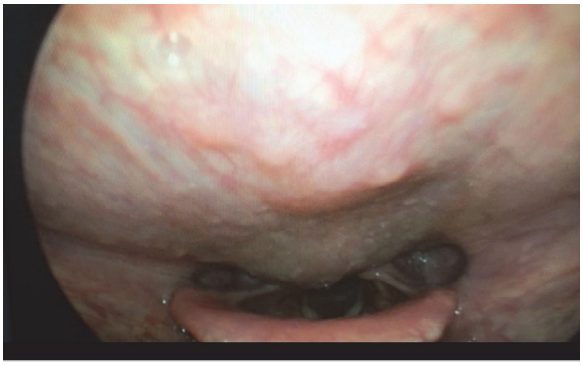

Figure1. In endoscopic examination a submucosal tumor like pathology which is forming by osteophytes is seen on the midline of the hypopharynx.

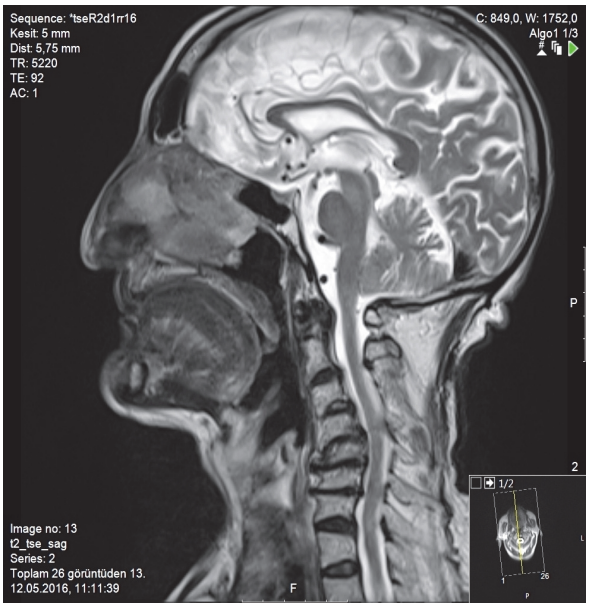

Figure2. In the T2 weighted MRI on sagittal plane between the anterior part of the C3-C6 vertebrae, degenerative and osteophytic changes are seen.

Additionally, the patient's lab tests were found normal. According to the examination, MRI findings, and lab test; the patient was diagnosed with Forestier syndrome and the treatment was planned. Because the patient's complaints were not serious, only antireflux and anti-inflammatory drugs were prescribed. The controls of the patient, who benefits pretty much from the medical treatments and refuses the surgical treatment, are continuing.

DISCUSSION

Ossification which is occurring at the end of the degenerative process is responsible from pathogenesis of the Forestier syndrome or DISH. In degenerative process, inflammation of the anterior longitudinal ligament spreads to foramen magnum to sacrum. Posterior longitudinal ligament, ligamentum flavum, and intervertebral disc space can be accompanied in this process. Radiological imaging methods and endoscopic examinations are directive for the diagnosis of the illness. X-ray films, computed tomography, or MRI and barium esophagography can be performed for diagnosis. In endoscopic examination a submucosal mass which narrows the pharynx, and esophagus can be seen. Esophageal stenosis that occurred due to pressure of the osteophytes can be detected with barium esophagography. In our case because we reached the diagnosis with MRI which was performed for the hypopharynx tumors that we especially suspected, we did not perform any other imaging methods. The radiological diagnosis requires a minimum of two (according to Forestier), or three (according to Resnick) continuous intervertebral bridges (7). According to Utsinger, in early stage cases that have only one intervertebral bridge or cases with entesophites without intervertebral bridge must be suspected from DISH. The Utsinger's criteria were required the following; preservation of the intervertebral disk spaces in effected areas, absence of sacroiliac erosion, or bone fusion and, the lack of ankylosing on the facet joints (8).

Although the etiopathogenesis is not known precisely, trauma may accelerate the course. Furthermore stress trauma, metabolic and endocrine disorders such as obesity, diabetes, hypoparathyroidism, hyperuricemia, dyslipidemia, hypervitaminosis A and also genetic factors, infection diseases, and cardiovascular disorders can be counted between the risk factors (6, 7, 9). There were no additional risk factors in our patient other than hypertension.

Several diseases such as ankylosing spondylitis, spondylosis deformans, osteoarthritis, acromegaly, and degenerative diseases of intervertebral discs should come to mind in differential diagnosis. Additionally in differential diagnosis of the dysphagia tumors of the neck, mediastinum, medulla spinalis and lungs also motility disorders of esophagus, esophageal stricture, esophagitis, Zenker's diverticulum, Plummer Vinson syndrome, reflux, vascular disorders, neurologic deficits, globus hystericus, and dermatomyositis should be considered (6).

In early stage and symptomatic cases, conservative treatment such as physiotherapy, training, and steroids, nonsteroidal antiinflammatory drugs, myorelaxants, and antireflux drugs may be sufficient (6,10). In patients with advanced dysphagia, persistent pain, and excessive weight loss that do not benefit from conservative treatments, surgery can be performed (10, 11). However, because the disease is basically inflammatory, the excision of the bone formations that are causing pressure can not always yield positive results. The patients that undergo surgery should be selected very carefully because the recurrence rates are high even after the surgery (10). Our case was benefited from medical treatment and surgery was not performed.

It should be suspected from Forestier syndrome especially in elderly male patients who admit to

2017;24(1):69-71
DOI:10.5455/jtomc.2016.06.074

physician with complaints of neck, and throat pain, foreign body sensation in the throat, and dysphagia, even if any pathological findings are not detected in examination. A simple lateral X-ray film of the neck would be helpful in diagnosis.

REFERENCES

1. Forestier J, Rotes-Querol J. Senile ankylosing hyperostosis of the spine. Ann Rheum Dis 1950;9(4):321–30.
2. Resnick D, Shaul SR, Robins JM. Diffuse idiopathic skeletal hyperostosis (DISH): Forestier's disease with extraspinal manifestations. Radiology 1975;115(3):513-24.
3. Yochum TR, Rowe LJ. Arthritic disorders. In: Rowe LJ, Yochum TR, eds. Essentials of skeletal radiology. 3rd edition. Philadelphia: Lippincott Williams&Wilkins; 2005. p. 990.
4. Mader R. Diffuse idiopathic skeletal hyperostosis: time for a change. J Rheumatol 2008;35(3):377-9.
5. Akhtar S, O'Flynn PE, Kelly A, Valentine PM. The management of dysphasia in skeletal hyperostosis. J Laryngol Otol 2000;114(2):154-7.
6. Pulcherio JO, Velasco CM, Machado RS, Souza WN, Menezes DR. Forestier's disease and its implications in otolaryngology: literature review. Braz J Otorhinolaryngol 2014;80(2):161-6.
7. Mazieres B. Diffuse idiopathic skeletal hyperostosis (Forestier-Rotes-Querol disease): What's new? Joint Bone Spine 2013;80(5):466-70.
8. Utsinger PD. Diffuse idiopathic skeletal hyperostosis Clin Rheum Dis 1985;11(2):325-51.
9. Weinfeld RM, Olson PN, Maki DD, Griffiths HJ. The prevalence of diffuse idiopathic skeletal hyperostosis (DISH) in two large American Midwest metropolitan hospital populations. Skeletal Radiol 1997;26(4):222-5.
10. Aydin E, Akdogan V, Akkuzu B, Kirbaş I, Ozgirgin ON. Six cases of Forestier syndrome, a rare cause of dysphagia. Acta Otolaryngol 2006;126(7):775-8.
11. Aslan G, Hamzaoğlu A. Forestier's disease and dysphagia. KBB Forum 2007;6(1):33-6.