Assessment of a Giant Retroperitoneal Abscess in Emergency Department: An Unusual Case Presentation

Acil Serviste Dev Retroperitoneal Bir Abse'nin Değerlendirilmesi: Nadir Raslanan Bir Olgu Sunumu

Uğur Lok[1], Hasan Büyükaslan[2], Umut Gülaçtı[1], Hacı Polat[3], İrfan Aydın[1]
1 Department of Emergency Medicine, Adiyaman University Faculty of Medicine, 02040 Adiyaman, Turkey
2Department of Emergency Medicine, Harran University Faculty of Medicine,63200 Sanliurfa, Turkey
3 Department of Urology, Adiyaman University Faculty of Medicine, 02040 Adiyaman, Turkey
Yazışma Adresi:
Yrd. Doç. Dr. Hasan Buyukaslan
Department of Emergency Medicine, Department of Emergency Medicine, Harran University Faculty of Medicine,63200 Sanliurfa, Turkey
e-mail: hasanbuyukaslan@hotmail.com

Geliş tarihi / Received:31.01.2016 **Kabul tarihi / Accepted:** 23.02.2016

Abstract
Retroperitoneal abscess (RA) is an unusual but potentially life-threatening intra abdominal infections which is rarely encountered in emergency departments (ED) (1,2). Insidious clinical manifestations and occult nature of abscess make it diagnostic challenge and causes delays and missed diagnosis that leads to prolonged sepsis, and increased morbidity and mortality rates (3,4). Retroperitoneal abscess may be classified as primary if the infection results from hematogenous spread or secondary if they are related to an infection in an adjacent organ. In a small percent RA may be idiopathic (4,5) which infections may be monomicrobial but are in most cases polymicrobial (4). Most commonly origin of abscess is primarily urinary tract infection, followed in frequency bowel-related diseases such as diverticulitis (1,6), retroperitoneal appendicitis, pancreatitis, biliary, and peptic ulcer diseases spinal and renal tuberculous disease(3). But cases have been described resulting from bone infections, trauma, hematogenous spread and malignancies(2,4). The most commonly isolated pathogens are gram-negative bacilli such as Escherichia coli and Proteus mirabilis in frequency, but anaerobic species such as Bacteroides may also be found Gram-positive cocci, mainly staphylococcal species and rarely streptococcal species, are usually isolated in cases of hematogenous spread(4). Manifest clinical symptoms include fever, abdominal and/or flank pain, lumbar mass, weakness, weight loss and anorexia (4). Mainly predisposing factors are diabetes mellitus and immunocompromised hosts (7). The most reliable and sensitive diagnosis tool remains Computed tomography CT scan (4,8). The treatment modalities consist of open surgery, percutaneous drainage and accompanied intravenous antibiotic administration (1,4).
We reported here a case of RA secondary to unknown etiology in a patient with mentally retarded, whose specification was delayed for weeks before it diagnosed and reached huge size.

Key Words: Retroperitoneal Abscess; Abdominal computed tomography; Emergency Department

Öz.

Retroperitoneal bölgenin enfeksiyonları belirsiz sinsi semptomlar ve nonspesifik klinik bulgu ve semptomlar nedeniyle tanı konulması zordur. Retroperitoneal abse acil serviste nadiren karşılaşılan potansiyel olarak hayatı tehdit edici intra-abdominal enfeksiyondur. Etyolojik olarak primer ve sekonder olarak ikiye ayrılır. En yaygın nedenleri üriner sistem enfeksiyonları, gastrointestinal sisteme ait hastalıklar, vertebra ve böbrek tüberkülozudur. Daha az görülen nedenleri arasında kemik enfeksiyonları, travma, uzak enfeksiyonlardan hematojen yolla yayılım ve kanser hastalıklarını içerir. Biz burada 51 yaşında mental retardasyonlu, başka ek hastalığı bulunmayan, tanı konulamamış ve etiyolojisi belirlenemeyen dev bir retroperitonel abseli hastayı tartıştık. Sonuç olarak bu tür hastaların zamanında tanı ve tedavisi için yüksek şüphe endeksi gereklidir özellikle mental retardasyon da bulunuyorsa.

AnahtarKelimeler: Retroperitoneal Abse, Batın bigisayarlı tomografisi; AcilServis

Case Report

A 51 years old mentally retarded Turkish male with chief complaints of general weakness, vague abdominal pain and constipation at least for 20 days, was treated initially with an antibiotic by family doctor and aemergency department of a local facility. On admission, he has poor conscious, a bad expression, but looked pale and in good general condition, complaining of poor oral intake. He had history of mental retardation for years and constipation for last 15 days. Patients' initial vital signs were normal limits. Body temperature :37.5, pulsation rate:101 beats/min and respiration rate: 23 breaths/min. Abdominal examination revealed moderate right lower quadrant and flank tenderness but he had normal bowel sounds and no peritoneal signs and nothing else.The rectal examination was unremarkable and negative for occult blood. No meningeal or respiratory symptoms were present.He was in no obvious distress or discomfort, and did not appear dehydrated. Laboratory studies white blood cells:15040/mm^{3}with left shift, hemoglobin: 15 gram/dL, platelets:621, hematokrit:47.1, glucose:125gr/dl, urea:38, kreatinin:0,8, aspartataminotransferaz: 65U/L,alanin aminotransferaz:99 U/L, gama-glutamil-transferase:75 U/L, sodium: 132, potassium: 8. Urine microscopic analyzes showed 1-2 leucocytes. Abdominal ultrasound showed a hypoechoic round mass with a thick capsule sizes 8.5x9x17 cm of cross diameter adjacent to right midrenal line and extending to pelvic cavity. CT showed a giant mass measuring 20 cm in longitudinal diameter with a covered thick capsule containing into fluid and gas, consistent with retroperitoneal abscess (figure A-F). Because the patient's general condition suddenly deteriorated, and a presepthic state abruptly developed, an emergency laparotomy was performed immediately on admission. Large amount of pus was drained by surgical intervention. On inspection at laparotomy, no purulent fluid, inflammatory masses, intestinal anomalies such as an internal hernia or malrotation, or intestinal perforations were found. Cavity was thoroughly irrigated with copious warm sterile saline fluids, and two drains were inserted into the cavity. After the operation, ceftriaxone was intravenously administered initially. Multiple anaerobic bacteria grew in microbiological cultures but urine culture showed no bacteria. Several antibiotic chemotherapy therapy combinations were intravenous (IV) infused according to culture

antibiogram test results. Postoperative 24th days, he was discharged uneventfully with outpatient follow-up.

Discussion

The retroperitoneal space is a potential body space between the peritoneum and the transversalis fascia lining the posterior abdominal cavity and extends from the diaphragm superiorly to pelvic brim inferiorly, and border of the quadratus lumborum muscles laterally. The retroperitoneal area divided into three distinct compartments to be the anterior pararenal, perirenal, and posterior pararenal areas. By means of congenital anatomical structural openings, the retroperitoneal infections have the potential risk ofrapid spread to the perirenal area, the psoas muscles, the lateral abdominal wall, and the lower extremities (2,4,8).

Retroperitoneal abscess mostly occurs in people aged 30 to 50 years, with a slight male predominance vs female (2). Retroperitoneal infection is a rare clinical presentation, that often with nonspecific clinical symptoms and signs. Most common cardinal symptoms of the disease are fever, back pain, and abdominal pain but may present with insidious symptoms and non-specific clinical signs. Abdominal pain was mainly presenting patients whose abscess was of a gastrointestinal (GI) origin. By contrast, back pain was noted in origins other than GI as the initial presentation, and limb numbness was noted in abscesses from bone origin only, additional other symptoms may be malaise, anorexia,hip and back weakness, chills and weight loss. Nevertheless which common presentations of fever and pain is undistinguished initial diagnosis that is usually missed or delayed, the mean time between admission and diagnosis is generally ranged 9.4 to 12.7 days(4), often for months, or confused with other clinical entities. Presentations may be dramatic, with the rapid onset of septic shock or other complications after perforation and release of bacterial contents into the peritoneum, thorax, meninges, and buttocks (2,8). However, our patient complained general weakness, vague abdominal pain and constipation at least for 20 days. This patient had already made two health care facility visits, and received repeated antibiotic chemotherapy prescription. In generally this delay in diagnosis is typical of retroperitoneal Abscess unless caution is not paid and kept in mind.

Diabetes mellitus, malignancies, both cellular and humoral immune deficiencies, alcohol abuse, glucocorticosteroids drug usage, HIV infection, IV drug abuse and urological and GI procedures or operations and bedridden conditions are well known primary predisposing conditions (2,4,5,9). But, we cannot fount any predisposing history or procedure associated to our case in past medical history except for mental retardation which has been found for years and never led to him bedridden position.

A variety of etiologic factors has been confirmed resulting from GI diseases such as diverculitis, appendicitis, inflammatory bowel disease, pancreatitis, biliary tract disease (4,8), renal diseases such as pyelonephritis or perinephric abscess, vaginal delivery, bone infections such as the spinal cord and tuberculosis of the vertabra, malignancies, blunt trauma, operative procedures and hematogenous spread from distant tissue infections(4,8). Tai et al. reported the formation of a gaind retroperitoneal abscess as a severe complication of pancreatitis (7). However, as is in our case, despite the variety of etiologic factors, the causal condition cannot be identified always and 9-12% of cases are characterized to be unknown or idiopathic etiology (4).

Ancillary laboratory evaluation may reveal leukocytosis with neutrophils, anemia sterile pyuria, an abnormal psoas shadows or ipsilateral diaphragmatic elevation, loss of renal outline, free gas or scoliosis on plain films, and urinary obstruction, but are usually unremarkable (4,8).

(CT) and magnetic resonance imaging (MRI) are very effective and reliable imaging modality for diagnosis of retroperitoneal abscess, with sensitivities of 88.5% and 100%, respectively (2,5,7,8). CT will provide important information regarding the exact location of the abscess as well as its relationship to contiguous organs, hence probable sources of the infection (4). Because of difficult visualization of retroperitoneal space with abdominal ultrasonography (USG) and due to bowel gas, and operator dependency, caution is still required (2,5,8). A study reported that sensitivity of ultrasonography of retroperitoneal abscess originating from GI and genitourinary tract is 53.8% and, the sensitivity of radiographs are 20% overall (2).

A wide range of pathogen of the retroperitoneal abscess may vary depending on the origin of the infection. The most common isolated pathogens are gram-negative basils which are Escherichia coli and Proteus mirabilis. Those usually isolated from the abscesses whichresulting from Urinary tract infection.Historically, the agent usuallyabstracted from abscesses regarding to GI tract infections are Escherichia coli, Enterobacter species, Enterococcus as well as anaerobic species. The most commonly isolated anaerobic agents are Peptostreptococcus species followed in frequency by Bacteroides species. In most of cases isolated bacterial agent, similar to our test result, are polymicrobial, containing mixed aerobic and anaerobic agent, and include several, in generally two to five bacterial species. The ratio of polymicrobial cases was reported to be 0%–8% to 27%–30% in literature data (2,4,7,8).

Early recognition and appropriate management of disease and preexisting conditions is mainstream of retroperitoneal abscess treatment that play pivotal role to reduce the morbidity and mortality associated with this disease. The mortality is ranged to be 1.5%–26% and the deaths were in generally resulting from sepsis (4,7,8). An open or image mediated percutaneous surgical drainage with a CT or ultrasound and along with antibiotic therapy are the gold standard for the management of retroperitoneal abscess (2,4,5,9). A small and uncomplicated abscesses can be treated with conservative treatment with antibiotics medication alone(4,10). There is no standardized an antibiotic treatment modality. It is suggested that a combination of two or three drugs, such as vancomycin, carbapenems, imipenem, rifampin, quinolones, and macrolides have achieved higher disease control rates, should be initiated using intravenously route in more severe infections (1,9). Bacteriemia and sepsis is a serious complication of retroperitoneal abscess and associated with a higher mortality rates, should be identified as early as possible, and an appropriate antibiotic chemotherapy immediately administered. The mortality rates of retroperitoneal abscess were reported to be 26% in a series which the ratio depends on the patient's comorbidities(2,11).

Conclusion

In here, we reported a giant retroperitoneal abscess of a mentally retarded patient that highlights the significance of early diagnosis and appropriate treatment of retroperitoneal abscess in ED. Because insidious clinic manifestation, a high suspicion index is pivotal for correct and timely diagnosis to avoid subsequent severe complications. The most effective

diagnostic tool for retroperitoneal abscess is CT. Emergency doctors should kept in mind that retroperitoneal abscess is rare and life-threatening condition and be performed abdominal CT imaging as early as possible, especially the patients with distorted mental health care and care dependant.

The authors declared that no conflict of interest

Figures show a giant mass measuring to be 10x8x20cm cross diameter and containing air-fluid level, extending from lower pole of the right kidney to right lower pelvic cavity and involved in musculus iliopusoas.

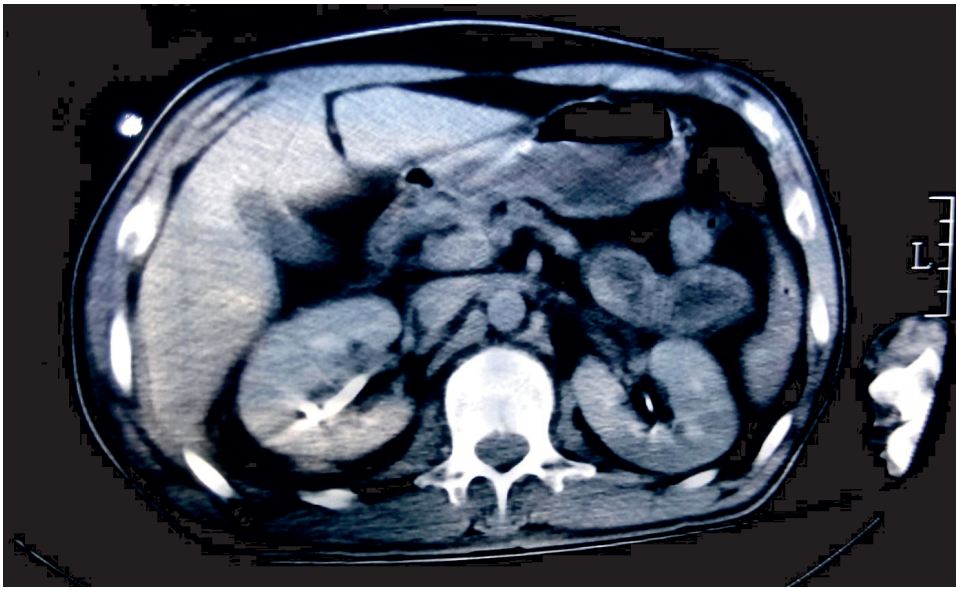

Figure A shows tip of the retroperitoneal abscess with contrast enhanced computed tomography (White Arrow)

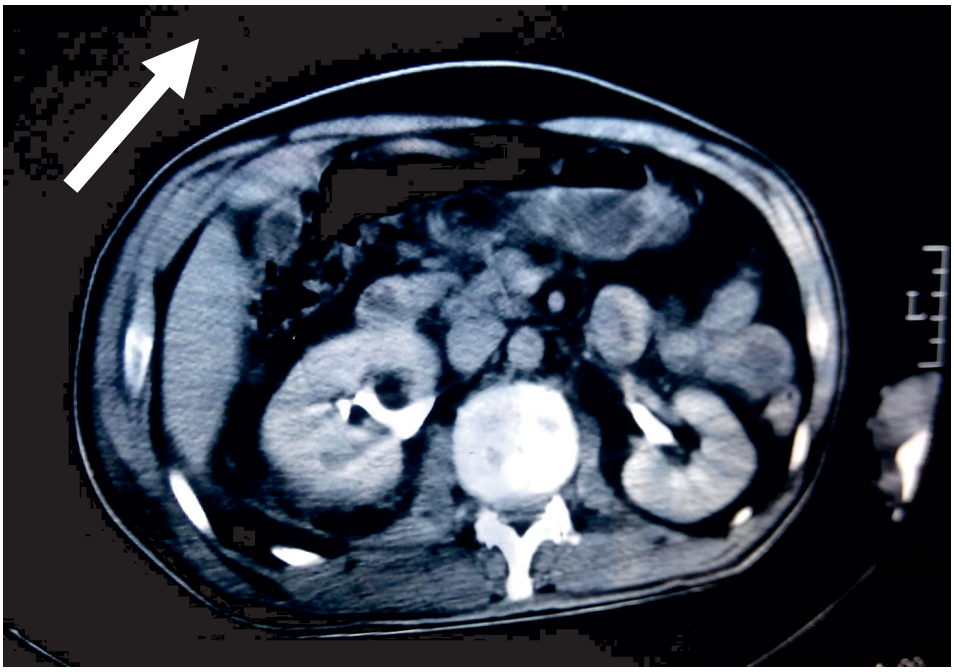

Figure B shows perinephric images of the retroperitoneal abscess with contrast enhanced computed tomography (White Arrow)

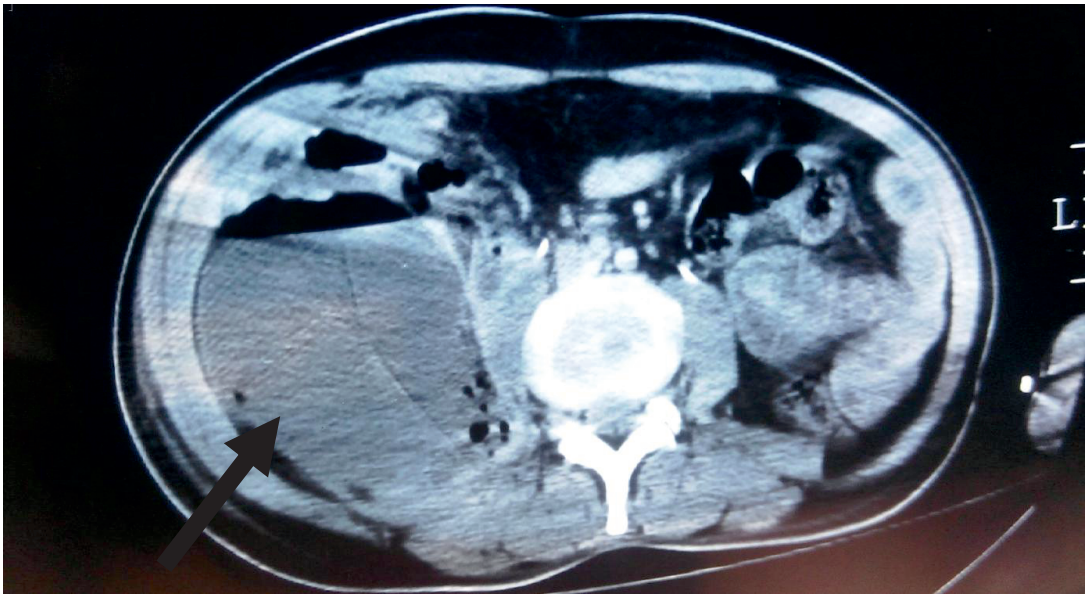

Figure C shows huge size of retroperitoneal abscess with air-fluid levels with contrast enhanced computed tomography (Black Arrow)

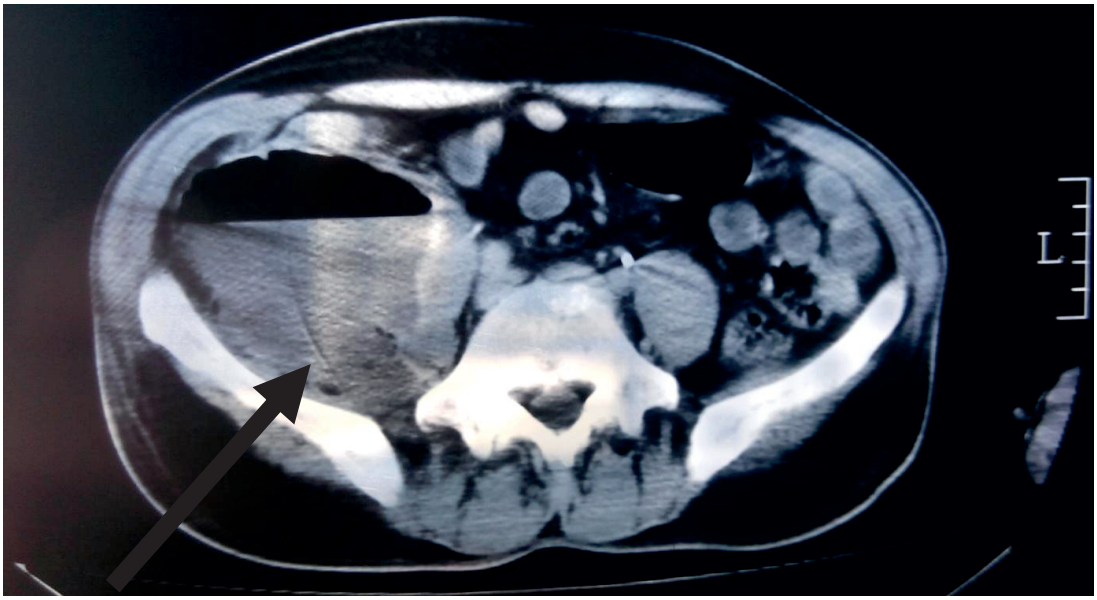

Figur D

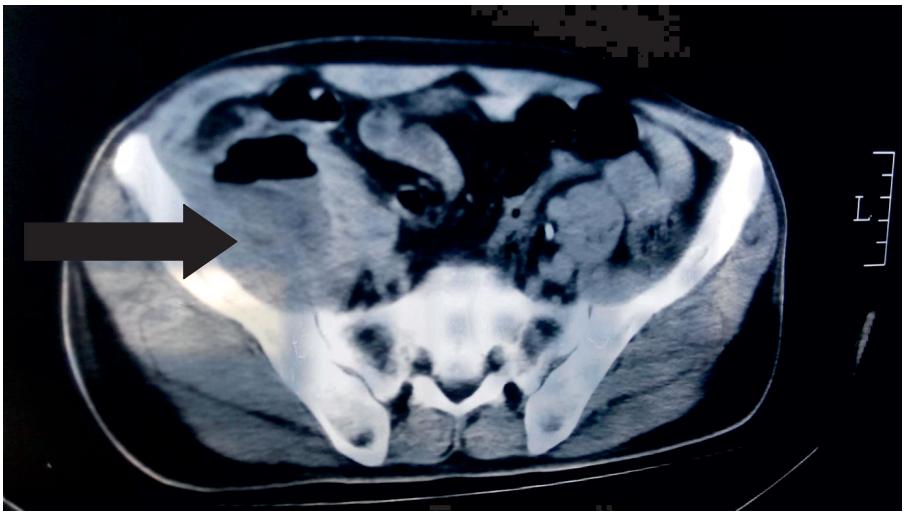

Figure E

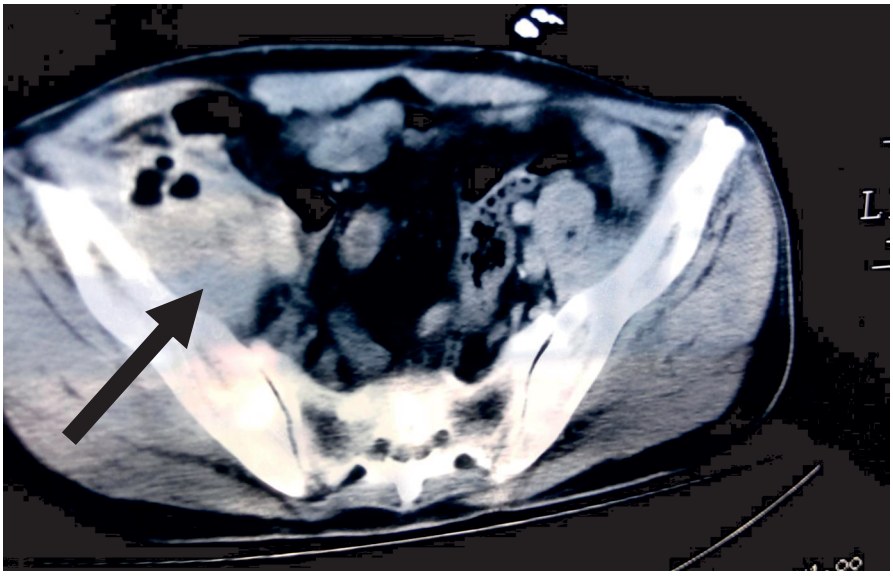

Figure F

Figure D, E and F shows contrast enhanced computed tomography pelvic images of retroperitoneal abscess with air-fluid levels (Black Arrows)

Referances

1.Ohara G, Kondo T, Kagohashi K, Watanabe H, Kawaguchi M, Kurishima K, et al.Retroperitoneal abscess shortly after chemotherapy for lung cancer: A case report.MolClinOncol. 2014 ;2(2):302-4

2.Huang SH, Lo WO, Lin CM, Hsieh TS, Wang SF, Tsai SW, Chen KC. Retroperitoneal abscess: 7-year experience of 29 cases in a tertiary care center in Taiwan. J Urol.2015; 26(3):218–21

3.Su CN, Hsieh DS, Sun GH, Yu DS, Fong CJ.Primary retroperitoneal abscess complicated with septic arthritis of the hip.J Chin Med Assoc. 2006;69(1):51-3.

4.Ioannidis O, Kakoutis E, Katsifa H, Rafail S, Chatzopoulos S, Kotronis A et al.Streptococcus mutans: a rare cause of retroperitoneal abscess.Adv Med Sci. 2011;56(1):113-8.

5.Woo MY.Psoas abscess.J EmergMed. 2014;47(5):129-30.

6.Li SY, Jiang JK, Chang YH, Wu TC, Yang WC, Ng YY.Recurrent retroperitoneal abscess due to perforated colonic diverticulitis in a patient with polycystic kidney disease.J Chin Med Assoc. 2009;72(3):153-5.

7.Shigemura K, Arakawa S, Miura T,Yasufuku T, Nakano Y, Tanaka K et al.Retroperitoneal abscess perforating into the thoracic cavity in an immunocompromised host.J Infect Chemother. 2008 ;14(4):305-7.

8.Amitai A, Sinert R.Necrotizing fasciitis as the clinical presentation of a retroperitoneal abscessJ Emerg Med. 2008 ;34(1):37-40.

9.Russo G, Lichtner M, Carnevalini M, Mascellino MT, Mengoni F, Oliva A et al.Primary retroperitoneal abscesses due to Rhodococcusequi in a patient with severe nephrotic syndrome: successful antibiotic treatment with linezolid and tigecycline.IntJ Infect Dis. 2010 ;14(6):533-5.

10.Nguyen CT, Tomford JW, Desai MM. Retroperitoneal cold abscess caused by mycobacteria chelonaeabscessus after percutaneous nephrolithotomy in India: strategies for detection, management, and prevention in the United States.Urology. 2009 ;73(1):209-13.

11.Katsuno S, Ando H, Seo T, Shinohara T, Ochiai K, Ohta M. A case of retroperitoneal abscess caused by Salmonella Oranienburg. J Pediatr Surg. 2003 ;38(11):1693-5.