Göztepe Tıp Dergisi 24(1):46-48, 2009 ISSN 1300-526X

OLGU SUNUMU Dahiliye

Kardiyak hidatik kist

Özlem Zeynep GÜRBÜZ (*), Fatma ALİBAZ ÖNER (*), Işıl UZUNHASAN (**), Mecdi ERGÜNEY (***)

SUMMARY

Cardiac hydatid cyst: A case report

Hydatid cyst is a zoonosis caused by echinococcos granulosis. Incidence of the disease varies between 5 to 20 in 100 000 in most countries. Cardiac hydatid cysts are rare and comprise 0,5 to 2 % of all hydatid cyst cases. The most frequent location is the free wall of left ventricle and interventriculer septum. A hydatid cyst localized at the apex of left ventricle is an extremely rare occasion. Most of the patients with cardiac hydati-dosis are asymptomatic. We present a case of cardiac hydatid cyst localized at the left ventriculer apex who presented with atrial fibrillation (AF) and symptoms of heart failure(HF). Hydatid cyst must be considered absolutely in the differantial diagnosis of cardiac cysts.

Key words: *Cardiac hydatid cyst, atrial fibrillation, heart failure*

Anahtar kelimeler: *Kardiyak hidatik kist, atriyal fibrilasyon, kalp yetmezliği*

INTRODUCTION

Hydatid cyst is a zoonosis caused by echinococcos granulosis in its slug state [1]. Incidence of the disease varies between 5 to 20 in 100 000 in most countries. Cardiac hydatid cysts are rare and comprise 0,5 to 2 % of all hydatid cyst cases [2,3]. The most frequent location is the free wall of left ventricle and interventriculer septum [4]. We want to present a hydatic cyst localized at the apex of left ventricle, which is an extremely rare occasion.

CASE REPORT

A 67-years old woman presented in our outpatient clinic with progressive symptoms of palpitation, dyspnea and cough. She did not comply with her therapy for hypertension and chronic obstructive lung disease. There was nothing special on her family history. She was a nonsmoker who did not take alcohol. Physical examination revealed a blood pressure of 70/50 mmhg with a heart rate of 110/minute. On cardiac oscultation, there was no murmur or gallop rhythm. Her axillary temperature was 38°C. Crepitations were oscultated at the base of lungs bilaterally. The abdomen was completely normal on physical examination. On chest X-ray ,there were bilateral perihiler nonhomogenous opacities and pneumonic infiltration on the right inferior lobe. The results of laboratory analysis were as follows: glucose 115 miligram/deciliter (mg/dl), urea 146 mg/dl, creatinin 1,2 mg/dl, total protein 7,2 mg/dl, albumin 3,4 mg/dl, white blood cell 6600/mm^3 with no eosinophilia, hematocrite 42 % erytrocite sedimentation rate 78 mm/hour, C-reactive protein level was 10 mg/dl. The electrolyte levels were within normal limits. The electrocardiography revealed atrial fibrillation with rapid ventricular rate. The patient was admitted in our coronary care unit for further evaluation and treatment with the diagnosis of AF and HF. She was given inodilatator therapy with dobutamin and dopamine and intravenous 40 mg furosemid. In 72 hours, her symtoms for heart failure subsided and inodilatator therapy was stopped. She was given digoxin 0,25 mg/day intravenously followed by oral 0,25 mg/day for heart rate control. Blood urea, creatinine and CRP levels were normal by one

Geliş tarihi: 07/02/2008
Kabul tarihi: 27/02/2009
SB. İstanbul Eğitim ve Araştırma Hastanesi 2. Dahiliye Kliniği Asistanı*; İ.Ü. Haseki Kardiyoloji Enstitüsü Kardiyoloji Uzmanı**; SB. İstanbul Eğitim ve Araştırma Hastanesi 2. Dahiliye Kliniği Şefi***
* Vakamız, ‘’9. Uluslararası Kardiyovasküler İnfeksiyonlarda ve Endokarditte Modern Yaklaşımlar Sempozyumu’’nda poster olarak sunulmuştur.

week. A transtorasic echocardiographic examination showed left ventriculer hypertrophy with diastolic dysfunction and a cystic lesion with a 3,8 centimeter (cm) diameter adjacent to the left ventriculer apex (Image 1). Serological tests for hydtatidosis (indirect hemagglunitation) was negative. Abdominal and cranial computerize tomography which was performed to rule out other cysts were normal. The patient was referred to cardiovascular surgery. The cyst was first sterilized with hypertonic saline solution; then it was punctured and its contents were drained. After the cyst was excised cystoraphy procedure was performed. Histopathologic analysis of the surgical specimen confirmed the diagnosis of echinococcosis. After operation, albendazole (50 mg/kg/daily) was given for 6 months. Three months after surgery, the patient was asymptomatic with no echocardiographic signs of recurrence.

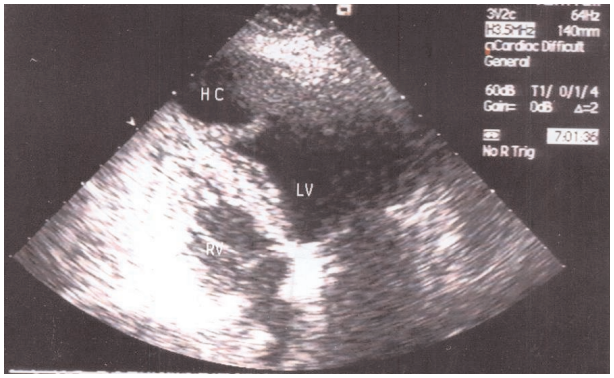

Image 1.

DISCUSSION

Echinococcosis is a parasitic disease which is caused by the slug state of echinococcos granulosis, echinococcos multilocularis or e. vogeli. It is expecially frequent in rural areas where cattle and flesh-eating animals (dog, etc) live together. The main host is dog which can excrete up to 20000 helminthes. Humans are intermediate hosts. When the oncosperes infect humans, the slug form gets into portal circulation and moves in the lung or liver. The slug form diffetantiates into hydatid cysts surrounded by a chitin membrane with a germinal layer inside. Most frequent location of hydatid cyst is in liver and lung. The cyst is usually an asymtomatic cyst. Echocardiography, computed tomography (CT) and magnetic resonance imaging (MRI) are valuable diagnostic tools. A pathognomonic finding is a circumscribed multiloculer cystic lesion of fluid attenuation with a peripheral thin capsule. Serologic tests are positive in patients with liver disease by 90 % whereas involvement of other organs have 50 % positive values. Echinococcuses come to the heart with coronary circulation, pulmonary circulation and foramen ovale [5]. Presenting symptoms of cardiac hydatid disease are variable depending on the localizationof the cyst, presenting of mass effect and the age of prostocolex viability. Hydatid cyst can result in serious consequences, such as rupture into the circulation with anaphylactic reaction, damage to the cardiac valves, ischemic syndromes from compression of coronary arteries or pseudoischemic electrocardiographic changes, systemic or pulmonary embolization. Yet, most of the patients with cardiac hydatidosis are asymptomatic [6,7]. Chest X-ray may show an abnormal heart contour, pulmonary cyst, an calsified lobular mass on left ventriculer free wall [8,9]. CT and MRI can be used for detection of extracardiac manifestations. Early operative therapy is the treatment of choice for cardiac hydatid cysts [10]. Hydatid cyst must be involved in the differantial diagnosis of cardiac cysts. Our case is special in its rare occuring appearance of the left ventriculer apex and its presentation with symptoms of heart failure and atrial fibrillation with high ventricular rate. Kaplan et al presented a female case having both left ventriculer apical cyst and hepatic cyst. But the patient was asymptomatic [11]. We believe that the symptoms of our patient may be due to the high ventricular rate atrial fibrillation rhythm, which may be associated with hemodynamic changes induced by such a large hydatic cyst. An alternative explanation may be that the patient was asymptomatic and a co-incident exacerbation in her obstructive lung disease caused heart failure symptoms with high ventricular rate response atrial fibrillation.

REFERENCES

1. Kasper DL, Braunwald E, Fauci AS, et al. Harrison's Principles of Internal Medicine. In:White AC, Weller PF, editors. İnfectıous diseases.16th edition 2006;1272-1275.
2. De Paulis R, Seddio F, Colagrande L, Polisca P, Chiariello. Cardiac echinococcosis causing coronary artery disease. Ann Thorac Surg 1999;67:1791-1793.
3. Miralles A, Bracamonte L, Pavie A, Bors V, Rabago G, Gandjbakhch I, et al. Cardiac echinococcosis. Surgical treatment and results. J Thorac Cardiovasc Surg 1994;107:184-90.
4. Macedo AJ, Magalhaes MP, Tavares NJ, Bento L, Sampayo F, Lima M. Cardiac hydatid cyst in a child. Pediatr Cardiol 1997;18:226-228.
5. Laglera S, Garcia-Enguita MA, Martinez-Guiterrez F, Guiterrez-Rodriguez A, Urieta A. A case of cardiac hydatidosis. British Journal of Anaesthesis 1997;79:671-673.
6. Lanzoni AM, Barrios V, Moya JL, Epeldegui A, Celemin D, Lafuente C, et al. Dynamic left ventrıcular outflow obstruction caused by cardiac echinococcosis. American Heart Journal 1992;124:1083-1085.
7. Grendell JH, Mc Quarid KR, Friedman SC. Disease of the liver and biliary system. Diagnosis &Treatment in Gastroenterology. Lange 1996;38:514.
8. Beggs I. The radiology of hydatid disease. Am J Roentgenol 1985;145:639-648.
9. Maroto LC, Carrascal Y, Lopez MJ, Forteza A, Perez A, Zavanella C. Hydatid cyst of the interventricular septum in a 3,5 year old child. Ann Thorac Surg 1998;66:2110-2111.
10. Abid A, Khayati A, Zargouni N. Hydatid cyst of the heart and pericardium. International Journal of Cardiology 1991;32:108-109.
11. Kaplan M, Demirtas M, Cimen S, Ozler A. Cardiac hydatid cysts with intracavitary expansion. Ann Thorac Surg 2001;71:1587-90.