Gazi Tıp Dergisi / Gazi Medical Journal

OLGU SUNUMU - CASE REPORT

2009: Cilt 20: Sayı 4: 178-180

HEPATIC LIPOMA: CT AND MRI FINDINGS

[1]Fatih CELIKYAY, [2]Zekiye Ruken Yuksekkaya CELIKYAY, [3]Yusuf Ali ONER

ABSTRACT:

Hepatic lipomas are rare benign tumours. They are usually asymptomatic regardless of size and are discovered incidentally. In this report computed tomography (CT) and magnetic resonance imaging (MRI) findings of a hepatic lipoma are presented. Since their imaging findings are characteristic and malignant transformation is unusual, further aggressive diagnostic procedures are seldom necessary.

Key words: Liver, Lipoma, CT, MRI

HEPATİK LİPOM: BT VE MRG BULGULARI

ÖZ:

Lipomlar karaciğer benign tümörleri arasında nadiren karşımıza çıkar. Genellikle boyutlarına bağlı olmaksızın bulgu vermezler ve rastlantısal olarak tanı alırlar. Bu olguda karaciğer lipomunun bilgisayarlı tomografi (BT) ve manyetik rezonans görüntüleme (MRG) bulguları sunulmaktadır. Karaciğer lipomalarının görüntüleme bulgularının tanı koydurucu olması ve malign dönüşümün nadiren gerçekleşmesi nedeniyle girişimsel tanısal işlemler nadiren gereklidir.

Anahtar Kelimeler: Karaciğer, Lipom, BT, MRG

[1]Rize State Hospital Department of Radiology, Rize, TURKEY
[2]Rize State Hospital Department of Radiology, Rize, TURKEY
[3]Gazi University School of Medicine, Ankara, TURKEY

INTRODUCTION

Benign and malignant lesions of the liver are frequently encountered in imaging procedures. Therefore, the differentiation of these lesions and selection of methods for this purpose are important. Hepatic lipomas are extremely rare benign mesenchymal tumours without risk of malignant transformation. We report herein a hepatic lipoma in a 39-year-old woman in whom the diagnosis was made on the basis of radiological features.

CASE REPORT

A 39-year-old woman with a history of a hepatic mass was referred to our hospital for re-evaluation. Her physical examinations and laboratory test results were normal. CT demonstrated a hypodense homogenous smoothly margined rounded focal mass, 1.5 cm in diameter with a mean density of –45 HU in segment 5 (Figure 1). On dynamic CT performed after injection of intravenous contrast material the density of the lesion was measured as -17 HU (Figure 2). On MRI, the lesion was hyperintense on both T1 and T2 weighted sequences (Figure 3a, b). On out-of-phase images, a chemical shift artifact was noted on the borders of the lesion (Figure 3c). The lesion was homogeneously hypointense and did not show enhancement on coronal postcontrast fat-suppressed T1-weighted GE images (Figure 3d). These imaging findings obviated an interventional procedure as the mass was understood to be a hepatic lipoma. On follow-up MRI scans the lesion was stable with no different imaging findings, which supported the radiological diagnosis.

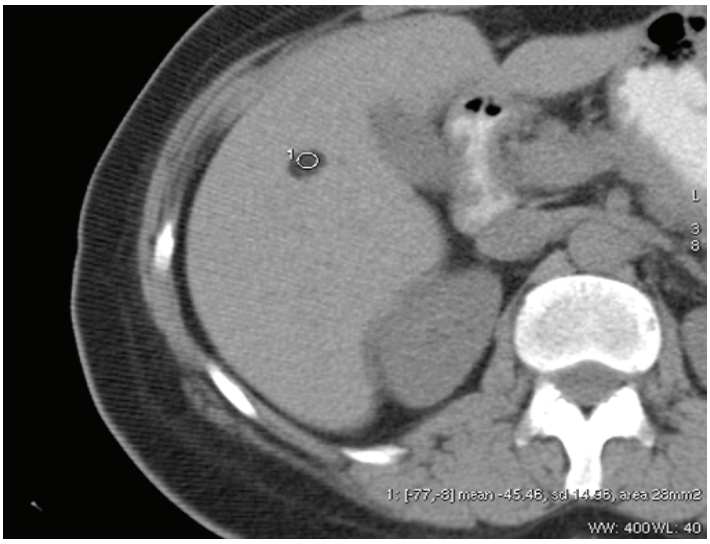

Figure 1. Pre-contrast CT shows a hypodens homogenous smoothly marginated, focalmass of 1.5 cm in diameter with a mean density of –45 HU in the segment 5

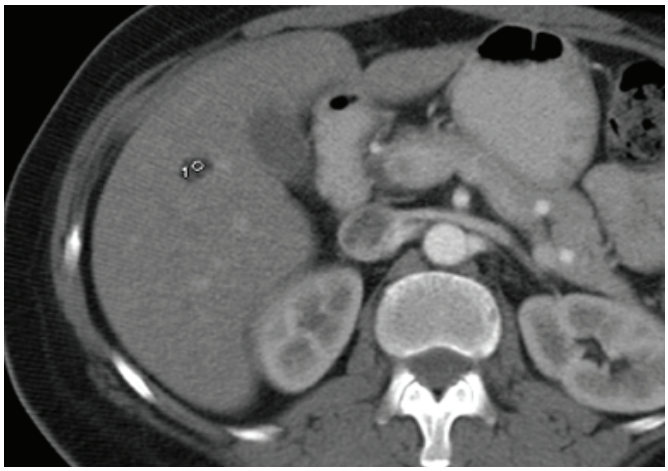

Figure 2. Post-contrast CT shows a mass with mean density of –17 HU

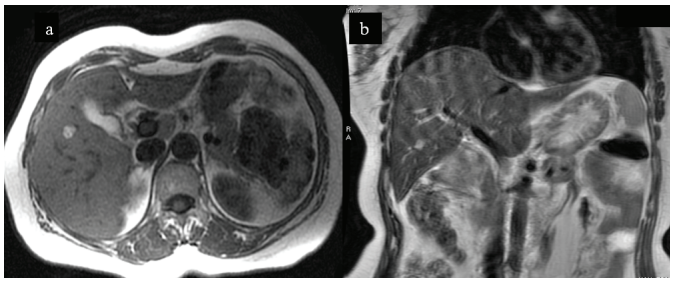

Figure 3. Axial T1 weighted (a) and coronally T2 weighted (b) images show hyperintensemass.

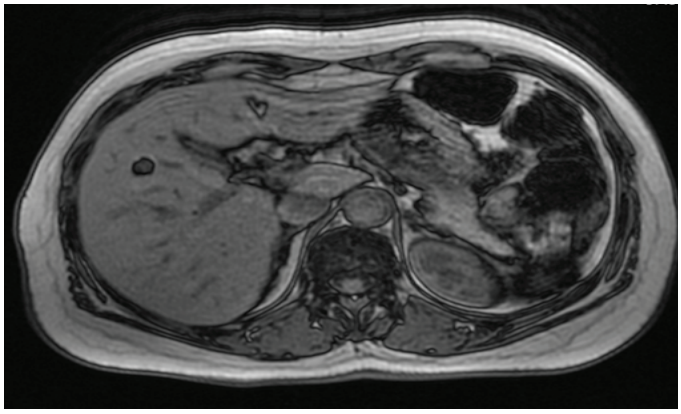

Figure 3c. On out of phases images chemical shift artefact is seen on the borders of thelesion



Figure 3d. On coronal postcontrast fat-suppressed T1-weighted GE image, loss in signal intensity and non-enhancement are seen in lesion.

DISCUSSION

Benign hepatic lipomatous tumours may be seen in unusual cases. These include lipoma, myelolipoma, angiomyolipoma, and angiomyelolipoma. Hepatic lipomatous tumours may occur in approximately 10% of cases of tuberous sclerosis and renal angiomyolipomas. However, solitary liver lipomas may exist without other lesions[1]. Most of them are diagnosed incidentally and are asymptomatic. Nevertheless, they may sometimes cause abdominal pain, depending on their size.

The radiological differential diagnosis of hepatic lipomas includes hemangioma, chronic hematoma, hepatocellular carcinoma, hepatocellular adenoma, fat-containing metastatic tumor (e.g. teratoma), and focal fatty liver[2]. Radiological workup, especially MRI and CT, increase the diagnostic accuracy of liver lipomas.

Lipomas present as sharply bordered hyperechogenic masses with posterior attenuation on US. Although small hemangiomas may be confused with lipomas, hemangiomas usually show posterior acoustic reinforcement on US[3]. Sonographic findings of many hepatic nodules, however, are usually nonspecific and do not allow a definitive diagnosis.

For hepatic lipomas, the diagnostic criteria on CT is a homogeneous image with the density of fat (–20 to –115 HU) and the increase in density on post-contrast images does not reach over 30 HU[4]. However, these density values must be calculated on the correct area to avoid partial volume averaging. Areas of positive density after administration of contrast medium present as adenomatous or angiomatous components[5]. Hepatocellular carcinoma and other tumours may sometimes include lipomatous degeneration, but CT may aid in their differential diagnosis[4,6]. The attenuation value of normal hepatic tissue is 65±5 HU. Most liver malignancies have slightly lower attenuation values and apparent enhancement on dynamic CT[4]. Hepatic hemangioma can be defined easily with an obvious globular contrast enhancement pattern. Hepatocellular adenoma shows early contrast enhancement during the arterial phase. Contrast enhanced MRI findings of primary and metastatic hepatic tumors (e.g. hemangioma, hepatocellular adenoma, and hepatocellular carcinoma) are similar to those of CT. The MRI appearance of hepatic lipomas is characteristic. These lesions present as well demarcated masses, homogeneously hyperintense on all pulse sequences[7]. The lesion is hypointense on fat suppressed images. Unlike other imaging modalities, chemical shift MR imaging is a useful technique for confirming the presence of fat in hepatic lipomas. On out-of-phase T1-weighted gradient-echo images, hypointense chemical shift artifacts occur around hepatic lipomas since the signal from fat within a voxel cancels out the signal from water. On pulse sequences, focal hepatic lesions that contain hemorrhages can also have high signal intensity. However, the use of chemical shift imaging and T1-T2 weighted sequences with fat suppression can discriminate these lesions[8]. On MR imaging, focal fatty infiltration of the liver may simulate a hepatic lipoma differently from CT imaging, and their specific location (e.g porta hepatis, gallbladder fossa), lack of chemi-

cal shift artifacts, wedge-shaped configuration, absence of a mass effect, and enhancement similar to normal liver help in their discrimination.

In conclusion, the appearance of hepatic lipomas on CT and especially on MRI including out-of-phase T1-weighted gradient-echo and fat suppression techniques is characteristic. Since no malignant transformation is reported, knowledge of their characteristic imaging findings may prevent unnecessary invasive procedures during their diagnostic workup.

Correspondence Address: Fatih ÇELİKYAY

Rize State Hospital Department of Radiology, Rize, TURKEY

Phone: 0532 717 46 34

E-mail: fatihcelikyay99@yahoo.com

REFERENCES

1 Roberts JL, Fishman EK, Hartman DS, Sanders R, Goodman Z, Siegelman SS. Lipomatous tumors of the liver: evaluation with CT and US. Radiology 1986; 158: 613-617.

2 Basaran C, Karcaaltincaba M, Akata D, et al. Fat-containing lesions of the liver: cross-sectional imaging findings with emphasis on MRI. Am J Roentgenol 2005; 184: 1103-1110.

3 Bruneton JN, Kerboul P, Drouillard J, Menu Y, Normand F, Santini N. Hepatic lipomas: ultrasound and computed tomographic findings. Gastrointest Radiol 1987; 12: 299-303.

4 Sonsuz A, Ozdemir S, Akdogan M, et al. Lipoma of the liver. Gastroenterol 1994; 32: 348-50.

5 Langsteger W, Lind P, Schneider GH, et al. Lipoma of the liver: computed tomographic, ultrasonographic, and cytologic findings. Gastroenterol 1990; 25: 302-306.

6 Itai Y, Ohtomo K, Kokubo T, et al. CT and MR imaging of fatty tumors of the liver. J Comput Assist Tomogr 1987; 11: 253-257.

7 Marti-Bonmati L, Menor F, Vizcaino I, Vilar J. Lipoma of the liver: US, CT, and MRI appearance. Gastrointest Radiol 1989; 14(2): 155-157.

8 Martín J, Puig J, Falcó J, et al. Hyperechoic liver nodules: characterization with proton fat-water chemical shift MR imaging. Radiology 1998; 207: 325-330.