European Journal of Therapeutics

DOI: 10.54614/eurjther.2022.0083

Original Article

Percutaneous Retrieval of Embolized Catheter Fragments from Preterm Newborn to Adult: A Single-Center Experience for 10 Years

Derya Aydın Şahin, Münevver Tuğba Temel, Osman Başpınar

Department of Pediatric Cardiology, Gaziantep University Medical Faculty, Gaziantep, Turkey

ABSTRACT

Objective: Umbilical vein catheterization and central venous catheters are frequently used. We aimed to present our experiences in 15 of 16 patients with embolized catheters who were successfully retrieved by percutaneous intervention.

Methods: During 10 years, 16 patients with embolized umbilical vein catheters, port catheters, central venous catheters, catheter fragments, and guide wires were examined. Demographic characteristics of the patients, catheter indications, embolized catheter types, localizations and lengths of a catheter, durations of flora, entry points during retrieval of embolized catheters, snare's features used, grasping location of the embolized catheter, and additional procedures were examined retrospectively.

Results: Of the 16 patients, 7 were girls; their ages were between 11 days and 39 years; 14 of the patients were children. Their weights were between 1.3 kg and 65 kg. The umbilical vein catheter in 5 patients, the port catheter in 7 patients, a double-lumen central venous catheter in 1 patient, the distal part of the fragmented sheath in 1 patient, and the guide wire in 2 patients were embolized.

Conclusions: The procedures of umbilical vein catheterization, peripheral central vein catheterization, and port catheterization are safe in experienced hands. Rarely, those catheters may break and embolize. As soon as it is diagnosed, embolized catheters should be removed to prevent complications. Since the retrieval of embolized catheters by percutaneous transcatheter route is safe and successful, it should be used as the first choice.

Keywords: Children, embolized catheter, transcatheter removal, umbilical vein catheterization

INTRODUCTION

Umbilical vein catheterization (UVC) is a frequently used procedure especially in low birth weight premature infants in neonatal intensive care units.[1,2] Central venous catheters (CVC) are frequently used in parenteral nutrition and for monitoring hemodynamic parameters. Those procedures have also complications as in other interventional procedures; the main ones are infection, embolization of catheter, and arrhythmias.[1-3]

It has been reported that its incidence is between 0.2% and 4.2% in a systematic review and it may occur even years after implantation.[3] Since the number of cases in children is low, the incidence is not known. Retrieving these embolized catheters is very important because embolized fragments can lead to serious consequences such as arrhythmias, myocardial damage, thrombosis, infection, perforation, and death.[1-3] In this article, we aimed to present our experiences in 16 patients with cardiac or noncardiac foreign body embolization.

METHODS

Sixteen patients who were attempted to percutaneously retrieve embolized umbilical vein catheters, port catheters (PCs), CVC, catheter fragments, and guide wires between 2011 and 2021 in the Clinic of Pediatric Cardiology were included in the study. Ethics committee approval was received for this study from the ethics committee of Gaziantep University (Date: June 30, 2021, Decision number: 2021/170). Five patients, who have prematurity, had embolized UVC. Seven of them, who are oncologic patients, had embolized PC. A peripheral central catheter was inserted into the patient due to a wide burn on the body and the need for long-term intensive care treatment. One of the patients had a central venous catheter inserted due to gunshot wounds and the need for a long-term intensive care period. The latter 2 patients had embolized guide wire. One of the patients had an embolized double-lumen central catheter used for dialysis due to chronic renal failure. The balloon was applied to the last patient due to valvular and infundibular stenosis, and the distal part of the sheath was embolized while the sheath was removed.

The removal of the embolized catheters was performed under sedation. Depending on the position of the embolized part and the patient's condition, the femoral vein, subclavian vein, umbilical vein, and hepatic vein were used for intervention.

Cite this article as: Şahin DA, Temel MT, Başpınar O. Percutaneous retrieval of embolized catheter fragments from preterm newborn to adult: A single-center experience for 10 years. *Eur J Ther.* 2022;28(1):22-29.

Corresponding author: Derya Aydın Şahin, e-mail: deryaaydin976@gmail.com

Received: July 30, 2021 **Accepted:** October 18, 2021

Copyright@Author(s) - Available online at eurjther.com.
Content of this journal is licensed under a Creative Commons Attribution-NonCommercial 4.0 International License.

While embolized catheters were retrieving, 10 mm Amplatz Goose Neck snare type (Plymouth, MN, USA) in 3 patients, Dotter intravascular retrieval basket catheter (Cook, Bloomington, USA) in 1 patient, and multisnare triple-loop snare in other patients (Merit Medical, South Jordan, USA) were used. Modified loop snare techniques were performed for embolized catheters that could not be retrieved by the standard method.

RESULTS

Of the 16 patients, 7 were girls, their ages were between 11 days and 39 years. Fourteen of the patients were children. Their weights were between 1.3 kg and 65 kg. Demographic characteristics of the patients, catheter indications, embolized catheter types, localizations and lengths of a catheter, durations of flora, entry points during retrieval of embolized catheters, snare's features used, grasping location of the embolized catheter, and additional procedures are shown in Table 1. Embolized catheters were successfully retrieved in 15 of 16 patients, no complications were seen.

Umbilical Vein Catheter Embolizations

The embolized umbilical vein catheter was seen in 5 of our patients. There were no clinical findings, the diagnosis was made by chest radiography, and confirmed by echocardiography (ECHO). The embolization sites were vena cava inferior (VCI) in 2 patients, extending from the right atrium to the pulmonary vein through the patent foramen ovale in 1 patient, and extending from the ductus venosus to the VCI in another patient.

The left subclavian vein was used while the embolized catheter was retrieved from the right atrium-pulmonary vein. In order to retrieve the embolized catheter with a snare, the cut pigtail and floppy wire were taken a tour around the catheter. The distal end of the wire was caught and pulled with another catheter (Figure 1). The distal part of the umbilical catheter extended from the umbilical vein- the ductus venosus to the VCI in another patient. The VCI was entered from the femoral vein with a 4F catheter. In addition, the umbilical vein was entered with an umbilical catheter, the embolized catheter was pushed from the rear and advanced to the VCI and right atrium-vena cava superior (RA-VCS). Later, an embolized catheter was caught in VCS and retrieved with a snare from the femoral vein (Figure 2). The embolized catheter was in the VCI in 1 of the patient and caused adhesion there. First, a piece of the catheter was removed with a snare. Then, the snare was advanced again and the other piece was removed. After the injection of the contrast substance, it has been observed that there is a narrowing in the VCI. The balloon was applied to the VCI and it has been seen that the lumen is opened in control injection (Figure 3). Embolized umbilical catheters were successfully retrieved in 4 of our patients, and, the embolized umbilical catheter could not be removed in 1 patient because it was stuck horizontally in the ductus venosus. Entry locations during the retrieval of embolized catheters, from which end they were caught, catheter lengths, and processing times are shown in Table 1. There were no complications during and after the procedure.

Main Points

- Umbilical vein catheterization and central venous catheters are frequently used procedures especially in parenteral nutrition and for monitoring hemodynamic parameters.
- Those procedures have also complications as in other interventional procedures; the main ones are infection, embolization of catheter, arrhythmias, myocardial damage, thrombosis perforation, and death.
- According to our knowledge, it is the largest series in the literature. Percutaneous retrieval of intravascular foreign bodies is a reliable, successful, effective, and first-choice method in experienced hands, and should be considered as the first step of treatment due to the high success rate and minimal risk of the procedure.

Port Catheter Embolizations

Port catheter embolization was seen in 7 patients. Embolization localizations are shown in Table 1. The PC was disconnected in 6 patients from the connection sites. While the PC was surgically removed, the distal part of 1 cm PC was embolized in one of our patients. The embolized PC extended from the right pulmonary artery branch to the left upper lobe of the lung in 1 patient, and the left end was immobile. When the tip of the catheter could not be caught with the multipurpose and pigtail catheter, the mobile end of the embolized catheter in the right pulmonary artery was caught with the vertebral catheter and removed (Figure 4). The duration of embolization was different in each patient. The embolized PC was noticed 1.5 years after embolization in one of our patients (it is not known when it was inserted, it was also noticed in the chest radiography 1.5 years ago). In 2 of our patients, it was embolized 1.5 months after the insertion of the PC. It was embolized in other 2 of our patients 10 months after the insertion of PC. In the last patient, while the PC was surgically removed, its 1 cm distal part was ruptured and embolized. Embolized catheters were confirmed by chest radiographs and ECHO. Entry locations during the retrieval of embolized catheters, from which end they were caught, catheter lengths, and processing times are shown in Table 1.

Non-catheter Guide Wire and Similar Foreign Body Embolizations

A peripheral central catheter was inserted into one of our patients due to a wide burn on the body and the need for long-term intensive care treatment, and she had dyspnea and orthopnea for 10 days. A long guide wire was seen in the iliac vein extending to the superior vena cava in the chest radiography. All peripheral venous interventional sites (left femoral vein, left and right subclavian vein, left and right internal jugular vein) were thrombosed, and collateral circulation was developed. Therefore, an embolized long guide wire was retrieved with transhepatic intervention and a vascular plaque was placed in the liver parenchyma (Figure 5).[4]

Another patient, who has embolized the long guide wire, was followed up in the intensive care unit due to trauma.

In another patient, a double-lumen catheter was inserted due to chronic renal failure for hemodialysis, and then it was embolized.

Eur J Ther 2022;28(1):22-29

Table 1. Demographic Characteristics of Patients and Percutaneous Retrieval Techniques

Case	Age	Sex	Weight	Diagnosis	Embolization Catheter	Localization of Embolization	Catheter Length	Entry Point	Sheath	Snare Type	Grabbing Site	Duration of Flora (minutes)
1	0.56 m/o	M	1.3 kg	PM +İCH	UVC	RA-PFO-PV	10 cm	SV	5F	Multisnare	Distal end	3.2
2	0.63 m/o	F	1.5 kg	PM	UVC	DV-KC-VCI	7 cm	FV/UV	4F	Multisnare	Distal end	3.6
3	2.2 m/o	M	2.5 kg	PM +NEC	UVC	VCI	3.1 cm	FV	4F	Multisnare	Proximal end	5.1
4	0.36 m/o	F	1.9 kg	PM	UVC	VCI	13 cm	FV	4F	Multisnare	Distal end	2.4
5	0.33 m/o	F	2.2 kg	PM +ESCOBAR	UVC	L-DV	8 cm	FV	4F		Unsuccessful	
6	6 y/o	M	30 kg	ALL	PC	RA-RV	10 cm	FV	5F	Gooseneck	Proximal end	4.8
7	4.5 m/o	M	5.5 kg	ALL	PC	RA	8 cm	FV	6F	Gooseneck	Distal end	1.7
8	39 y/o	M	65 kg	ALL	PC	RV-RPA	28 cm	FV	7F	Multisnare	Proximal end	2
9	5.5 y/o	M	16 kg	ALL	PC	RPA-LPA	9.5 cm	FV	6F	Multisnare	Distal end	2.1
10	11.7 y/o	F	40 kg	ALL	PC	VCS	1.5 cm	FV	5F	Gooseneck	Proximal end	1.9
11	10.6 y/o	M	35 kg	ALL	PC	HV-RV	15 cm	FV	6F	Multisnare	Proximal end	0.7
12	18 y/o	F	50 kg	SARCOMA	PC	VCS-RV	6 cm	FV	7F	Multisnare	Distal end	4.1
13	13 y/o	F	43 kg	BURNED	GW	VCI-RA-RV-VCS	50 cm	HV	5F	Multisnare	Distal end	4.7
14	39 y/o	M	65 kg	TRAUMA	GW	FV	50 cm	FV	7F	Multisnare	Proximal end	3
15	16 y/o	M	45 kg	CKD	DLC	VCI-RA	15 m	FV	14F	Multisnare	Proximal end	5.9
16	7 y/o	F	24 kg	PS	Fragmented sheath FV	FV	8.5 cm	FV	5F	Multisnare	Distal end	3.1

m/o, months old; y/o, years old; PM, prematurity; İCH, intracranial hemorrhage; NEC, necrotizing enterocolitis; ALL, acute lymphoblastic leukemia; CKD, chronic kidney disease; PS, pulmonary stenosis; UVC, umbilical vein catheter; PC, port catheter; GW, guide wire; RA, right atrium; PFO, patent foramen ovale; PV, pulmonary vein; DV, ductus venosus; VCI, vena cava inferior; L, liver; RV, right ventricle; RPA, right pulmonary artery; LPA, left pulmonary artery; VCS, vena cava superior; FV, femoral vein; HV, hepatic vein; SV, subclavian vein; UV, umbilical vein.

Figure 1. (A) Angiographic images of an embolized catheter in RA-PFO-PV. (B) In order to retrieve the embolized catheter by a snare, the cut pigtail and floppy wire were taken a tour around the catheter. (C) The embolized catheter is snared. (D) Pulling back of the catheter. RA, right atrium; PFO, patent foramen ovale; PV, pulmonary vein.

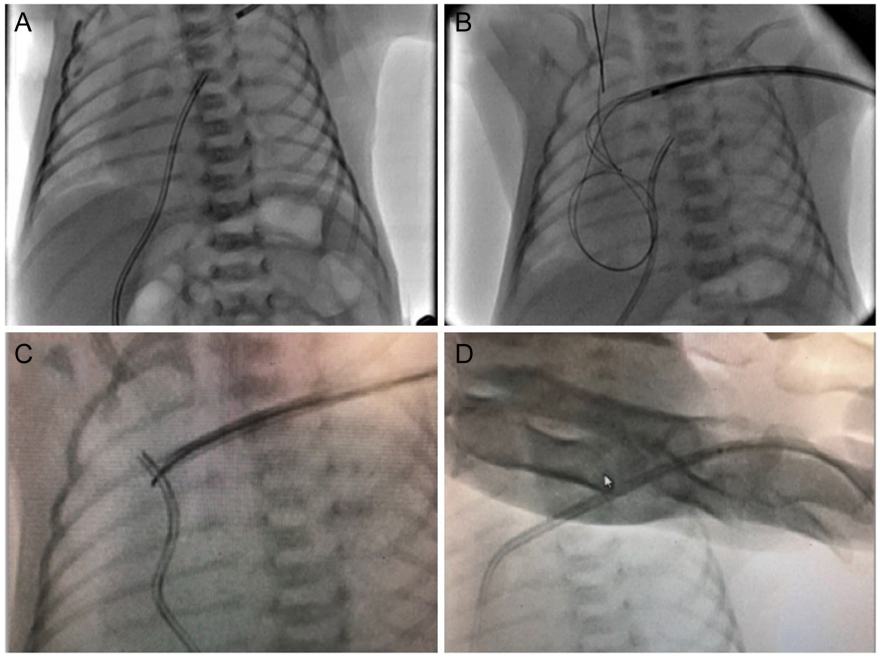

Figure 2. (A) Angiographic images of the distal part of the umbilical catheter extending from the umbilical vein- the ductus venosus to the VCI, embolized catheter advanced from the rear by an umbilical catheter inserted into the umbilical vein. (B) Embolized catheter is grabbed in VCS. (C) Pulling back of the embolized catheter. (D) Withdrawal from the femoral vein into the sheath. VCI, vena cava inferior; VCS, vena cava superior.

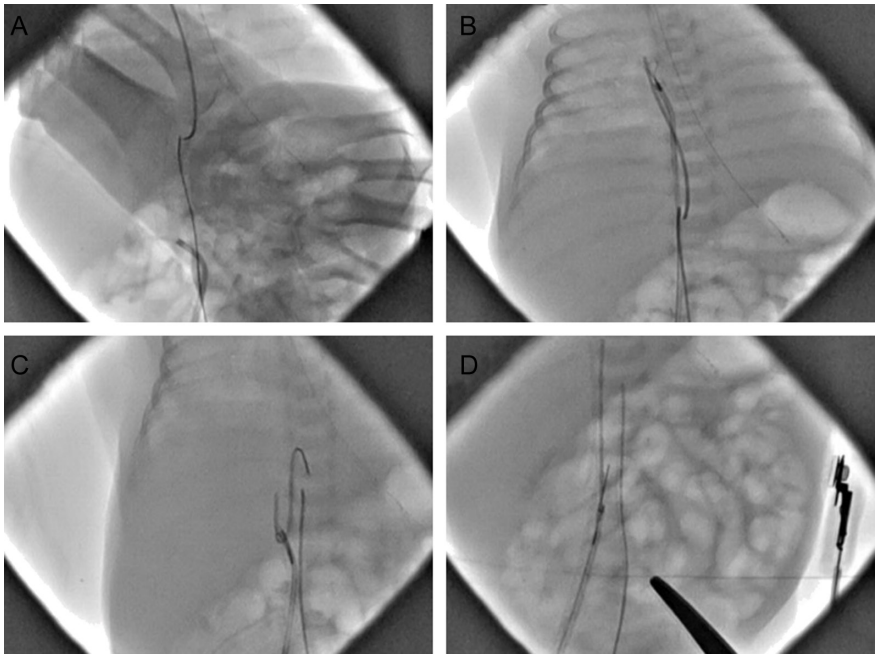

Figure 3. (A) Image shows an embolized catheter in the VCI. (B) Grabbing the proximal end of the embolized catheter by a snare. (C) Withdrawal into the catheter. (D) Narrowing in VCI. (E) Balloon application to VCI. (F) The image shows the opening of the lumen in the control injection. VCI, vena cava inferior.

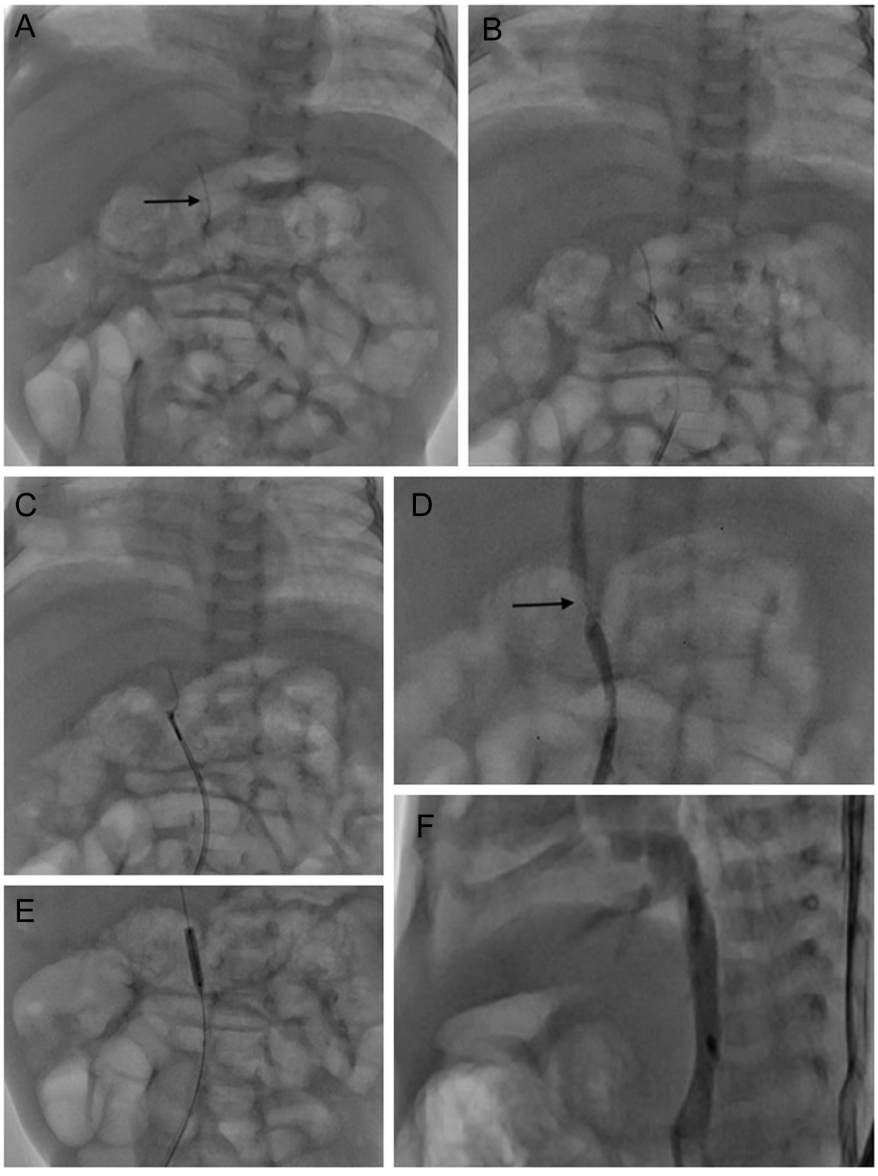

Pulmonary balloon valvuloplasty was applied to another patient due to valvular and infundibular stenosis. At the end of the procedure, while the 8F sheath was withdrawn, the 8.5 cm intravascular part of the sheath remained in the femoral vein. Then, the puncture needle was inserted into the sheath and the hydrophilic guide was advanced, 5F sheath was placed, 13F Mullins long sheath was placed in the left femoral vein, then the sheath was caught in the right atrium with a basket catheter and retrieved (Figure 6).[5] All procedures were successful and no complications were observed during follow-up.

DISCUSSION

Umbilical vein catheterization is a frequently used procedure, especially in low birth weight premature infants for parenteral nutrition, drug administration, blood sampling. It is usually simple and safe, but may rarely cause complications such as infection, thrombosis, arrhythmias, embolizations, and catheter fractures. Serious clinical findings ranging from arrhythmia to sudden death may occur in patients with catheter fractures and embolization.[1,2] Placement, care, and retrieval of UVC should be done by experts. The most common causes of embolization are the movement of the patient, inappropriate use of scissors or scalpels during these procedures. Embolization of UVC is rare in the literature, there are limited case reports.[1,2,6-8]

The number of cases is quite high in our study. According to our knowledge, it is the largest series in the literature. We think that the reason for the high incidence of UVC embolizations in our

Figure 4. (A) The embolized port catheter extending from the right pulmonary artery branch to the left upper lobe of the lung. (B) The mobile end of the embolized catheter in the right pulmonary artery is grabbed by a snare. (C) Pulling back into the catheter. (D) Withdrawing from the femoral vein into the sheath.

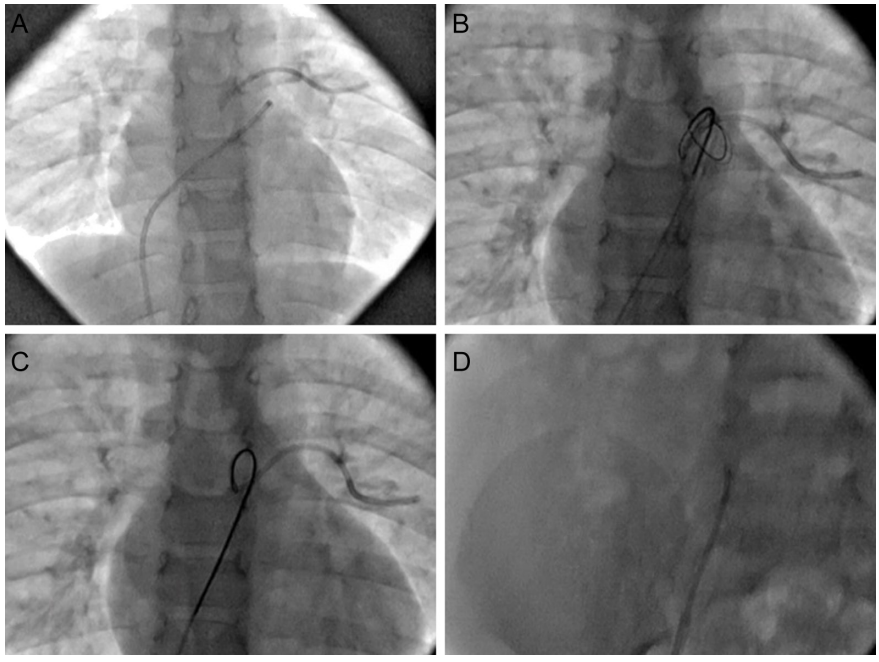

series is the high number of referrals from other hospitals as our center is a reference center.

The presence of foreign bodies in premature babies predisposes a risk for thrombus formation. Therefore, it is recommended to retrieve embolized catheters immediately at the time of diagnosis, rather than starting heparin due to the risk of intracranial bleeding.[7]

The embolization time of the patients except one was uncertain and there were no symptoms. Embolization occurred 4 days ago in 1 patient and there were no symptoms. It has been reported that the patient is asymptomatic although a period of 2 months passed after embolization.[8]

It has been reported that 1 premature patient deteriorates 11 days after being extubated and then re-intubation is performed.[6] After detailed re-evaluation of the patient, it has been determined that the umbilical vein catheter is embolized from the hepatic vein into the right upper pulmonary vein on chest radiography. The embolized catheter was removed successfully percutaneously. Then, the general condition of the patient improved and he was discharged 5 days later.

Central venous catheters are frequently used in parenteral nutrition and for monitoring hemodynamic parameters. These procedures have also complications as in other interventional procedures. The main complications are infection, catheter embolization, and arrhythmias. Embolization mechanisms of PC differ. In the study of Surov et al.[3] embolizations were mostly noticed due to pinch-off syndrome. The other reasons they detected were catheter damage, distal and proximal catheter fractures, disconnection of the port reservoir from the port cannula during catheter replacement or removal, respectively. The reasons for the embolizations of PC are incorrect locking of the PC connection, strong injection, pulling of the extravascular part of the catheter by the chest wall soft tissues.

Disconnection of the port reservoir and cannula part and embolization was observed in 6 of our patients (Figure 4). While the reservoir of the PC was surgically removed, the distal part of 1 cm PC was ruptured and embolized in one of our patients. Another cause of catheter fracture is catheter fatigue. Catheters that remain in the body for a long time become fragile and fractures are more commonly seen. Embolization was not noticed in one of the patients, because the PC was not used for a long time, and the patient was also asymptomatic. The cause of embolization in this patient may be increased fragility due to catheter fatigue. Therefore, unused PCs should be removed as soon as possible to prevent complications.

Duration of embolization is very different for each patient. After implantation, the duration of catheter embolization is difficult to determine. An embolized catheter is often noticed in the chest radiography taken incidentally. Therefore, sometimes it may remain unnoticed for a long time. To evaluate the risk of embolization, the PC should be examined regularly by the chest x-ray after insertion.[9,10]

In our study, the most common embolization site is the right ventricle, mostly extending from the right atrium to the pulmonary

Figure 5. (A) The embolized guide wire is observed in this chest x-ray from the midpoint of the superior caval vein to the iliac vein, with a loop in the heart. (B) Entrance to the liver with the Chiba needle. (C) The manual contrast medium injection through the Chiba needle reveals the blood flow to the heart with the hepatic vein and the portal venous flow spread in the portal area. (D) The coronary guide wire inside the Chiba needle is advanced from the hepatic vein to the inferior caval vein and right atrium. (E and F) The embolized guide wire (arrow), which is trapped between the 2 right Judkins catheters and the hydrophilic guide wire, is advanced inside the long sheath.

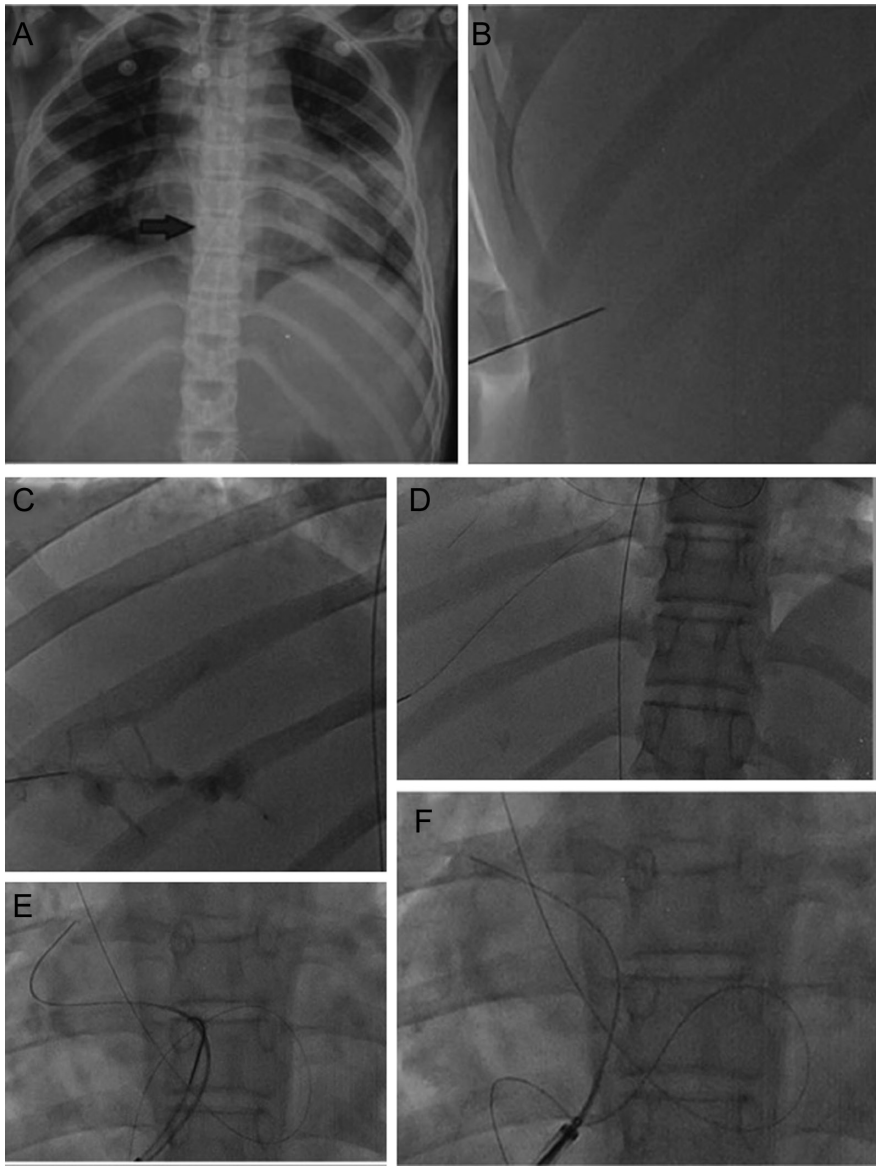

artery. In the study conducted by Surov et al.[3] catheter embolizations were mostly in the pulmonary artery. The most common association was the right ventricle and the pulmonary artery, and catheter parts were long enough to cover several regions. It has been reported that localizations of PC embolization are in different parts of the cardiovascular system such as the superior vena cava, right atrium, right ventricle, or pulmonary artery in 7 patients.[9] In the study conducted by Pazinato et al.[11] the embolization site was pulmonary artery in 44.1% of the patients. The localization of the embolized catheter fragments in the cardiovascular system varies depending on the length and stiffness of the embolized substance, and the flow pattern of the reservoir or vessel. Most fragments embolize to the superior vena cava, right ventricle, and/or pulmonary artery. Flexible long catheter fragments inserted into the subclavian vein usually go to the right ventricular trabeculum and settle there. Shorter pieces of catheter go into the smaller branches of the pulmonary artery and are more difficult to retrieve.[9]

After venous catheter embolization, mortality and morbidity depend on the localization of the embolized parts. The highest

Figure 6. (A) Opened basket catheter attempt to snare the sheath with a coaxial position in the right atrium. (B) The whole system was slowly withdrawn from the opposite femoral vein.

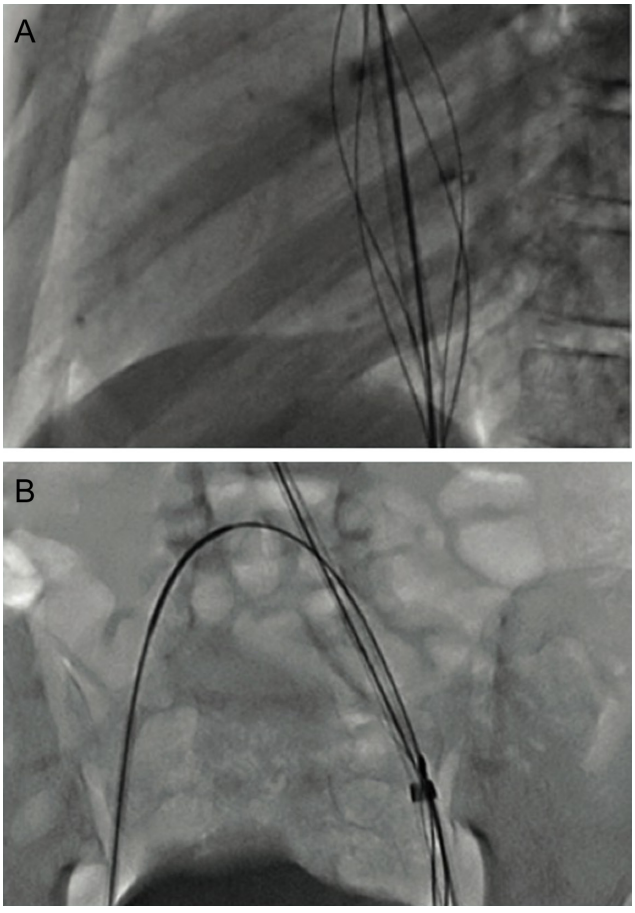

mortality is seen when catheter fragments are compressed in the right ventricle. Less mortality in the pulmonary artery and the least mortality are seen in the vena cava or peripheral veins.[3] There was no mortality in our study. We were successful in 15 of 16 patients. Our success rate was 93.7%. The reason for the failure in 1 patient was that the umbilical catheter is stuck horizontally in the ductus venosus. Despite repeated attempts through the venous system, the embolized catheter could not be removed because there was no free tip.

The major limitation of our study was that it is retrospective. In contrast to that, the number of our patients was high since our hospital is the reference center of the region. We think that this will increase the impact of the study.

CONCLUSION

As a result, embolized catheters are difficult to diagnose and may remain unnoticed for a long time. It should be removed at the time of diagnosis, and embolized catheters can be retrieved with loop snare and its modification in most cases. Percutaneous retrieval of intravascular foreign bodies is a reliable, successful, effective, and first-choice method in experienced hands, and should be considered as the first step of treatment due to the high success rate and minimal risk of the procedure. Percutaneous intervention should be tried even in delayed cases before referring it to surgery.

Ethics Committee Approval: Ethics committee approval was received for this study from the ethics committee of Gaziantep University (Date: June 30, 2021, Decision number: no: 2021/170).

Informed Consent: N/A.

Peer-review: Externally peer-reviewed.

Author Contributions: Concept – D.A.S., O.B.; Design – D.A.S., M.T.T., O.B.; Supervision – O.B.; Materials – D.A.S., M.T.T., O.B.; Data collection &/or processing – D.A.S., M.T.T.; Analysis and/or interpretation – D.A.S., O.B.; Literature search – D.A.S., M.T.T., O.B.; Writing – D.A.S., O.B.; Critical review – D.A.S., O.B.

Declaration of Interests: The authors have no conflicts of interest to declare.

Funding: The authors declared that this study has received no financial supportt.

REFERENCES

1. Nigam A, Trehan V, Mehta V. Umbilical venous catheter retrieval in a 970 gm neonate by a novel technique. *Ann Pediatr Cardiol*. 2014;7(1):52-54. [CrossRef]
2. Demirel A, Güven G, Okan F, Saygılı A. Successful percutaneous removal of broken vein catheter in a very low-birth-weight preterm infant. *Turk Kardiyol Dern Ars*. 2016;44(8):700-702. [CrossRef]
3. Surov A, Wienke A, Carter JM, et al. Intravascular embolization of venous cathater causes, clinical signs, and management: a systematic review. *JPEN J Parenter Enteral Nutr*. 2009;33(6):677-685. [CrossRef]
4. Baspinar O, Sahin DA, Yildirim A. Retrieval of an intra-cardiac embolised ver long wire via transhepatic access from a war victim child. *Cardiol Young*. 2016;26(4):784-786. [CrossRef]
5. Başpınar O, Aldudak B, İrdem A. Case images: an 8 French introducer embolized into the patient's femoral vein. *Turk Kardiyol Dern Ars*. 2012;40(3):284. [CrossRef]
6. Varan B, Yakut K,Harman A. Transcatheter retrieval of embolized catheter using venovenous loop in a neonate. *Turk J Pediatr*. 2018;60(1):113-115. [CrossRef]
7. Gasparis AP, Santana D, Blewett C, Bohannon WT, Silva MB. Endoluminal retrieval of a dislodged umbilical vein catheter: a case report. *Vasc Endovasc Surg*. 2004;38(6):583-586. [CrossRef]
8. Akın A, Bilici M, Demir F, Yılmazer MM, İpek MŞ, Kara H. Percutaneous retrieval of umblical vein catheter fragment in an infant two months after embolization. *Turk J Pediatr*. 2018;60(2):191-193. [CrossRef]
9. Yen HJ, Hwang B, Lee PC, Meng CC. Transcatheter retrieval of different types of central venous catheter fragment: experience in 13 cases. *Angiology*. 2006;57(3):347-353. [CrossRef]
10. Baspinar O, Sulu A, Sahin DA. Transcatheter removal of embolized port catheters from the hearts of two children. *Case Rep Cardiol*. 2015;2015:973196. [CrossRef]
11. PazinatoLV, Leite TFO, Bortolini E, Pereira OI, Nomura CH, Motta-Leal-Filho JMD. Percutaneous retrieval of intravascular foreign body in children: a case series and review. *Acta Radiol*. 2021:2841851211006904. [CrossRef]