Original Article

Access this article online
Quick Response Code:

Website:
www.eurasianjpulmonol.com

DOI:
10.4103/ejop.ejop_14_18

Robotic surgery in mediastinal cystic pathologies

Erkan Kaba, Kemal Ayalp[1], Tugba Cosgun, Alper Toker[1]

Abstract:

PURPOSE: In this study, results of surgery for patients with mediastinal cystic pathology who were treated by the utilization of robotic surgery system were analyzed.

MATERIALS AND METHODS: Prospectively collected data of 296 patients on whom robotic surgery system was used between October 2011 and June 2017 were retrospectively examined. Of these patients, 9 (3%) patients who were operated due to cystic pathologies of mediastinum were included in this study. Age, gender, docking, and console times of the robot, pathology results, length of hospital stay, anatomic localization of the lesions, blood transfusion requirement, conversion to open surgery, mortality, and morbidity rates were recorded.

RESULTS: Five patients were male and 4 were female, and the mean age was 45.5 ± 21.2 years. The lesion was localized in anterior mediastinum in two patients, middle mediastinum in four patients, and in posterior mediastinum in three patients. Six patients underwent surgery with the diagnosis of bronchogenic cyst, one patient underwent surgery with the diagnosis of the pericardial cyst, and two patients underwent surgery with the diagnosis of the thymic cyst. The mean length of hospital stay was 3.3 ± 1.5 days. The median console time was 45 min (30–110 min) and the median docking time was 20 min (10–40 min).

CONCLUSION: We consider that, with technical advantages provided to the surgeon in mediastinal surgery, robotic technology can be preferred in cystic pathologies of the mediastinum localized in areas that may pose challenges in dissection.

Keywords:

Bronchogenic cyst, mediastinal cystic pathologies, robotic surgery

Introduction

Mediastinal cysts are rarely encountered lesions in the practice of thoracic surgery. They constitute 15%–20% of all mediastinal lesions.[1] They are divided into two groups as congenital and acquired lesions. Bronchogenic cysts, esophageal cysts, and pericardial cysts are some of the congenital cysts of the mediastinum. Thymic cysts and dermoid cysts can be given as an example to acquired cysts of the mediastinum. These lesions are mostly asymptomatic and incidentally detected. These lesions may manifest with compression symptoms as they grow over the years or with infections when the lesion becomes infected. In the study conducted by Takeda *et al.*, it was reported that bronchogenic cysts are observed at a rate of 44.8% and tyhmic cysts are observed at a rate of 28.6% among other mediastinal cysts.[1]

Sternotomy and thoracotomy are traditional surgical approaches in mediastinal pathologies. Even though video thoracoscopic surgery is not a routine procedure, it is more commonly used in mediastinal surgery.[2] One of the recently published studies report limited movement ability of standard thoracoscopic instruments poses problems in narrow anatomic spaces. Robotic surgery is reported to have advantage and superiorities in technically difficult areas.[3]

Received: 18.09.2017
Accepted: 22.11.2017

Department of Thoracic Surgery, Istanbul Bilim University, [1]Department of Thoracic Surgery, Group Florence Nightingale Hospital, Istanbul, Turkey

Address for correspondence:
Prof. Erkan Kaba, Abide İ Hürriyet Cad. No: 164 Şişli, Istanbul, Turkey.
E-mail: erkankaba@hotmail.com

This is an open access journal, and articles are distributed under the terms of the Creative Commons Attribution-NonCommercial-ShareAlike 4.0 License, which allows others to remix, tweak, and build upon the work non-commercially, as long as appropriate credit is given and the new creations are licensed under the identical terms.

For reprints contact: reprints@medknow.com

How to cite this article: Kaba E, Ayalp K, Cosgun T, Toker A. Robotic surgery in mediastinal cystic pathologies. Eurasian J Pulmonol 2018;20:65-69.

In our previous studies, we analyzed the outcomes in patients with surgical thoracic pathologies in the scope of our robotic surgery program and reported that robotic surgery could safely and successfully transfer technical skills of the surgeon to minimally invasive methods.[4-6]

In this study, our surgical results on mediastinal cysts using the da Vinci robotic system (Intuitive Surgical, Inc., Mountain View, California, USA) and technical details are presented.

Materials and Methods

Of 296 patients who underwent thoracic surgical intervention using da Vinci robotic system between October 2011 and June 2017, 9 (3%) patients who were operated due to mediastinal cystic disease, were included in the study. Prospectively, recorded data of these patients were retrospectively examined. Age, gender, docking and console times, pathology results, length of hospital stay, anatomic localizations of the lesions, blood transfusion requirement, rate of conversion to open surgery, lesion sizes, and mortality and morbidity rates were recorded; patients attended outpatient control visits 1 week after surgery, and thoracic computed tomography (CT) scans were obtained at 1-year control visits and the results were recorded. The docking time is calculated as the time between the first skin incision and the beginning of the use of the robotic arm from the console, and the console time is calculated as the time from when console surgeon starts using the robotic arms to the time when the robotic surgeon leaves the console.

Operative technique

After single-lung ventilation was provided with a double-lumen endobronchial tube placed with the help of a pediatric flexible bronchoscope under general anesthesia, heart rate, arterial blood pressure, and oxygen saturation of the patients were monitored. The patient was brought to 30 degrees semi-supine position if the lesion was located in the anterior mediastinum. Due to our experience in video-assisted thoracoscopic surgery (VATS) thymectomy, in patients for which we prefer the right-sided approach in robotic excision of anterior mediastinal lesions, the patients were supported with a roll under the right shoulder and then, the right arm was brought below the level of rib cage [Figure 1]. Three robotic arms were used in all surgeries. Incisions were performed around the breast without violating the breast tissue. First port was opened as a camera port in the 7th intercostal space (ICS) on the anterior axillary line, and other ports were placed with the help of zero degrees camera. The surgeon switched to 30 degrees up and down the camera when needed during surgery. Robotic left arm port was opened on the anterior axillary fossa, and right arm was opened on the 5th or 6th ICS on the

Figure 1: Patient position in operations at anterior mediastinum and trocar placements

midclavicular line. After the ports were placed, the robot arms docked on the patient by side docking [Figure 2]. The working area was expanded with CO_2 insufflations at a pressure of 6 mmHg and a flow rate of 6 L/min until the opposite pleura opened. Prograsper forceps (Intuitive Inc., Sunnyvale, CA, USA) was preferred in the robotic left arm, and Maryland dissector was preferred in the robotic right arm (Intuitive Inc., Sunnyvale, CA, USA).

Patients, who underwent surgery for lesions localized in the posterior or middle mediastinum, were placed in lateral decubitus position slightly tilted anteriorly. Surgical table was repositioned as to be 30 degrees to the perpendicular axis of the room. After the camera port was placed from posterior axillary line 8th ICS, right arm were placed from line 5th ICS and anterior axillary line, left arm were placed from the 8th ICA and posterior axillary line with the help of 30 degrees camera in a way to have at least 10 cm between each other [Figure 3]. After all these incisions, the robot was docked from the posterior [Figure 4]. After exposing the lesion, the pleura was opened with Maryland dissector, cyst contents were aspirated, and the cyst was excised with its capsule. After complete excision, the specimen was brought out from the anterior port incision with the help of Endo-bag (End Catch™ Specimen pouch 15-mm, Covidien Mansfield, MA, USA). After performing intercostal blockage with bupivacaine hydrochloride (Marcaine) 10–15 mg infiltration at all levels, 28F chest tube was placed into the thorax cavity through the anterior port incision, and the surgery was completed. The patients were extubated in the operating theatre and then transferred to the recovery room.

Results

Outpatients who were operated with the diagnosis of mediastinal cyst, 6 (67%) had bronchogenic cysts, 1 (11%)

had pericardial cyst, and 2 (22%) had thymic cysts. The youngest patient was 8-year-old and the eldest patient was aged 74-year-old, and both patients underwent surgery with the diagnosis of bronchogenic cyst. The most commonly observed symptom was cough that occurred in 33% of the patients, whereas the cysts were incidentally detected in four patients. The mean age of the patients was 45.5 ± 21.2 years. The data of these 9 patients are shown in Table 1. Surgery was completed with robotic approach in all patients without requiring utility incisions and none of the patients required conversion to open surgery. The mean console time was 55.5 ± 23.7 min and the mean docking time was 19.4 ± 8.9 min. The shortest console time was 30 min and this patient was operated due to bronchogenic cyst. The longest console time was 100 min and this patient also operated due to bronchogenic cyst and decortication. The mean operating time was 75 ± 29.5 min. The mean length of hospital stay was 3.3 ± 1.5 days. The largest cyst diameter was, on an average 48 mm (20–70 mm). Complete cyst excision was carried out in all patients. Blood transfusion was not performed in any of the patients. No mortality or morbidity occurred in any of the patients. The mean follow-up for this group was 34 months (range, 3–57 months). The patients were followed up with physical examination and thoracic CT with 6-month intervals and no relapse was detected in their follow-up.

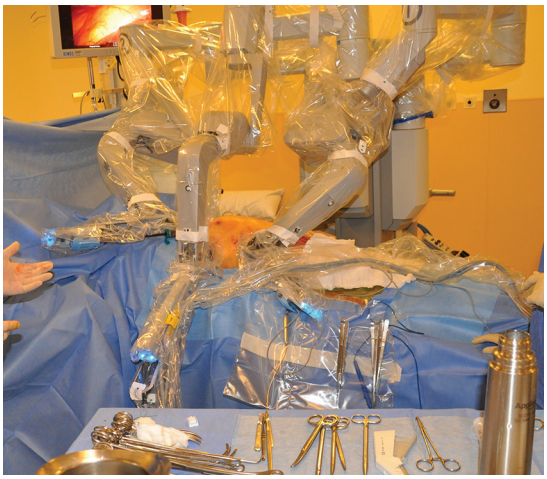

Figure 2: Docking of robot at cases with anterior mediastinal lesions

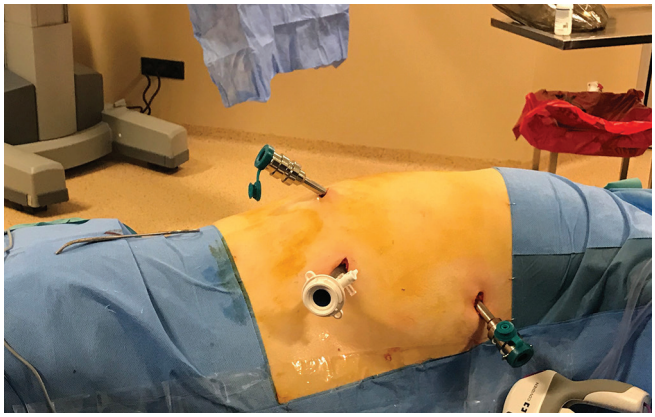

Figure 3: Patient position and localizations of ports in cases with middle or posterior mediastinal lesions

Figure 4: Docking of robot in patients with middle or posterior mediastinal lesions

Discussion

Routine surgical procedure in mediastinal cysts is excision with open surgery;[7] In recent years, studies supporting excision of mediastinal cysts with minimally invasive procedures have started to appear.[8-10] Mediastinal cysts are mostly located in the vicinity of vital organs such as trachea, esophagus, and aorta and thus, even though video thoracoscopic surgery is less invasive than open surgery, there may be difficulties during the dissection of mediastinal cysts due to narrow spaces. The basis of surgical innovation is causing less morbidity and mortality while increasing treatment success. We observe the transition from open surgery to thoracoscopic surgery and from thoracoscopic surgery to robotic surgery as a result of the innovation. Thus, in recent years, minimally invasive procedures have become preferable in thoracic surgery, as is the case in all other surgical branches.[11] Robotic surgery can be seen as the state of the art in minimally invasive surgery technology with its technical characteristics such as high-resolution image acquisition, tremor filtration, and the ability to move in more axes. In recent years, some authors have published studies, which report that robotic technologies are safe and applicable in mediastinum lesions requiring complete resection due to advantages of robotic technology to the surgeon.[12-15] Working thoracoscopically in close proximity to vulnerable large vessels and nerves poses an increased risk. There is very little space, the image of the operating field on the monitor is two-dimensional only, and a surgeon's tremor is heightened by the long instruments. Of any thoracic surgery, mediastinal procedures is the one for which

Table 1: The data of patients

Symptom	Age	Sex	Docking time (min)	Console time (min)	Localization	Size (mm)	Pathology	Length of stay in hospital (day)
No	19	M	40	80	Middle mediastinum	45×30×5	Bronchogenic cyst	2
Fever, cough	44	F	25	60	Anterior mediastinum	52×40×20	Thymic cyst	3
No	8	F	20	55	Middle mediastinum	35×20×10	Bronchogenic cyst	2
Abdominal pain	62	F	20	110	Posterior mediastinum	70×30×20	Bronchogenic cyst	6
No	43	F	10	45	Middle mediastinum	50×20×20	Pericardial cyst	3
No	68	M	10	40	Middle mediastinum	60×50×30	Bronchogenic cyst	6
Cough	59	M	10	30	Posterior mediastinum	30×20×15	Bronchogenic cyst	2
Cough	33	M	20	40	Anterior mediastinum	10×10×70	Thymic cyst	3
No	74	M	20	40	Posterior mediastinum	20×15×5	Bronchogenic cyst	3

Min: Minute M: Male F: Female

Figure 5: Thorax CT scan of infected bronchogenic cyst

the robot's characteristics have significant advantage.[16] In this study, robotic mediastinum cyst excision was performed in 9 patients with mediastinal cysts. The mean length of hospital stay was 3.3 ± 1.5 days and no complications occurred and no relapse was observed in any of the patients during the follow-up period.

One of the patients required decortication, and complete excision of the bronchogenic cyst was performed. This patient was also undergoing hemodialysis due to chronic renal failure. The CT scan images of this patient before and after infection are shown in Figure 5. In another patient, bronchogenic cyst extended from posterior mediastinum beyond the diaphragm. In this patient, complete excision was performed by opening the diaphragm, and the diaphragm was primarily closed robotically. The chest X-ray of this patient is shown [Figure 6]. Another patient was aged 8 years, and this patient underwent robotic excision with the diagnosis of bronchogenic cyst.[17] We believe that safe dissection can be carried out in small thoracic cavities due to the ability of the robotic arms to move in multiple axes and this patient was published as the youngest robotic surgery case ever treated in Turkey.[17]

It was reported in some studies that the mean operating time in mediastinal surgery using the da Vinci robotic technology is between 120 and 175 min.[18-20] In this study, the mean operating time was 75 ± 29.5 min. The mean operating time was reported to be 104 ± 34 min in another study published by the present authors where

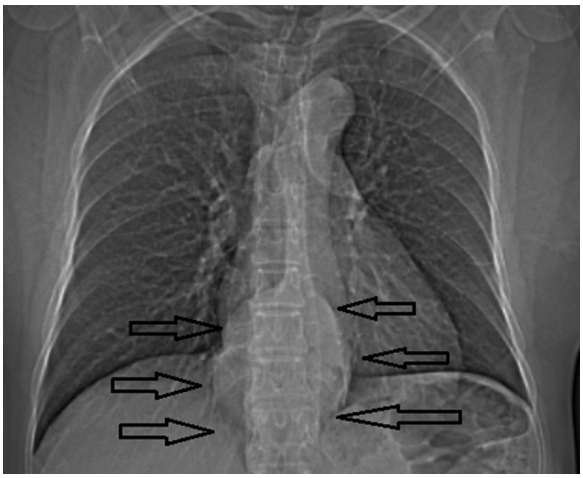

Figure 6: X-ray of bronchogenic cyts that extended from posterior mediastinum beyond the diaphragm

the outcomes in patients after anatomic lung resection were published.[6] In our robotic surgery program which was started in October 2011, the authors preferred lung resections as the first cases to be treated in the scope of the program. As our experience increased in robotic surgery, we started using it in mediastinal pathologies, and it can be considered that due to our high experience in VATS, especially in thymus surgery, our mean operating time is shorter than those reported in the literature.

Conclusion

We believe that in centers, which have completed the learning curve in open mediastinal surgery and where thoracoscopic surgery is routinely performed in daily practice, robotic surgery procedures can easily be adapted. Moreover, the transfer of technical skills to the patient and can be performed with the anticipation of lower morbidity in surgical diseases of the mediastinum.

In mediastinum surgery, we prefer robotic system due to technical superiorities provided to the

surgeon. In mediastinal cystic pathologies, especially bronchogenic cysts that are located in regions, which may cause difficulty in dissection due to adhesions to vital organs, and where complete resection is inevitable, robotic surgery may provide superiorities.

Declaration of patient consent

The authors certify that they have obtained all appropriate patient consent forms. In the form the patient(s) has/have given his/her/their consent for his/her/their images and other clinical information to be reported in the journal. The patients understand that their names and initials will not be published and due efforts will be made to conceal their identity, but anonymity cannot be guaranteed.

Financial support and sponsorship

Nil.

Conflicts of interest

There are no conflicts of interest.

References

1. Takeda S, Miyoshi S, Akashi A, Ohta M, Minami M, Okumura M, *et al*. Clinical spectrum of primary mediastinal tumors: A comparison of adult and pediatric populations at a single Japanese institution. J Surg Oncol 2003;83:24-30.
2. Roviaro G, Rebuffat C, Varoli F, Vergani C, Maciocco M, Scalambra SM. Videothoracoscopic excision of mediastinal masses: Indications and technique. Ann Thorac Surg 1994;58:1679-83.
3. Melfi FM, Fanucchi O, Mussi A. Minimally invasive mediastinal surgery. Ann Cardiothorac Surg 2016;5:10-7.
4. Toker A, Ayalp K, Uyumaz E, Kaba E, Demirhan O, Erus S, *et al.* Robotic lung segmentectomy for malignant and benign lesions. J Thorac Dis 2014;6:937-42.
5. Demir A, Ayalp K, Ozkan B, Kaba E, Toker A. Robotic and video-assisted thoracic surgery lung segmentectomy for malignant and benign lesions. Interact Cardiovasc Thorac Surg 2015;20:304-9.
6. Toker A, Özyurtkan MO, Kaba E, Ayalp K, Demirhan Ö, Uyumaz E. Robotic anatomic lung resections: The initial experience and description of learning in 102 cases. Surg Endosc 2016;30:676-83.
7. Shields TW. Overview of primary mediastinal tumors and cysts. In: Shields TW, LoCicero J, Ponn RB, Rusch VW, editors. General Thoracic Surgery. 6th ed., Vol. 2. Philadelphia: Lippincott Williams & Wilkins; 2005. p. 2489-93.
8. Weber T, Roth TC, Beshay M, Herrmann P, Stein R, Schmid RA, *et al*. Video-assisted thoracoscopic surgery of mediastinal bronchogenic cysts in adults: A single-center experience. Ann Thorac Surg 2004;78:987-91.
9. Tölg C, Abelin K, Laudenbach V, de Heaulme O, Dorgeret S, Lipsyc ES, *et al*. Open vs. thorascopic surgical management of bronchogenic cysts. Surg Endosc 2005;19:77-80.
10. De Giacomo T, Diso D, Anile M, Venuta F, Rolla M, Ricella C, *et al.* Thoracoscopic resection of mediastinal bronchogenic cysts in adults. Eur J Cardiothorac Surg 2009;36:357-9.
11. Suda T, Sugimura H, Tochii D, Kihara M, Hattori Y. Single-port thymectomy through an infrasternal approach. Ann Thorac Surg 2012;93:334-6.
12. Yoshino I, Hashizume M, Shimada M, Tomikawa M, Tomiyasu M, Suemitsu R, *et al.* Thoracoscopic thymomectomy with the da vinci computer-enhanced surgical system. J Thorac Cardiovasc Surg 2001;122:783-5.
13. Bodner J, Wykypiel H, Wetscher G, Schmid T. First experiences with the da vinci operating robot in thoracic surgery. Eur J Cardiothorac Surg 2004;25:844-51.
14. Rea F, Bortolotti L, Girardi R, Sartori F. Thoracoscopic thymectomy with the 'da vinci' surgical system in patient with myasthenia gravis. Interact Cardiovasc Thorac Surg 2003;2:70-2.
15. Yoshino I, Hashizume M, Shimada M, Tomikawa M, Sugimachi K. Video-assisted thoracoscopic extirpation of a posterior mediastinal mass using the da vinci computer enhanced surgical system. Ann Thorac Surg 2002;74:1235-7.
16. Weissenbacher A, Bodner J. Robotic surgery of the mediastinum. In: Ferguson MK, Mineo TC, editors. Thoracic Surgery Clinics. Technical Advances in Mediastinal Surgery. Philadelphia: Elsevier Inc.; 2010. p. 331-9.
17. Toker A, Ayalp K, Grusina-Ujumaza J, Kaba E. Resection of a bronchogenic cyst in the first decade of life with robotic surgery. Interact Cardiovasc Thorac Surg 2014;19:321-3.
18. Bodner J, Wykypiel H, Greiner A, Kirchmayr W, Freund MC, Margreiter R, *et al.* Early experience with robot-assisted surgery for mediastinal masses. Ann Thorac Surg 2004;78:259-65.
19. Rea F, Marulli G, Bortolotti L, Feltracco P, Zuin A, Sartori F. Experience with the "da vinci" robotic system for thymectomy in patients with myasthenia gravis: Report of 33 cases. Ann Thorac Surg 2006;81:455-9.
20. Fleck T, Fleck M, Müller M, Hager H, Klepetko W, Wolner E, *et al.* Extended videoscopic robotic thymectomy with the da vinci telemanipulator for the treatment of myasthenia gravis: The vienna experience. Interact Cardiovasc Thorac Surg 2009;9:784-7.