[Downloaded free from http://www.eurasianjpulmonol.com on Friday, March 27, 2020, IP: 10.232.74.26]

Case Report

Access this article online
Quick Response Code:

Website:
www.eurasianjpulmonol.com

DOI:
10.4103/ejop.ejop_11_19

Pulmonary eosinophilia associated with recent waterpipe smoking

Muhammet Nesim Reşat Noristani, Pınar Yıldız Gülhan[1], Cemil Işık Sönmez, Mehmet Gamsizka[2]

ORCID:
Muhammet Nesim Reşat Noristani: https://orcid.org/0000-0001-5292-1547
Pınar Yıldız Gülhan: https://orcid.org/0000-0002-5347-2365
Cemil Işık Sönmez: https://orcid.org/0000-0001-7854-3804
Mehmet Gamsizka: https://orcid.org/0000-0001-9942-4898

Abstract:

Acute eosinophilic pneumonia (AEP) is one of the causes of acute respiratory failure. Classical clinical picture includes acute febrile illness, bilateral pulmonary opacities, pulmonary eosinophilia, hypoxia, and pleuritic chest pain. We observed AEP with atypical presentation after recent waterpipe (hookah) smoking in our patient. We reported the case of a male with laboratory AEP findings without the typical clinical presentation which resolved after abstinence from waterpipe smoking.

Keywords:

Acute eosinophilic pneumonia, pulmonary eosinophilia, smoking habits, waterpipe smoking

Introduction

Description of acute eosinophilic pneumonia (AEP) has been made in 1989 as one of the causes of acute respiratory failure. Classical clinical picture includes acute febrile illness, bilateral pulmonary opacities, pulmonary eosinophilia, hypoxia, and pleuritic chest pain. The exact mechanism of AEP has not been clarified yet. It is believed that AEP is caused by a hypersensitivity reaction to an unknown inhaled antigen.[1,2] A significant relation between changing smoking habits, recent waterpipe smoking, and AEP has been suggested in numerous studies.[3-8] In our case, we observed AEP with atypical presentation after recent waterpipe (hookah) smoking.

Case Report

A male patient in his thirties presented to the family medicine clinic with the complaints of cough with tiny amounts of yellow-colored sputum production, runny nose, chills, and sweating. Chronic cough was present for 15 years but increased in frequency for the last month. He has a smoking history of 10 packages per year and quitted cigarette smoking 5 years ago. He is an active waterpipe smoker two times a week for the past 2 months. He had no history of alcohol and using illicit drugs.

Medical history includes 10 days of admittance for acute bronchitis in 1998, allergic rhinitis since 2016, and positive skin test for allergy of house dust mite and pollen. Family history includes three brothers with chronic cough and bronchitis-like symptoms, his mother has hypothyroidism, two aunts and an uncle with colon cancer, another aunt has died with the diagnosis of leukemia. Occupational history was insignificant.

On physical examination, the vitals were stable (heart rate: 80 bpm, respiratory rate:

Departments of Family Medicine, [1]Pulmonology, and [2]Pathology, Düzce University Faculty of Medicine, Duzce, Turkey

Address for correspondence:
Dr. Muhammet Nesim Reşat Noristani, Department of Family Medicine, Düzce University Faculty of Medicine, Centrum, Duzce, Turkey.
E-mail: resatnoristani@gmail.com

Received: 23-02-2019
Revised: 15-04-2019
Accepted: 07-05-2019
Published: 30-12-2019

This is an open access journal, and articles are distributed under the terms of the Creative Commons Attribution-NonCommercial-ShareAlike 4.0 License, which allows others to remix, tweak, and build upon the work non-commercially, as long as appropriate credit is given and the new creations are licensed under the identical terms.

For reprints contact: reprints@medknow.com

How to cite this article: Noristani MN, Gülhan PY, Sönmez CI, Gamsizka M. Pulmonary eosinophilia associated with recent waterpipe smoking. Eurasian J Pulmonol 2019;21:204-6.

© 2019 Eurasian Journal of Pulmonology Published by Wolters Kluwer - Medknow

[Downloaded free from http://www.eurasianjpulmonol.com on Friday, March 27, 2020, IP: 10.232.74.26]

12/min, body temperature: 36.7°C, blood pressure: 110/80 mmHg, and SaO_2: 98%). Oropharynx was slightly hyperemic with serous post-nasal discharge. Expiratory rhoncus is heard over the right middle and lower pulmonary zones. Physical examination was otherwise normal.

Chest X-ray is obtained to rule out bronchial compression (tumor and foreign object). Diffuse reticular densities, bilateral hilar opacities, and a left lower sided linear atelectasis were observed on X-ray [Figure 1].

Given the history of recent waterpipe smoking and X-ray findings, high-resolution pulmonary computed tomography and flexible fiberoptic bronchoscopy obtained with the prediagnosis of interstitial lung disease and AEP. On pulmonary high-resolution computed tomography, patchy ground-glass opacities on the left lower lobe, bilateral bronchial wall thickening on the lower zones, and hazy ground-glass opacities on the right upper lobe have been observed [Figure 2]. Laboratory results revealed elevated total IgE (236 IU/ml) and bronchoalveolar lavage (BAL) cell differential with 40% polymorphonuclear leukocytes, 30% eosinophils, and 30% lymphocytes [Figure 3]. BAL cultures were negative for infective microorganisms. Antibiotics and symptomatic treatment have been started. Abstinence from waterpipe smoking is recommended. Patient's complaints resolved after 1 week of abstinence and antibiotherapy. On the follow-up, the patient has reported that he has discontinued antibiotics after the first 3 days. One month after the onset of symptoms, another X-ray has been obtained. Reticular opacities resolved slightly on the right upper zone and patient's complaints resolved completely.

Figure 1: Chest X-ray is obtained to rule out bronchial compression (tumor and foreign object). Diffuse reticular densities, bilateral hilar opacities, and a left lower sided linear atelectasis were observed

Discussion

Our patient's complaints were very benign in the context of AEP. He did not have any breathing difficulty, hypoxia, tachypnea, or pleuritic chest pain. All the vital signs were normal. His only complaints were acute febrile illness and nonproductive cough which can easily be thought as an upper respiratory tract infection.

However, we thought that it may be the very early stage of acute eosinophilic pneumonia after the detailed history, physical examination and chest X-ray findings. We thought that it may be the very early stage of acute eosinophilic pneumonia. BAL with cell differential has been obtained early as the disease tends to progress rapidly and may cause respiratory failure if the diagnosis has been delayed. Early bronchoscopy has been recommended if suspicion for etiology is present.[2,3,8] We have reviewed cases of AEP associated with recent waterpipe smoking.[5-7] All of the cases were presented with acute febrile illness, tachycardia, tachypnea, bilateral infiltrates, and progressively worsening clinical picture, which at some point required intensive care unit admission and invasive mechanical ventilation until establishing the diagnosis and initiation of corticosteroids. One of the cases required extracorporeal membranous oxygenation. All the patients were young adults and their complaints resolved completely after corticosteroid treatment. Our case presented very benign in comparison to these cases which allowed us an outpatient follow-up. Effects of waterpipe smoking on BAL cell differential have not been studied well, but there is a small scale study in which eight young healthy waterpipe smokers' BAL cell differential were compared with five lifetime

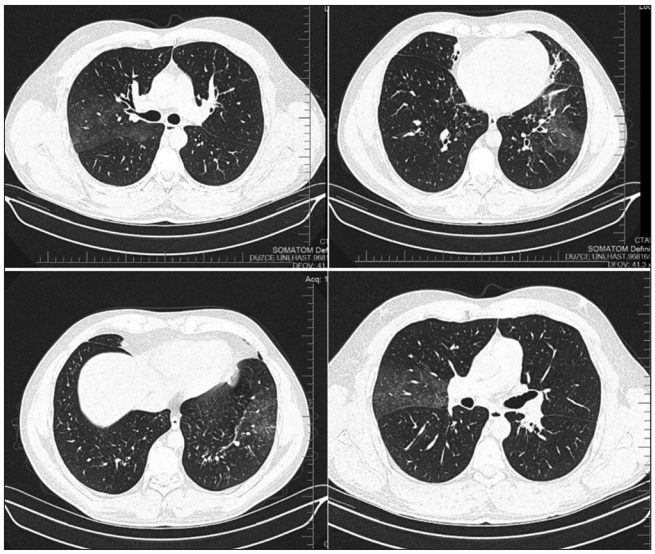

Figure 2: High-resolution computed tomography; patchy ground glass opacities on the left lower lobe, bilateral bronchial wall thickening on the lower zones, and hazy ground glass opacities on the right upper lobe

[Downloaded free from http://www.eurasianjpulmonol.com on Friday, March 27, 2020, IP: 10.232.74.26]

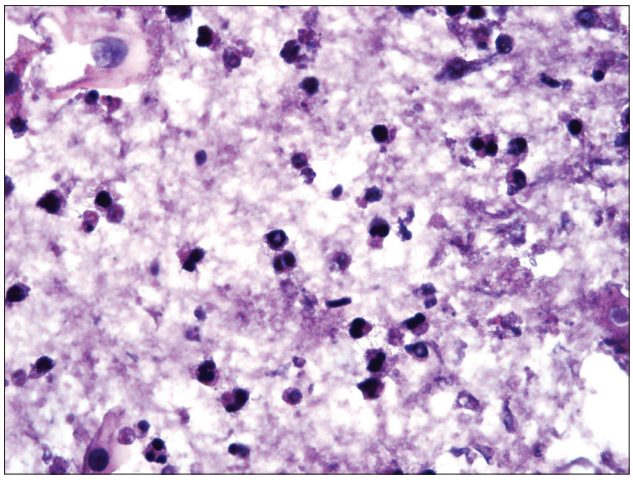

Figure 3: Microscopic examination of the bronchoalveolar lavage fluid with cell differential revealed 30% eosinophilia (H and E, x100)

nonsmokers, and there was no statistically significant difference between two groups which compatible with our AEP diagnosis.[9] However, large-scaled studies are needed to determine the pulmonary effects of waterpipe smoking as it may change BAL cell differential. We could not find any study linking, the waterpipe smoking with simple pulmonary eosinophilia. As changing of smoking habits associated with AEP; recent waterpipe smoking history, bilateral pulmonary infiltrates, 40% eosinophil count in BAL fluid supported our diagnosis. According to the American Thoracic Society guidelines, an eosinophil differential count >25% is virtually diagnostic of acute or chronic eosinophilic pneumonia.[10] We concluded that recent waterpipe smoking maybe a cause of AEP with benign clinical course. Our early diagnosis may contribute to this result or waterpipe smoking may cause pulmonary eosinophilia without any clinical syndrome.

Conclusion

When taking a smoking history of a patient, changing of smoking habits, or the initiation of new tobacco products should always be asked in addition to smoking status. Recent exposure to waterpipe smoking or change in smoking habits should be considered as a risk factor for AEP. If no clinical improvement has been observed after the treatment for the common causes of patient's complaints and risk factors mentioned above were present, AEP should be considered.

Declaration of patient consent

The authors certify that they have obtained all appropriate patient consent forms. In the form the patient(s) has/have given his/her/their consent for his/her/their images and other clinical information to be reported in the journal. The patients understand that their names and initials will not be published and due efforts will be made to conceal their identity, but anonymity cannot be guaranteed.

Financial support and sponsorship

Nil.

Conflicts of interest

There are no conflicts of interest.

References

1. Badesch DB, King TE Jr., Schwarz MI. Acute eosinophilic pneumonia: A hypersensitivity phenomenon? Am Rev Respir Dis 1989;139:249-52.
2. Slabbynck H, Coeck C, Galdermans D, Van Schaardenburg C, Coolen D. Dyspnea, fever, and eosinophilia. Chest 1993;104:585-6.
3. Philit F, Etienne-Mastroïanni B, Parrot A, Guérin C, Robert D, Cordier JF, *et al.* Idiopathic acute eosinophilic pneumonia: A study of 22 patients. Am J Respir Crit Care Med 2002;166:1235-9.
4. Uchiyama H, Suda T, Nakamura Y, Shirai M, Gemma H, Shirai T, *et al.* Alterations in smoking habits are associated with acute eosinophilic pneumonia. Chest 2008;133:1174-80.
5. Raj V, Berman A. Acute eosinophilic pneumonia after use of a hookah (Water Pipe) causing severe hypoxemia requiring ECMO. Chest 2013;144:916A.
6. Dyal H, Singhvi A, Patel R, Mendez M, Thavarajeh K, Jennings JA. Case of eosinophilic pneumonia following recent onset of hookah smoking. Chest 2014;146 Suppl 2:406.
7. Ali M, Saleh Z, Laktineh A, Huda N. Acute eosinophilic pneumonia in a hookah smoker. American Thoracic Society. Am J Respir Crit Care Med 2017;199:A5873.
8. Umeki S, Soejima R. Acute and chronic eosinophilic pneumonia: Clinical evaluation and the criteria. Intern Med 1992;31:847-56.
9. Strulovici-Barel Y, Shaykhiev R, Salit J, Deeb RS, Krause A, Kaner RJ, *et al.* Pulmonary abnormalities in young, light-use waterpipe (Hookah) smokers. Am J Respir Crit Care Med 2016;194:587-95.
10. Meyer KC, Raghu G, Baughman RP, Brown KK, Costabel U, du Bois RM, *et al.* An official American Thoracic Society clinical practice guideline: The clinical utility of bronchoalveolar lavage cellular analysis in interstitial lung disease. Am J Respir Crit Care Med 2012;185:1004-14.