Access this article online
Quick Response Code:

Website:
www.eurasianjpulmonol.com

DOI:
10.4103/ejop.ejop_7_20

Chemotherapy given lung cancer in intensive care unit

Aybüke Kekeçoğlu[1], Burcu İleri Fikri[2], Özkan Devran[1], Murat Haliloğlu[2], Ayşe Filiz Koşar[1]

ORCID:
Aybüke Kekeçoğlu: 0000-0002-5589-6786
Burcu İleri Fikri: 0000-0002-9220-5294
Özkan Devran: 0000-0002-1498-8609
Murat Haliloğlu: 0000-0001-6597-2810
Ayşe Filiz Koşar: 0000-0001-5707-2716

Abstract:

Lung cancer is the leading cause of cancer-related death among all types of cancers. In lung cancer patients, hospitalization rates in intensive care units (ICUs) are gradually increasing due to both illness- and treatment-related complications. A 61-year-old male patient who had undergone radiotherapy for small cell lung cancer (SCLC) was admitted to the ICU on the 3rd day of his treatment because of hypercapnic respiratory failure. High-flow oxygen therapy was started. The mass lesion showed rapid progression. Chemotherapy was performed for SCLC which is a chemosensitive tumor.

Keywords:

Chemotherapy, high-flow oxygen therapy, intensive care unit, small cell lung cancer

Introduction

Small cell lung cancer (SCLC) is one of the most common thoracic tumors and currently constitutes 13.6% of all lung cancers.[1] The tumor is sensitive to chemotherapy and radiotherapy (RT) and can be controlled by chemotherapy in short term. New treatment options and algorithms are used to prolong the survival of these patients. Because of prolonged life expectancy and treatments, hospitalization rates of lung cancer patients in intensive care units (ICUs) are gradually increasing due to both the disease and the complications associated with the treatment. In this article, we report the successful use of chemotherapy in a newly diagnosed SCLC patient admitted to the ICU for respiratory failure.

Case Report

A 61-year-old male patient was admitted to a thoracic surgery outpatient clinic with complaints of neck swelling, redness of the face, and respiratory distress. Thorax computed tomography (CT) detected a 7 cm × 3.5 cm irregular mass lesion displacing the superior vena cava extending to the paratracheal area posteriorly in the anterior mediastinum [Figure 1]. The patient was diagnosed with SCLC by mediastinoscopy. Due to the large airway compression and vena cava superior syndrome, the patient was decided to undergo emergency radiotherapy, positron emission tomography and cranial magnetic resonance imaging was planned. The patient was directed to an oncology outpatient clinic. The patient whose imaging could not be performed due to increased shortness of breath, was taken to the ICU after the respiratory failure was

[1]Department of Pulmonology, [2]Department of Intensive Care, Health Sciences University, Yedikule Chest and Thoracic Surgery Training and Research Hospital, Pulmonary Intensive Care Unit, Istanbul, Turkey

Address for correspondence:
Dr. Aybüke Kekeçoğlu, Health Sciences University, Yedikule Chest and Thoracic Surgery Training and Research Hospital, Pulmonary Intensive Care Unit, Istanbul, Turkey.
E-mail: aybuke-kekecoglu@hotmail.com

Received: 24-01-2020
Revised: 20-03-2020
Accepted: 02-05-2020
Published: 29-04-2021

This is an open access journal, and articles are distributed under the terms of the Creative Commons Attribution-NonCommercial-ShareAlike 4.0 License, which allows others to remix, tweak, and build upon the work non-commercially, as long as appropriate credit is given and the new creations are licensed under the identical terms.

For reprints contact: WKHLRPMedknow_reprints@wolterskluwer.com

How to cite this article: Kekeçoğlu A, Fikri BI, Devran O, Haliloğlu M, Koşar AF. Chemotherapy given lung cancer in intensive care unit. Eurasian J Pulmonol 2021;23:72-75.

© 2021 Eurasian Journal of Pulmonology Published by Wolters Kluwer - Medknow

detected from the emergency clinic that RT was applied on the 3rd day.

The patient was admitted to the ICU for further examination and treatment because of respiratory failure. On physical examination, his body temperature was 36.8°C, heart rate was 112 beats/min, respiratory rate was 42/min, and blood pressure was 135/63 mmHg. Blood count parameters were erythrocytes erythrocytes 6,77x106/uL, leukocyte count 9100/mm^3, hemoglobin value 13.9 g/dL, hematocrit value 44.7%, and platelet count 283,000/mm^3. Liver function tests were aspartate aminotransferase 14 U/L, alanine aminotransferase 40 U/L, serum total bilirubin 0.56 mg/dl, and albumin 35.6 g/L. Kidney function test results were as follows: creatinine clearance – 95 ml/min/1.73 m^2, creatinine – 0.83 mg/dl, and blood urea nitrogen – 48 mg/dl. Among other biochemical test results, C-reactive protein was 18 mg/L (high risk >3) and procalcitonin was 0.41 ng/ml. Arterial blood gas analysis (room air) results were as follows: pH – 7.31, $PaCO_2$ – 87 mmHg, PaO_2 – 41 mmHg, SpO_2 – 69.9%, and HCO_3 – 40.6 mmol/L. The patient underwent noninvasive mechanical ventilation (NIMV) support. Bilevel-positive airway pressure in spontaneous-time mode was applied with inspiratory positive airway pressure of 15 cm/ H_2O, expiratory positive airway pressure of 8 cm/H_2O, FiO_2 of %60. Fourth-hour blood gas sample values were as follows; pH – 7.39, $PaCO_2$ –68 mmHg, PaO_2 – 83.7 mmHg, SpO2– 95.9%, HCO_3– 40.6 mmol/L and PaO_2/ FiO_2 ratio – 139. Oxygenation improved with NIMV support and dyspnea and tachypnea decreased. Due to the inefficacy of mask oxygen therapy, high-flow oxygen therapy (HFOT) (heat: 31°C, flow: 50 L/min, FiO_2: %65) was applied to the patient who got desaturated after quitting NIMV.

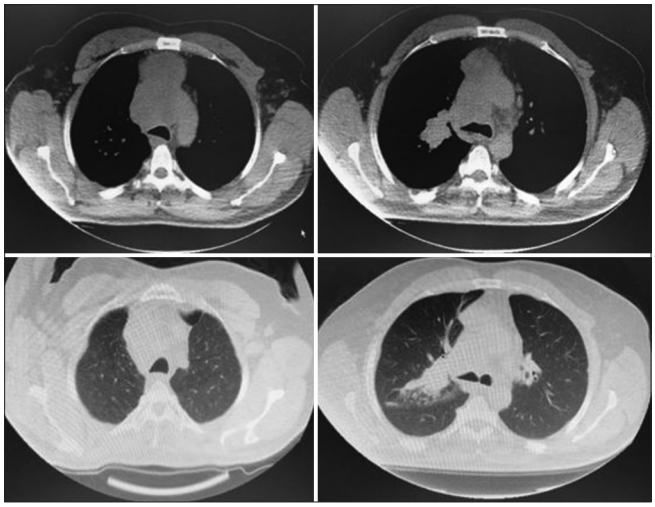

Figure 1: Thorax computed tomography detected a 7 cm × 3.5 cm irregular mass lesion displacing the superior vena cava extending to the paratracheal area posteriorly in the anterior mediastinum

Thrombosis was not detected on lower and upper extremity venous Doppler ultrasonography. There was no bacterial reproduction in sputum, blood, and urine cultures. The lesion showed rapid progression and no signs of infection; chemotherapy was decided for SCLC. Etoposide was given 100 mg/day for 3 days. After one course of chemotherapy, dyspnea decreased. Regression of the lesion was observed on chest X-ray after chemotherapy [Figure 2]. During ICU follow, the patient did not need NIMV and HFOT. The oncological treatment was planned with oxygen supplementation, and the patient was discharged from the ICU. The oncological treatment of the patient was ongoing, and outpatient control was performed in the 3rd month of discharge. SpO_2 in room air was 97%, and thorax CT showed significant regression of the lesion [Figure 3].

Discussion

Lung cancer is the leading cause of cancer death worldwide. Worldwide, 2.09 million patients were diagnosed with lung cancer in 2018, and the same year 1.76 million deaths due to lung cancer occurred.[2] It has been reported that the median lifetime for lung cancer is generally 12 months and the 5-year survival ratio is approximately 19%.[3] New treatment options and algorithms applied to patients with lung cancer that are not suitable for surgery, prolong the survival of these patients.[4,5]

Due to the prolonged life span and the treatments applied, it can be said that the increasing number of lung cancer patients has been followed up in the ICUs for disease-related or treatment-related reasons.[5] The indications for ICU hospitalization may be cancer related (e.g., critical organ involvement and pulmonary embolism), may be associated with treatment (e.g., sepsis and drug toxicity), or may be due to comorbid diseases (e.g., kidney failure, heart failure, and chronic obstructive pulmonary disease attack).[5,6] However, apart from all these factors, the most common reason for cancer patients to be followed up in the ICU is acute organ failure, usually one or more of the following:

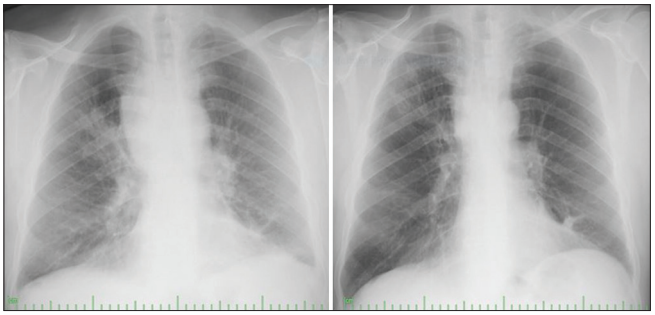

Figure 2: Regression of the lesion was observed on chest X-ray after chemotherapy

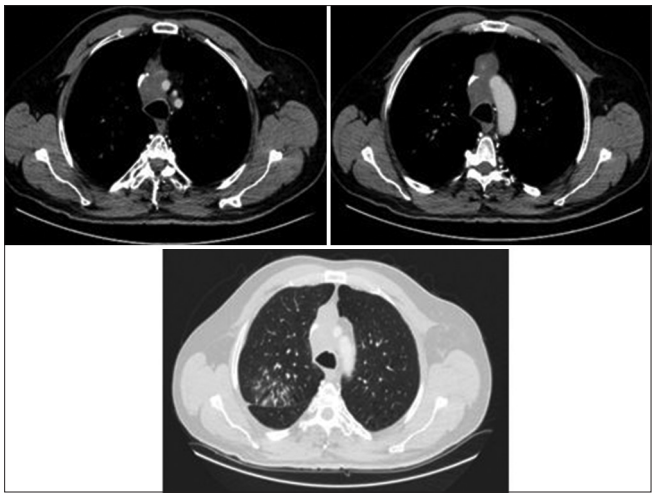

Figure 3: Thorax computed tomography showed significant regression of the lesion after 3 months of chemotherapy

- Respiratory failure requiring ventilation
- Renal failure requiring renal replacement therapy
- Septic shock with cardiovascular failure requiring vasopressor support.

Other common ICU admission reasons include pulmonary edema, electrolyte disorders, neurological disorders, acute airway obstruction, massive hemoptysis, side effect development against drugs and blood products, and the need for postoperative observation.

High-flow oxygen treatment is a new alternative treatment method used in critically ill patients with severe hypoxemic respiratory failure and slow-flow conventional oxygen supply. High flow oxygen treatement provides not only positive end-expiratory pressure, but also prevents dead space ventilation and reduces work of breathing. It is well tolerated and can be used for a long time.[7] In our case, the reason for admission to the ICU was severe hypoxic respiratory failure developing acutely and high FiO requirement. The HFOT treatment applied reduced the patient's dyspnea, improved oxygenation, and prevented intubation.

SCLC is a malignant solid tumor highly sensitive to chemotherapy and RT (with 50%–70% remission rate).[8] The first-line treatment option for SCLC is chemotherapy. Patients with a good physical condition (Zubrod-Eastern Cooperative Oncology Group-World Health Organization [ZPS] score: 0–2) can also choose standard dose etoposide–cisplatin and carboplatin–etoposide.[9,10] In patients with a ZPS score of 3–4, a decision must be made with the patient and family, taking into account the physiological functions of the patient and the advantages and disadvantages of the treatment.

Although the benefits of chemotherapy in ICU have been shown in patients with hematologic cancer, there is insufficient evidence to give ICU chemotherapy in lung cancer.[11] However, in critical situations caused by chemotherapy-sensitive tumors, chemotherapy can relieve symptoms and save time for subsequent treatments. In this case, while respiratory failure was treated with HFOT, it was decided to perform simultaneous chemotherapy in our patient whose pathological diagnosis was chemosensitive SCLC and chest radiographs showed that the lesion was rapidly progressing. Besides the respiratory failure, the patient tolerated chemotherapy because of having normal liver and kidney functions. Applied chemotherapy reduced mortality and increased survival.

Conclusion

Advances in the diagnosis and treatment of ICUs and noninvasive treatment options have a positive effect on the prognosis of malignant patients. However, there is no consensus as to which malignant patients will benefit from treatment. It may be appropriate to give ICU treatment chance, especially for those with acute respiratory failure. If the patient's age, performance status, and comorbid conditions are appropriate and there is a pathological diagnosis sensitive to chemotherapy such as SCLC, oncological treatment without invasive respiratory support such as NIMV and/or HFOT can be applied and treatment of the patient can be continued by controlling the respiratory failure due to the tumor, which is the reason for intensive care.

Consent

Written informed consent was obtained for the case report.

Declaration of patient consent

The authors certify that they have obtained all appropriate patient consent forms. In the form, the patient has given his consent for his images and other clinical information to be reported in the journal. The patient understands that his name and initials will not be published and due efforts will be made to conceal identity, but anonymity cannot be guaranteed.

Financial support and sponsorship

Nil.

Conflicts of interest

There are no conflicts of interest.

References

1. Jett JR, Schild SE, Kesler KA, Kalemkerian GP. Treatment of small cell lung cancer: Diagnosis and management of lung cancer,

3rd ed.: American College of Chest Physicians evidence-based clinical practice guidelines. Chest 2013;143:400-19.

2. World Health Organization. GLOBOCAN 2012: Estimated Cancer İncidence, Mortality and Prevalence Worldwide in 2012. Available from: http://globocan.iarc.fr/Pages/fact_sheets_ cancer.aspx. [Last accessed on 2018 Oct 10].
3. Howlader N, Noone AM, Krapcho M, Miller D, Brest A, Yu M, *et al*. SEER Cancer Statistics Review, 1975- 2016, National Cancer Institute. Bethesda, MD, https://seer.cancer.gov/csr/1975_2016/ posted to the SEER web site, April 2019.
4. Patel T, McGovern EM, Wolfe D, Lewis ME, Chowdhury M. Pharmacologic Considerations in Oncology Critical Care. Oncology Critical Care 2016;35:68.
5. 5Soubani AO, Ruckdeschel JC. The outcome of medical intensive care for lung cancer patients: The case for optimism. J Thorac Oncol 2011;6:633-8.
6. Azoulay E, Schlemmer B. Diagnostic strategy in cancer patients with acute respiratory failure. Intensive Care Med 2006;32:808-22.
7. Sztrymf B, Messika J, Bertrand F, Hurel D, Leon R, Dreyfuss D, *et al*. Beneficial effects of humidified high flow nasal oxygen in critical care patients: A prospective pilot study. Intensive Care Med 2011;37:1780-6.
8. von Pawel J, Schiller JH, Shepherd FA, Fields SZ, Kleisbauer JP, Chrysson NG, *et al*. Topotecan versus cyclophosphamide, doxorubicin, and vincristine for the treatment of recurrent small-cell lung cancer. J Clin Oncol 1999;17:658-67.
9. Buccheri G, Ferrigno D, Tamburini M. Karnofsky and ECOG performance status scoring in lung cancer: A prospective, longitudinal study of 536 patients from a single institution. Eur J Cancer 1996;32A: 1135-41.
10. Verger E, Salamero M, Conill C. Can Karnofsky performance status be transformed to the Eastern Cooperative Oncology Group scoring scale and vice versa? Eur J Cancer 1992;28A: 1328-30.
11. Moors I, Pène F, Lengline É, Benoit D. Urgent chemotherapy in hematological patients in the ICU. Curr Opin Crit Care 2015;21:559-68.