Patient with Mal de Meleda in whom a Novel Gene Mutation was Identified

Gulhan Gurel[1], Oguz Cilingir[2], Ozden Kutluay[2], Serap Arslan[2], Sevinc Sahin[3], Emine Colgecen[1]

Cite this article as: *Gurel G, Cilingir O, Kutluay O, Arslan S, Sahin S, Colgecen E. Patient with Mal de Meleda in whom a Novel Gene Mutation was Identified. Eurasian J Med 2019; 51(2): 206-8.*

ORCID IDs of the authors:
G.G.: 0000-0001-5716-8750
O.C.: 0000-0002-5593-4164
O.K.: 0000-0001-5509-6650
S.A.: 0000-0002-7112-5658
S.S.: 0000-0002-9409-8138
E.C.: 0000-0001-9651-6068

This article was presented as a poster on the V. DOD Dermatology Agenda. Kuşadası, Turkey. 28 September - 1 October, 2017.

[1]Department of Dermatology, Bozok University School of Medicine, Yozgat, Turkey
[2]Department of Medical Genetics, Osmangazi University School of Medicine, Eskişehir, Turkey
[3]Department of Pathology, Bozok University School of Medicine, Yozgat, Turkey

Received: June 1, 2018
Accepted: September 15, 2018
Available Online Date: November 30, 2018

Correspondence to: Gulhan Gurel
E-mail: gulhanozturkgurel@hotmail.com

DOI 10.5152/eurasianjmed.2018.18215

Content of this journal is licensed under a Creative Commons Attribution 4.0 International License.

ABSTRACT

Mal de Meleda, also known as keratoderma palmoplantaris transgrediens, is a rare type of autosomal recessive palmoplantar keratoderma. A 19-year-old male presented with a congenital yellowish discoloration and thickening of both palms and soles of the feet. His family history revealed that there was no consanguinity between the mother and the father and that the patient had three healthy brothers. The second- and third-degree relatives, five females and one male, also exhibited similar skin findings. From the isolated DNA samples, the extrinsic regions of the SLURP1 gene were screened using the sequence analysis and the Sanger sequencing was performed with the 3130 Sequence Analyzer. Results of this analysis show that a p.Arg 96 Pro (R96P) (c.287 CGA>CCA) homozygous missense point mutation was detected on the SLURP 1 (a secreted toxin-like mammalian lymphocyte antigen 6/urokinase-type plasminogen activator receptor-related protein 1) gene of the patients, while heterozygous p.Arg 96 Pro (R96P) (c.287 CGA>CCA) mutation was detected in the mother, father, and brothers. Our search of the Human Genome Mutation Database and previous literature revealed no reports of this mutation in mal de Meleda. We report this case due to the identification of a novel gene mutation in a patient with mal de Meleda, a palmoplantar keratoderma.

Keywords: Mal de Meleda, palmoplantar keratoderma, SLURP1

Introduction

Mal de Meleda, also known as keratoderma palmoplantaris transgrediens, is a rare type of autosomal recessive palmoplantar keratoderma [1]. It was first described in 1826 in a patient from Mljet, formerly known as the Meleda Island in the Adriatic Sea. The prevalence of this extremely rare disease is 1/1,000,000 [2, 3]. Since its discovery in 1826, the disease has been reported in at least 19 countries in addition to Croatia. These include Algeria, Chile, China, Germany, India, Indonesia, Italy, Japan, Korea, Laos, Libya, The Netherlands, Pakistan, Saudi Arabia, Scotland, Sweden, Tunisia, Turkey, and the United Arab Emirates [2].

We report a case of a 19-year-old male diagnosed with mal de Meleda, in whom a novel gene mutation was identified.

Case Presentation

A 19-year-old male presented with a congenital yellowish discoloration and thickening of both palms and soles of the feet. His only other symptoms were hyperhidrosis and foul odor in the hands and feet. His previous medical history was unremarkable. His family history revealed that there was no consanguinity between the mother and the father and that the patient had three healthy brothers. The second- and third-degree relatives, five females and one male, also exhibited similar skin findings. Patient's family tree is shown in Figure 1. No pathology was observed on the systemic examination. A dermatological examination revealed bilateral palmoplantar pointed pits, maceration, and foul odor between the toes on slightly erythematous yellowish hyperkeratotic areas extending to the dorsal aspect of the hands and feet (Figure 2). An examination of the hair, teeth, and mucosa was unremarkable. Subungual hyperkeratosis and dystrophic changes were found in the nails. The hands and toes were free of contractures, and there was no motion limitation observed. Routine laboratory analyses were within the normal limits. Hyphae and spores were observed upon a direct KOH analysis of samples prepared from palms

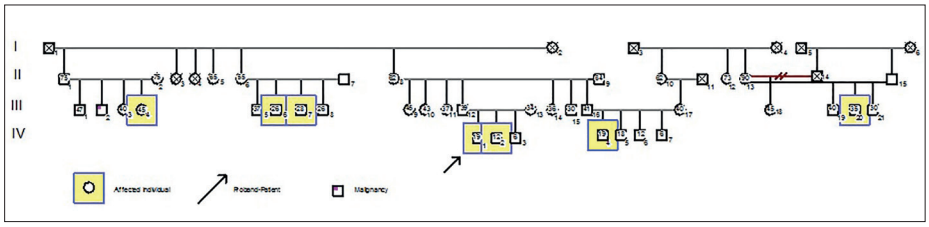

Figure 1. Pedigree.

Figure 2. Bilateral palmoplantar pointed pits on slightly erythematous yellowish hyperkeratotic areas, extending to the dorsal aspect of the hands and feet.

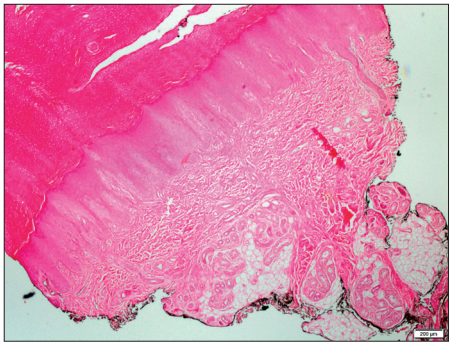

Figure 3. Light microscopic image of the lesion showing hyperkeratosis on the surface, thickening of the granular layer, and marked psoriasiform hyperplasia (hematoxylin–eosin staining, x40).

and soles of the feet and from the nails. An informed consent form was obtained from the patient. A punch biopsy was obtained from the hyperkeratotic lesion. Light microscopy revealed hyperkeratosis on the surface. Thickening of the granular layer and marked psoriasiform hyperplasia of the epidermis were observed. A mild perivascular mononuclear inflammatory cellular infiltration was observed in the superficial dermis (Figure 3).

Mal de Meleda was diagnosed based on the clinical and histopathological findings. Moisturizers and topical antifungal medications were prescribed for the hyperkeratotic lesions.

We collected blood samples from 4 individuals, including our patient, and performed genomic DNA isolation. Three pairs of primers were used for the SLURP1 gene. These primers included 1F: 5'GAACAGTGAGTTCCCCAGTG 3', 1R: 5'CACTGAGAATGAGGAGGGTG 3', 2F: 5'GATGTCAGCGAGACTCCTTC 3', 2R: 5'CAGGACTGGGTCTCTGAG 3', 3F: 5'GAACAGGGATCACAGGGAG 3', and 3R: 5'GTCATGTCCACTCTTGGCTT 3', respectively. From the isolated DNA samples, the extrinsic regions of the SLURP1 gene were screened using the sequence analysis, and Sanger sequencing was performed with the 3130 Sequence Analyzer.

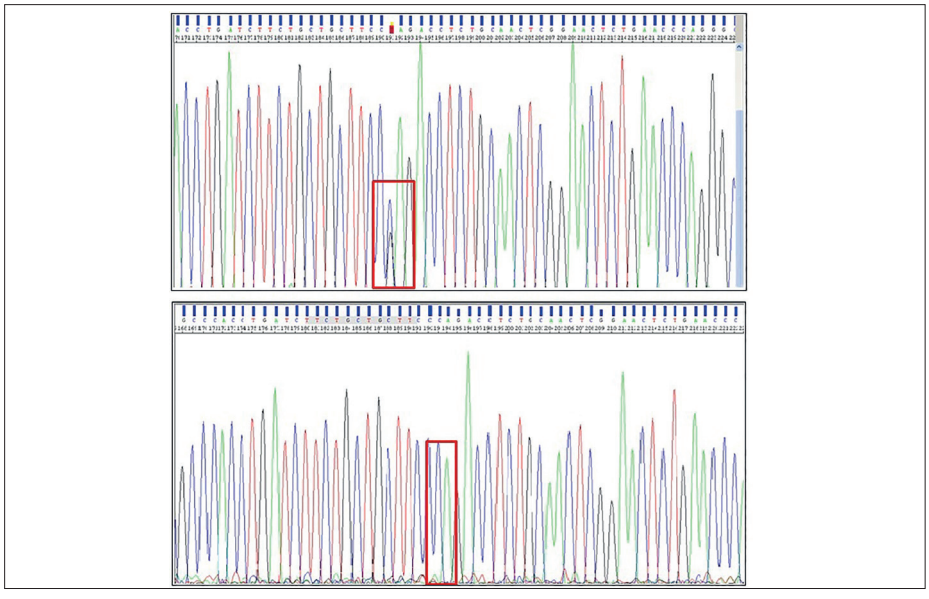

Figure 4. Sanger sequence heterozygosity image (mother, father, and brothers; above) and Sanger sequence homozygosity image of the patient (below).

The results of this analysis show that a p.Arg 96 Pro (R96P) (c.287 CGA>CCA) homozygous missense point mutation was detected on the SLURP1 gene of the patients, while a heterozygous p.Arg 96 Pro (R96P) (c.287 CGA>CCA) mutation was detected in the mother, father, and brothers (Figure 4). Our search of the Human Genome Mutation Database and previous literature revealed no previous report of this mutation in mal de Meleda.

Discussion

Mal de Meleda, a hereditary palmoplantar keratoderma, is characterized by symmetrical palmoplantar keratoderma and hyperkeratosis covering the dorsal surface of the hands and feet in a glove/sock form, occurring at birth or within a few years after birth [3]. In addition to these findings, patients have also presented with hyperhidrosis in the palms and soles of the feet; pointed pits in palmoplantar keratoderma areas; perioral erythema; brachydactyly; nail disorders; progressive, conical, thinning; contracture and pseudoarthritic developments on the fingertips; and cleft palate [3-5]. Our patient presented with hyperhidrosis in palms and soles of the feet, pointed pits in palmoplantar keratoderma areas, and subungual hyperkeratosis.

Autosomal recessive palmoplantar keratodermas should be considered during differential diagnosis of mal de Meleda. Among these, the Papillon–Lefèvre syndrome is characterized by periodontitis and premature teeth loss [6]. Our patient's teeth were normal in appearance. Hyperkeratosis, which was observed on the dorsal surfaces of our patient's hands and feet and mild erythema also helped to differentiate it from the autosomal dominant Thost–Unna keratoderma [3]. The absence of mental retardation and corneal dystrophy distinguished it from the Richner–Hanhart syndrome, while the absence of periorificial verrucous papules and hyperkeratosis distinguished it from the Olmsted syndrome. A honeycomb pattern and star-like hyperkeratosis, deafness, spontaneous amputations, and the absence of ichthyosis distinguished it from the autosomal dominant Vohwinkel syndrome; the absence of concomitant esophageal malignancy and oral mucosal lesions distinguished it from the Howel–Evans syndrome; while the absence of woolly hair and cardiac anomalies helped to distinguish it from Mal de Naxos [2, 5-8].

In 2001, the pathogenesis of mal de Meleda was reported to be due to the ARS (component B)

gene mutation encoding SLURP1 in the chromosome 8q24.3 region [9]. In addition to its role as a neuromodulator regulating epidermal homeostasis, the SLURP1 protein is also known to inhibit the secretion of tumor necrosis factor alpha from macrophages during wound healing. These roles also explain the hyperproliferative and inflammatory processes reflected in the clinical manifestation of mal de Meleda [1]. Examination of the DNA material obtained from patient's blood sample revealed a p.Arg 96 Pro (c.287 CGA>CCA) homozygous missense mutation in the SLURP1 gene. No case of mal de Meleda with this mutation was encountered in our scan of the previous literature.

Mal de Meleda, with its chronic course, is difficult to treat. Topical keratolytic agents are usually used [7]. A treatment with systemic retinoids, 5-fluorouracil infusion, and bath PUVA has also been reported to be very effective [10, 11]. However, the symptoms may resurface when treatment is discontinued. Treatment should be supplemented with antibacterial and antifungal medication due to an increased risk of bacterial and fungal infections in these patients [1]. Topical antifungal therapy was administered in our case because hyphae and spores were observed upon a direct KOH analysis prepared from the palms and soles of the feet, and also from the nails.

We report this case due to the identification of a novel gene mutation in a patient with mal de Meleda, a palmoplantar keratoderma.

Informed Consent: Informed consent was informed from the patient who participated in this study.

Peer-review: Externally peer-reviewed.

Author Contributions: Concept – ., G.G., C.O., K.O; Design - G.G., A.S, S.S.; Supervision - G.G., C.O., S.S.; Resources - C.O., K.O., A.S., S.S. ; Materials - G.G., A.S., K.O.; Data Collection and/or Processing – G.G., A.S., S.S.; Analysis and/or Interpretation - G.G., C.O., K.O.; Literature Search - A.S., S.S., C.E.; Writing Manuscript - G.G, C.O., S.S.; Critical Review - C.E.

Conflict of Interest: The authors have no conflict of interest to declare.

Financial Disclosure: The authors declare that this study has received no financial support.

References

1. Oh YJ, Lee HE, Ko JY, Ro YS, Yu HJ. A Sporadic Case of Mal de Meleda Caused by Gene Mutation in SLURP-1 in Korea. Ann Dermatol 2011; 23: 396-9. [CrossRef]
2. Perez C, Khachemoune A. Mal de Meleda: A Focused Review. Am J Clin Dermatol 2016; 17: 63-70. [CrossRef]
3. Bouadjar B, Benmazouzia S, Prud'homme JF, Cure S, Fischer J. Clinical and genetic studies of 3 large, consanguineous, Algerian families with Mal de Meleda. Arch Dermatol 2000; 136: 1247-52. [CrossRef]
4. Nath AK, Chaudhuri S, Thappa DM. Mal de meleda with lip involvement: a report of two cases. Indian J Dermatol 2012; 57: 390-3. [CrossRef]
5. Hu G, Yildirim M, Baysal V, Yerebakan O, Yilmaz E, Inaloz HS, et al. A recurrent mutation in the ARS (component B) gene encoding SLURP-1 in Turkish families with mal de Meleda: evidence of a founder effect. J Invest Dermatol 2003; 120: 967-9. [CrossRef]
6. Patel S, Davidson LE. Papillon-Lefèvre syndrome: a report of two cases. Int J Paediatr Dent 2004; 14: 288-94. [CrossRef]
7. Braun-Falco O, Plewig G, Wolf HH, Burgdorf WHC, editors. Dermatology. 2th ed. Berlin: Springer-Verlag; 2000; 14: 288-94.
8. Sakiyama T, Kubo A. Hereditary palmoplantar keratoderma "clinical and genetic differential diagnosis". J Dermatol 2016; 43: 264-74. [CrossRef]
9. Fischer J, Bouadjar B, Heilig R, et al. Mutations in the gene encoding SLURP-1 in Mal de Meleda. Hum Mol Genet 2001; 10: 875-80. [CrossRef]
10. Lienemann AO, Colucci VJ, Jones MS, Trauscht JM. Treatment of palmoplantar keratoderma with continuous infusion 5-fluorouracil. Cutis 2004; 73: 303-8.
11. Kaskel P, Leiter U, Krähn G, et al. PUVA-bath photochemotherapy for congenital palmoplantar keratoderma in an 11-year-old girl. Br J Dermatol 2000; 143: 464-5. [CrossRef]