Erciyes Med J 2022; 44(1): 12–9 • DOI: 10.14744/etd.2021.41524
ORIGINAL ARTICLE – OPEN ACCESS

This work is licensed under a Creative Commons Attribution-NonCommercial 4.0 International License.

Computed Tomography Features of Pulmonary Hydatid Cysts: Factors Related to Cyst Rupture and Clinical and Therapeutic Issues

Mehmet Tahtabaşı[1], Tuğrul Hoşbul[2]

ABSTRACT

Objective: The aim of this study was to present computed tomography (CT) findings associated with the rupture of a pulmonary hydatid cyst (HC) and to assess related factors. HC rupture is a serious and potentially life-threatening complication of hydatid disease, also known as echinococcosis.

Materials and Methods: The case records of 125 patients with a confirmed pulmonary HC and who underwent CT evaluation were included and studied retrospectively. The CT images were analyzed for radiologic findings and signs of rupture, and the cysts were classified based on a manifestation of rupture and size (giant cyst).

Results: In the group, 52% of the patients were female. It was determined that 60.8% (n=76) of the cysts were solitary, and most were located in the right lung (n=71, 54.4%), lower lobes (n=83, 66.4%), or periphery (n=92, 73.6%). There were 64 (51.2%) ruptured cysts. The most common finding in cases of contained rupture cases was the air bubble sign (n=16, 12.8%), and the water lily sign (n=13, 10.4%) was most frequent in complete rupture cases. The rates of airway compression, consolidation, pleural effusion, cysto-bronchial fistula, and lung resection were significantly higher in cases of ruptured cysts, in addition to the length of hospitalization ($p<0.05$). The prevalence of giant cysts was 12.8% (n=6), and these cases demonstrated a significantly higher incidence of a central location, airway compression, consolidation, rupture, and elevated C-reactive protein level ($p<0.05$).

Conclusion: The majority of the pulmonary HCs reviewed were solitary and located in the lower lobes and periphery. The results revealed that the morbidity and lung resection rates, as well as length of hospitalization, were higher in cases of ruptured cysts as a result of airway compression, consolidation, and bronchial fistulas. Pulmonary HC should be evaluated with CT early and treated surgically to avoid further complications.

Keywords: Computed tomography, echinococcosis, hydatid cyst, pulmonary, rupture

Cite this article as: Tahtabaşı M, Hoşbul T. Computed Tomography Features of Pulmonary Hydatid Cysts: Factors Related to Cyst Rupture and Clinical and Therapeutic Issues. Erciyes Med J 2022; 44(1): 12-9.

[1]Department of Radiology, University of Health Sciences, Mehmet Akif İnan Training and Research Hospital, Şanlıurfa, Turkey
[2]Department of Medical Microbiology, University of Health Sciences, Gülhane Faculty of Medicine, Ankara, Turkey

Submitted 06.11.2020

Accepted 29.03.2021

Available Online 16.12.2021

Correspondence
Mehmet Tahtabaşı, University of Health Sciences, Mehmet Akif İnan Training and Research Hospital, Department of Radiology, Şanlıurfa, Turkey
Phone: +90 414 318 65 90
e-mail: mehmet.tahtabasi@sbu.edu.tr

©Copyright 2022 by Erciyes University Faculty of Medicine - Available online at www.erciyesmedj.com

INTRODUCTION

Hydatid disease (HD), or echinococcosis, is an important zoonotic helminth infection. It represents a significant problem that threatens public health and causes economic losses, particularly in developing countries (1–3). HD is caused by infection with the *Echinococcus* (*E.*) tapeworm in the larval stage. *E. granulosus* is the most frequently seen species responsible for human disease. Another species, *E. multilocularis*, causes alveolar echinococcosis, and is becoming increasingly more common. Two new species, *E. vogeli* and *E. oligarthrus*, are associated with neotropical echinococcosis (3). According to World Health Organization (WHO) statistics, globally, more than 1 million people live with HD, and it results in an estimated 19,300 deaths per year. The WHO noted that HD can result life-threatening clinical syndromes and reduced quality of life are common, since it is often diagnosed at a late stage. They reported an average postoperative death rate of approximately 2.2% and recurrence in 6.5% (4). In a study funded by the European Union to investigate the prevalence of HD in rural areas of Bulgaria, Romania, and Turkey in 2014–2015, 24,693 participants from 6 provinces in different regions of Turkey (Ankara, Aksaray, Balıkesir, Bitlis, Edirne, and Şanlıurfa) underwent an ultrasonography examination. HD was detected in approximately 1 (0.6%) of every 163 people (5). HD is an important public health problem in Turkey, but it remains neglected because patients are usually asymptomatic for years and it is often not reported, though reporting is mandatory.

Since the reliability of serological methods to diagnose echinococcal infection is low, these tests have largely been replaced by radiological examination (6). The failure to detect cysts in the majority of seropositive cases significantly limits the value of studies based on serological methods. Radiological imaging is important in the diagnosis and treatment of HD infection for individuals as well as public policy.

The most common site of HD in adults is the liver (75%), followed by the lungs (15%). In the pediatric population, however, the most common location is the lungs (3). Uncomplicated pulmonary HCs are generally asymptomatic

Table 1. Computed tomography features of pulmonary hydatid cyst rupture

	Definition
Contained rupture	
Crescent or meniscus sign	A crescent of air trapped between the pericyst and endocyst due to bronchial erosion.
Inverse crescent sign	Air crescents along the posterior side of the lesion without anterior extension.
Signet ring sign	Blebs of air between the pericyst and the endocyst, indicating impending rupture.
Air bubble sign	Small intracystic air foci between the pericyst and the endocyst at the periphery of the cyst.
Complete rupture	
Water lily or camelotte sign	Detachment of the endocyst results in floating membranes within the pericyst.
Whirl or serpent sign	Wavy, collapsed membranes seen within the cyst after the expectoration of cyst fluid.
Cumbo or double arch sign	Curved membrane defined by air within the endocyst and a crescent of air between the endocyst and the pericyst.
Dry or empty cyst sign	Air-filled cyst after the complete expectoration of cyst fluid and membranes.

and detected incidentally on chest X-rays (3). In contrast, cases of complicated cysts (rupture or infection) frequently present with various nonspecific clinical features, such as chest pain, coughing, and hemoptysis (2, 3). Imaging methods can play a very important role in the diagnosis of the disease. Although typical imaging findings are well described in the literature, radiologists should also be familiar with the spectrum of atypical imaging findings that may occur secondary to complications (3). The objective of this study was to assess the computed tomography (CT) findings associated with rupture, the most important complication of HC, and the factors affecting rupture. The relationships between cyst rupture and cyst diameter, lobar distribution, and peripheral versus central location seen in a single center, the referral hospital in Sanliurfa province, were evaluated and analyzed.

MATERIALS and METHODS

Ethics committee approval was obtained for this retrospective study (HRU/20.10.02).

Patient Data

The records of 125 patients who were surgically and histopathologically diagnosed with pulmonary HC and underwent contrast-enhanced thoracic CT examination at a single center between January 2015 and April 2020 were analyzed retrospectively. Patient characteristics, including age, gender, clinical symptoms, laboratory findings, operations performed, and hospitalization time were obtained from electronic medical records.

Computed Tomography Protocol and Image Assessment

All of the CT images were obtained from picture archiving and communication system. The images were evaluated independently by 2 radiologists with 8 (M.T.) and 9 years (E.K.) of experience in chest imaging. The numerical data were derived using the mean of 2 measurements of a parameter. Any significant disagreement between the radiologists was analyzed and re-evaluated in the presence of a third radiologist (N.K.) who has 10 years of experience in chest imaging.

All of the chest CT examinations were performed using a CT scanner with 16-slice, multidetector capability (Aquilion; Toshiba Medical Systems Corp., Otawara, Tochigi, Japan; or Somatom Definition; Siemens Healthineers GmbH, Erlangen, Germany). CT images were obtained with the patient in the supine position at full inspiration and the zone scanned extended from the bilateral apex to the base. Intravenous contrast medium enhancement via the administration of 1 mg/kg of iohexol was performed in all cases. In addition to axial images with a thickness of 1–5 mm, coronal and sagittal reformat images were also examined. The following features were evaluated: cyst count, longest cyst diameter, location (peripheral vs. central), cystobronchial fistula, airway compression, parenchymal consolidation/atelectasis, calcification, and the presence of daughter vesicles. In addition, extrapulmonary involvement was examined using abdominal CT and/or ultrasound images. The cysts were divided into 2 groups: ruptured or intact, as shown in Table 1 (3). Airway compression was defined as external compression of the cyst on the bronchus and a decrease in the diameter of the bronchi. Cysts with a diameter >10 cm were defined as giant cysts (7). Only patients with >1 lung cyst and a surgically confirmed diagnosis were included in the study.

Statistical Analysis

IBM SPSS Statistics for Windows, Version 22.0 software (IBM Corp., Armonk, NY, USA) was used to perform the statistical analysis. Categorical variables were expressed as numbers and percentages and compared using a chi-squared test. Continuous variables were expressed as the median (minimum–maximum) and mean±SD. Continuous variables that demonstrated a normal distribution were compared using Student's t-test, whereas the Mann-Whitney U test was used for non-normally distributed samples. The kappa coefficient was used to determine the consensus of the 2 radiologists. The accepted statistical significance level was $p<0.05$.

RESULTS

The demographic and clinical characteristics of patients with a ruptured or an intact pulmonary HC are summarized in Table 2. Of the 125 patients included in the study, 65 were female (52%) and 60 were male (48%); the mean age was 24.7±17.5 years (median: 17 years, min–max: 5–75 years). In the study group, 74.4% of the patients were <30 years of age. The mean diameter of the cysts was 6.55±3.24 cm (median: 7 cm, min–max: 2.5–27.2 cm). Most

Table 2. Comparison of ruptured and non–ruptured cysts

	Ruptured cyst n=64	Intact cyst n=61	All patients n=125	p
Age (years)	15.5 (5–75)	20 (5–70)	17 (5–75)	0.917
<30 years, n (%)	51 (79.7)	42 (68.9)	93 (74.4)	0.219
Male gender, n (%)	38 (59.4)	22 (36.1)	60 (48)	0.009*
Cyst diameter (cm)	7.8 (3.6–12.6)	6.4 (2.6–27.0)	7 (2.6–27.0)	0.08
Location, n (%)				
Right upper lobe	7 (10.9)	8 (13.1)	18 (12)	
Right middle lobe	6 (9.4)	5 (8.2)	11 (8.8)	
Right lower lobe	20 (31.3)	22 (36.1)	42 (33.6)	0.832
Left upper lobe	5 (7.8)	7 (11.5)	12 (9.6)	
Lingula	3 (4.7)	1 (1.6)	4 (3.2)	
Left lower lobe	23 (35.9)	18 (29.5)	41 (32.8)	
Number of cysts, n (%)				
1	39 (60.9)	37 (60.7)	76 (60.8)	
2	18 (28.1)	12 (19.7)	30 (24)	0.287
≥3	7 (10.9)	12 (19.7)	19 (15.2)	
CT findings, n (%)				
Peripheral location	40 (62.5)	52 (85.2)	92 (73.6)	0.01*
Airway compression	22 (34.4)	9 (14.8)	31 (24.8)	0.011*
Lung consolidation	34 (53.1)	7 (11.5)	41 (32.8)	<0.001*
Pleural effusion	20 (31.3)	1 (1.6)	21 (16.8)	<0.001*
Pleural thickening	15 (23.4)	11 (18)	26 (20.8)	0.457
Fistula	18 (28.2)	0 (0)	18 (14.4)	<0.001*
Extrapulmonary involvement	25 (39.1)	19 (31.1)	44 (35.2)	0.354
Clinical data and symptoms				
Rural residence	59 (92.2)	56 (91.8)	115 (92)	0.937
Cough	53 (82.8)	33 (54.1)	86 (68.8)	0.001*
Chest pain	49 (76.6)	36 (59)	85 (68)	0.036*
Hemoptysis	27 (42.2)	9 (14.8)	36 (28.8)	0.001*
Dyspnea	26 (40.6)	7 (11.5)	33 (26.4)	<0.001*
Fever	23 (35.9)	1 (1.6)	24 (19.2)	<0.001*
Expectoration	16 (25)	0 (0)	16 (12.8)	<0.001*
Laboratory data				
C-reactive protein (g/dL)	4.4 (0.06–222.1)	1.8 (0.07–94.5)	2.2 (0.06–222.1)	0.08
White blood cell count (10^3xmm)	10.8 (5.7–21.7)	9.6 (5.1–20.1)	10.4 (5.7–21.7)	0.09
Eosinophil count (10^3xmm)	0.33 (0.01–5.1)	0.16 (0.001–2.6)	0.18 (0.001–5.1)	0.002*
Eosinophilia, n (%)	24 (37.5)	8 (13.1)	32 (25.6)	0.002*
Type of operation				
Cystectomy/cystotomy (Cx)	44 (68.8)	57 (93.4)	101 (80.8)	0.003*
Lung resection	7 (10.9)	3 (4.9)	10 (8)	
Cx+fistula repair	8 (12.5)	0 (0)	8 (6.4)	
Resection+fistula repair	6 (9.4)	0 (0)	6 (4.8)	
Hospitalization (days)	7 (3–20)	4 (2–12)	6 (2–20)	<0.001*

All numerical variables were expressed as median (minimum–maximum) and compared using the Mann-Whitney U test; *: p<0.005; CT: Computed tomography

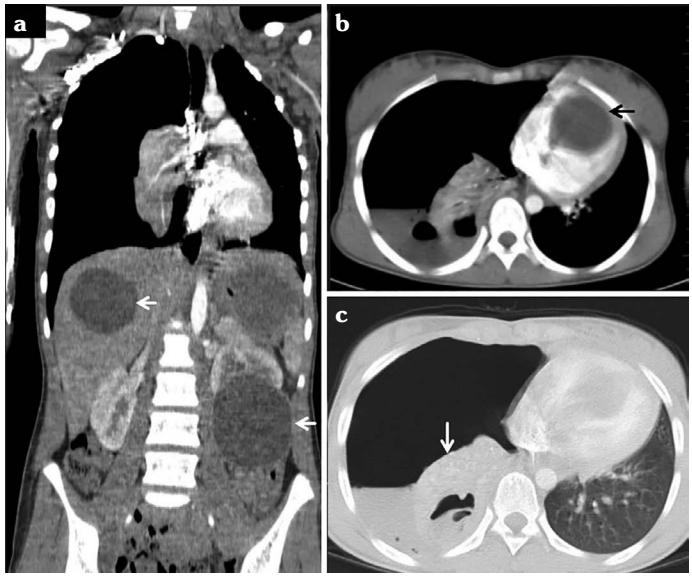

Figure 1. A patient with direct rupture of hydatid cyst into the pleural cavity. Computed tomography images in the mediastinal window. (a) Coronal image shows hydatid cysts in the liver and left kidney (white arrows). (b) Axial images illustrate a cyst in the heart (black arrow) and (c) a parenchyma window image reveals a totally collapsed lung (white arrow) and hydropneumothorax (air-fluid level) after rupture

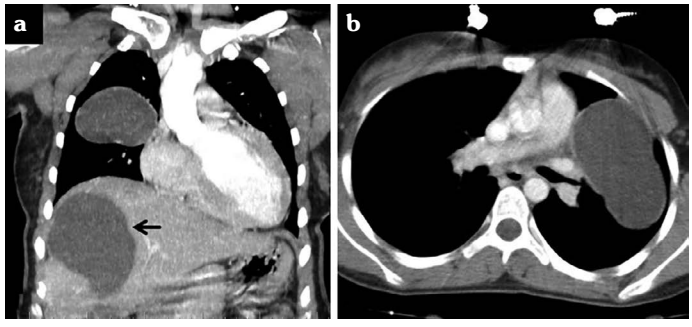

Figure 2. Computed tomography mages of 2 patients with intact hydatid cyst. (a) Coronal thoracoabdominal images of a 29-year-old woman show non-ruptured cysts in the right lung and liver (arrow). (b) A cystic lesion with well-circumscribed fluid attenuation, homogeneous content, and smooth, hyperdense walls in the left lung of axial chest CT images of a 37-year-old woman

of the cysts were located in the right lung (n=71, 54.4%). The most common localization of the cysts was the right lower lobe (n=42, 33.6%), followed closely by the left lower lobe (n=41, 32.8%). Peripherally localized cysts (n=92, 73.6%) outnumbered central cysts (n=17, 13.6%). There were 16 (12.8%) cysts that covered both the periphery and the central lung. In this study, 64.8% of patients had lung involvement, and 35.2% (n=44) had cysts in an extrapulmonary localization (Fig. 1, 2) (Table 3).

Airway compression was detected in 31 (24.8%) patients, parenchymal consolidation in 41 (32.8%), pleural effusion in 21 (16.8%), pleural thickening in 26 (20.8%), cysto-bronchial fistula in 18 (28.2%), and hydro-pneumothorax was detected in 1 (0.8%) patient, as a result of rupture into the pleural cavity (Fig. 1) (Table 2).

Table 3. Distribution of extrapulmonary involvement

	n	%
Extrapulmonary involvement	44	35.2
Liver only	31	24.8
Liver and spleen	6	4.8
Liver and kidney	3	2.4
Diaphragm	2	1.6
Heart, liver, and kidney	1	0.8
Brain	1	0.8

Table 4. Patient distribution according to CT signs of pulmonary hydatid cyst

	n	%
Contained cyst rupture signs		
Air bubble sign	16	12.8
Signet ring sign	15	12
Crescent sign	11	8.8
Inverse crescent sign	6	4.8
Complete cyst rupture signs		
Water lily sign	13	10.4
Whirl sign	12	9.6
Cumbo sign	10	8.0
Dry cyst sign	8	6.4
Pleural rupture		
Hydrothorax	6	4.8
Hydropneumothorax	1	0.8
Other		
Calcification	2	1.6
Daughter vesicles	7	5.6

CT: Computed tomography

The prevalence of contained and complete rupture findings in this study group is shown in Table 4. There were 64 (51.2%) ruptured cysts and 61 (48.8%) intact cysts. The most common findings were the air bubble sign (n=16, 12.8%) and the signet ring sign (n=15, 12%) in contained ruptures (Fig. 3, 4), and the water lily sign (n=13, 10.4%) and the whirl or serpent sign (n=12, 9.6%) in complete ruptures (Fig. 5, 6). Seven (5.6%) cysts were found to have ruptured directly into the pleural cavity. The incidence of ruptured cysts in men was significantly higher than that of intact cysts (59.4% vs. 36.1%; p=0.009). Intact cysts in the periphery were significantly more common than ruptured cysts (85.5% vs. 62.5%; p=0.01). The rate of airway compression, lung consolidation, pleural effusion, and cysto-bronchial fistula was significantly higher in cases of ruptured cysts (p=0.011, p<0.001, p<0.001, and p<0.001, respectively). Symptoms of cough, chest pain, hemoptysis, dyspnea, fever, and expectoration were significantly more frequent in the ruptured cyst group at the time of admission (p=0.001, p=0.036, p=0.001, p<0.001, p<0.001, and p<0.001, respectively). None of the patients experienced an aller-

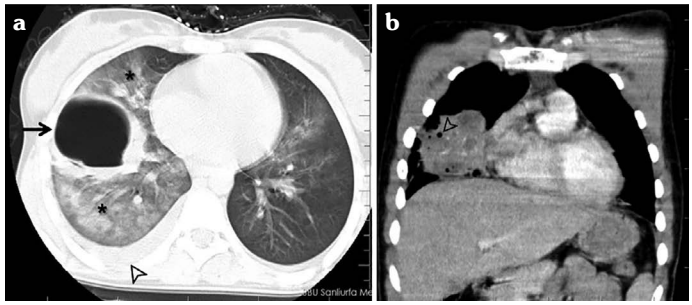

Figure 3. Images of 2 patients with dry cyst and air bubble signs. (a) Axial computed tomography (CT) image of a 16-year-old female patient illustrating the air-filled cyst (arrow), lung parenchyma infiltration (asterisks) and pleural effusion (arrowhead) in the right lung after complete expectoration of the cyst fluid and membranes. (b) Coronal CT image of a 24-year-old woman with an infected hydatid cyst shows small air foci (arrowhead) located at the periphery of the cyst. Daughter vesicles and calcification were also visible

gic reaction or anaphylactic shock following cyst rupture. The rate of eosinophilia was significantly higher in patients with a ruptured cyst (37.5% vs. 13.1%; p=0.002). All of the study cases were surgically treated with posterolateral thoracotomy. The specific type of operation is shown in Table 2 and Table 5. The parenchymal resection rate was significantly higher in the cases of a ruptured cyst (20.3% vs. 4.9%; p=0.003). The median length of hospitalization in patients with a ruptured cyst was 7 days, while it was 4 days in those without a rupture (p<0.001) (Table 2).

The prevalence of a giant lung HC >10 cm in size was 12.8% (n=16). There was no significant difference in age, sex, location, extrapulmonary involvement, type of operation, or length of hospital stay between those with giant or non-giant cysts (all p>0.05). The features of central location, airway compression, consolidation, rupture, solitary cyst, and an elevated C-reactive protein level were significantly more common in those with a giant cyst (p=0.001, p<0.001, p=0.032, p=0.002, p=0.014, and p=0.013, respectively) (Table 5). All of the patients were given 10 mg/kg albendazole daily in the postoperative 3–6–month period. There was no operation-related mortality in either group.

There was strong agreement on the CT evaluations between the 2 radiologists, with a kappa value of 0.80 (0.71–0.81).

DISCUSSION

The objective of this study was to determine specific CT findings associated with rupture of a pulmonary HC. Rupture is the most common, and potentially very serious, complication; the postoperative morbidity and mortality rate is higher in these patients. While the radiological findings of uncomplicated pulmonary HCs have been well defined in the literature, imaging findings related to complications secondary to cyst rupture are less well defined. Previous studies have identified 3 types of cyst rupture: contained, complete, and direct rupture (3, 8, 9). The data of the prevalence of rupture findings have generally been based on chest radiograph findings; however, studies investigating the specifics of contained and complete rupture findings are limited. One

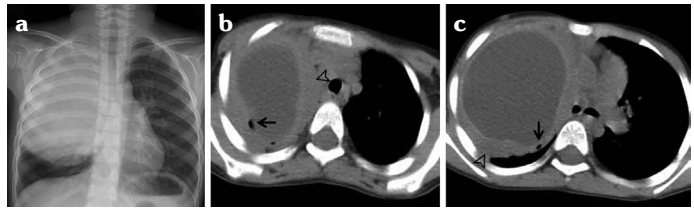

Figure 4. Images of a 5-year-old patient with a giant cyst and a contained rupture in the right lung. (a) Chest radiography showing a well-defined round radio-opacity in the right lung. (b, c) Axial computed tomography images show air blebs (arrows) between the pericyst and the endocyst, indicating rupture (signet ring sign) and parenchymal consolidation (arrowheads) around the cyst

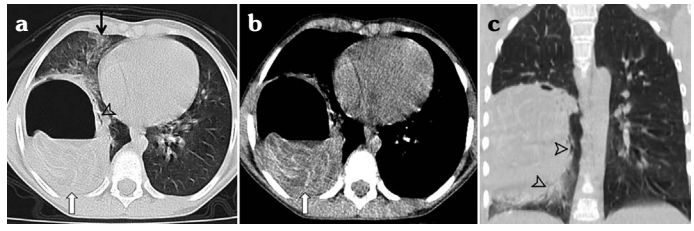

Figure 5. Water lily sign. (a, b) Axial and (c) coronal multiplanar reconstruction computed tomography images of a 25-year-old male patient with a hydatid cyst rupture show crumpled endocyst as floating membrane in the cyst fluid (white arrows). Lung consolidation (black arrow) and airway compression (arrowheads) can also be seen

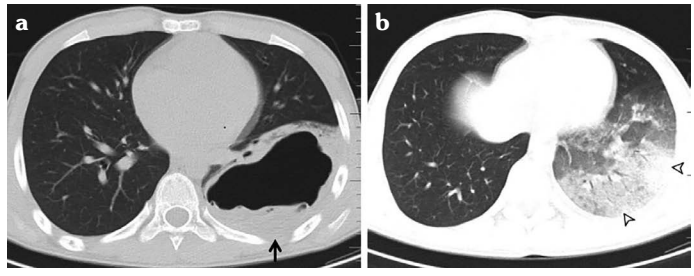

Figure 6. Whirl sign. Chest computed tomography images of a 15-year-old male patient with a ruptured hydatid cyst show (a) collapsed membranes (arrow) without fluid within the cyst in the lower left lobe and (b) inferior consolidation (arrowheads)

study of CT findings of rupture in pediatric patients found that the most common finding was the water lily sign (24.6%), followed by the air crescent sign (15.9%) and the whirl sign (15.9%) (8). Burgos et al. (10) reported that among 240 patients, 70 (29%) showed signs of cyst rupture and that in 28.6% the lesion was an empty cavity and pleural effusion was present in 11.4%. CT images with high sensitivity and specificity were used in this study to classify cyst ruptures as contained or complete and the findings were evaluated in detail. The most common CT finding in contained rupture cases was the air bubble sign (12.8%), while it was the water lily sign in cases of complete rupture (10.4%). Additional studies evaluating and comparing the radiological findings of contained and complete HC rupture will provide valuable supplementary information for radiologists.

Table 5. Features of giant and non–giant cysts

	Giant cyst (>10 cm) n=16	Non-giant cyst n=109	p
Age (years)	15 (5–75)	17 (5–70)	0.579
<30 years, n (%)	12 (75)	81 (74.3)	0.953
Male gender, n (%)	10 (62.5)	50 (45.9)	0.214
Cyst diameter (cm)	11.5 (10.2–27.0)	5.7 (2.6–9.4)	<0.001
Location, n (%)			
Right upper lobe	2 (12.5)	13 (11.9)	
Right middle lobe	0	11 (10.1)	
Right lower lobe	7 (43.8)	35 (32.1)	0.467
Left upper lobe	0	12 (11.0)	
Lingula	1 (6.3)	3 (2.8)	
Left lower lobe	6 (37.5)	35 (32.1)	
Number of cysts, n (%)			
1	15 (93.8)	61 (56)	
2	1 (6.3)	29 (26.6)	0.014
≥3	0 (0)	19 (17.4)	
CT findings, n (%)			
Extrapulmonary involvement	3 (18.8)	41 (37.6)	0.140
Central location	10 (62.5)	23 (21.1)	0.001
Lung consolidation	9 (56.3)	32 (29.4)	0.032
Airway compression	13 (81.3)	18 (16.5)	<0.001
Rupture rate	14 (87.5)	50 (45.9)	0.002
Laboratory data			
C-reactive protein (g/dL)	11.9 (0.06–184.7)	1.8 (0.07–222.1)	0.08
White blood cell count (10^3xmm)	10.8 (9.1–17.2)	9.9 (5.4–21.7)	0.09
Eosinophil count (10^3xmm)	0.15 (0.01–0.66)	0.22 (0.001–5.1)	0.002*
Eosinophilia, n (%)	4 (25)	28 (25.7)	0.002*
Type of operation			
Cystectomy/cystotomy (Cx)	11 (68.8)	90 (82.6)	0.292
Lung resection	1 (6.3)	9 (8.3)	
Cx+fistula repair	2 (12.5)	6 (5.5)	
Resection+fistula repair	2 (12.5)	4 (3.7)	
Hospitalization (days)	6 (3–18)	5.5 (2–20)	0.131

All numerical variables were expressed as median (minimum–maximum) and compared using the Mann–Whitney U test; *: p< 0.005; CT: Computed tomography

A cyst rupture can occur in the bronchus (manifesting with cough and phlegm containing hydatid fluid and membrane fragments) or in the pleural cavity (manifesting with pneumothorax, effusion, and empyema), and can lead to fatal conditions, such as anaphylactic shock. Although the rate of rupture has been reported to be 33% to 47.5% in pediatric series, a range of 41% to 61% has been noted in studies of both children and adults (8, 9, 11–13). Similarly, the rate of rupture prevalence in the mixed population of our study was 51.2%.

The reported rate of rupture in the pleural cavity ranges from 3.4% to 8.9% in many studies, and our finding of 5.6% was consistent (8, 11, 14). In the literature, pleural complications have been reported at a rate of 0.5% to 8.2%, pneumothorax at a rate of 2.4% to 6.2%, and effusion/empyema at a rate of 6.0% to 7.6% (9, 15). However, Aribas et al. (15) observed a rate of pleural complications as high as 27.9%. In our series, although the rate of pneumothorax (0.8%) was low, the rate of pleural effusion/empyema (16.8%) and pleural thickening (20.8%) was higher than that of some studies. Complications are thought to occur as a result of a reactive inflammatory response, pleural irritation, and pleural necrosis due to the pressure effect of peripheral and subpleural cysts. Moreover, parenchymal infiltration caused by the compression effect on the airways is thought to contribute to the formation of parapneumonic effusion.

The results of this study indicated that 60.8% of the cysts were solitary and, as in other studies, the HCs were most frequently localized in the lower lobes of the lung (66.4%). In our group, 33.6% were localized in the right lower lobe and 32.8% in the lower left lobe.

Onal et al. (11), Akgul et al. (8), and Aribas et al. (15), respectively, reported that 54.6%, 57.6%, and 68% of the cysts were localized in the lower lobes and most often in the right lobe. In addition to lobar localization, several studies have investigated peripheral versus central distribution of the cyst and the relationship to rupture. Onal et al. (11) found that 59.7% of 134 cysts and Akgul et al. (8) found that while 61.4% of 145 cysts were peripherally located, a peripheral location was not significantly associated with rupture when compared with a central location. However, Lewall et al. (16) suggested that the thinness of the pericyst layer and lung tissue in cysts with a peripheral location can lead to rupture directly into the pleural cavity. Similarly, Ozer et al. (17) noted that increased pressure in peripherally and subpleurally located cysts could contribute to pleural necrosis. They argued that these factors had an effect on perforation of the pleural cavity. In our series, 73.6% of the cysts were peripherally located, and unlike in some other studies, more intact cysts tended to be peripherally located (62.5%–85.2%; p=0.01). Centrally localized cysts are close to the bronchi, and airway compression is considered a factor for rupture. In addition, the presence of bronchial fistula (28.2%) and endobronchial rupture (45.6%) in our study revealed that invasion of the bronchial wall appeared to be associated with rupture.

A giant HC has been defined as a cyst >10 cm in size, and is more common in children and young adults than in older patients (8, 18). Consistent with the literature, in our study, 12 (75%) of the 16 giant lung HCs were observed in children and young patients under 30. Previous studies have shown a direct relationship between cyst size and symptoms, for example, bronchial irritant cyst can cause coughing and hemoptysis, and pleural irritation can cause chest pain. In our series, it was determined that most of the giant cysts were located centrally, causing atelectasis or pneumonia due to airway compression. Kuzucu et al. (18) and Akgul et al. (8) found that while giant cysts did not increase the rate of rupture in their study of 537 patients, similar to our findings, they reported that rupture was more frequent in cases of a giant cyst (27% vs. 15%; p=0.01). In our series, the rate of rupture of giant cysts was significantly greater than that of non-giant cysts (87.5% vs 45.9%; p=0.002). However, the size of ruptured and intact cysts was statistically similar (median diameter: 7.8 vs 6.4 cm, p=0.08). This may be related to assessment of incomplete and direct ruptures: The cyst empties and may become smaller and less spherical (12).

A hepatic cyst may accompany a significant portion of pulmonary HC cases. Kanat et al. (19) reported that 33% of children and 77% of adults with pulmonary HCs also had liver cysts. In several studies involving both children and adults, this ratio has been reported to be 16% to 23.1% (8, 10, 13). Some researchers have noted that failure to perform abdominal imaging can lead to asymptomatic liver cysts going undetected. The rate (hepatopulmonary concomitant: 32%) may be slightly underestimated, however, abdominal imaging (ultrasound or CT) is routinely performed in patients with pulmonary HCs in our center. The findings suggest that every patient with a pulmonary HC should have abdominal imaging. Unlike extrapulmonary cysts, calcification (0.7%–4.3%) and daughter vesicle formation are extremely rare in pulmonary HCs (3, 12, 20). Similarly, in our study, 1.6% of the cysts showed calcification and 5.6% had daughter vesicles. In the literature, this has been explained by the fact that the low carbon dioxide content within the lung parenchyma reduces serum calcium levels despite the presence of sufficient phosphorus released by tissue necrosis for calcium precipitation (20).

CONCLUSION

The data of our study indicated that the majority of pulmonary HCs were solitary and located in the lower lobes and periphery. Morbidity and lung resection rates, as well as length of hospitalization, were higher in ruptured cysts as a result of airway compression, consolidation, and bronchial fistula. Therefore, it is important that pulmonary HCs be evaluated early by CT and treated surgically to avoid any further complications. CT should be performed to identify the cystic structure of the lesion, to show special signs useful in the diagnosis of HCs, to reveal cysts located in hidden areas, to determine the lobar location of the cyst, and to evaluate complicated lesions or those involving more than 1 thoracic compartment. Radiologists should be aware of the atypical imaging features of rupture and should have the ability to evaluate the radiological findings of contained and complete ruptures. The relationship between cyst rupture and size and location warrants further investigation.

Acknowledgements: We would like to thank Nihat Kılıçarslan and Ergin Karaman for their support in CT reviews.

Ethics Committee Approval: The Harran University Clinical Research Ethics Committee granted approval for this study (date: 01.06.2020, number: HRU/20.10.02).

Informed Consent: The informed consent form was waived because the study was retrospective.

Peer-review: Externally peer-reviewed.

Author Contributions: Concept – MT; Design – MT; Supervision – MT, TH; Resource – MT, TH; Materials – MT; Data Collection and/or Processing – MT; Analysis and/or Interpretation – MT, TH; Literature Search – MT, TH; Writing – MT, TH; Critical Reviews – MT.

Conflict of Interest: The authors have no conflict of interest to declare.

Financial Disclosure: The authors declared that this study has received no financial support.

REFERENCES

1. Yazar S, Ozkan AT, Hökelek M, Polat E, Yilmaz H, Ozbilge H, et al. Cystic echinococcosis in Turkey from 2001-2005. Turkiye Parazitol Derg 2008; 32(3): 208–20.
2. Kayhan S, Akgüneş A. Histopathologically diagnosed pulmonary complicated hydatid cyst cases. Turkiye Parazitol Derg 2011; 35(4): 189–93.
3. Garg MK, Sharma M, Gulati A, Gorsi U, Aggarwal AN, Agarwal R, et al. Imaging in pulmonary hydatid cysts. World J Radiol 2016; 8(6): 581-7.
4. World Health Organization. Echinococcosis. Available from: URL: https://www.who.int/news-room/fact-sheets/detail/echinococcosis. Accessed 24 Sep, 2020.
5. Tamarozzi F, Akhan O, Cretu CM, Vutova K, Akinci D, Chipeva R, et al. Prevalence of abdominal cystic echinococcosis in rural Bulgaria, Romania, and Turkey: a cross-sectional, ultrasound-based, population study from the HERACLES project. Lancet Infect Dis 2018; 18(7): 769–78.
6. Ok ÜZ, Kilimcioğlu AA, Özkol M. Cystic echinococcosis in humans in Turkey. Mikrobiyol Bul 2020; 54(3): 510–22.
7. Arroud M, Afifi MA, El Ghazi K, Nejjari C, Bouabdallah Y. Lung hydatic cysts in children: comparison study between giant and non-giant cysts. Pediatr Surg Int 2009; 25(1): 37–40.

8. Akgul Ozmen C, Onat S. Computed Tomography (CT) findings of pulmonary hydatid cysts in children and the factors related to cyst rupture. Med Sci Monit 2017; 23: 3679–86.
9. Cevik M, Boleken ME, Kurkcuoglu IC, Eser I, Dorterler ME. Pulmonary hydatid disease is difficult recognized in children. Pediatr Surg Int 2014; 30(7): 737–41.
10. Burgos R, Varela A, Castedo E, Roda J, Montero CG, Serrano S, et al. Pulmonary hydatidosis: surgical treatment and follow-up of 240 cases. Eur J Cardiothorac Surg 1999; 16(6): 628–35.
11. Onal O, Demir OF. The relation between the location and the perforation rate of lung hydatid cysts in children. Asian J Surg 2018; 41(5): 422–6.
12. Turgut AT, Altinok T, Topçu S, Koşar U. Local complications of hydatid disease involving thoracic cavity: imaging findings. Eur J Radiol 2009; 70(1): 49–56.
13. Montazeri V, Sokouti M, Rashidi MR. Comparison of pulmonary hydatid disease between children and adults. Tanaffos 2007; 6(1): 13–8.
14. Sayir F, Cobanoglu U, Sehitogullari A. Surgical treatment of pulmonary hydatid cysts, which perforated to the pleura. Eurasian J Med 2012; 44(2): 79–83.
15. Aribas OK, Kanat F, Gormus N, Turk E. Pleural complications of hydatid disease. J Thorac Cardiovasc Surg 2002; 123(3): 492–7.
16. Lewall DB. Hydatid disease: biology, pathology, imaging and classification. Clin Radiol 1998; 53(12): 863–74.
17. Ozer Z, Cetin M, Kahraman C. Pleural involvement by hydatid cysts of the lung. Thorac Cardiovasc Surg 1985; 33(2): 103–5.
18. Kuzucu A, Ulutas H, Reha Celik M, Yekeler E. Hydatid cysts of the lung: lesion size in relation to clinical presentation and therapeutic approach. Surg Today 2014; 44(1): 131–6.
19. Kanat F, Turk E, Aribas OK. Comparison of pulmonary hydatid cysts in children and adults. ANZ J Surg 2004; 74(10): 885–9.
20. Sarkar M, Pathania R, Jhobta A, Thakur BR, Chopra R. Cystic pulmonary hydatidosis. Lung India 2016; 33(2): 179–91.