ENT Updates

CASE REPORT

ENT UPDATES 11(3):144-147
DOI: 10.5152/entupdates.2021.210240

Late-onset Pneumo-orbit and Orbital Compartment Syndrome After Blunt Maxillofacial Trauma

ABSTRACT

Orbital compartment syndrome (OCS) is an urgent condition which requires immediate treatment to avoid permanent vision loss. If the associated increased intraorbital pressure causes optical nerve and disc compression, emergency treatment to reduce the pressure is required. Here, we report the initially conservative management of a minimally displaced medial orbital fracture after blunt maxillofacial trauma and the late but sudden development of pneumo-orbit and OCS.

Keywords: Endoscopic orbital decompression, endoscopic sinus surgery, maxillofacial trauma, pneumo-orbit, orbital compartment syndrome

INTRODUCTION

Orbital compartment syndrome (OCS) can cause vision loss and therefore requires immediate treatment. The orbit is a conical cavity surrounded by bony walls except at the anterior region[1] and has an average orbital volume and intraorbital pressure of 30 mL and 3-6 mmHg, respectively.[2,4] Any condition that creates a mass effect in the eye can lead to OCS, and this most often develops due to trauma, followed by hemorrhages and hematoma after orbital surgery.[1,5] Orbital cellulite, with or without abscess formation, is an additional important factor that increases the risk of developing OCS. In addition, OCS can occur as a complication of functional endoscopic sinus surgery through damage to the orbital medial wall and periorbita, and hemorrhages and OCS can be a complication of some open maxillofacial or transorbital surgical approaches.[1,5]

CASE PRESENTATION

A 43-year-old male presented to the emergency department after a blunt trauma to the face, and the patient was consulted for maxillofacial evaluation to Otorhinolaryngology Department. Maxillofacial computed tomography (CT) was done as the patient had complained of pain at the supraorbital rim and step palpation in the nasal bone. Computed tomography revealed displaced fractures of the bilateral nasal bone and the left lamina papyracea with extraconal minimal air values. The patient's vision and eye movements were normal at this stage, and only reduction of the nasal fracture was recommended as there was no apparent need to perform other interventions. However, the patient had a history of rhinoplasty and refused fracture reduction, and he was discharged with recommendations after about 6 hours of examination and follow-up. Approximately 15 hours later, the patient returned to the emergency department with swelling, ecchymosis, and severe proptosis of the left eye.

A complete otorhinolaryngological examination was performed; blurred vision with some limitation of movement in all directions was detected in the left eye. The patient stated that the swelling had started around 3 hours earlier after he sneezed and blew his nose, and the blurring had continued to progress since then. An ophthalmological examination showed that the left eye had limited movement in all directions and a visual examination with eye drops revealed 0.2 vision in the eye examination chart and vanishing in the temporal areas of the left optical disc. Examination of the right eye was normal.

An orbital CT was performed, and this revealed a massive pneumo-orbit with significant intraconal and extraconal distances. The patient was thought to have OCS and optic nerve

Hazan Başak[1]
Levent Yücel[2]
Süha Beton[1]

[1]Department of ORL, Ankara University School of Medicine, Ankara, Turkey
[2]Department of ORL, Gülhane Research and Training Hospital, University of Health Sciences, Ankara, Turkey

Cite this article as: Başak H, Yücel L, Beton S. Late-onset pneumo-orbit and orbital compartment syndrome after blunt maxillofacial trauma. *ENT Updates.* 2021;11(3):144-147.

Corresponding author:
Hazan Başak
Email: *hbasak@ankara.edu.tr*
Received: *June 11, 2021*
Accepted: *July 30, 2021*

Content of this journal is licensed under a Creative Commons Attribution-NonCommercial 4.0 International License.

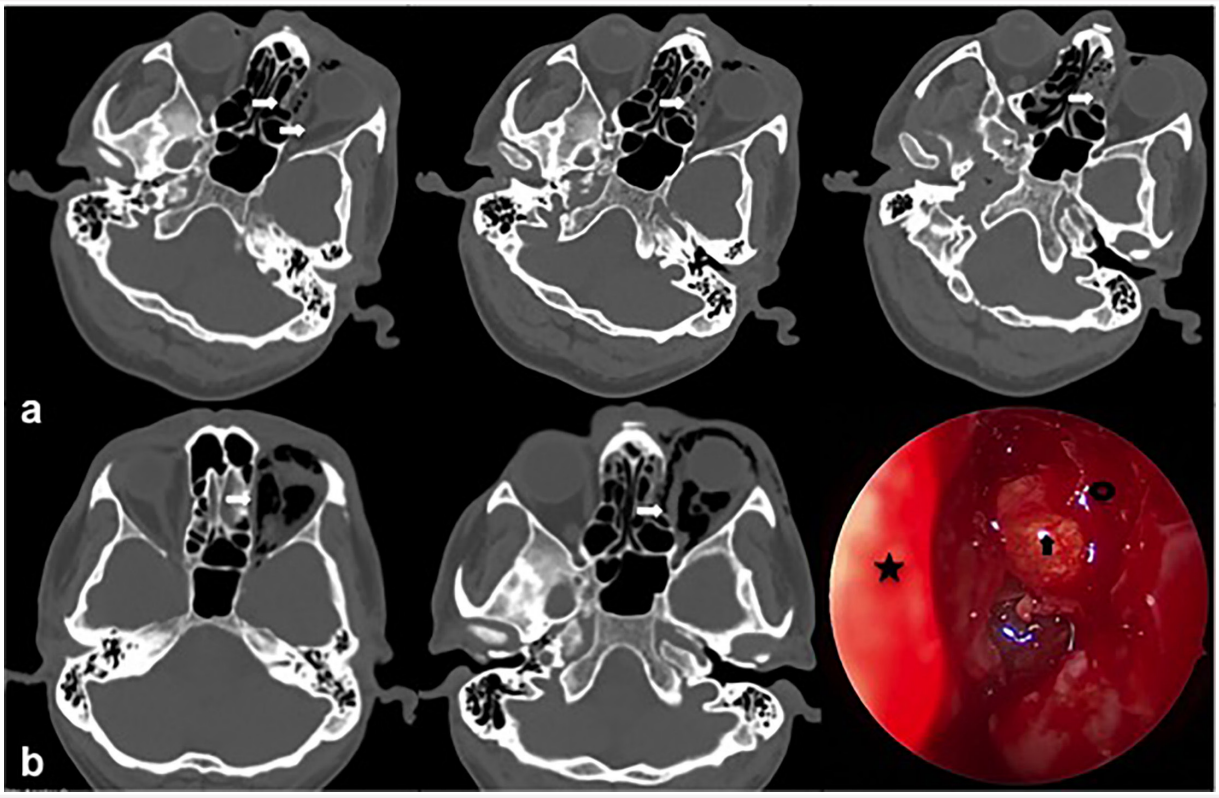

Figure 1. a,b. (a) Axial sections of initial maxillofacial CT scan indicate slightly depressed left orbital medial wall (white arrow) and minimal air. (b) Axial sections show pneumo-orbit and intraoperative endoscopic view of sinonasal cavity showing nasal septum (★), fracture in lamina papyracea (○), and protruding fat (é).

pressure and immediately endonasal endoscopic orbital decompression was performed. At the beginning of surgery, 1000 mg metilprednisolon was administered to reduce the edema around the optic nerve (Figure 1).

Intraoperatively, the middle concha was mediated, total uncinectomy and left maxillary antrostomy were performed, and hemorrhage remnants were cleaned. The frontal sinus ostium was expanded with the intact bulla technique and total sphenoethmoidectomy subsequently performed. The orbital medial wall was exposed and an empty space was provided for decompression. A small amount of orbital fat was observed protruding through the medial fracture. The lamina papyracea was removed completely, and a clear view was achieved. By applying external pressure to the eye, the orbital air was seen to reach the nasal cavity, and the orbital swelling was immediately reduced. Decompression was accomplished by making a periorbital incision.

On the first post-operative day, improvements in proptosis, swelling, and movements of the left eye were detected (Figure 2). Given these complete improvements, the patient was discharged with steroid therapy (1 mg/kg/day metilprednisolon) in reducing doses by half at 2-day intervals.

MAIN POINTS

- Orbital compartment syndrome (OCS) can cause vision loss and requires immediate treatment.
- A small fracture can lead to pneumo-orbit and OCS by working as a valve mechanism that prevents air escaping the eye.
- Endoscopic orbital decompression is the best treatment with or without lateral canthotomy.
- High-dose corticosteroids can improve visual capacity by reducing edema around the optic nerve and disc.
- It is important to inform the patients about the later complications that may occur.

DISCUSSION

Orbital compartment syndrome occurs through mass effect or fluid accumulation in the orbit which can compress the optic nerve and cause ischemia. Although there is an increased probability of post-traumatic OCS from hemorrhage and fracture, the development of pneumo-orbit and OCS has been rarely described in these circumstances,[1,4,5,6] although sneezing, nose blowing, or coughing after an orbital wall fracture can all be causes.[7] There are many etiological factors and several studies have shown OCS development in different, but relatively rare cases. Early diagnosis and immediate treatment are crucial because OCS can lead to vision loss through prolonged compression of the optic nerve.[1-5]

Figure 2. a-c. (a) Swelling and ecchymosis at first presentation. (b) Proptosis at subsequent presentation. (c) Improvements on first postoperative day.

To diagnose OCS, all possible causes, including surgical or maxillofacial trauma, anticoagulant use, bleeding diathesis, and intraorbital mass, must be investigated. Patients often complain of decreased vision and pain with a feeling of pressure in the eye,[1,8] and loss of movement or even total ophthalmoplegia can be detected. Color vision should also be evaluated in a patient who does not show a decrease in visual acuity.[8,9] After trauma, visual examination is crucial even if eyelid edema, ecchymosis, or proptosis make the process difficult.

Although eyelid emphysema is common after blunt trauma, a large volume of air intake and pneumo-orbit are relatively rare.[6,7] As in this case, however, even a small fracture can lead to pneumo-orbit, and OCS, by working as a valve mechanism that prevents air escaping the eye. In such small orbital fractures, which are typically treated conservatively, it is important to inform the patient about the visual complications that may develop and the precautions they may need to take to avoid them. If OCS following pneumo-orbit occurs, the patient should be treated immediately as even the smallest delay could lead to optic nerve ischemia and permanent loss of vision.

If OCS is diagnosed, the possible treatment includes surgical decompression followed by medical therapy. It is particularly important to expand the closed bony walls of the orbital cavity to reduce intraocular pressure and prevent optical nerve damage. This orbital decompression can be performed using external incisions or an endonasal endoscopic approach, but the aim is to reduce orbital pressure as quickly as possible in either case.[1,4,5]

Lateral canthotomy and cantholysis are bedside procedures that can moderately reduce intraorbital pressure under local anesthesia,[10] but if rapid surgical intervention is possible, endoscopic orbital decompression with the removal of the bone wall is the best treatment with or without lateral canthotomy.[7,9,10] Existing studies have shown that lateral canthotomy provides some decrease in intraorbital pressure but does not achieve sufficient reduction.[10]

Endoscopic decompression can be performed using a transorbital, transnasal, or transcranial route, with transnasal decompression being a particularly effective and reliable approach, especially in diffuse masses, lesions, or fractures. The medial orbital wall is removed where it protrudes into the sinuses, and interventions can be made to resolve the underlying condition at the same time.

While surgical intervention is the first choice, it is important to support it with appropriate subsequent treatment.[8] In cases of only slightly increased intraocular pressure, close follow-up with medical treatment can be applied. After surgical intervention, any orbital edema and remaining pressure can be further reduced with relevant drug therapies such as the most commonly used corticosteroids.[1] High-dose corticosteroids can improve visual capacity by reducing edema around the optic nerve and disc.

In conclusion, although an OCS diagnosis may not be possible in the period immediately after a blunt maxillofacial trauma affecting the orbit, it is important to inform patients about the later complications that may occur. Timing is important in the treatment of OCS with appropriate interventions and orbital decompression. A well-timed endoscopic approach ensures the preservation of vision and rapid recovery without scarring and can be implemented as a safe and minimally invasive method in most OCS cases.

Informed Consent: Written informed consent was obtained from the patient who participated in this case.

Peer Review: Externally peer-reviewed.

Author Contributions: Concept - H.B.; Design - H.B.; Literature Review - L.Y.; Writing Manuscript - H.B.; L.Y.; Critical Review - S.B.

Conflict of Interest: The authors have no conflicts of interest to declare.

Financial Disclosure: The authors declared that this study has received no financial support.

REFERENCES

1. McCallum E, Keren S, Lapira M, Norris JH. Orbital compartment syndrome: An update with review of the literature. *Clin Ophthalmol*. 2019;13:2189-2194. [CrossRef]
2. Sun MT, Chan WO, Selva D. Traumatic orbital compartment syndrome: Importance of the lateral canthomy and cantholysis. *Emerg Med Australas*. 2014;26(3):274-278. [CrossRef]
3. Kratky V, Hurwitz JJ, Avram DR. Orbital compartment syndrome. Direct measurement of orbital tissue pressure: 1. Technique. *Can J Ophthalmol*. 1990;25(6):293-297.
4. Riemann CD, Foster JA, Kosmorsky GS. Direct orbital manometry in patients with thyroid-associated orbitopathy. *Ophthalmology*. 1999;106(7):1296-1302. [CrossRef]
5. Edmunds MR, Haridas AS, Morris DS, Jamalapuram K. Management of acute retrobulbar haemorrhage: A survey of non-ophthalmic emergency department physicians. *Emerg Med J*. 2019;36(4):245-247. [CrossRef]
6. Roelofs KA, Starks V, Yoon MK. Orbital Emphysema: A Case Report and Comprehensive Review of the Literature. *Ophthalmic Plast Reconstr Surg*. 2019;35(1):1-6. [CrossRef]
7. Key SJ, Ryba F, Holmes S, Manisali M. Orbital emphysema – the need for surgical intervention. *J Craniomaxillofac Surg*. 2008;36(8):473-476. [CrossRef]

8. Lima V, Burt B, Leibovitch I, et al. Orbital compartment syndrome: the ophthalmic surgical emergency. *Surv Ophthalmol*. 2009;54(4):441-449. [CrossRef]
9. Perry M. Acute proptosis in trauma: retrobulbar hemorrhage or orbital compartment syndrome—does it really matter? *J Oral Maxillofac Surg*. 2008;66(9):1913-1920. [CrossRef]
10. Mootha VV, Cowden TP, Sires BS, Dortzbach RK. Subperiosteal orbital hemorrhage from retrobulbar injection resulting in blindness. *Arch Ophthalmol*. 1997;115(1):123-124. [CrossRef]