ENT Updates

ORIGINAL ARTICLE

ENT UPDATES 11(3):180-187
DOI: 10.5152/entupdates.2021.21104

Radiologic Evaluation of the Prechiasmatic Sulcus in Adults and Clinical Implications

ABSTRACT

Background: The present work intended to analyze the prechiasmatic sulcus types in adults via cone-beam computed tomographic images.

Methods: Four hundred randomly selected adult patient files registered in the electronic system of Gaziantep University Faculty of Dentistry were investigated retrospectively. The morphological features of the prechiasmatic sulcus including its size, angulation, and classification were revealed.

Results: The planum length was measured as 11.82±3.12 mm (4.70-20.72 mm), the sulcal length as 5.61±1.50 mm (1.82-11.20 mm), the sulcal angle (SA) as 18.66±9.90° (0-50.60°), and the interoptic distance as 17.65±2.14 mm (8.60-24.52 mm). The interoptic distance was greater in male samples compared to females ($P < .001$); however, the sulcal angle ($P = .834$), sulcal length ($P = .658$), and planum length ($P = .326$) were similar in genders. Considering the average groove length and angle, the narrow steep sulcus was observed as 22.25% (89 cases), the narrow flat sulcus as 26.75% (107 cases), the wide steep sulcus as 25.5% (102 cases), and the wide flat sulcus as 25.5% (102 cases).

Conclusions: The findings of this radiologic study may be helpful for neurosurgeons, neuroradiologists, and otorhinolaryngologists in selection of patients suitable for surgical approach (e.g., endonasal or transcranial), by providing categorization of the prechiasmatic sulcus during resection of sulcus-related pathological entities.

Keywords: Adult, cone-beam computed tomography, prechiasmatic sulcus, sellar region

INTRODUCTION

The complex anatomy of the suprasellar region leads to the diversification of surgical approaches (endonasal, pterional, subfrontal, supraorbital, etc.) in the resection of lesions such as meningiomas.[1,2] Anatomic variations of the prechiasmatic sulcus (PS), the groove between the limbus of the sphenoid and tubercle of the sella turcica, may result in a technical challenge for operation teams (neurosurgeons, neuroradiologists, and otorhinolaryngologists) in terms of determining appropriate approach.[1] Taking into account the sulcal angle (SA) (steep sulcus > mean angle and flat sulcus < mean angle) and sulcal length (SL) (wide sulcus > mean length and narrow sulcus < mean length), the PS was identified by Guthikonda et al[1] as 4 types: the wide flat sulcus (WFS), wide steep sulcus (WSS), narrow flat sulcus (NFS), and narrow steep sulcus (NSS). Guthikonda et al[1] recommended the pterional approach in a case with the NSS during removing tumors such as meningioma, while the supraorbital or subfrontal approach in a case with the WFS. They also proposed transcranial techniques in a case with a narrow groove, whereas transsphenoidal approaches in a case with a wide groove.[1]

This classification, based on the average angle and length of the groove, facilitates the selection of patients suitable for surgical procedures such as endonasal and transcranial approaches.[1,3,4] It is known that computed tomography imaging will be beneficial before many skull base surgeries.[5] In accordance with this, Guthikonda et al[1] recommended performing a preoperative radiological evaluation prior to resection of pathological entities, as the PS types enable the categorization of the suprasellar region. In the literature, the sulcus types were studied in different populations (e.g., Turkish, Greek, and American), samples (e.g., adult dry skulls, fetuses, and children), and techniques (radiologic or direct

Orhan Beger[1]
İlhan Bahşi[1]
Saliha Seda Adanır[1]
Mustafa Orhan[1]
Piraye Kervancıoğlu[1]
Eda Didem Yalçın[2]

[1]Department of Anatomy, Gaziantep University Faculty of Medicine, Gaziantep, Turkey
[2]Department of Dentomaxillofacial Radiology, Dokuz Eylül University Faculty of Dentistry, İzmir, Turkey

Cite this article as: Beger O, Bahşi İ, Adanır SS, Orhan M, Kervancıoğlu P, Yalçın ED. Radiologic evaluation of the prechiasmatic sulcus in adults and clinical implications. *ENT Updates.* 2021;11(3):180-187.

Corresponding author:
İlhan Bahşi
Email: *dr.ilhanbahsi@gmail.com*
Received: *September 9, 2021*
Accepted: *November 9, 2021*

Content of this journal is licensed under a Creative Commons Attribution-NonCommercial 4.0 International License.

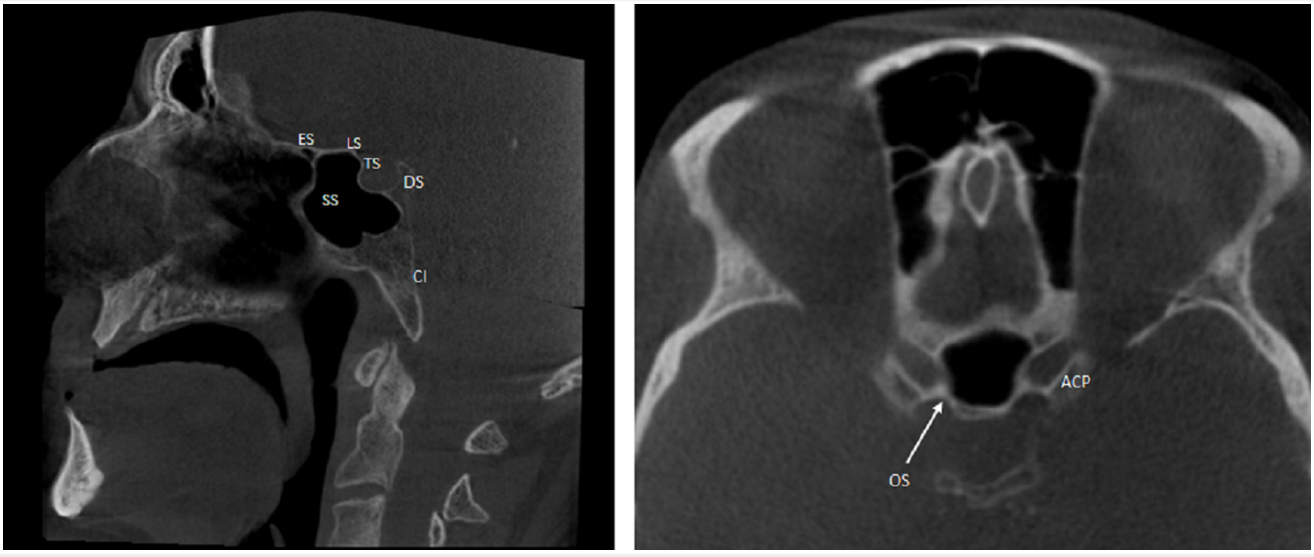

Figure 1. The suprasellar region was presented in the photographs.
Cl, clivus; LS, limbus of sphenoid; TS, tubercle of the sella turcica; ACP, anterior clinoid process; OS, optic strut; ES, ethmoidal spine; SS, sphenoid sinus; DS, dorsum sellae.

anatomic measurements).[1,3,4,6] As far as we know, radiological analysis is limited to Beger et al's[3] study conducted on pediatric patients aged under 20 years. It is known that the most critical disadvantage of dry bone studies is the difficulty in knowing the gender, age, and ethnic characteristics.[7] Besides, the bone structures can be seen quite clearly on the cone-beam computed tomography (CBCT) images.[8] In this context, the present work intended to present the PS types in adult subjects via CBCT images.

METHODS

This study, which was carried out on the images in the CBCT archive in the Dentomaxillofacial Radiology Department of the Gaziantep University Faculty of Dentistry, was approved by the Gaziantep University Clinical Research Ethics Committee (Decision number: 2020/377). Images of the patients who applied for CBCT for any reason after ethical approval were evaluated retrospectively. The inclusion criteria in the population were: (a) 400 randomly selected adult cases, 200 males and 200 females, (b) cases over 18 years, (c) cases without fractures in skull bones, (d) cases without genetic or syndromic malformations such as cleft lip and cleft palate, (e) patients without tumoral, infectious, or vascular diseases in the head region, and (f) patients with high-quality CBCT scans. The exclusion criteria of the work were as follows: (a) cases below 18 years, (b) cases with vascular lesions, infectious diseases, tumors, fractures, and malformations (genetic or syndromic) in the head area, (c) cases with low-quality CBCT scans, and (d) cases after 400 randomly chosen patients. Using a CBCT device (Planmeca ProMax 3D Mid, 90 kV, 9-12 mA, 12-14 s, voxel size: 0.4 mm^3, Helsinki, Finland), the patients' heads were scanned in standard imaging protocol to obtain axial, coronal, and sagittal scans with 1-mm slice thickness.

First, anatomical landmarks are determined in sagittal and transverse sections (Figure 1), and the following 4 parameters were examined (Figure 2):

The interoptic distance (IOD): the distance between both optic struts' posteromedial aspects

The planum length (PL): the distance from the ethmoidal spine to the limbus of sphenoid

SA: the angle between the PS and sphenoidal yoke

SL: the distance from the limbus of sphenoid to tubercle of the sella turcica

Later, according to the study of Guthikonda et al[1] the PS was classified into 4 types considering the average sulcus length and angle: NSS, NFS, WSS, and WFS.

MAIN POINTS

- Endonasal approaches may be proffered in cases with wide interoptic distance (which is taken into consideration as the distance between the right and left lateral opticocarotid recesses at endoscopic transnasal appearance), as the groove provides a spacious endoscopic field of view.
- In this context, a successful and effective surgical corollary in the sellar region including the prechiasmatic sulcus may be thought to be dependent on detailed anatomical knowledge (exhaustive classifications, extended morphometric datasets, etc.) of an operation team.
- These findings about the prechiasmatic sulcus may be useful for operation teams in selections of patients suitable for surgical approaches such as endonasal and transcranial approaches.

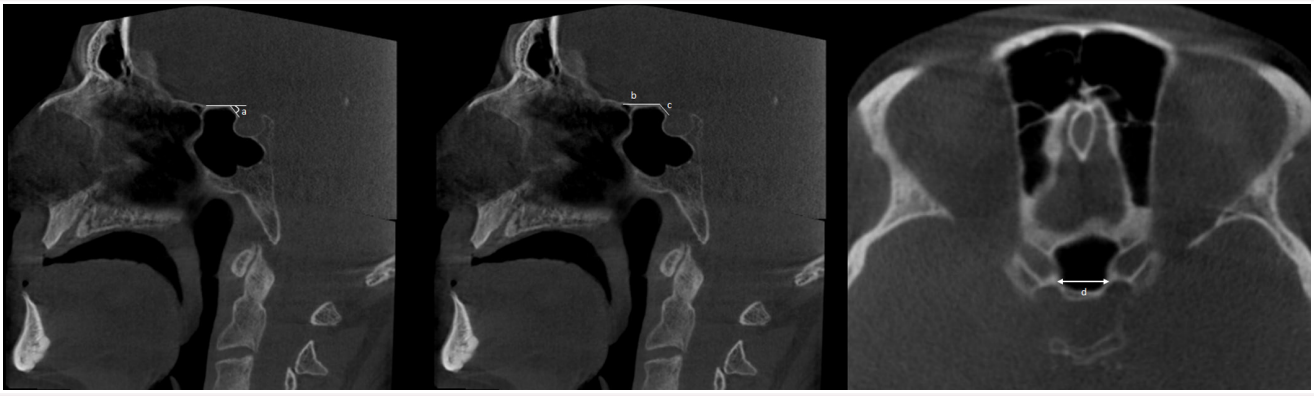

Figure 2. The parameters were presented in the photographs. a, sulcal angle; b, planum length; c, sulcal length; d, interoptic distance.

Statistical Analysis

The Shapiro–Wilk test was used to test the suitability of morphometric values for the normal distribution. The independent sample *t*-test was utilized for sex comparison. Through the Pearson correlation coefficient test, the relations between the morphometric values were evaluated. Alterations in the parameters relative to the classification of the PS were investigated via the one-way ANOVA and post hoc Bonferroni tests. The relation between sex and the PS types was assessed with the Chi-square test. Statistical Package for the Social Sciences (SPSS) version 22.0 (IBM SPSS Corp.; Armonk, NY, USA) was used for statistical analysis, and the significance level for statistical analysis was accepted as $P < .05$.

Table 2. Correlations Between the Parameters

Parameters		PL (mm)	IOD (mm)	SA (˚)
SL (mm)	*r*	0.058	-0.065	*0.161**
	P	.246	.197	*.001*
PL (mm)	*r*		-.015	*-0.134**
	P		.762	*.007*
IOD (mm)	*r*			0.020
	P			.694

**P* values are statistically significant for these *r* values ($P < .05$).
SL, sulcal length; PL, planum length; IOD, interoptic distance, SA, sulcal angle.

RESULTS

The CBCT images of 200 females (mean age: 42.22±14.25) and 200 males (mean age: 43.83±14.33) were examined in detail. There was no statistically significant difference between the genders ($P = .261$). The average values ± standard deviations of the parameters were presented in Table 1. Our findings were as follows:

The IOD was greater in males compared to females ($P < .001$); however, the SA ($P = .834$), SL ($P = .658$), and PL ($P = .326$) were similar in males and females (Table 1).

The PL was very weak and negatively correlated with the SA ($P = .007$, $r = -0.134$), and the SL was very weak and positively correlated with the SA ($P < .001$, $r = 0.161$) (Table 2).

Considering the average values of the SL (wide groove > 5.61 mm, narrow groove < 5.61 mm) and SA (steep groove > 18.66˚, flat groove < 18.66˚), the NSS was observed as 22.25% (89 cases), the NFS as 26.75% (107 cases), the WSS as 25.5% (102 cases), and the WFS as 25.5% (102 cases) (Figure 3).

As expected, the SL in subjects with the WSS and WFS was greater than that in subjects with the NSS and NFS ($P < .001$). Moreover, the SA in subjects with the NSS and WSS was greater than that in subjects with the WFS and NFS ($P < .001$) (Table 3).

The IOD did not alter according to the PS types ($P = .054$), whereas the PL in subjects with the NSS was smaller compared to that in subjects with the WFS and NFS ($P = .001$) (Table 3).

The distribution percentage of the PS types according to sexes showed that the classification of the optic groove was not related to sexes in adults ($P = 0.726$) (Table 4).

The dispersion ranking of the types in male samples was observed as WFS (27.5%) > NFS (25.5%) > WSS (24%) > NSS (23%), whereas that in female samples as NFS (28%) > WSS (27%) > WFS (23.5%) > NSS (21.5%) (Table 4).

Table 1. The Measurements of the PS and Also Sex Comparison

Parameters	All Samples	Males	Females	*P*
SL (mm)	5.61±1.50 (1.82-11.20)	5.64±1.55	5.57±1.46	.658
PL (mm)	11.82±3.12 (4.70-20.72)	11.98±3.21	11.67±3.03	.326
IOD (mm)	17.65±2.14 (8.60-24.52)	18.28±2.18	17.02±1.91	*<.001**
SA (˚)	18.66±9.90 (0-50.60)	18.77±10.01	18.56±9.81	.834

SL, sulcal length; PL, planum length; IOD, interoptic distance; SA, sulcal angle.

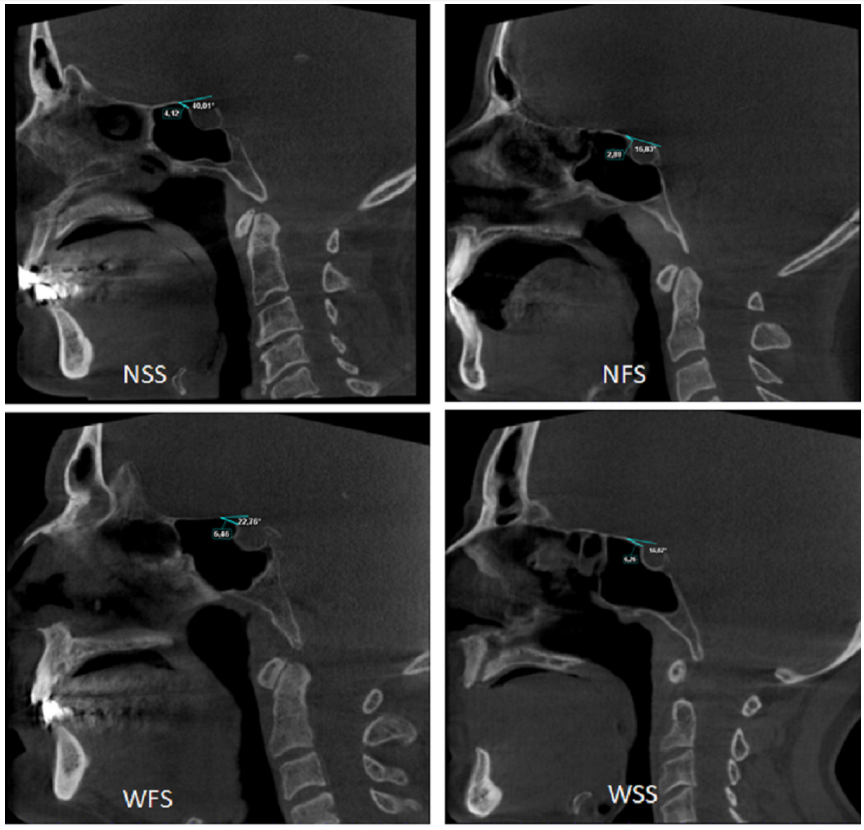

Figure 3. Types of the PS. NSS, narrow steep sulcus; NFS, narrow flat sulcus; WSS, wide steep sulcus; WFS, wide flat sulcus; PS, prechiasmatic sulcus.

Table 3. Comparison of the Parameters According to the PS Types

Parameters	NSS (N = 89)	NFS (N = 107)	WSS (N = 102)	WFS (N = 102)	*P*
SL (mm)	4.46±0.82[b,c]	4.34±0.87[b,c]	6.83±0.94	6.71±1.02	*< 0.001**
PL (mm)	10.72±2.83[a,c]	12.29±3.41	11.85±3.01	12.28±2.94	*0.001**
IOD (mm)	18.14±1.77	17.48±1.94	17.32±2.48	17.74±2.22	0.054
SA (°)	26.12±6.23[a,c]	10.65±5.21[b]	27.36±7.82[c]	11.87±4.83	*< 0.001**

[a]Comparison to NFS; [b]Comparison to WSS; [c]Comparison to WFS. *Statistical difference ($P < .05$).
SL, sulcal length; PL, planum length; IOD, interoptic distance; SA, sulcal angle; WFS, wide flat sulcus; WSS, wide steep sulcus; NFS, narrow flat sulcus; NSS, narrow steep sulcus.

Table 4. Distribution of the PS Types in Males and Females

PS Types	Males	Females	Total	*P*
NSS	46 (23%)	43 (21.5%)	89 (22.25%)	.726
NFS	51 (25.5%)	56 (28%)	107 (26.75%)	
WSS	48 (24%)	54 (27%)	102 (25.5%)	
WFS	55 (27.5%)	47 (23.5%)	102 (25.5%)	
Total	200	200	400	

PS, prechiasmatic sulcus; WFS, wide flat sulcus; WSS, wide steep sulcus; NFS, narrow flat sulcus; NSS, narrow steep sulcus.

DISCUSSION

One of the essential ways to avoid technical challenges during the treatment of sellar lesions (e.g., meningioma) is to understand the complex anatomy of the region.[1,9-11] For instance, the sphenoid sinus pneumatization deficiency leads to deficient bone thickness, obscure anatomical landmarks, and a decrease in IOD; therefore, its lack poses a risk for damage to neurovascular structures during endonasal approaches even when implemented under neuronavigation.[11,12] Since transnasal approaches are thought to be contraindicated in patients with pneumatization deficiency (especially in young

children), transcranial techniques may be recommended.[11-13] Guthikonda et al[1] defined the chiasmatic ridge as a bony projection of the sphenoidal yoke over the PS and argued that a hidden area formed by the ridge during resection of the sellar lesions with pterional or subfrontal approaches might result in a residual tumor due to the limitation of the surgeon's field of vision. In such cases, the chiasmatic ridge should be resected or a different surgical procedure such as transnasal approaches should be preferred during preoperative radiologic evaluation.[1,14] On the other hand, anatomical structures (the lateral opticocarotid recess, optic strut, anterior clinoid process) associated with the PS may be used as landmarks during surgical interventions in the sellar region.[1,9-11,15-18] Endonasal approaches may be proffered in cases with wide IOD (which is taken into consideration as the distance between the right and left lateral opticocarotid recesses at endoscopic transnasal appearance), as the groove provides a spacious endoscopic field of view.[1,4,16,17] In this context, a successful and effective surgical corollary in the sellar region including the PS may be thought to be dependent on detailed anatomical knowledge (exhaustive classifications, extended morphometric datasets, etc.) of an operation team.

The range (3.91-8.70 mm) of average SL in previous studies conducted on fetuses (3.91 mm),[3] children (6.94 mm),[3] and adults (4.75-8.70 mm)[1,4,19-23] was given in Table 5, which showed that after birth, the length did not vary in accordance with our adult data (5.61±1.50 mm). The SA (18.66±9.90°) in this study was smaller than that (mean range: 24.05-31.01°) in previous works focused on the fetuses (24.52°),[6] children (31.01°),[3] and adults (24.05-31.00°).[1,4] In their fetal investigation, Beger et al[6] reported that the angle reached adult dimension in the prenatal period, taking into account the adult data in the literature[1,4]; nevertheless, in their radiologic examination focused on children aged between 0 and 20 years,[3] the authors observed that the angle did not alter after birth (41.05° in infants) up to prepubescent (33.61°) but it decreased statistically in postpubescent (22.12°) (Table 5). Although the average angle in our adult population was lower than those available from the previous adult works,[1,4] it seemed to promote interpretations of Beger et al (who argued that the growth dynamic of the angle possibly depending on the spheno-occipital synchondrosis and sphenoid sinus pneumatization showed an erratic downward trend in pediatric subjects) and Kier and Rothman[24] (who explained that increased pneumatization of the sphenoid sinus might result in the more uncertain and more flat groove). The PL (11.82±3.12 mm) in our adult population was greater than that in fetuses (6.55±1.51 mm)[6] whereas smaller than that in children (14.84±4.12 mm)[3] and adults (14.10-19.00 mm).[1,4,17,25] The IOD (17.65±2.14 mm) in this study was found in accordance with adult (14.40-19.30 mm)[1,4,19,21,22] and child (14.70±2.85 mm)[3] measurements in the literature but greater than fetal data (6.88±1.04 mm).[6]

In the literature, average values of the parameters were offered in a wide range (Table 5).[1,3,4,6,17,19-23,25] The reasons for differences between the studies might be listed as follows: (a) demographic features (age, race, region, sex, etc.), (b) materials (cadavers, dry skulls, patients, etc.), (c) skull base development (fetuses, children, adults), and (d) measurement techniques (radiologic or anatomical investigation, i.e., digital caliper, goniometer, or software). For example, no difference was discovered between measurements of the PL, SA, or SL in terms of sexes. Beger et al[3] found that the SL in boys (7.15±1.37 mm) was statistically greater than that in girls (6.74±1.09 mm). Also, Kanellopoulou et al[4] declared that the SA in females (14.82±12.43°) was statistically smaller compared to that in males (28.29±15.24°). Similar to measurements of Beger et al[3] (14.21±2.70 mm for girls, 15.20±2.92 mm for boys), we sighted that the IOD in females (17.02±1.91 mm) was statistically smaller than that in males (18.28±2.18 mm). One of the reasons triggering difference between the studies may be working methodology. The SA in our adult samples (measurements with the software on CBCT images) was found smaller compared to the studies focused on adults (measurements with goniometer on dry skulls).[1,4] Considering the study of Guthikonda et al[1] (e.g., the IOD in American samples: 19.30±2.40 mm), Kanellopoulou et al[4] reported that regional or ethnic differences might significantly affect the morphology of the sellar region including the PS (e.g., the IOD in Greek samples: 16.90±2.50 mm). On the other hand, prenatal and postnatal development processes of the skull base directly change the groove morphology.[3,6,23,24] Depending on the spheno-occipital synchondrosis and sphenoid sinus pneumatization, the groove evolves to a flatter shape[3,24]; therefore, the SA in children (infants and young children) is higher than in adults.[3]

Taking into account the classification of Guthikonda et al.[1] the PS types in our adult population were put in order as NFS (26.75%) > WSS (25.5%) = WFS (25.5%) > NSS (22.25%). This collocation was not compatible with the rankings in fetuses (WSS, 30.43% > NSS, 26.09% > NFS, 21.74% = WFS, 21.74%),[6] children (WFS, 26.5% > NFS, 26% > NSS, 24% > WSS, 23.5%),[3] and adult dry skulls (NSS, 30-35.8% > WFS, 29-32.1% > NFS, 18.5-22% > WSS, 13.6-19%) (Table 6).[1,4] Beger et al[3] stated that the PS type dispersion was affected by ages in children (e.g., infants vs. postpubescents) (Table 6). This explanation may explain why our ranking is different from fetuses and children. The distribution in our adult examination (radiologic work) was distinctly different from the order in the previous studies conducted on adult dry skulls (anatomical work).[1,4] In our opinion, this situation might be due to methodological differences. On the other hand, the percentage of the patients with steep groove (NSS and WSS) in females (44.44% for fetuses, 43% for children, and 36.4% for adult dry skulls) was reported as lower than that in males (64.28% for fetuses, 52% for children, and 51.8% for adult dry skulls).[3,4,6] In this study, this percentage in adult males (47%) was found as similar to adult females (48.5%). This observation seemed to contradict the explanation of Beger et al[3,6] (who claimed that the groove was flatter in girls). In this study, the IOD, SL, and SA (except the expected difference due to the classification) did not vary according to the PS types, but the PL in samples with the NSS was smaller than that with NFS and WFS. Kanellopoulou et al[4] reported greater PL in NFS and WFS than in the NSS and WSS and greater length in WFS than in NFS. Beger et al[3] and Kanellopoulou et al[4] found greater SL in WFS than in WSS. Beger et al[3] measured greater SA in NSS than in WSS, while Kanellopoulou et al[4] measured greater angle in the NFS than in the WFS. Beger et al[3] observed greater IOD in WFS than in WSS.

Table 5. The Literature Data Related to the Measurements of PS Parameters

Studies	Region	Numbers	Samples	Age	SL (mm)	PL (mm)	IOD (mm)	SA (°)
Beretta et al[19]	USA	50	Dry skulls	Adult	6±0.50	-	14.40±1.40	-
Ozcan et al[17]	Turkey	29	Cadavers	Adult	-	14.80 (12.38-18.90)	-	-
Dağtekin et al[20]	Turkey	25	Dry skulls	-	6.70 (3.50-11.50)	-	-	-
Guthikonda et al[1]	USA	100	Dry skulls	Adult	7.45±1.27	19±2.35	19.30±2.40	31±14.20
Kanellopoulou et al[4]	Greece	96	Dry skulls	Adult	7.20±1.80	18.60±3.20	16.90±2.50	24.05±17.17
Lang[23]	-	-	-	-	6.80 (3.30-10.30)	14.20 (6.10-23.60)	14	24.80 (9-43)
Zada et al[25]	USA	100	Healthy persons	Adult	-	14.10 (6.40-28.80)	-	-
Beger et al[6]	Turkey	23	Fetuses	21.70±3.12 weeks	3.91±0.74	6.55±1.51	6.88±1.04	24.52±9.51
de Notaris et al[21]	-	24	Patients	-	4.75±1.25	-	17.70±2.64	-
Gökçe et al[22]	Turkey	50	Male patients	Adult	8.70±1.80	-	18.40	-
		50	Female patients	Adult	8.30±2.20	-	18	-
Beger et al[3]	Turkey	200	Children	10.50±5.78 years	6.94±1.25	14.84±4.12	14.70±2.85	31.01±18.13
		20	Infancy	0-2 years	7.19±1.33	9.30±2.15	11.21±1.47	41.05±15.29
		30	Early childhood	3-5 years	6.90±1.33	11.44±1.85	11.99±1.49	37.02±18.47
		40	Later childhood	6-9 years	6.61±1.20	12.79±2.82	14.40±2.04	34.43±21.94
		40	Prepubescence	10-13 years	7.05±1.28	17.37±3.41	14.97±2.04	33.61±17.28
		70	Postpubescence	14-20 years	7.03±1.20	17.61±2.72	16.89±2.35	22.12±12.82
This study	Turkey	400	Patients	43.02±14.30 years	5.61±1.50	11.82±3.12	17.65±2.14	18.66±9.90

SL, sulcal length; PL, planum length; IOD, interoptic distance; SA, sulcal angle; PS, prechiasmatic sulcus.

Table 6. The Literature Data Related to the PS Types

Studies	Regions	Numbers	Samples	Ages	NSS (%)	NFS (%)	WSS (%)	WFS (%)
Guthikonda et al[1]	USA	100	Dry skulls	Adult	30	22	19	29
Kanellopoulou et al[4]	Greece	96	Dry skulls	Adult	35.8	18.5	13.6	32.1
		29	Males	-	29.6	25.9	22.2	22.2
		17	Females	-	18.2	18.2	18.2	45.5
Beger et al[6]	Turkey	23	Fetuses	21.70±3.12 weeks	26.09	21.74	30.43	21.74
		14	Boys	-	28.57	14.29	35.71	21.43
		9	Girls	-	22.22	33.33	22.22	22.22
Beger et al[3]	Turkey	200	Children	10.50±5.78 years	24	26	23.5	26.5
		100	Boys	-	27	16	25	32
		100	Girls	-	21	36	22	21
		20	Infancy	0-2 years	25	10	50	15
		30	Early childhood	3-5 years	33.3	20	36.7	10
		40	Later childhood	6-9 years	40	27.5	7.5	25
		40	Prepubescence	10-13 years	27.5	12.5	35	25
		70	Postpubescence	14-20 years	8.6	40	12.8	38.6
This study	Turkey	400	Adult patients	43.02±14.30 years	22.25	26.75	25.5	25.5
		200	Males	43.83±14.33 years	23	25.5	24	27.5
		200	Females	42.22±14.25 years	21.5	28	27	23.5

PS, prechiasmatic sulcus; WFS, wide flat sulcus; WSS, wide steep sulcus; NFS, narrow flat sulcus; NSS, narrow steep sulcus.

CONCLUSION

The SL in this study was found in accordance with previous investigations, which explained that after birth, the length did not vary. The SA in our adult population was lower than those available from the previous studies focused on adult dry skulls; however, the angle seemed to match the erratic downward trend in children. In our opinion, the findings of this radiologic examination may be useful for operation teams in the selection of patients suitable for surgical approaches such as endonasal and transcranial approaches.

Ethics Committee Approval: This study was approved by the Ethics Committee of Gaziantep University (Approval number: 2020/377).

Informed Consent: Informed consent was not obtained due to the retrospective design of this study.

Peer Review: Externally peer-reviewed.

Author Contributions: Concept - B.O., B.İ., A.S.S., O.M., K.P., Y.E.D.; Design - B.O., B.İ., A.S.S., O.M., K.P., Y.E.D.; Supervision - B.O., B.İ., A.S.S., O.M., K.P., Y.E.D.; Resource - B.O., B.İ., A.S.S., O.M., K.P., Y.E.D.; Materials - B.O., B.İ., A.S.S., O.M., K.P., Y.E.D.; Data Collection and/or Processing - B.O., B.İ., A.S.S., O.M., K.P., Y.E.D.; Analysis and/or Interpretation - B.O., B.İ., A.S.S., O.M., K.P., Y.E.D.; Literature Search - B.O., B.İ., A.S.S., O.M., K.P., Y.E.D.; Writing - B.O., B.İ., A.S.S., O.M., K.P., Y.E.D.; Critical Reviews - B.O., B.İ., A.S.S., O.M., K.P., Y.E.D.

Conflict of Interest: The authors have no conflict of interest to declare.

Financial Disclosure: The authors declared that this study has received no financial support.

REFERENCES

1. Guthikonda B, Tobler WD, Jr, Froelich SC, et al. Anatomic study of the prechiasmatic sulcus and its surgical implications. *Clin Anat*. 2010;23(6):622-628. [CrossRef]
2. Mortazavi MM, Brito da Silva H, Ferreira M, Jr, Barber JK, Pridgeon JS, Sekhar LN. Planum sphenoidale and tuberculum sellae meningiomas: operative nuances of a modern surgical technique with outcome and proposal of a new classification system. *World Neurosurg*. 2016;86:270-286. [CrossRef]
3. Beger O, Ten B, Balcı Y, et al. A computed tomography study of the prechiasmatic sulcus anatomy in children. *World Neurosurg*. 2020;141:e118-e132. [CrossRef]
4. Kanellopoulou V, Efthymiou E, Thanopoulou V, et al. Prechiasmatic sulcus and optic strut: an anatomic study in dry skulls. *Acta Neurochir (Wien)*. 2017;159(4):665-676. [CrossRef]
5. Uçar H, Bahşi I, Orhan M, Yalçin ED. The radiological evaluation of the crista galli and its clinical implications for anterior skull base surgery. *J Craniofac Surg*. 2021;32(5):1928-1930. [CrossRef]
6. Beger O, Taghipour P, Çakır S, et al. Fetal anatomy of the optic strut and prechiasmatic sulcus with a clinical perspective. *World Neurosurg*. 2020;136:e625-e634. [CrossRef]
7. Bahsi I. An anatomic study of the supratrochlear foramen of the humerus and review of the literature. *Eur J Ther*. 2019;25(4):295-303. [CrossRef]
8. Bahşi I, Orhan M, Kervancıoğlu P, Yalçın ED, Aktan AM. Anatomical evaluation of nasopalatine canal on cone beam computed tomography images. *Folia Morphol*. 2019;78(1):153-162. [CrossRef]
9. Gagliardi F, Donofrio CA, Spina A, et al. Endoscope-assisted transmaxillosphenoidal approach to the sellar and parasellar regions: an anatomic study. *World Neurosurg*. 2016;95:246-252. [CrossRef]
10. Kerr RG, Tobler WD, Leach JL, et al. Anatomic variation of the optic strut: classification schema, radiologic evaluation, and surgical relevance. *J Neurol Surg B Skull Base*. 2012;73(6):424-429. [CrossRef]

11. Locatelli M, Di Cristofori A, Draghi R, et al. Is complex sphenoidal sinus anatomy a contraindication to a transsphenoidal approach for resection of sellar lesions? Case series and review of the literature. *World Neurosurg*. 2017;100:173-179. [CrossRef]
12. Hamid O, El Fiky L, Hassan O, Kotb A, El Fiky S. Anatomic variations of the sphenoid sinus and their impact on trans-sphenoid pituitary surgery. *Skull Base*. 2008;18(1):9-15. [CrossRef]
13. Mazzatenta D, Zoli M, Guaraldi F, et al. Outcome of endoscopic endonasal surgery in pediatric craniopharyngiomas. *World Neurosurg*. 2020;134:e277-e288. [CrossRef]
14. Beger O, Bahşi I. Chiasmatic ridge: incidence, classification, and clinical implications. *J Craniofac Surg*. 2021;32(5):1910-1912. [CrossRef]
15. Cares HL, Bakay L. The clinical significance of the optic strut. *J Neurosurg*. 1971;34(3):355-364. [CrossRef]
16. Kassam AB, Gardner PA, Snyderman CH, Carrau RL, Mintz AH, Prevedello DM. Expanded endonasal approach, a fully endoscopic transnasal approach for the resection of midline suprasellar craniopharyngiomas: a new classification based on the infundibulum. *J Neurosurg*. 2008;108(4):715-728. [CrossRef]
17. Ozcan T, Yilmazlar S, Aker S, Korfali E. Surgical limits in transnasal approach to opticocarotid region and planum sphenoidale: an anatomic cadaveric study. *World Neurosurg*. 2010;73(4):326-333. [CrossRef]
18. Peris-Celda M, Kucukyuruk B, Monroy-Sosa A, Funaki T, Valentine R, Rhoton AL, Jr. The recesses of the sellar wall of the sphenoid sinus and their intracranial relationships. *Neurosurgery*. 2013;73(suppl 2 Operative):ons117-ons131; discussion ons31. [CrossRef]
19. Beretta F, Sepahi AN, Zuccarello M, Tomsick TA, Keller JT. Radiographic imaging of the distal dural ring for determining the intradural or extradural location of aneurysms. *Skull Base*. 2005;15(4):253-261; discussion 61-62. [CrossRef]
20. Dagtekin A, Avci E, Uzmansel D, et al. Microsurgical anatomy and variations of the anterior clinoid process. *Turk Neurosurg*. 2014;24(4):484-493. [CrossRef]
21. de Notaris M, Solari D, Cavallo LM, et al. The "suprasellar notch," or the tuberculum sellae as seen from below: definition, features, and clinical implications from an endoscopic endonasal perspective. *J Neurosurg*. 2012;116(3):622-629. [CrossRef]
22. Gökce C, Cicekcibasi AE, Yilmaz MT, Kiresi D. The morphometric analysis of the important bone structures on skull base in living individuals with multidetector computed tomography. *Int J Morphol*. 2014;32(3):812-821. [CrossRef]
23. Lang J. *Skull Base and Related Structures: Atlas of Clinical Anatomy*. Stuttgart: Schattauer Verlag; 2001.
24. Kier EL, Rothman S, eds. Radiologically significant anatomic variations of the developing sphenoid in humans. *Symposium on the Development of the Basicranium* (Publication no. NIH 1976).
25. Zada G, Agarwalla PK, Mukundan S, Jr, Dunn I, Golby AJ, Laws ER, Jr. The neurosurgical anatomy of the sphenoid sinus and sellar floor in endoscopic transsphenoidal surgery. *J Neurosurg*. 2011;114(5):1319-1330. [CrossRef]