Diagn Interv Radiol 2019; 25:480–484
© Turkish Society of Radiology 2019

MUSCULOSKELETAL IMAGING
PICTORIAL ESSAY

Calcific tendinitis: intramuscular and intraosseous migration

Cem Burak Kalaycı
Eşref Kızılkaya

ABSTRACT
Calcific tendinitis is a well-documented and extensively studied disease in the literature. Intramuscular and intraosseous migration are rare complications, which may present diagnostic challenges. This pictorial essay illustrates the imaging findings of these complications. Considering that neoplastic processes and infectious diseases are included in the differential diagnosis, recognizing the imaging findings of these complications is of critical importance.

Calcific tendinitis refers to the pathologic deposition of hydroxyapatite crystals in tendons, which may lead to a limited range of motion of the involved joint. Calcific tendinopathy and hydroxyapatite deposition disease are other names that are used to refer to this condition. The calcific deposits may lead to reactive inflammatory changes and may cause excruciating pain. If the deposits are large enough, they may cause the symptoms of impingement. This condition typically affects the rotator cuff tendons of the shoulder, but other sites of involvement are also documented, such as the hip, elbow, wrist, and knee (1).

Calcific deposits are not always symptomatic and can be the incidental findings of the imaging studies of any joint and of periarticular soft tissues (2). On the other hand, these deposits may be a significant source of joint pain (3) and account for 7% of shoulder pain (4).

This condition is characterized by the deposition of hydroxyapatite crystals that mostly affect the pre-insertional portions of the rotator cuff tendons, especially the supraspinatus tendon (5).

Pathogenesis

The pathogenesis of calcific tendinitis is not completely understood. It seems to be related to a cell-mediated response in which tenocytes undergo a metaplastic transformation into chondrocytes, ultimately resulting in calcium formation in the tendons (6). A decrease of intratendinous oxygen levels promotes fibrocartilaginous metaplasia and cellular necrosis, resulting in calcium deposition.

Uhthoff et al. (7) described calcific tendinitis in three stages: precalcific, calcific, and postcalcific. The precalcific stage represents the fibrocartilaginous transformation of tendon tissue. The calcific stage is the stage of calcium deposition in tendon tissue. This stage is further subdivided into formative and resorptive phases. The formative phase is characterized by the deposition of calcium crystals in tendon tissue. The resorptive phase begins with the vascular weaving of the affected area with subsequent macrophage phagocytosis of the calcium deposits (8). This phase is characterized by edema and increased tendinous pressure with the possible extravasation of calcium crystals in the subacromial-subdeltoid (SASD) bursa. The last stage, the postcalcific phase, includes the remodeling of the tendon via fibroblasts and granulation tissue, ultimately resulting in the complete healing of the involved tendon. This evolving process has distinct imaging findings that often correlate with the symptomatology of patients.

The latent period between the formative and resorptive phases is highly variable, and the resorptive phase is the phase that induces acute pain, leading to imaging studies.

From the Department of Diagnostic Radiology (C.B.K. ✉ *drburakkalayci@gmail.com, cem.kalayci@acibadem.com.tr*) Acıbadem University Atakent Hospital, İstanbul, Turkey.

Received 03 January 2019; revision requested 28 January 2019; last revision received 21 February 2019; accepted 10 March 2019.

Published online 23 August 2019.

DOI 10.5152/dir.2019.18593

You may cite this article as: Kalaycı CB, Kızılkaya E. Calcific tendinitis: intramuscular and intraosseous migration. Diagn Interv Radiol 2019; Diagn Interv Radiol 2019; 25:480–484.

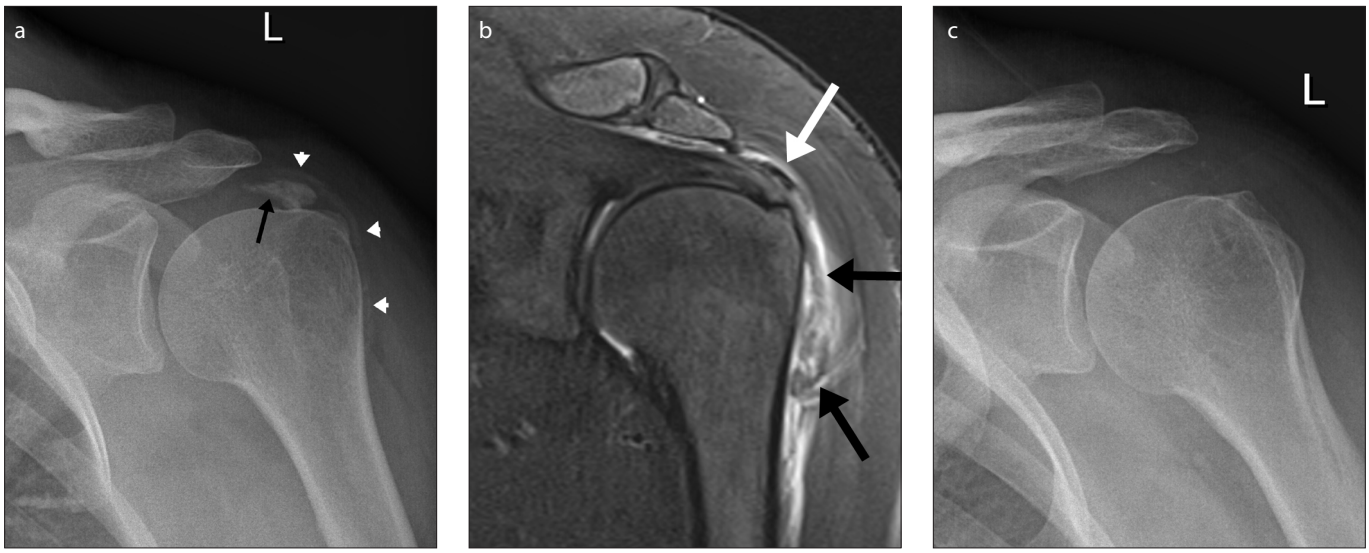

Figure 1. a–c. A 51-year-old female with acute onset left shoulder pain. An anteroposterior (AP) radiograph of the shoulder **(a)** shows calcification in the region of the supraspinatus tendon *(black arrow)*. Some of the calcification has drained into the subacromial-subdeltoid (SASD) bursa *(white arrowheads)*. Fat-saturated T2-weighted coronal image **(b)** depicts the calcium deposit in the supraspinatus tendon *(white arrow)*. The SASD bursa are filled with disseminated calcium deposits *(black arrows)*, which appear to be spontaneously drained, causing the acute onset of pain. Reactive bursitis is evident. Radiographs obtained 3 months after conservative treatment **(c)** show the resolution of the calcifications in the SASD bursa. The patient was asymptomatic at that time.

A rare complication of this relatively common entity is the migration of calcific deposits into adjacent tissues. Migration to SASD bursa can occur (Fig. 1). Adjacent bone (usually the humeral head where the rotator cuff tendons insert) and muscular structures are other sites of migration, and these are far less frequently encountered than other complications of calcific tendinopathy.

Intramuscular migration

Pereira et al. (5), in their retrospective study involving multiple hospitals over a 7-year time period, reported a series of 11 cases with intramuscular migration of calcium hydroxyapatite crystals that were located in the supraspinatus and infraspinatus tendons. Stable calcific deposits appear sharply defined, homogeneous and dense on X-ray examinations. On magnetic resonance imaging (MRI), the deposits are visualized as sharply defined hypointense areas on all pulse sequences. Intramuscular migration usually occurs in the resorptive phase of calcific tendinitis. Migrated calcific deposits increase in size. The migrated deposits are of a lower density than the stable portion of the calcific deposit that they migrated from, and their contours become ill-defined (9). On T1-weighted MRI, the migrated portion usually has a higher intensity than the main stable calcium bulk, and a small neck, which is often referred to as a "comet-tail" in the literature (10), can be identified in imaging studies, binding to the main bulk and the migrated portion (Fig. 2). Ultrasonography is another modality that can be used for the detection of calcific deposits and on which they appear as hyperechoic foci. Becciolini et al. (11) described four cases of intramuscular migration of calcium that were demonstrated by ultrasonography. The supraspinatus and infraspinatus muscles seem to be more commonly affected by the migration of calcium crystals. However, migrated calcium can also be seen in the subscapularis muscle (Fig. 3). The extensive reactive edema in the muscle adjacent to the calcific deposits may be confusing and raise concerns about infectious processes such as pyogenic myositis or of a denervation injury of the involved muscles. Another common differential diagnosis is traumatic injury to the rotator cuff tendons and accompanying muscular strain. In case of a partial-thickness tear, the retracted fibers may have a globular appearance, making the distinction much more difficult (12). MRI is suggested as the modality of choice to assess muscular involvement in calcific tendinopathy (5). However, as mentioned above, this modality may cause diagnostic confusion, and the presence of the calcium deposits needs to be confirmed using X-rays (Figs. 2, 3). Further imaging and possible interventions can be avoided by using plain X-rays as the first step of the diagnostic workup.

Main points

- Calcific tendinitis may affect any tendon in the body.
- The intraosseous and intramuscular migration of calcific tendinitis are rare complications that may lead to diagnostic difficulties.
- Recognizing the imaging characteristics of these complications can prevent further unnecessary investigation and interventional procedures.

Intraosseous migration

The mechanism of cortical erosion and the subsequent intraosseous migration of calcific deposits is not completely understood. Enzymatic actions may facilitate the lysis of the cortical bone and the subsequent dissemination of calcific deposits subcortically. Intraosseous migration can be classified as cortical erosion, subcortical calcium migration, and intramedullary diffusion (13).

Marinetti et al. (14) reported two cases with intraosseous migration of calcific tendinitis, providing MRI findings to aid the differential diagnosis and prevent unnecessary interventional procedures for diagnostic purposes. Intraosseous migration can also be documented using ultrasonogra-

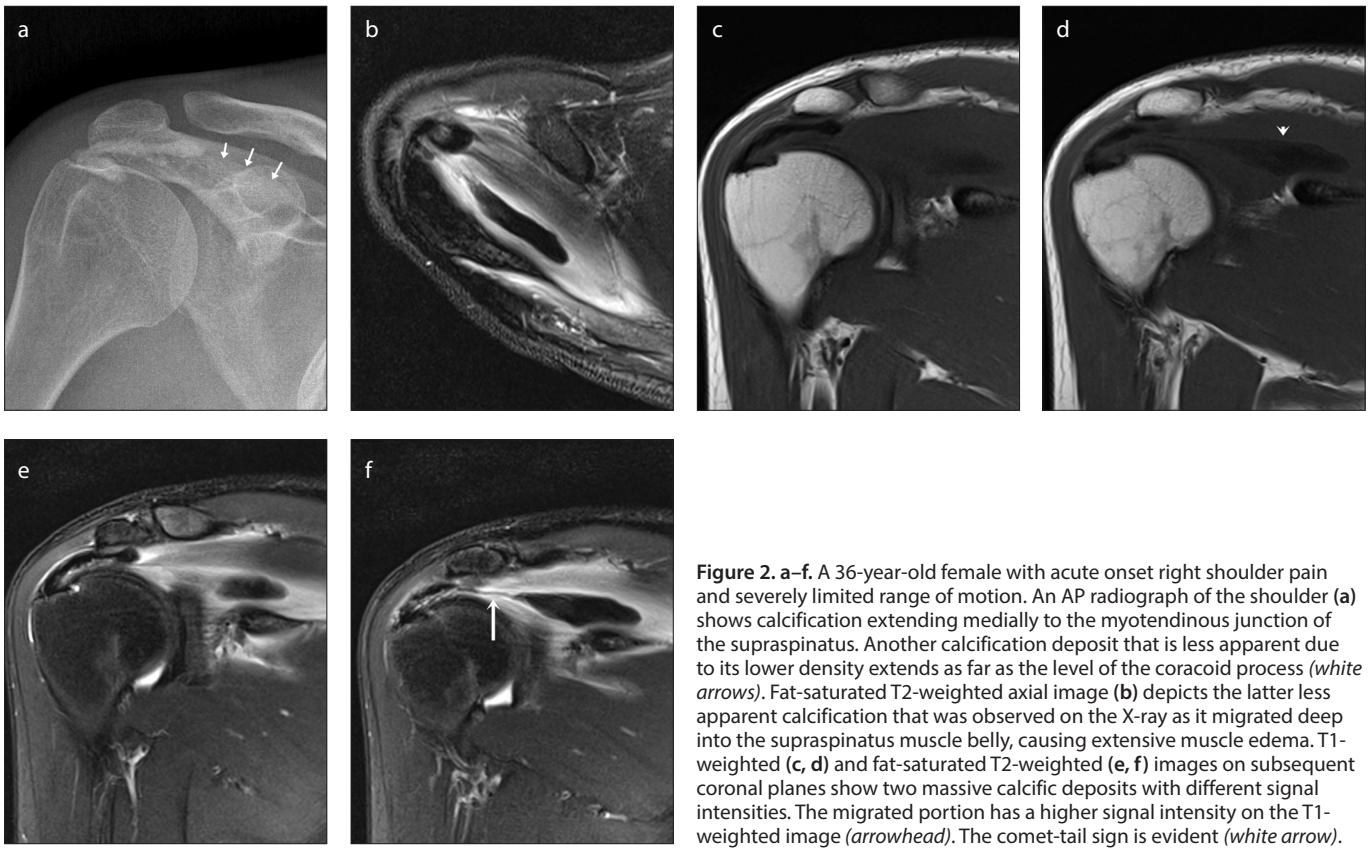

Figure 2. a–f. A 36-year-old female with acute onset right shoulder pain and severely limited range of motion. An AP radiograph of the shoulder **(a)** shows calcification extending medially to the myotendinous junction of the supraspinatus. Another calcification deposit that is less apparent due to its lower density extends as far as the level of the coracoid process *(white arrows)*. Fat-saturated T2-weighted axial image **(b)** depicts the latter less apparent calcification that was observed on the X-ray as it migrated deep into the supraspinatus muscle belly, causing extensive muscle edema. T1-weighted **(c, d)** and fat-saturated T2-weighted **(e, f)** images on subsequent coronal planes show two massive calcific deposits with different signal intensities. The migrated portion has a higher signal intensity on the T1-weighted image *(arrowhead)*. The comet-tail sign is evident *(white arrow)*.

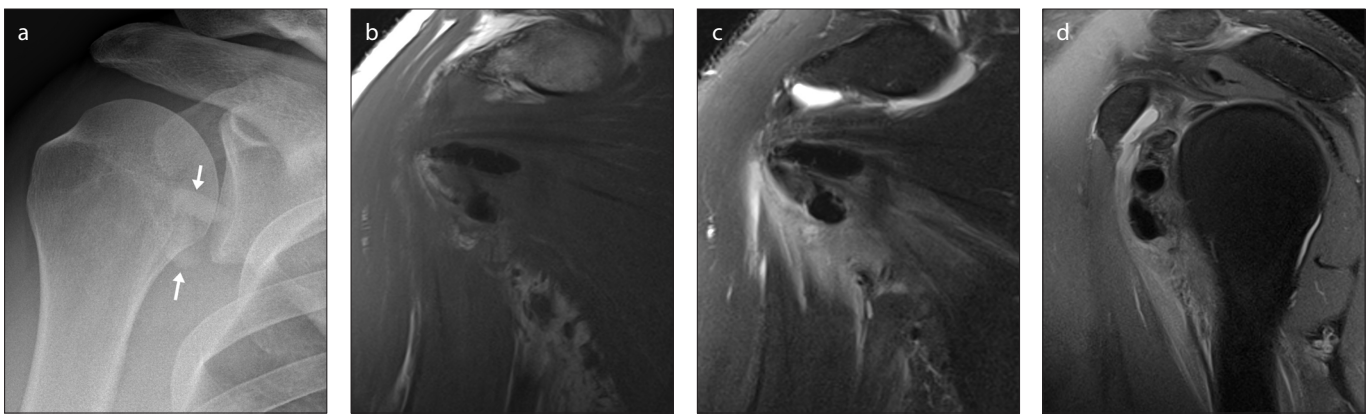

Figure 3. a–d. A 39-year-old male with acute onset right shoulder pain and limited range of motion. A plain X-ray **(a)** shows two large calcifications in the region of the subscapularis muscle *(white arrows)*. T1-weighted and T2-weighted fat-saturated coronal images **(b, c)** show the migration of calcium deposits medially along the subscapularis fibers. Muscle edema and accompanying subcoracoid bursitis are also evident on the sagittal T2-weighted fat-saturated image **(d)**.

phy, and local hyperemia can be detected in areas of cortical erosion using color Doppler imaging (15).

Calcific dissemination can cause extensive reactive medullary edema on MRI. This may lead to diagnostic challenges. Neoplastic processes (especially juxtacortical growths such as osteoid osteoma, chondroid lesions and periosteal osteosarcoma) and infectious processes, such as osteomyelitis, need to be ruled out. The lack of joint effusion and the absence of soft tissue mass with acute clinical presentation may help with the exclusion of such entities. Computed tomography scans are extremely efficient in demonstrating the migration of calcific deposits and should be used as a problem-solving tool in problematic cases (Figs. 4, 5). Follow-up examinations can take advantage of the self-limiting nature of calcific tendinitis and may show the complete resolution of imaging findings, excluding neoplastic processes.

Radiologists should be aware that calcific deposits can be seen in any tendon. The pectoralis major tendon insertion, flexor carpi ulnaris tendon distal attachment and flexor tendons of the fingers of the hand are common sites of involvement. The insertion of the gluteus maximus tendon on the gluteal tubercle of the femur is another common site of such deposits. Reactive

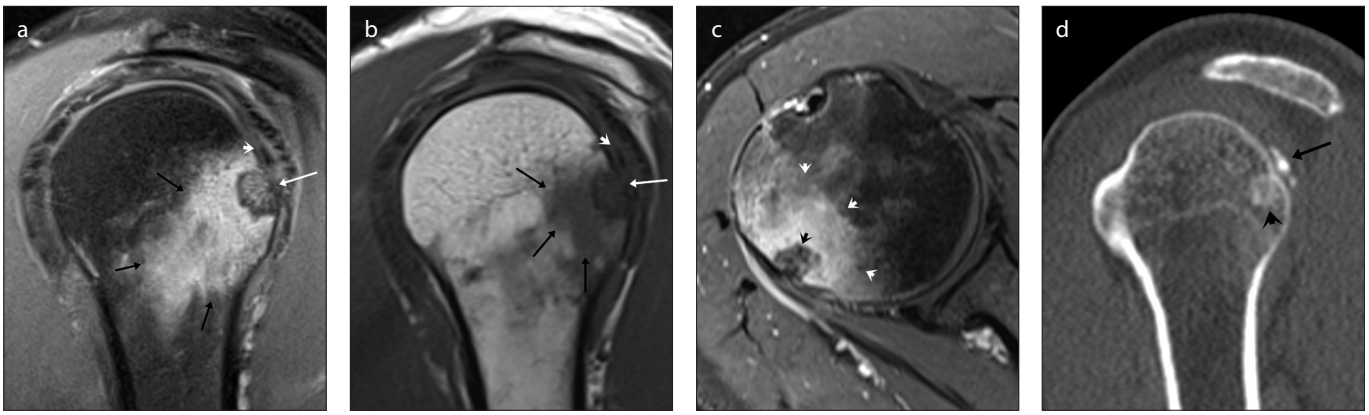

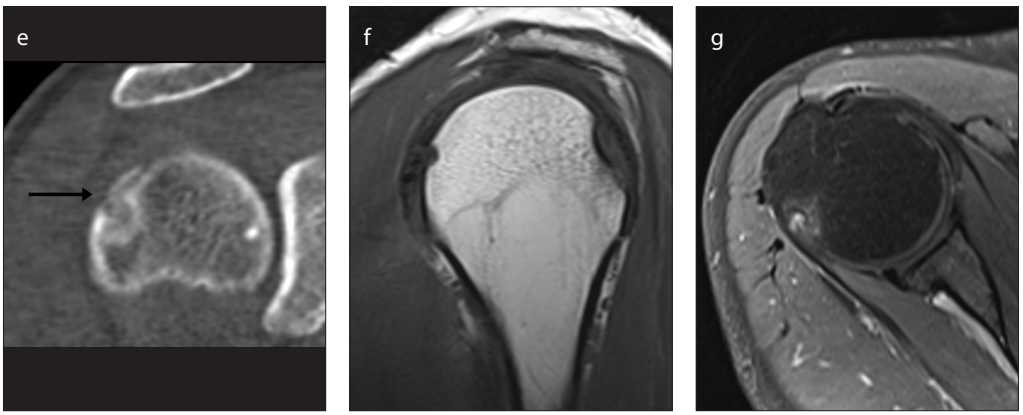

Figure 4. a–g. A 40-year-old female with acute exacerbation of chronic right shoulder pain. The shoulder X-ray was unremarkable (not shown). T2-weighted fat saturated and T1-weighted images at the same level on the sagittal plane **(a, b)** show a juxtacortical mass lesion *(white arrow)* with an accompanying bone marrow-edema-like signal *(black arrows)*. A subtle area of hypointensity on the infraspinatus tendon caused the suspicion of calcification *(white arrowhead)*. A postcontrast T1-weighted fat-saturated image on the axial plane **(c)** depicts extensive perilesional enhancement *(white arrowheads)*. The lesion itself appears to be nonenhancing *(black arrowhead)*. A sagittal reformatted CT image **(d)** shows calcification in the infraspinatus tendon *(black arrow)* and amorphous subcortical calcification *(black arrowhead)* in the posterior aspect of the humeral head, corresponding to the suspected juxtacortical mass lesion on magnetic resonance images. A coronal reformatted CT image **(e)** clearly depicts the intraosseous migration of calcific tendinitis *(black arrow)*. Follow-up sagittal T1-weighted and postcontrast T1-weighted fat-saturated axial images **(f, g)** at the same level as images **(b)** and **(c)** nearly 1 year later show complete resolution of the findings without specific treatment. The patient was free of symptoms.

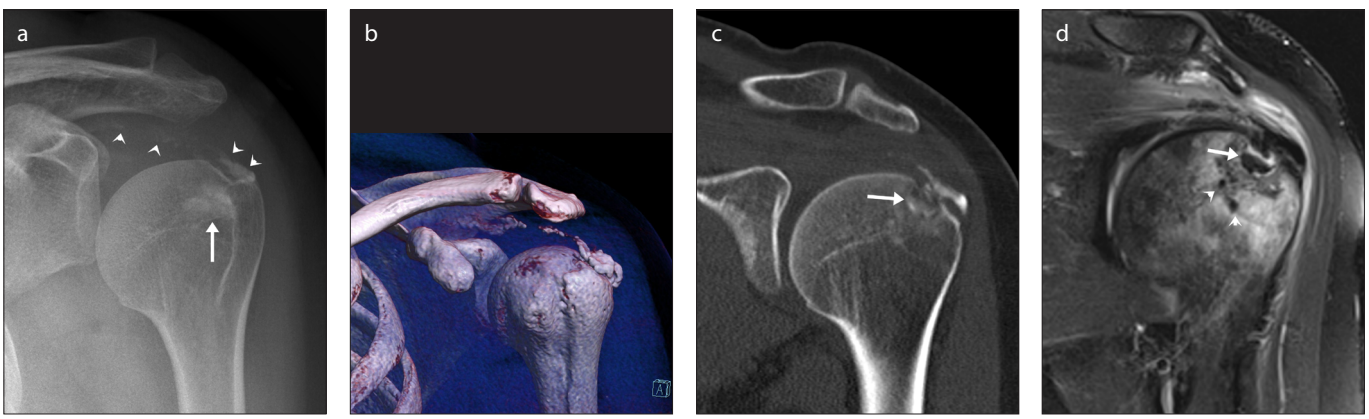

Figure 5. a–d. A 45-year-old female with shoulder pain. A plain X-ray **(a)** shows the presence of amorphous heterogeneous calcium deposits in the acromiohumeral space *(arrowheads)*, along with a sclerotic area of the humeral head *(arrow)*. 3D volume rendering image **(b)**, coronal reformatted CT image **(c),** and T2-weighted fat-saturated image **(d)** on the coronal plane depict massive calcific deposits extending from the myotendinous junction of both the supra- and infraspinatus muscles to their footprints on the humeral head. The cortical disruption of the humeral head and the subcortically located calcium milk is evident *(white arrow)*. Smaller, low signal areas in the epiphyseal region *(***d,** *white arrowheads)* indicate dissemination of the calcium deposits deep into the bone marrow, which shows intensive reactive edema.

edema in the adjacent thigh muscles may be quite exaggerated and cause the suspicion of myositis. In some cases, subcortical erosion caused by calcific migration may mimic a nidus of osteoid osteoma (Fig. 6). The specific site of the tendon insertion and the elongated calcium deposit along the tendon, rather than the reactive sclerotic osteoid formation seen in osteoid osteoma, can aid in making the correct diagnosis.

Conclusion

Calcific tendinitis is a common and well-documented disease in the literature. The intraosseous and intramuscular migra-

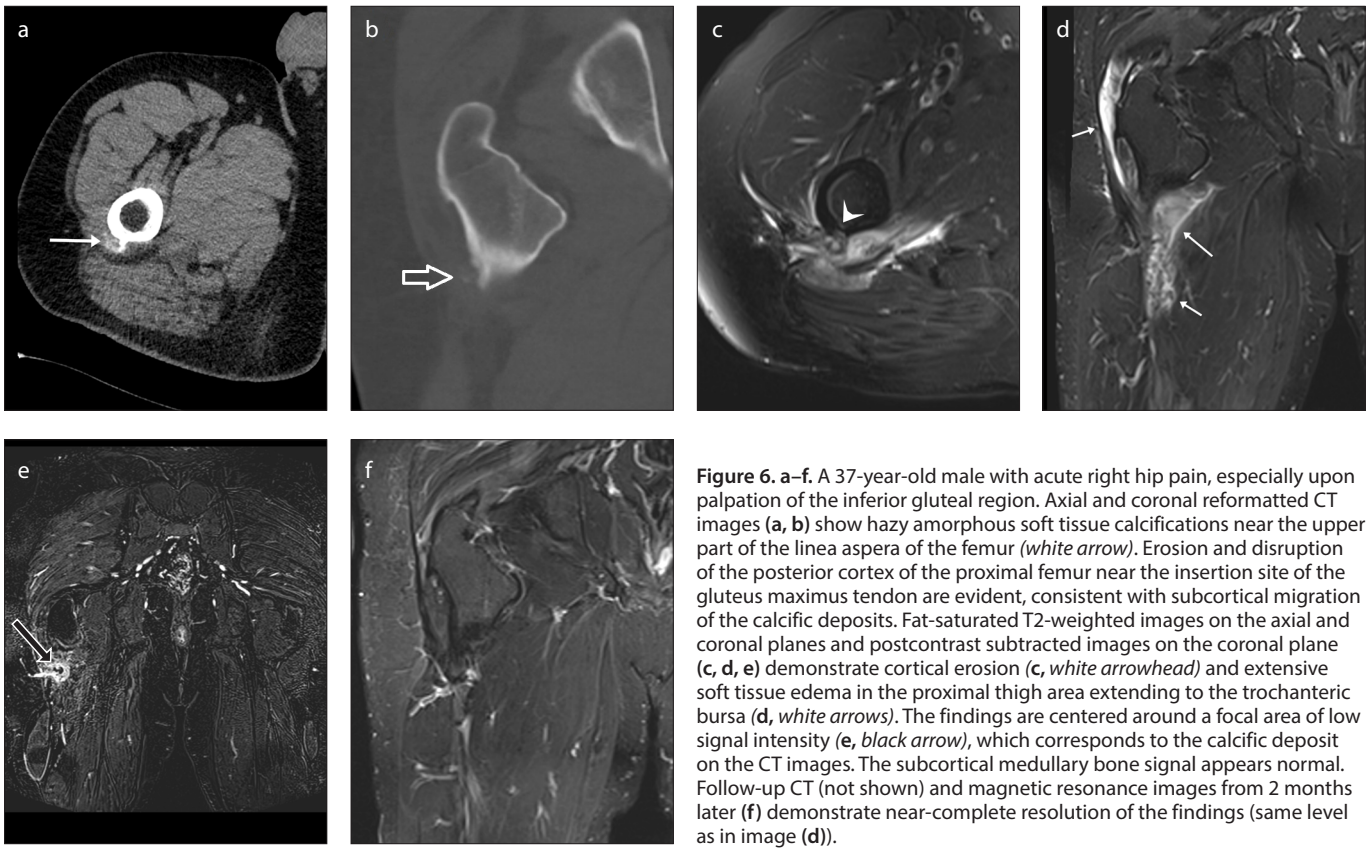

Figure 6. a–f. A 37-year-old male with acute right hip pain, especially upon palpation of the inferior gluteal region. Axial and coronal reformatted CT images **(a, b)** show hazy amorphous soft tissue calcifications near the upper part of the linea aspera of the femur *(white arrow)*. Erosion and disruption of the posterior cortex of the proximal femur near the insertion site of the gluteus maximus tendon are evident, consistent with subcortical migration of the calcific deposits. Fat-saturated T2-weighted images on the axial and coronal planes and postcontrast subtracted images on the coronal plane **(c, d, e)** demonstrate cortical erosion *(***c,** *white arrowhead)* and extensive soft tissue edema in the proximal thigh area extending to the trochanteric bursa *(***d,** *white arrows)*. The findings are centered around a focal area of low signal intensity *(***e,** *black arrow)*, which corresponds to the calcific deposit on the CT images. The subcortical medullary bone signal appears normal. Follow-up CT (not shown) and magnetic resonance images from 2 months later **(f)** demonstrate near-complete resolution of the findings (same level as in image **(d)**).

tion of calcific tendinitis are rare complications and may cause diagnostic challenges. Recognizing the imaging characteristics of these complications can prevent further unnecessary investigation and even interventional procedures.

Conflict of interest disclosure

The authors declared no conflicts of interest.

References

1. Hayes CW, Conway WF. Calcium hydroxyapatite deposition disease. Radiographics 1990; 10:1031–1048. [CrossRef]
2. Hayes CW, Rosenthal DI, Plata MJ, Hudson TM. Calcific tendinitis in unusual sites associated with cortical bone erosion. AJR Am J Roentgenol 1987; 149:967–970. [CrossRef]
3. Bosworth B. Calcium deposits in the shoulder and subacromial bursitis: a survey of 12,122 shoulders. JAMA 1941; 116:2477e81. [CrossRef]
4. Speed CA, Hazleman BL. Calcific tendinitis of the shoulder. N Engl J Med 1999; 340:1582e4. [CrossRef]
5. Pereira Bruno PG, Chang EY, Resnick DL, Pathria MN. Intramuscular migration of calcium hydroxyapatite crystal deposits involving the rotator cuff tendons of the shoulder: report of 11 patients. Skelet Radiol 2016; 45:97–103. [CrossRef]
6. De Carli A, Pulcinelli F, Rose GD, Pitino D, Ferretti A. Calcific tendinitis of the shoulder. Joints 2014; 2:130–136. [CrossRef]
7. Uhthoff HK, Sarkar K. Calcifying tendinitis. Baillieres Clin Rheumatol 1989; 3:567–581. [CrossRef]
8. Greis AC, Derrington SM, McAuliffe M. Evaluation and nonsurgical management of rotator cuff calcific tendinopathy. Orthop Clin North Am 2015; 46:293–302. [CrossRef]
9. Cho NS, Lee BG, Rhee YG. Radiologic course of the calcific deposits in calcific tendinitis of the shoulder: does the initial radiologic aspect affect the final results? J Shoulder Elb Surg 2010; 19:267–272. [CrossRef]
10. Newberg AH. Soft tissue calcification and ossification. Imaging Arthritis Metab Bone Dis 2009; 39:681–696. [CrossRef]
11. Becciolini M, Bonacchi G, Galletti S. Intramuscular migration of calcific tendinopathy in the rotator cuff: ultrasound appearance and a review of the literature. J Ultrasound 2016; 19:175–181. [CrossRef]
12. Taneja AK, Kattapuram SV, Chang CY, Simeone FJ, Bredella MA, Torriani M. MRI findings of rotator cuff myotendinous junction injury. AJR Am J Roentgenol 2014; 203:406. [CrossRef]
13. Malghem J, Omoumi P, Lecouvet F, Vande BB. Intraosseous migration of tendinous calcifications: cortical erosions, subcortical migration and extensive intramedullary diffusion: a SIMS series. Skelet Radiol 2015; 44:1403–1412. [CrossRef]
14. Marinetti A, Sessa M, Falzone A, Della Sala S.W. Intraosseous migration of tendinous calcifications: two case reports. Skelet Radiol 2018; 47:131–136. [CrossRef]
15. Bianchi S, Becciolini M. Ultrasound appearance of the migration of tendon calcifications. J Ultrasound Med 2019; 9999:1–14. [CrossRef]