Cukurova Medical Journal

Olgu Sunumu / Case Report

Cerebellar Hemangioblastoma: Four Case Reports and Review of the Literature

Serebellar Hemangioblastoma: Dört Olgu Sunumu ve Literatür Incelemesi

Sevgi Bakariş[1], Mürüvet Yüksel[2]

[1]Kahramanmaras Sütçüimam University, School of Medicine Department of Pathology, [2]Department of Radiology, KAHRAMANMARAŞ

Cukurova Medical Journal 2015;40(1):184-192.

ABSTRACT

Hemangioblastoma (HB) is a benign, slow-growing, highly vascular tumour of not well defined histological origin. These tumors make up about 1 to 2 percent of all intracranial neoplasms and occur primarily in the posterior fossa. Hemangioblastomas can occur sporadically but in about 20% to 30% cases, it is associated with von Hippel-Lindau (VHL) disease. Four cases of cerebellar haemangioblastoma, not associated with von Hippel-Lindau disease (sporadic haemangioblastomas), were presented and reviewed the relevant literature.Four hemangioblastomas of the central nervous system were examined with haematoxylin & eosin (H&E), reticulin stain and with a panel of antibodies including CD34, vimentin, NSE, S-100, CD99, CD56, GFAP, cytoceratin, epithelial membrane antigen (EMA), CD10. Of the 4 patients in this study 1 was male and 3 were female. Their ages ranged from 46 years to 60 years with a mean age of 54.75 years. All of them were as cystic nodules about 2-3 cm in diameter. In the histopathological examination, the tumors sections showed large and vacuolated stromal cells and numerous arborizing capillary-size blood vessels. Some tumors showed atypical nuclei. Vimentin was strongly positive both stromal cells and blood veessels in all tumors. In 4 cases of HB, some stromal cells were positive for NSE and CD99. Three tumors were positive for S-100 and CD56, two tumors were focally positive for glial fibrillary acidic protein (GFAP). CD34 immunostaining highlighted the arborizing and complex vascular network, whereas the tumor stromal cells were negative. The stromal cells were negative for epithelial markers such as cytokeratin, EMA and CD10. Ki-67 index was less than 1% of the tumor cells. Hemangioblastoma, a rare, benign tumors of uncertain histogenesis, is characterized histologically by the presence of vacuolated, lipid containing cells and a well developed, fine capillary network. The main histological differential diagnosis of HB is metastatic clear cell carcinoma. Additionally, because of the cystic mural features, pilocytic astrocytomas of the cerebellum must be separated from haemangioblastomas.

Key words: hemangioblastoma, von Hippel-Lindau, cantral nervous system, histopathology

ÖZET

Hemanjiyoblastoma; histolojik kökeni henüz tam olarak tanımlanmamış, iyi huylu, yavaş büyüyen ve oldukça damarsal bir tümördür. Bu tümörler tüm kafatası içi neoplazmaların %1-2'sini oluşturur ki genellikle posterior fossada meydana gelirler. Hemanjiyoblastomalar normalde belirli aralıklarla düzensiz şekillerde meydana gelmektedirler ancak bu oran von hippel-lindau (VHL)'li vakaların yaklaşık %20-30'unda gözlenmektedirler. Burada Von Hippel-Lindau ile ilişkili olmayan dört serebellar hemanjiyoblastoma vakasının sunumu ve ilgili literatürün derlemesi yapıldı. Merkezi sinir sisteminde yer alan 4 hemanjiyoblastoma vakası hematoksilin-eosin, retikülin boya ve CD34, vimentin, NSE, S-100, CD99, CD56, GFAP, sitokeratin, epitelyal membran antijeni (EMA) ve CD10 antibiyotiklerini içeren bir panel ile incelemeleri yapıldı. Üç kadın bir erkek toplam 4 hastanın yaş ortalaması 54.75 (46 -60) idi. Hastalarda 2-3 cm çapında sistik nodüller vardı. Histopatolojik incelemeler sonucunda tümör kesitleri bizlere, büyük ve vaküollenmiş stromal

hücreleri ve çok sayıda dallanma gösteren ve bir kıl kadar ince kan damarları olduğunu gösterdi. Tümörlerin bazıları atipikal çekirdek oluşumunu ortaya çıkardı. Vimentin tümörlerin hem stromal hücrelerinde hem de kan damarlarında yüksek seviyelerde pozitiflik gösterdi. Dört HB vakasında bazı stromal hücreler NSE ve CD99 için pozitifdi. Üç tümör S-100 ve CD56 için pozitifti. İki tümör odaksal olarak glial fibriler asidik protein (GFAP) için pozitifti. Tümör stromal hücrelerinin negatif olmalarının aksin CD34 immün boyama, dallanan ve kompleks vasküler bağlantının varlığını gösterdi. Stromal hücreler sitokeratin, EMA ve CD10 gibi epitelyal işaretçiler için negatifti. Ki-67 indeksi tümör hücrelerinin %1'inden daha azdı. Nadir, histogenezisi tam olarak belli olmayan, iyi huylu tümör olan hemanjiyoblastoma; vakuollenmiş, lipid içeren hücreler ve iyi gelişmiş kapiller bağlantıların varlığı ile karakterize edilmektedir. HB'nin temel histolojik olarak ayrımlı teşhisi; metastatik açık hücre karsinomasıdır. İlaveten, sistik mural özelliklerinden dolayı serebellumun pilositik astrositomları hemanjiyoblastomlardan ayrılması gerekmektedir.
Anahtar kelimeler: Hemanjiyoblastoma, histopatoloji, merkezi sinir sistemi, von Hippel-Lindau.

INTRODUCTON

In 1928, the term hemangioblastoma was originally suggested by Cushing and Bailey to describe these tumors, which were thought to arise from "vasoformative" cells (endothelial cells) of the central nervous system (CNS)[1]. In 1931, Swedish pathologist Arvid Vilhelm Lindau based distinctness of CNS haemangioblastomas on a series of criteria including 'unmistakable neoplasticity' with 'composition of blood vessel elements' and a 'tendency towards cyst formation[2]. Lindau's tumor specifically refers to the HB of the cerebellum and von Hippel's tumor to hemangioblastoma of the retina. Lindau' s disease, or von Hippel-Lindau's (VHL) complex, designates a more diffuse inherited disorder characterized by multiple hemangioblastomas in the CNS associated with certain visceral manifestations such as retinal angiomas, renal cell carcinoma, pheochromocytomas, serous cystadenomas and neuroendocrine tumors of the pancreas[3].

HBs are rare tumors of central nervous system, and constitute 1.5-2.5 % of all brain tumors and 7-12 % of all infratentorial tumors in adults[4]. They may occur sporadically as isolated tumors of the cerebellum or in about 20% to 30% cases it may represent a familial disorder as part of the VHL complex[5-7]. Patients with sporadic HBs typically seek treatment at age 40–50, whereas patients with VHL disease-related HBs seek treatment in their 20s or 30s. Haemangioblastomas are more common in males than in females (1.3:1 ratio)[8].

Haemangioblastoma of CNS is a benign, slow-growing, solid or cystic, highly vascular tumour of not well defined histological origin. Hemangioblastomas are grade I benign tumours which have been classified under the category of meningeal tumors in the fourth edition of WHO classification of CNS tumors, 2007 with an uncertain origin[9].

Four cases of cerebellar haemangioblastoma, not associated with von Hippel-Lindau disease (sporadic haemangioblastomas), were presented and reviewed the relevant literature.

CASES

In this article, 4 cases of capillary hemangioblastoma diagnosed in our department of pathology are presented and the histopathological and the clinical features are discussed.

Of the 4 patients in this study 1 was male and 3 were female. Their ages ranged from 46 years to 60 years with a mean age of 54.76 years. All tumors were located on cerebellar hemisphere. Von Hippel-Lindau clinical screening was negative.

Grossly, hemangioblastomas are usually well circumscribed mural nodules within a large, fluid filled cyst. These tumours may be solid or cystic or have both solid and cystic areas. On CT and MRI, the hemangioblastoma most commonly appears as a solid 'mural nodüle' within a well-circumscribed thin-walled cyst as in our case (Figure1). Following the administration of intravenous contrast the mural nodule will enhance homogeneously The cyst wall generally does not enhance[10].

Four hemangioblastomas of the central nervous system were examined with haematoxylin & eosin (H&E), reticulin stain and with a panel of antibodies including CD34, vimentin, NSE, CD99, CD56, S-100, GFAP, cytoceratin, EMA, CD10.

Histopathologically, the neoplastic growth of haemangioblastoma is basically highly cellular, vascularized and composed of haphazardly oriented small capillaries and sinusoidal channels lined by plump endothelial cells separated by larger pleomorphic stromal cells. The stromal cells have round to elongated hypercromaticl nuclei with inconspicuous nucleoli and pale-clear cytoplasm due to the presence of intracytoplasmic vacuoles. Some stromal cells nuclei were pleomorphic No mitotic rate or necrosis was identified. These cells were accompanied by a rich vascular network of capillary type and blood extravasation (Fig.2A,B,C). Numerous thin walled vessels are apparent and are readily outlined by a reticulin stain. All tumours had a prominent reticulo-vascular network (Fig.2D) The neoplastic growth of haemangioblastoma were usually separated from the adjacent brain tissue by a rim of gliosis.

Immunohistochemical analysis revealed that the tumor stromal cells labeled for vimentin (Figure 3A), S-100 protein (Figure 3B) neuron-specific enolase (Fig.3C), CD 56 (Fig 3D), CD99 (Fig. 3E), and GFAP.(Fig. F) but they were negative for CD34. EMA, CD10. Vimentin was strongly positive both stromal cells and blood veessels in all tumors. In 4 cases of HB, some stromal cells were positive for CD99 and NSE. Three tumors were focally positive for S-100 and CD56, two tumors were focally positive for glial fibrillary acidic protein (GFAP) because of included or reactive astrocytes as well as positive stromal cells. CD34 immunostaining highlighted the arborizing and complex vascular network, whereas the tumor stromal cells were negative. Ki-67 index was less than 1% of the tumor cells.

Given the above findings, we identified the tumor as an capillary hemangioblastoma (World Health Organization grade I).

In our cases, hematoxylen-eosin stained sections were sufficient for the diagnosis The histochemical and the immunohistochemical stains (vimentin, NSE, S- 100, CD31, GFAP, keratin, CD-68, VEGF ,reticulin stains) were applied to support the diagnosis and the staining patterns were found to be consistent with the related publications.

Stromal cells showed a variable immunoreactivity for neuroectodermal markers, such as S-100 protein, CD56, CD99, and neuron-specific enolase. This result, in conjunction with the absence of immunoreactivity for epithelial, mesenchymal, and endothelial markers, indicates that the stromal cells of hemangioblastoma might originate from primitive neuroectodermal cells,

The stromal cells are negative for epithelial markers such as CD10 and EMA. The study using a combination of immunohistochemical markers (e.g. CD10, EMA) was useful for differential diagnosis of hemangioblastoma from metastatic renal cell carcinoma.

DISCUSSION

Hemangioblastoma (HB) is an infrequent, benign (WHO grade I), slowly growing, highly vascular, solid or cystic neoplasm of not well defined histological origin[4,5-9]. The solid component, so called the mural nodule shows contrast enhancement on CT and prominent vascular features on angiography[10].

Hemangioblastomas on gross examination in-situ are usually cherry red in color. They may include a cyst that contains a clear or xanthochromic fluid, and solid tumors are as common as cystic ones. Posterior fossa tumours are often cystic (70%). The cyst walls are non-neoplastic. They are usually well-demarcated lesions but without true capsules. There was some invasion into brain parenchyma by the tumor in the subarachnoid space but most of the larger nodules were well circumscribed with compression of the surrounding brain parenchyma. The symptoms are associated with the progressively growing cystic component of the tumor.

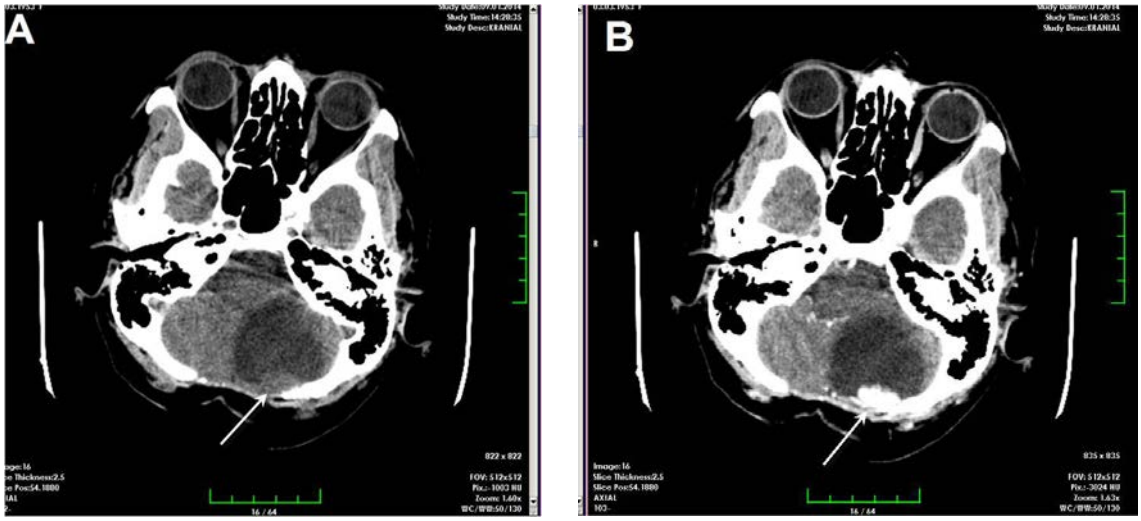

Figure 1 A,B

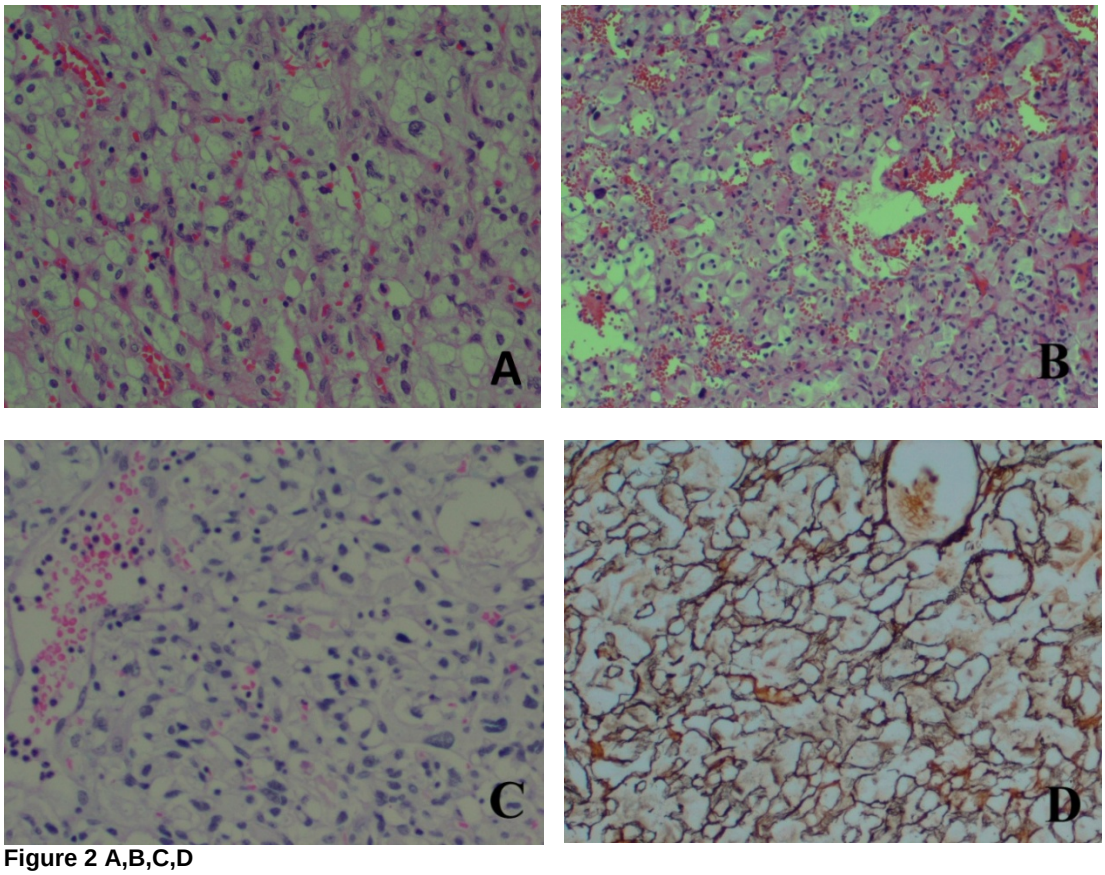

Figure 2 A,B,C,D

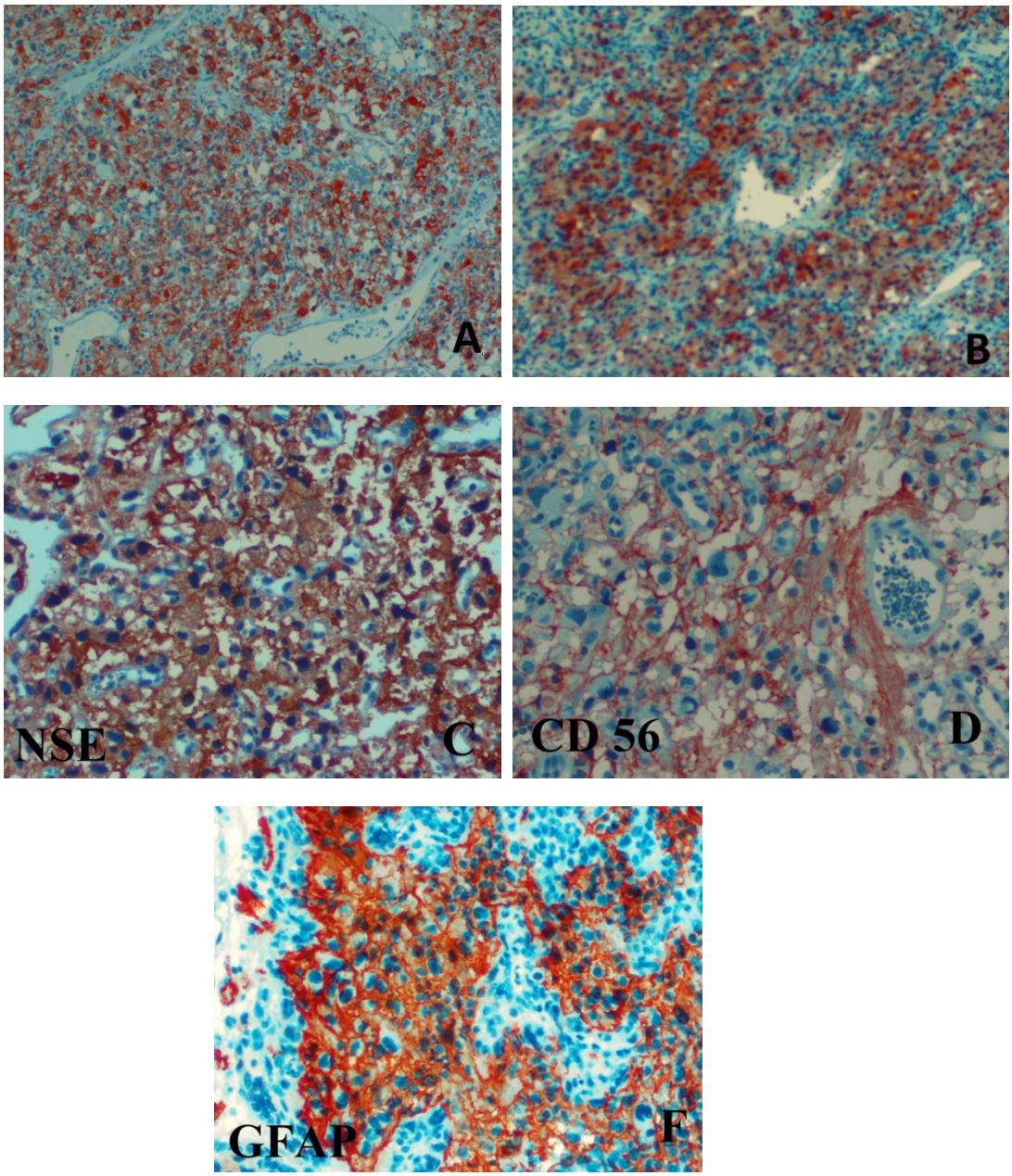

Figure 3.A,B,C,D,F

The most common clinical symptom of cerebellar HB is headache or nausea, associated with elevated intracranial pressure (ICP) or cerebellar ataxia. In our all the four patients had features of raised incracranial pressure at presentation[11,12]. In particular, solid lesions remain stable in size and therefore asymptomatic for many years. In some cases, as a result of the erythropoetin secretion from the vascular endothelial cells of the tumor, polycythemia becomes apparent[13].

The cellular component of haemangioblastoma is composed of four cell types: endothelial cells lining capillary spaces; pericytes surrounded by basement membrane; stromal cells, or multivacoulated cells; and mast

cells. The endothelial cells, pericytes and mast cells are non-neoplastic. The stromal cells (also known as Zwischenzellen cells) are the real tumor components of HBs although they represent a heterogeneity. They have round to pleomorfic or lobule nuclei with inconspicuous nucleoli and pale vacuolated clear cytoplasm (lipid-laden cytoplasm) The vascular spaces are variable sized, closely packed, and thin walled (capillary or sinusoidal). The tumour is also rich in reticulin that separates the vascular cells from the stromal cells. The network of reticulin fibres usually are surround groups of stromal cells and support the vascular architecture as in our cases[14,15]. The relation between the cellular component and the reticulovascular network allowed the separation of the tumours into two groups: a reticular variant, where stromal cells are evenly distributed among the capillary meshwork; and a cellular variant in which stromal cells are arranged in larger nests or sheets[16].

The histogenesis of haemangioblastoma is debatable Tissue microdissection, combined with deletion analysis of the VHL gene locus, have identified the stromal and not the vascular cells as neoplastic[17,18].

Although many investigations including ultrastructural and immunohistologic studies have been published on the histogenetic origin of this tumor, its origin has not been satisfactorily clarified. The suggested origin of tumor stromal cells includes glial, endothelial, arachnoid, neuroendocrine, fibrohistiocytic, and neuroectodermal cells. Recent studies have also postulated that an embryonic progenitor cell with hemangioblastic differentiation may be a cytologic equivalent of tumor stromal cells[19].

Several electron microscopic studies have demonstrated the vascular origin of these cells[14,20] which is supported by the presence of Weibel-Palade bodies[21].

Stromal cells lack endothelial cell markers, such as von Willebrand factor and CD34, and do not express endothelium-associated adhesion molecules such as CD31 (PECAM)[22,23] stromal cells variably express neuron-specific enolase, neural cell adhesion molecule, S-100, CD56 and ezrin[24,22,25]. In our cases CD34 was expressed in endothelial cells. Immunohistochemical stains (vimentin, NSE, S-100, CD99, CD56) were found to be consistent with the related publication. We demonstrated cytoplasmic NSE immunoreactivity in the stromal cells of all 4 examined hemangioblastomas Vimentin strongly reacted with both stromal and endothelial cells

Böhling et al[26] has been found that the stromal cells express abundant epidermal growth factor receptor (EGFR) and some platelet-derived growth factor receptor-alpha (PDGF-alpha).

The presence of GFAP-positive stromal cells was reasoned by Becker and his colleagues to the following possibilities: (i) GFAP positive cells are not neoplastic but lipidized or altered reactive astrocytes; (ii) haemangioblastomas are mixed and partly composed of neoplastic astrocytes, and (iii) stromal cells can engulf extracellular GFAP protein derived from the adjacent reactive astrocytes[27]. Kepes et al. (1979)[28] suggested that GFAP-positive stromal cells may be lipidized astrocytes. On the other hand Deck and Rubinstein (1981)[16] proposed that stromal cells may take up GFAP released from reactive astrocytes.

In our cases, two tumors were focally positive for GFAP, we observed were in areas with degenerative changes as well as positive stromal cells, or reactive astrocytes.

Also positive staining for some lysosome markers (alpha-1-antitrypsin, alpha-1-antichymotrypsin and CD68) are occasionally observed in stromal cells raising the possibility of fibrohistiocytic differentiation of these cells[29,30].

This has resulted in the current WHO classification of hemangioblastomas as a ‘‘neoplasm of uncertain histogenesis’’ although World Health Organization classified it as a class of neoplasms related to the meninges in 2007[9].

Differential diagnostic problems may arise with respect to some primary CNS tumours[31] and

of secondary tumours such as metastatic renal cell carcinoma[32,33]. Because of the distinct components, such as prominent vessels and peripheral vacuolated cells around the vessels, HB must be renal cell carcinoma, In our patient, lack of immunoreactivity for EMA, CD10, along with a negligibly low proliferation index allowed for this alternative to be confidently ruled out. In addition, the lesions that should be considered in the differential diagnosis of capillary haemangioblastoma haemangiopericytomas, cystic astrocytomas and arachnoid cysts (if mural nodule too small to be seen on CT scan.), paraganglioma and so on. Macroscopic cysts are quiet frequent in low-grade pilocytic astrocytomas of the cerebellum. Therefore, these lesions must be separated from haemangioblastomas. Unlike haemangioblastomas, examination of the mural nodule of pilocytic astrocytomas reveals glial cell hypercellularity (neoplastic astrocytes); rosenthal fibres and microcysts. The lesions were reported in several different sites, such as the breast[34], skin[35], retroperitoneum[36], peripheral nerves[37] and liver[38].

HB is thought to be a benign tumor curable by microsurgery; however, several previous studies have reported that the recurrence rate after surgical excision is 15-27%[39]. Tumor recurrence is to some extent associated with incomplete surgical excision. Risk factors for recurrence are; diagnosis at < 30 years old; diagnosis of VHLD; presence of multi-centric tumors of the central nervous system at initial diagnosis; and lower frequencies of histopathological cyst formation and lower proportion of lipid – laden stromal cells[40]. Recently, a histological subtype was also found to correlate positively with a probability of haemangioblastoma recurrence, with a 25% recurrence rate in cellular subtype and an 8% recurrence rate in reticular subtype[41].

Because new lesions may develop during the patient's lifetime. so that, regular clinical inspection is recommended in order to check up the development of any new lesions.

REFERENCES

1. Cushing H, Bailey P. Tumors arising from the blood vessels of the brain: angiomatous malformations and hemangioblastomas. Springfield: Charles C Thomas, 1928:105-9.
2. Lindau A. Discussion on vascular tumors of the brain and spinal cord. Proc R Soc Med. 1931;24:363–70.
3. Richard S, Martin S, David P. Von Hippel-Lindau disease and centralnervous system hemangioblastoma. Neurochir. 1998;44:258-66.
4. Resche F, Moisan JP, Mantoura J, de Kersaint-Gilly A, Andre MJ, Perrin-Resche I, et al. Haemangioblastoma, haemangioblastomatosis, and von Hippel-Lindau disease. Advances and technical standards in neurosurgery. 1993;20:197-304. Epub 1993/01/01.
5. Neumann HP, Eggert HR, Weigel K, Friedburg H, Wiestler OD, Schollmeyer P: Hemangioblastomas of the central nervous system. A 10- year study with special reference to von Hippel-Lindau syndrome. J Neurosurg. 1989,70:24-30.
6. Conway JE, Chou D, Clatterbuck RE, Brem H, Long DM, Rigamonti D: Hemangioblastomas of the central nervous system in von Hippel-Lindau syndrome and sporadic disease. Neurosurgery. 2001;48:55-63.
7. Wanebo JE, Lonser RR, Glenn GM, Oldfield EH: The natural history of hemangioblastomas of the central nervous system in patients with von Hippel-Lindau disease. J Neurosurg. 2003;98:82-94
8. Vater GE. Hemangioblastoma. In: Neuro-oncology. edn. Philadelphia PA: Elsevier Saunders. 2005:294-300.
9. WHO Classification of Tumours of the Central Nervous System. 4 ed. Lyon: International Agency for Research on Cancer. 2007:309.
10. Ho VB1, Smirniotopoulos JG, Murphy FM, Rushing EJ Radiologic-pathologic correlation: hemangioblastoma. Am J Neuroradiol. 1992;13:1343-52
11. Constans JP, Meder F, Maiuri F, Donzelli R, Spaziante R, de Divitiis E. Posterior fossa hemangioblastomas. Surg Neurol. 1986;25:269-75.
12. Jagannathan J, Lonser RR, Smith R, DeVroom HL, Oldfield EH. Surgical management of cerebellar

hemangioblastomas in patients with von Hippel-Lindau disease. Journal of neurosurgery. 2008;108:210-22.

13. Bohling T, Haltia M, Rosenlof K, Fyhrquist F: Erythropoietin in capillary hemangioblastomas. Acta Neuropathol (Berl) 1987;74:324-32

14. Kawamura J., Garcia J.H., Kamijyo Y. Cerebellar hemangioblastoma: histogenesis of stroma cells. Cancer. 1973;31:1528–40.

15. Del Basso De Caro M., De Stefano V., Bucciero A. et al. [Solitary capillary hemangioblastoma, cellular variant. Clinical, radiological, and anatomo-pathological study of 2 cases]. Pathologica. 1995;8:518–21.

16. Deck H.N. and Rubinstein L.J. Glial Fibrillary Acidic Protein in Stromal cells of some capillary hemangioblastomas: significance and possible implications of an immunoperoxidase study. Acta Neuropathol. (Berl.) 1981;54:173-81.

17. Lee JY, Dong SM, Park WS, Yoo NJ, Kim CS, Jang JJ, et al. Loss of heterozygosity and somatic mutations of the VHL tumor suppressor gene in sporadic cerebellar hemangioblastomas. Cancer research. 1998;58:504-8.

18. Vortmeyer AO, Gnarra JR, Emmert-Buck MR, Katz D, Linehan WM, Oldfield EH, et al. von Hippel-Lindau gene deletion detected in the stromal cell component of a cerebellar hemangioblastoma associated with von Hippel-Lindau disease. Human pathology. 1997;28:540-43.

19. Plate KH, Vortmeyer AO, Zagzag D, et al. Von Hippel-Lindau disease and haemangioblastoma. In: Louis DN, Ohgaki H, Wiestler OD, Cavenee WK, eds. WHO Classification of Tumours of the Central Nervous System. 4th ed. Lyon: IARC. 2007:215-7.

20. Chaudhry A.O., Montes M. and Cohn G.A. . Ultrastructure of cerebellar hemangioblastoma. Cancer 1978;42:1834-50.

21. Ho K.L. Ultrastructure of cerebellar capillary haemangioblastoma. 1. Weibel-palade bodies and stromal cell histogenesis. J. Neuropathol. Exp. Neurol. 1984;43:592-608.

22. Bohling T, Maenpaa A, Timonen T, Vantunen L, Paetau A, Haltia M. Different expression of adhesion molecules on stromal cells and endothelial cells of capillary hemangioblastoma. Acta neuropathologica. 1996;92:461-6.

23. Wizigmann-Voos S, Plate KH. Pathology, genetics and cell biology of hemangioblastomas. Histology and histopathology. 1996;11:1049-61.

24. Ishizawa K, Komori T, Hirose T. Stromal cells in hemangioblastoma: neuroectodermal differentiation and morphological similarities to ependymoma. Pathology international. 2005;55:377-85.

25. Bohling T, Turunen O, Jaaskelainen J, Carpen O, Sainio M, Wahlstrom T, et al. Ezrin expression in stromal cells of capillary hemangioblastoma. An immunohistochemical survey of brain tumors. The American journal of pathology. 1996;148:367-73.

26. Böhling T, Hatva E, Kujala M. Expression of growth factors and growth factor receptors in capillary hemangioblastoma. J Neuropathol Exp Neurol 1996;55:522-7.

27. Becker I., Paulus W., Roggendorf W. (1989) Histogenesis of stromal cells in cerebellar hemangioblastomas. An immunohistochemica study. Am. J. Pathol. 1989;134:271–5.

28. Kepes J., Rengachary S.S. and Lee S.H. (1979). Astrocytes in hemangioblastomas of the central nervous system and their relationship with stromal cells. Acta Neuropathol. (Berl.) 1979;47:99-104.

29. Grossniklaus H.E., Thomas J.W., Vigneswaran N., Jarrett W.H., III Retinal hemangioblastoma. A histologic, immunohistochemical, and ultrastructural evaluation. Ophthalmology 1992;99;140–45.

30. Nemes Z (1992) Fibrohistiocytic differentiation in capillary hemangioblastoma. Hum. Pathol. 1992;23:805–10.

31. McComb R.D., Eastman P.J., Hahan F.J. and Bennett D.R.. Cerebellar haemangioblastoma with prominent stromal astrocytosis: diagnostic and histogenetic considerations. Clin. Neuropathol. 1987;6:149-54.

32. Andrew S. and Gradwell E.. lmmunoperoxidase labelled antibody staining in differential diagnosis of central nervous system haemangioblastomas and central nervous system metastases of renal carcinomas. J. Clin. Pathol. 1986;30:917-19.

33. Gouldesbrough D.R., Bell J.E. and Gordon A. Use of immunohistochemical methods in the differential diagnosis between primary cerebellar haemangioblastoma and metastatic renal carcinoma. J. Clin. Pathol. 1988;41:861-65.

34. Zaucha R. & Welnicka-Jaskiewicz M. (1996) [Hemangioblastoma of the breast]. Pol. Arch. Med. Wewn. 1986;95:145–6.

35. Boyd A.S. & Zhang J. Hemangioblastoma arising in the skin. Am. J. Dermatopathol. 2001;23:482–84.

36. Fanburg-Smith J.C., Gyure K.A., Michal M., Katz D., Thompson L.D. Retroperitoneal peripheral hemangioblastoma: a case report and review of the literature. Ann. Diagn. Pathol. 2000;4:81–7.

37. Tender G.C., Butman J.A., Oldfield E.H., Lonser R.R. (2004) Thoracic spinal nerve hemangioblastoma. Case illustration. J. Neurosurg. Spine 2004;1:142.

38. Rojiani A.M., Owen D.A., Berry K. et al. Hepatic hemangioblastoma. An unusual presentation in a patient with von Hippel-Lindau disease. Am. J. Surg. Pathol. 1991;15 81–6.

39. Poussa K, Sankila R, Haapasalo H, Kaariainen H, Pukkala E, Jaaskelainen J. Long-term prognosis of haemangioblastoma of the CNS: impact of von Hippel-Lindau disease. Acta Neurochir (Wien). 1999;141:1147-56.

40. de la Monte S.M. & Horowitz S.A. Hemangioblastomas: clinical and histopathological factors correlated with recurrence. Neurosurgery. 1989;25:695–8.

41. Hasselblatt M., Jeibmann A., Gerss J. et al. Cellular and reticular variants of haemangioblastoma revisited: a clinicopathologic study of 88 cases. Neuropathol. Appl. Neurobiol. 2005;31:618–22

Yazışma Adresi / Address for Correspondence:
Dr. Sevgi Bakariş
Kahramanmaraş Sütçü İmam University Faculty of Medicine
Department of Pathology
E-mail: sevgi.bakaris@gmail.com

Geliş tarihi/Received on : 20.08.2014
Kabul tarihi/Accepted on: 29.09.2014