Cerrahpaşa Med J 2022; 46(1): 83-85 CASE REPORT

A Rare Case of an Uterine Intravenous Leiomyomatosis

Ediz Karataş Şahin[1], Dilek Yüksel[2], Mehmet Ünsal[3], Çiğdem Güler Mesci[4], Kamil Hakan Müftüoğlu[5], Tuğba Kınay[1], Vakkas Korkmaz[1,2]

[1]Department of Gynecology and Obstetrics, Health Sciences University Etlik Zubeyde Hanım Women's Health Teaching and Research Hospital, Ankara, Turkey
[2]Department of Gynecologic Oncology Department, Health Sciences University Etlik Zubeyde Hanım Women's Health Teaching and Research Hospital , Ankara, Turkey
[3]Department of Gynecologic Oncology, Ankara City Hospital, Ankara, Turkey
[4]Department of Pathology, Health Sciences University Etlik Zubeyde Hanım Women's Health Teaching and Research Hospital, Ankara, Turkey
[5]Department of Pathology, Ankara City Hospital, Ankara, Turkey

Cite this article as: Karataş Şahin E, Yüksel D, Ünsal M, et al. A rare case of an uterıne intravenous leiomyomatosis. *Cerrahpaşa Med J.* 2022;46(1):83-85.

Abstract

Intravenous leiomyomatosis is a rare benign neoplasm originating from smooth muscle cells. Although histopathologically benign, its behavior may be aggressive and fatal outcomes can occur. However, it is very difficult to diagnose this entity, and intravenous leiomyomatosis is usually only suspected intraoperatively or after pathological analysis. In this article, we presented an interesting case of intravenous leiomyomatosis who was diagnosed intraoperatively and complicated with massive bleeding. Subsequent histopathological and immunohistochemical examination confirmed the diagnosis as intravenous leiomyomatosis.

Keywords: Hysterectomy, immunohistochemical analysis, intravenous leiomyomatosis, smooth muscle tumors, uterine fibroids

Intravenous leiomyomatosis (IVL) is a rare benign neoplasm that arises from benign smooth muscle cells and grows in the uterine and extrauterine venous system, including into the inferior vena cava, right atrium, and pulmonary arteries.[1] The incidence of IVL is low, and prior to 2018, only 300 cases have been described in the literature. It was first reported by Birch-Hirschfeld in 1896.[2] Although histologically benign, it may be aggressive in behavior.[3] An appropriate diagnosis and radical surgical approach for IVL are essential as recurrence may occur.[4,5] However, IVL is usually suspected intraoperatively or after pathological analysis. To prevent intraoperative complications such as massive bleeding, preoperative diagnosis is important. There are no published IVL cases with preoperative diagnosis without extra pelvic involvement. An uncommon case is presented here of isolated pelvic IVL detected as a result of intraoperative massive bleeding.

Case Presentation

A 50-year-old woman was admitted to our gynecology department with a 5-year history of heavy menstrual bleeding causing chronic anemia. Preoperative endometrial biopsy was reported as proliferative endometrium. During the pelvic examination, a 12-week uterus was palpable. Transvaginal ultrasonography (USG) revealed an enlarged uterus measuring 119 × 90 × 85 mm with multiple hypoechoic myomas, the largest of which was 76 × 63 mm, and a 40 mm myoma originating from the posterior wall of the cervix. There was no pathologic vascularization on Doppler exam. There were no ascites. Both ovaries were normal in appearance. During the operation, after clamping the uterine arteries, the myoma which was thought to have originated from the cervix released itself from the uterus, and severe bleeding started from the point of detachment of the myoma. The tissue of the myoma was much softer than expected and had a highly vascular appearance. After a quick hysterectomy, the source of the bleeding was determined. It was observed that the bleeding was caused by an extremely dilated vein deep on the right side of the pelvis, and the myoma had detached from this dilated vein. The defect on the aneurysm which caused the massive bleeding was repaired (Figure 1). The right uterine artery and hypogastric artery were ligated. There were no complications after surgery, and the patient was discharged after 5 days. After 1 week, a computed tomography angiography (CTA) was performed to observe the aneurysmatic vein. A smooth and lobulated contoured dilated venous structure, approximately 41 × 27 mm in size, located in the right lateral of the rectum was seen. After 2 months, color doppler USG of the abdominal aorta revealed no abnormal venous structure. Macroscopically, hysterectomy material with degenerated myoma on the right side wall and one nodular tissue with an elastic consistency of 40 × 30 × 20 mm was observed. In the cavity, fibroids with the largest diameter of 5 cm were observed. When a section was taken from the disintegrated area, myomatous structures were observed in the dilated spaces in the subserous area. Immunohistochemical staining was performed to determine whether these dilated spaces were vascular structures. The tumor cells were positive smooth muscle actin (SMA), caldesmon, and desmin. Nuclei were positive for estrogen receptors (ER) (Figure 2a-c). Monoclonal antibody for endothelial cells (CD34) was positive (Figure 3). The patient's consent was obtained for this case report.

Received: July 21, 2021 **Accepted:** September 7, 2021 **Available Online Date:** November 7, 2021
Corresponding author: Dilek Yüksel, Department of Gynecologic Oncology Department, Health Sciences University Etlik Zubeyde Hanım Women's Health Teaching and Research Hospital, Ankara, Turkey
e-mail: drdilekacar@hotmail.com
DOI: 10.5152/cjm.2021.21073

Content of this journal is licensed under a Creative Commons Attribution-NonCommercial 4.0 International License.

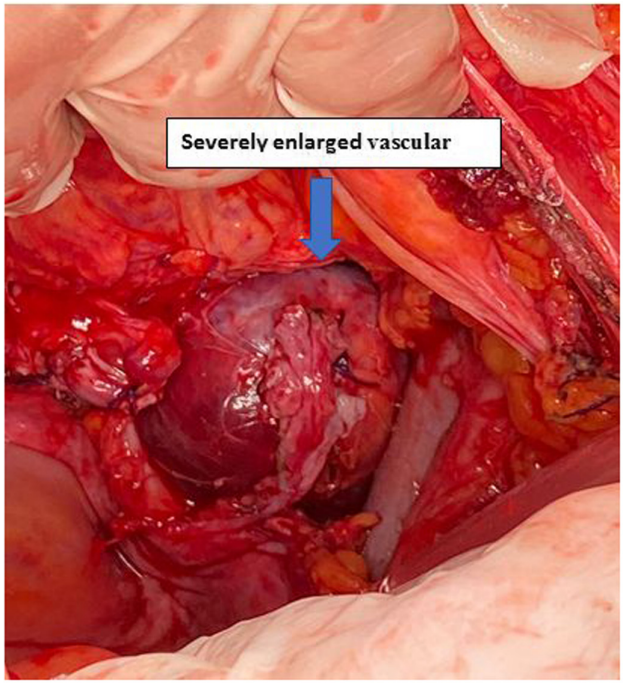

Figure 1. The enlarged area of vascular hemorrhage repaired after IVL excision.

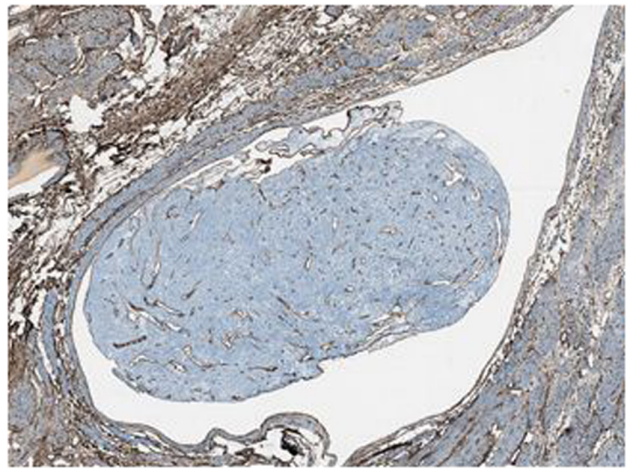

Figure 3. Endothelial vascular walls stained with CD34 marker, confirming the intravenous component of leiomyomatosis.

Discussion

Leiomyomas can occasionally develop into uncommon growth patterns and be found in unusual locations.[6] Diffuse peritoneal leiomyomatosis, intravenous leiomyomatosis, benign metastasizing leiomyomas, retroperitoneal leiomyomas, and parasitic leiomyomas are examples of leiomyomas with unusual growth patterns.[7] Two theories have been reported about IVL: the first is that it originates directly from the vein wall, and the second is that it develops as a result of vascular invasion of the leiomyoma.[4] Uterine IVL can be divided into 4 stages, which are described as stage I: tumors invading the uterine vein and limited to the pelvis, stage II: tumors extending to the abdominal cavity but without involvement of the renal vein, stage III: tumors invading the renal vein and inferior vena cava and extending further up to the right atrium but without reaching the pulmonary arteries, and stage IV: tumors reaching the pulmonary arteries and/or metastasizing to the lungs.[8] It usually affects women of reproductive age and occurs in premenopausal and multiparous women at the age of 40-50 years.

In the current case, multiple uterine leiomyomas were observed and IVL originating from the lateral wall of the uterus into the uterine vessel was detected. This case was accepted as stage I. Therefore, the possibility of IVL should be considered in cases with multiple uterine fibroids and appropriate imaging techniques should be used.

Female gonadal steroids, especially elevated estrogen levels, venous blood stasis, and local injuries such as a history of uterine surgery have an important role in the pathogenesis.[8] Clinical symptoms are non-specific, and usually symptoms are related to the pelvic mass, abnormal uterine bleeding, and abdominal pain.

Immunohistochemical markers including vimentin, desmin, SMA, progesterone receptor (PR) and estrogen receptor (ER) positivity, and positive CD34 expression are used in the diagnosis of IVL. Similarly, ER, desmin, caldesmon, SMA, and CD34 were positive in the current case.

The standard and adequate treatment for IVL is complete excision of all existing tumors and hysterectomy + bilateral oophorectomy. As these tumors are mostly ER positive, recurrence may occur in patients with preserved ovaries.[9] Treatment with gonadotropin releasing hormone analogue (GNRHa), tamoxifen, or medroxyprogesterone acetate (MPA) is controversially recommended in cases where complete resection is not performed to prevent the risk of recurrence.[10,11] The recurrence rate after complete removal is unknown, but recurrence 15 years after diagnosis and resection have been reported.[12] However, there is no definite consensus regarding the follow-up interval. It is difficult to distinguish between ordinary leiomyoma and IVL on imaging. Computed tomography angiography can be useful for determining tumor spread and pathway than other imaging tecniques.[13]

In conclusion, IVL is a rare disease, and radical surgery and long-term follow-up are necessary due to the risk of recurrence.

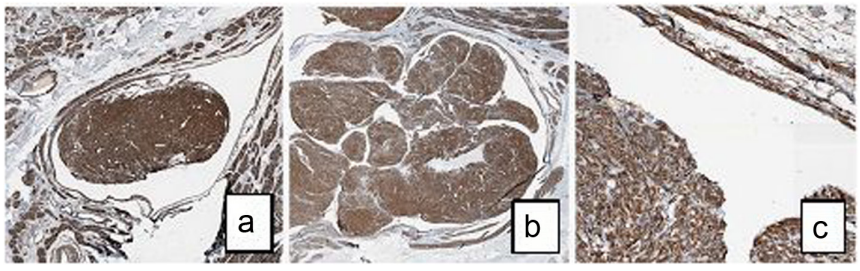

Figure 2. a-c. Immunohistochemical staining indicated SMA (a), desmin (b), and caldesmon (c). SMA, smooth muscle actin.

Preoperative imaging should be used to exclude the IVL in patients with multiple uterine myomas. To prevent massive bleeding, suspected cases should be operated on by a team of experienced surgeons in experienced centers.

Informed Consent: Written informed consent was obtained from patient who participated in this study.

Peer-review: Externally peer-reviewed.

Author Contributions: Concept – D.Y., T.K., V.K.; Design – D.Y., V.K.; Supervision – D.Y., T.K., V.K.; Materials – M.Ü., Ç.G.M., K.H.M.; Data Collection and/or Processing – E.K.Ş., M.Ü., Ç.G.M., K.H.M.; Analysis and/or Interpretation – D.Y., M.Ü., K.H.M.; Literature Search – E.K.Ş., D.Y., Ç.G.M., K.H.M.; Writing Manuscript – E.K.Ş., D.Y.; Critical Review – D.Y., T.K., V.K.

Declaration of Interests: The authors have no conflicts of interest to declare.

Funding: The authors declared that this study has received no financial support.

References

1. Burke M, Opeskin K. Death due to intravenous leiomyomatosis extending to the right pulmonary artery. *Pathology*. 2004;36(2):202-203. [CrossRef]
2. Barksdale J, Abolhoda A, Saremi F. Intravenous leiomyomatosis presenting as acute Budd-Chiari syndrome. *J Vasc Surg*. 2011;54(3):860-863. [CrossRef]
3. Shi T, Shkrum MJ. A case report of sudden death from intracardiac leiomyomatosis. *Am J Forensic Med Pathol*. 2018;39(2):119-122. [CrossRef]
4. Lam PM, Lo KW, Yu MY, et al. Intravenous leiomyomatosis: two cases with different routes of tumor extension. *J Vasc Surg*. 2004;39(2):465-469. [CrossRef]
5. Fatma D, Najeh H, Hajer B, Wael M, Hedhili O, Chaouki M. Intravenous leiomyomatosis of the uterus: a case report. *Obstet Gynecol Cases Rev*. 2017;4(2):108. [CrossRef]
6. Fasih N, Prasad Shanbhogue AKP, Macdonald DB, et al. Leiomyomas beyond the uterus: unusual locations, rare manifestations. *RadioGraphics*. 2008;28(7):1931-1948. [CrossRef]
7. Yüksel D, Kilic C, Kodal B, et al. A rare case of a retroperitoneal leiomyomatosis. *J Gynecol Obstet Hum Reprod*. 2020;50(6):101760. [CrossRef]
8. Yu X, Fu J, Cao T, Huang L, Qie M, Ouyang Y. Clinicopathologic features and clinical outcomes of intravenous leiomyomatosis of the uterus: a case series. *Medicine*. 2021;100(1):e24228. [CrossRef]
9. Tresukosol D, Kudelka AP, Malpica A, Varma DG, Edwards CL, Kavanagh JJ. Leuprolide acetate and intravascular leiomyomatosis. *Obstet Gynecol*. 1995;86(4 Pt 2):688-692. [CrossRef]
10. Low HY, Zhao Y, Huang KS, Shen HP, Wu PJ, Tseng CJ. Intravenous leiomyomatosis of the uterus: a clinicopathological analysis of nine cases and literature review. *Taiwan J Obstet Gynecol*. 2017;56(3):362-365. [CrossRef]
11. Du J, Zhao X, Guo D, Li H, Sun B. Intravenous leiomyomatosis of the uterus: a clinicopathologic study of 18 cases, with emphasis on early diagnosis and appropriate treatment strategies. *Hum Pathol*. 2011;42(9):1240-1246. [CrossRef]
12. Clement PB, Young RH, Scully RE. Intravenous leiomyomatosis of the uterus. A clinicopathological analysis of 16 cases with unusual histologic features. *Am J Surg Pathol*. 1988;12(12):932-945. [CrossRef]
13. Wang H, Nie P, Chen B, et al. Contrast-enhanced CT findings of intravenous leiomyomatosis. *Clin Radiol*. 2018;73(5):503.e1-503.e6. [CrossRef]