Ann Med Res 2020;27(12):3099-3106

Annals of Medical Research

DOI: 10.5455/annalsmedres.2020.05.424

Original Article

Radiological evaluation of anatomical changes in implant and adjacent segments after rigid fusion

Umit Ali Malcok[1], Nilufer Aylanc[2]

[1]Department of Neurosurgery, Faculty of Medicine, Canakkale Onsekiz Mart University, Canakkale, Turkey
[2]Department of Radiology, Faculty of Medicine, Canakkale Onsekiz Mart University, Canakkale, Turkey

Copyright@Author(s) - Available online at www.annalsmedres.org
Content of this journal is licensed under a Creative Commons Attribution-NonCommercial 4.0 International License

Abstract

Aim: We aimed to determine the anatomical remodeling seen after lumbar spine stabilization in detail. Using magnetic resonance images, it is also aimed to reveal this remodeling is not only limited to the adjacent segment and also happens in the upper instrumented vertebra region. At the end of this study, it is suggested to develop new radiological parameters to predict the changes in the adjacent segment and upper instrumented vertebra regions.

Materials and Methods: Twenty cases operated for degenerative lumbar stenosis were included in our study. Quantitative data were obtained by radiological measurements by a radiologist and neurosurgeon. On magnetic resonance images, the anatomical structures changed by remodeling were compared before and after the operation during (6-26 months) postoperative period. Unlike previous studies, anterior, middle and posterior disc heights; Cobb angle in the adjacent segment, spinal canal area, bilateral neural foramen, facet joint areas and flavum thicknesses were evaluated.

Results: From the sixth month after lumbar fusion, it was observed that angles and anatomical structures were changed in adjacent segment. Also, it was observed that the areas with neural structures expanded in the upper instrumented vertebra region. The degeneration in adjacent segment and relaxation in the upper instrumented vertebra region were found to be statistically significant. A statistically strong positive correlation was found between the number of vertebrae included in the lumbar fusion and the mean height of the adjacent segment disc (r: 0.526, p: 0.017).

Conclusion: After comparing the measurements in adjacent segment and upper instrumented vertebra regions before and after the operation, it was concluded that the remodeling was statistically significant. We suggest that the parameters in our study can be used as a scoring method for early detection of adjacent segment degeneration and/or disease. Thus, it will be possible to create follow-up indicators findings after fusion.

Keywords: Adjacent segment; lumbar vertebrae; spinal fusion; upper instrumented vertebra

INTRODUCTION

There are still unknowns about the prognosis and nature of developing lumbar degenerative spinal stenosis. Back pain is a very common and important problem in societies. About 60-80% of people experience low back pain at least once in their lifetime (1). Since not all the asymptomatic cases apply to the clinics, the distribution of cases in the healthy population cannot be revealed. After transpedicular screws are applied in the treatment of lumbar degenerative diseases, adjacent segment (AS) degeneration and disease do not always follow each other. Degeneration refers to the radiological changes at the level adjacent to the stabilized vertebra independent of symptoms. Disease is defined as the neurological symptoms characterized by compression of neural structures and pain during which degeneration occurs (2). "Decompression and fusion" is a widely used surgical technique in the treatment of lumbar degenerative spinal stenosis and is being applied in many centers every year around the world (3). Adjacent segment disease is a process that occurs after spinal fusion operations, causing patient discomfort and surgical failure (4). Different types of surgical techniques and implants are being investigated to prevent adjacent segment (AS) disease (5). Many studies were made and more are still ongoing about this process (6). In studies, generally one or more anatomical structures and their relationship with the patient's clinical situation are examined (4,7–11). Despite efforts to prevent the disease, an effective method has not been developed yet. It has been reported that after fusion operations, AS degeneration develops in 9-26.6% and disease in 8.5% of these patients (12). In the series of 1000 cases with posterior lumbar interbody fusion,

Received: 02.05.2020 **Accepted:** 23.11.2020 **Available online:** 22.12.2020
Corresponding Author: Umit Ali Malcok, Department of Neurosurgery, Faculty of Medicine, Canakkale Onsekiz Mart University, Canakkale, Turkey **E-mail:** umalcok@comu.edu.tr

Okuda et al. reported that AS degeneration was 9% and the average of this process was 4.7 years. In the same study, revision surgery was applied to 6.2% of the cases in the first 5 years and to 9.9% of them before the tenth year (13).

We aimed to show the degenerative changes in the early postop period, using measurements on affected anatomical sides due to AS degeneration and disease, and also remodeling of upper instrumented vertebra (UIV) region. For this purpose, radiologic parameters on magnetic resonance (MR) images were used. In our study, structural changes in the UIV, to which transpedicular screw was applied, were also investigated. Facet areas, neural foramen, disc heights, ligamentum flavum (LF) thickness, segmental Cobb angle and spinal canal area were measured in AS and UIV. After the evaluation of these parameters, it was aimed to obtain new insight about the development of AS disease and process in UIV region.

MATERIALS and METHODS

Patients operated between January 2017 and June 2019 for instability and spinal stenosis, with background of lumbar degenerative disease, was included in our study. MR images were obtained from all patients because it was the most sensitive imaging technique in evaluating neural anatomy and perineural anatomical structures, especially soft tissues. The data from MR images retrospectively evaluated in the preoperative period and at the earliest sixth months after the operation. Ethics committee approval was taken from Canakkale Onsekiz Mart University Clinical Research Ethics Committee date 26.02.2020 and number 04 decision. The necessary permissions for the medical records to be used for scientific purposes were on consent forms obtained from patients before the operation.

Patients who had intense implant artifacts, and who underwent laminectomy, discectomy, and foraminotomy, were excluded from the study. In addition, patients who received radiotherapy at the measurement site, patients with lower limb asymmetry, congenital hip dislocation, pelvic imbalance, gait disturbance, dysfunction of the lower limb peripheral nerves, advanced lumbar spondylolisthesis, infection in the lumbar spine or lumbar region were also excluded. A homogeneous group was formed by selecting cases that were operated for adult degenerative lumbar spinal stenosis and instability. Radiological images of the lumbar spine were obtained using a 1.5 Tesla MR (Signa Excite; GE Medical Systems, WI) device. On MR images, T2-weighted sequences of the sagittal and axial plan were included from twenty patients, who had images from before and after the operation.

Cobb angle, disc heights (anterior, middle and posterior), neural foramen areas were measured in the sagittal plane. In the axial plan, LF thicknesses, facet joint areas and spinal canal areas were calculated. Disc heights and LF thicknesses were measured in mm, while neural foramen, spinal canal and facet joint areas were in mm^2. The selection of the areas used in the measurements was made in accordance with the references in the literature (14,15).

The measurements of the anatomic areas and structures affected by AS degeneration and disease were performed independently by a radiologist and neurosurgeon, as in different studies (16). The data were analyzed by taking the averages of these measurements. The measurement of disc heights was made in accordance with the technique described by Tunset et al. on the sagittal midline section (15). The anterior, middle and posterior heights of the disc in the AS and UIV regions were measured with linear measurement line (Figure 1).

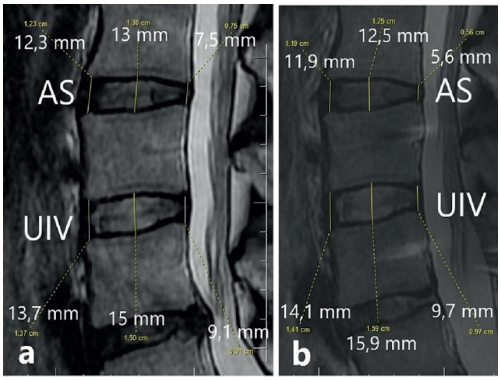

Figure 1. Disc heights. Preoperative (a) and postoperative (b)

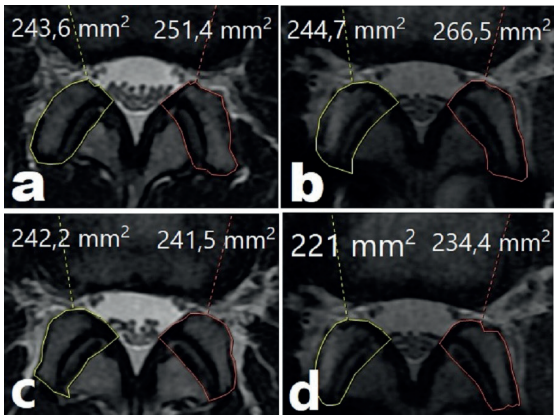

Figure 2. Facet joint areas. Preoperative; AS (a), UIV (b) and postoperative; AS (c), UIV (d)

In the measurement of the facet areas, the borders of bone forming the facet joint, including the flavum, were calculated. Limits of facet joint area are; bony cortex belonging to the superior articular facet of the lower vertebra laterally and anteriorly, anterior medial border of LF facet joint capsule anterior border on the medial side and subchondral bone edge of inferior articular process of the upper vertebra forming the posterior part of the joint (Figure 2). Borders were drawn by multi-point circle line and the area included was calculated in mm^2 as in the study of Otsuka et al. (10). The fusion segment with the proximal of AS was included in the planning for the Cobb angle measurement. Cobb angles before and after the operation were measured and recorded (Figure 3). In order to determine the Cobb angle; the linear line tangent to the upper end plate of the vertebra forming the AS above, and the line tangent to the lower end plate of the UIV in the fusion segment and the narrow angle at the intersection of the lines intersecting these two lines at right angles were measured (17).

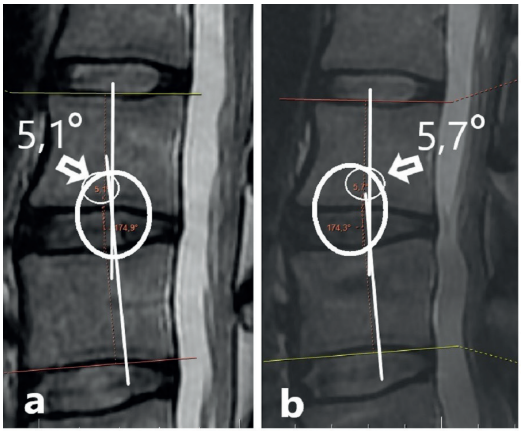

Figure 3. Cobb angle. Preoperative (a) and postoperative (b). Sagittal plan Cobb angles of UIV and AS junction

In neural foramen area measurement, the neural structure and perineural adipose tissue were included and the periosteal boundaries were accepted as limits (Figure 4). For the spinal canal area, limit markers were the periosteum surrounding the dural sac and epidural adipose tissue, root outlets at the level of the neural foramen entry, lines connecting the vertebral corpus to posterolateral corner and the corner of the antero-medial capsule of the facet joint (Figure 5). The measurement was done on axial images and borders were drawn using a multi-point circle line, in mm^2 unit (18). Ligamentum flavum thicknesses were measured on the axial MR images at the thickest point of the ligament, by taking into account an axis extended from the thickest region of the flavum across the neural foramen (11). If the ligament borders were irregular, the thickest region was used for the measurement (Figure 6). The measurements were obtained as two-dimensional, with the help of the area calculation module in the PACS (Picture Archiving and Communicating System) software.

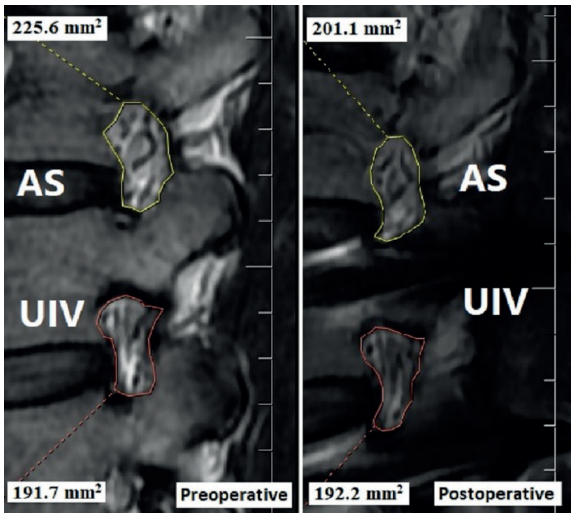

Figure 4. Neural foramen areas. Preoperative and postoperative AS and UIV

The data was analyzed by SPSS version 20 (Statistical Package for the Social Sciences, IBM SPSS Statistics for Windows, Armonk, NY, USA), using number, mean, standard deviation, median, minimum and maximum values the data presentation. According to the results of the normal distribution compatibility test, the Significance of the Difference between Two Spouses was used as the parametric test and Wilcoxon Paired Two Sample Test was used as the nonparametric test. Spearman Correlation Analysis was applied in the analysis of data with correlation, according to the results of the normal distribution compatibility test. The correlation coefficient was evaluated as; r: 0-0.24-weak; r: 0.25-0.49-medium; r: 0.50-0.74-strong; r: 0.75-1.0- very strong. $p<0.05$ was accepted as significant.

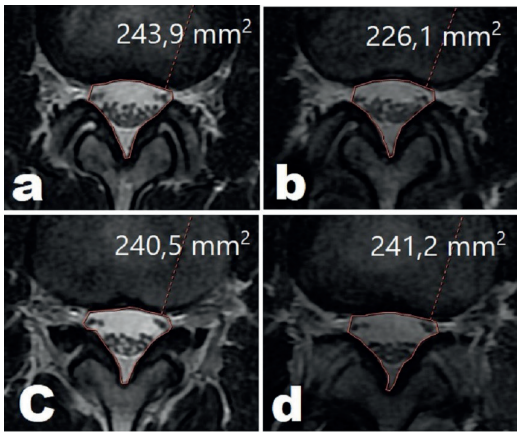

Figure 5. Spinal canal areas. Preoperative AS (a), UIV (b) and postoperative AS (c), UIV (d)

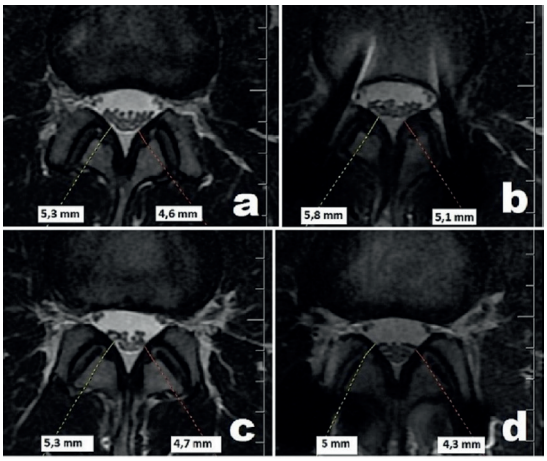

Figure 6. Ligamentum flavum thickness. Preoperative AS (a), UIV (b) and postoperative AS (c), UIV (d)

RESULTS

Analysis of measurements

Flavum thicknesses

Ligamentum flavum thicknesses in the AS and UIV regions were measured bilaterally on the axial T2 sequence. A total of 160 LF's were measured before and after the operation, 8 in each case. LF thicknesses mean values in AS were preoperatively 3.6 ± 1.1 (Median: 3.5, Min-Max: 1.5-6.2) mm, postop 4 ± 1.2 (Median: 4, Min-Max: 1.7-5.8) mm and 0.4 mm increase in LF was observed, which was statistically significant ($p<0.05$). The mean thickness of LF in the UIV were preoperatively 3.8 ± 1.2 (Median: 3.4, Min-Max: 2.2-6.3) mm, postop 3.1 ± 1.1 (Median: 2.8,

Min-Max: 1.9-5.6) mm. An average of 0.7 mm decrease in this segment in the postop period, according to Wilcoxon Paired Two Sample Test, was considered statistically significant (p<0.05) (Table 1).

Disc heights

Disk heights in 80 different sections in the AS and UIV regions were measured before and after the operation. The height of each disc on the sagittal plane was taken from anterior, middle and posterior. In addition, disk height averages were included in the analysis. Anterior disc heights were; preoperative / postoperative 9.9 ± 2.7 / 9.7 ± 2.6 mm difference -0.2 mm (p>0.05) and middle preoperative / postoperative 10.6 ± 2.4 / 10.3 ± 2.6 mm difference -0.3 mm (p>0.05), although there was a decrease in heights, there was no statistically significant difference. However, the difference in preoperative / postoperative 7 ± 1.8 / 6.2 ± 2.2 mm in the posterior disc height was considered significant (p<0.05). There was a strong positive, statistically significant correlation between the number of vertebrae included in the lumbar fusion and the AS disc heights' mean values before and after the operation, as r: 0.526 was found to be p: 0.017 (r: Correlation coefficient, p: Spearman correlation test). Thus, as the number of vertebrae included in the fusion increased, the disc height decreased in AS. Posterior (p<0.05), middle (p<0.05) and anterior (p<0.05) disc heights in UIV were increased after postop period, and was statistically significant (Table 1). This increase is explained by the decrease in disc pressure due to the axial load carried by pedicular screws and rods (19).

Table 1. Results of measurements made before and after the operation

Measured Region	Preoperative		Postoperative		
	Mean ± Sd (Min-Max)	Median	Mean ± Sd (Min-Max)	Median	P value
Cobb angle	7.8±4.0	8.4 (0.2-15.1)	9.9±4.4	9.2 (0.4-19.3)	<0.001
Spinal canal area UIV	180±49.8	188 (80.2-253)	187.8±46.9	202.3 (95.3-245)	< 0.05
Spinal canal area AS	201.8±62.6	197.3 (102.4-331.7)	186.8±54.6	183.3 (88-298.8)	<0.001
Facet joint bilateral mean area UIV	195±61.2	212.9 (99.4-294.4)	182±63.4	184 (91.9-300.3)	< 0.05
Facet joint bilateral mean area AS	159±48.9	159 (101-279.1)	172±53.9	162.3 (110.7-286)	< 0.05
Disc heights anterior+central+posterior mean UIV	9±2.5	9.2 (4.2-13.8)	9.7±2.3	10.4 (4.3-13.4)	<0.001
Disc heights anterior+central+posterior mean AS	9.1±2	9.1 (4.4-13)	8.7±2.3	8.9 (3.4-12.8)	< 0.05
Ligamentum flavum thickness right+left mean UIV	3.8±1.2	3.4 (2.2-6.3)	3.1±1.1	2.8 (1.9-5.6)	< 0.05*
Ligamentum flavum thickness right+left mean AS	3.6±1.1	3.5 (1.5-6.2)	4±1.2	4 (1.7-5.8)	< 0.05
Neural foramen area right+left mean UIV	101.4±31.7	102.2 (51.6-158.5)	113.2±29.1	117 (67.3-164.3)	<0.001
Neural foramen area right+left mean AS	106.8±33.3	106.6 (37.4-176.1)	90.8±31.6	89.5 (26.7-157.6)	<0.001

Sd: Standard Deviation, Min: Minimum, Max: Maximum, AS: Adjacent Segment, UIV: Upper Instrument Vertebra. The Significance of the Difference Between Two Spouses* was used as the parametric test and Wilcoxon Paired Two Sample Test was used as the nonparametric test. p: <0.05 was considered significant

Facet joint areas

Facet joint area measurements were evaluated bilaterally, and mean values were compared. At the level of AS, facet joint areas mean values were 159 ± 48.9 mm^2 before the operation, while they were 172 ± 53.9 mm^2 in postop period (p<0.05). These results show that increases in the areas of the facet joints are a response to the increased mechanical load in AS. In the UIV region, facet joint areas mean values were 195 ± 61.2 mm^2 preoperatively and were 182 ± 63.4 mm^2 postoperatively (p<0.05).

Cobb angles

Sagittal plan Cobb angles increase to 9.9 ± 4.4 degrees after the operation (p<0.001) and it showed that kyphosis began in the average 11.2. months with this significant increase (Table 1).

Spinal canal areas

Adjacent segment spinal canal area mean values were 201.8 ± 62.6 mm^2 before the operation and 186.8 ± 54.6 mm^2 after the operation. When these were compared, a significant narrowing was observed in the canal at the AS level in the post-operative period (p<0.001). This change was regarded as a marker of early-onset degeneration in AS. In contrast to the narrowing of the spinal canal in AS, it was observed that there was a significant amount of expansion in the spinal canal in UIV region, as preoperatively 180 ± 49.8 mm^2 and postoperatively 187.8 ± 46.9 mm^2) (p<0.05) (Table 1).

Neural foramen areas

Neural foramen areas were calculated bilaterally on sagittal images. It was observed that mean values in AS were 106.8 ± 33.3 mm^2 preoperatively and regressed to 90.8 ± 31.6 mm^2 after the operation (p<0.001). This result shows that the pressure on spinal roots at the AS level started in the early period. Neural foramen areas mean values in UIV were 101.4 ± 31.7 mm^2 in preoperative period,

while expanded to 113.2 ± 29.1 mm^2 after the operation ($p<0.001$). Despite the changes at AS level, the pressure on spinal roots at the level of UIV decreased in the early postop period (Table 1).

There are some limitations in our study. One of them is using only MR images, not the other modalities, especially bone-sensitive ones. Another limiting factor is the lack of correlation between clinical data and imaging findings in this retrospective study. Therefore, in terms of contributing to the literature further studies are needed including global balance, pelvic parameters, other angles of the spinal axis and clinical data.

DISCUSSION

Degenerative stenosis in the lumbar spine advances progressively with aging and reduces the life quality. Lumbar stenosis causes morbidity and also effects mortality indirectly (20). Recently, decompression and fusion technique were used to reduce pressure on neural structures because of instability and stenosis (3). Biomechanical forces change as a result of restriction of movement in the spine (21). After changing load distribution, process in the transition region of the stable and mobile segments - called as AS, begin progressively (22). The anatomical structures in AS are exposed to remodeling under these forces. Progressive change in anatomy affected by this process leads to AS degeneration and disease, and so revision surgery might be required after the process has developed. Because of high risks of this surgical technic for some patients, studies are ongoing on algorithms which will enable us to recognize these patients in the early period (23,24). As long as there is no distinct algorithm that helps us predict the development of AS degeneration and disease, the need for such studies will continue. In order to contribute to solving this problem, in this study we used multiple measurements of anatomical regions.

With the aim of getting new data about AS degeneration/disease process in the early period, area and angle measurements were made on MR images at the level of AS and UIV. Anatomical structure and remodeling in these areas were seen in response to changing biomechanical forces after fusion. Because of the progressive period, early anatomical and postural changes at relevant levels on MR images were evaluated in order to determine problems with degeneration before they became clinically apparent.

Many studies about development of kyphosis after lumbar fusion (25), increased area due to facet joint trophism (7), increased load in disc and torque-dependent degeneration (26), narrowing of the spinal canal and neural foramen due to flavum thickening (9,11) can be seen in the literature, but those focused on certain structures. However, remodeling occurs in whole region, tissues and angles. It is seen that more detailed studies are needed to obtain a clearer picture about AS degeneration and disease process.

Increase in kyphosis and a positive shift of the sagittal balance can lead to impaired sagittal balance, back pain and decreased respiratory capacity. It has been reported that the increase in sagittal Cobb angle after AS degeneration causes proximal junctional kyphosis (25). More than 10 degrees difference between the sagittal Cobb angles measured radiologically before and after the operation, is defined as proximal junctional kyphosis (22).

In our study, the difference in sagittal Cobb angle before and after the operation was 2.1 degrees ($p<0.001$). It was concluded that the kyphotic angle between the AS and the UIV segment increased in the early postoperative period (11.2 months average) and may be a marker of kyphotic development of AS degeneration in the late period. Axial loading and shear force are known to be effective in increasing kyphotic angulation by changing the sagittal Cobb angle (27). The radiological detection of the increase in sagittal Cobb angle in the early period after lumbar stabilization, was also evaluated as a parameter that could be used to detect AS disease in the early period. Therefore, the sagittal Cobb angle measurement can be useful to detect development of AS degeneration in the early period and is useful in preventing the disease.

The changing biomechanical force distribution causes the formation of new tensile forces on the ligaments and LF in the AS and UIV regions (28,29). In response to varying tensile forces and increased loads on AS, flavum thicknesses increase (9). In our series, an average of 0.4 mm increase was detected in the LFs in AS after fusion. As emphasized in the literature, it is known that structural narrowing of the lateral recess and spinal canal cause neurological symptoms doe to neural compression (9). In studies evaluating the late period of operation, LF and spinal canal have been shown to be continuously remodeled after surgical interventions for fusion (9).

In our study, a 0.7 mm reduction in flavum thickness was observed in the UIV region. Therefore, as a result of the decrease in LF thickness, it is expected that the neural foramen will expand and the pressure in the neural structures will decrease in the early postop period.

The acceleration of degeneration in disc structure in the AS after fusion is explained by biomechanically increased rotational moment and axial loading (26). The fact that the anterior and middle disc regions are more mobile than the posterior disc region enables diffusion of nutrients from the end plate and more active disc metabolism (30,31). After the reduction of segmental mobilization, disc metabolism slows down and as a result, the height of the disc continues to progressively decrease with the triggering of disc degeneration (32). In finite element studies, the increase in the loading force that AS is exposed to and the decrease in posterior disc height have been shown (33).

In our study, we determined that this decrease occurred in AS disc heights radiologically. There was a minimal decrease in the height of the anterior (difference -0.2 mm,

p>0.05) and middle (difference -0.3 mm, p> 0.05) disc heights in the sagittal plane, statistically not significant. On the other hand, an average decrease of 0.9 mm (p<0.001) in posterior disc heights was statistically significant. This difference between anterior, middle and posterior parts heights is biomechanically explained by the fact that the posterior column carries more load than the anterior and middle, is exposed to high pressure and is less mobile (33). From the measurements in our study, it was seen that the height of the posterior disc began to decrease in the early period and it can be used as one of the early parameters of degeneration. Also, in neural foramen measurements before and after stabilization, neural foramen areas decreased an average of 17 mm^2 as well as decreased disc height (p<0.001). This finding shows that degenerative processes progress in more than one area simultaneously

It has been reported that the load on AS increases biomechanically and this increase is higher in posterior disc as shown in the finite element studies (33). The fact that the anterior and middle disc regions are more mobile than the posterior disc side enables the end plate diffusion and causes disc metabolism to be more active (30,31). After the degeneration progresses and decreases mobilization, which provides diffusion, disc metabolism slows down and its height decreases. However, the reduction in disc height continues progressively (32).

In different studies it has been shown that the degenerative process in this region slows down as a result of the decrease in rotational forces along with the facet joint, ligamentum flavum in the stabilized segment, other connective tissues and the axial loads on intervertebral disc (19,34). Similar to these processes, in our study it was observed that there was an average 0.7 mm increase in disc height at the level of UIV, where a transpedicular implant was applied (p<0.001). Consequently, the expansion of the neural foramen areas due to the increase in the height of the degenerative spine levels included in the fusion is an expected result. The fact that neural foramen areas in the fusion segment expanded by an average of 16 mm^2 in our measurements was consistent with this result (p<0.001) (Table 1). This increase is explained by the fact that axial loading is carried by pedicular screws and rods and the pressure on discs decreases (19). Therefore, after stabilization, the decrease of symptoms due to spinal root compression is the reflection of the widening of these anatomic areas. As a result, the quality of life of patients increases with the decrease in the pressure in neural tissues (35).

Experimental and retrospective studies have shown that increased biomechanical forces cause degeneration and deformation in the AS facet complex (36,37). The facet joint is particularly affected by the flexion moment and increased anterior shear force that AS is exposed to on the sagittal plane (7). The degeneration in the facet joints with the effect of the changing load distribution reshapes the joint structure. In these studies, reshaping is shown as; facet tropism (bilateral asymmetric facet joint angles), flattened joint surfaces, joint capsule thickening and increase in osteophytic degeneration (7,34).

The data we obtained from the measurements in our study show that the AS facet joint areas increased significantly after the operation (difference +13 mm^2, p<0.05). This result showed us that the increase in AS facet joint areas in the studies in which the cases were followed for a long time, started in the early period (average 11.2 months). In the study, using the finite element model in the lumbar spine, it was shown that the disc pressure at the level of the implant decreased and the load on the facet joint decreased (34). In the biomechanical study by Rohlmann et al., seven different load vectors were used and the results were evaluated by simulation and reported that intradiscal pressure, forces on the facet joint, facet joint motion and rotational moment in the spine decreased at implant levels (34). In our measurements there was a significant decrease in the fusion developed right / left and mean facet areas (difference (-13 mm^2) p<0.05) (Table 1). This reduction in facet areas is explained by the transfer of the load on the axial plane to another segment by pedicular screws and rods as a result of a similar biomechanical change leading to a decrease in disc height (19,34). Therefore, with the decrease in facet joint areas, the pressure on the neural tissues in the stabilized segment will also decrease.

There are many studies which show remodeling of the one or more anatomical structures in AS in the process of degeneration and disease, which was encountered after the fusion operations in lumbar region (3,6-10,18,27,33,36,37). Also, a limited number of anatomical structures were observed in studies on UIV, which have undergone changes after fusion (19,28,29,34,35). In each of those studies, it was shown that the reshaped anatomical structures are not limited to AS, but also in the UIV region. However, these results were achieved by evaluating a limited number of anatomical structures.

In our study, we focused on AS and UIV regions in order to evaluate all the structures affected simultaneously in the degeneration process. At these levels, we measured disc height, spinal canal area, facet joint area, neural foramen area, LF thickness and kyphosis angle. Thus, changes in the degenerative process due to remodeling were evaluated radiologically on MRI. by evaluating the possible effects of time on this process, it was seen that the changes started in the early period. When all the measurements were evaluated, it was observed that remodeling in AS caused pressure on the neural structures and all the structures in the area of the measurement contributed to this neural foraminal stenosis. The reduction of pressure-related symptoms in neural structures is a positive result of remodeling in the UIV region. There are some limitations in our study. One of them is using only MR images, not the other modalities, especially bone-sensitive ones.

Another limiting factor is the lack of correlation between clinical data and imaging findings in this retrospective study. Therefore, in terms of contributing to the literature further studies are needed including global balance, pelvic parameters, other angles of the spinal axis and clinical data.

CONCLUSION

As a conclusion, it was seen that including all the measurements of the structures affecting each other is needed in order to understand the remodeling in AS and UIV regions. On postop MR images, it was revealed that the UIV region should also be examined in addition to AS. Performing MR in an average of 11.2 months (6-26 months) after the operation and using appropriate radiological parameters can give valuable information about the progression. More specific results were achieved with the inclusion of the entire AS and UIV region in the study.

In future studies, it would be better to get reliable interpretations about AS problems by scoring and measuring additional parameters on MR images, and including clinical data. Also, it will be possible to prepare a guide about postop period to be used in the reporting of follow-up MRs. In this way, follow-up markers to use in reporting, and an auxiliary scale can be created to determining patients as AS disease candidates after fusion.

Conflict of interest : The authors declare that they have no competing interest.

Financial Disclosure: There are no financial supports.

Ethical approval: Ethics committee approval was taken from Canakkale Onsekiz Mart University Clinical Research Ethics Committee date 26.02.2020 and number 04 decision.

REFERENCES

1. Ozger O, Kaplan N. Evaluation of clinical outcomes of 271 patients undergoing lumbar microdiscectomy in the light of literature. Ann Med Res 2020;27:664-9.
2. Hilibrand AS, Robbins M. Adjacent segment degeneration and adjacent segment disease : the consequences of spinal fusion? Spine J 2004;4:190-4.
3. Martin BI, Mirza ĀSK, Spina N, et al. Trends in Lumbar Fusion Procedure Rates and Diseases in the United States , 2004 to 2015. Spine (Phila Pa 1976) 2019;44:369-76.
4. Babayev R, Özgen S, Ekşi M, et al. Lomber Posterior Transpediküler Fiksasyon ile Füzyon Operasyonu Yapılan Hastalarda Postoperatif Dönemde Gelişen Komşu Segment Dejenerasyonu ve klinik Sonuçları. Türk Nöroşir Derg 2015;25:22-6.
5. Park P, Garton HJ, Gala VC, et al. Adjacent segment disease after lumbar or lumbosacral fusion: Review of the literature. Spine (Phila Pa 1976) 2004;29:1938-44.
6. Masevnin S, Ptashnikov D, Michaylov D, et al. Risk factors for adjacent segment disease development after lumbar fusion. Asian Spine J 2015;9:239-44.
7. Kim HJ, Kang KT, Son J, et al. The influence of facet joint orientation and tropism on the stress at the adjacent segment after lumbar fusion surgery: A biomechanical analysis. Spine J 2015;15:1841-7.
8. Kotani Y, Cunningham BW, Cappuccino A, et al. The effects of spinal fıxation and destabilization on the biomechanical and histologic properties of spinal ligaments: An in vivo study. Spine (Phila Pa 1976) 1998;23:672-83.
9. Ohtori S, Orita S, Yamauchi K, et al. Change of lumbar ligamentum flavum after indirect decompression using anterior lumbar interbody fusion. Asian Spine J 2017;11:105-12.
10. Otsuka Y, An HS, Ochia RS, et al. In Vivo Measurement of Lumbar Facet Joint Area in Asymptomatic and Chronic Low Back Pain Subjects. Spine (Phila Pa 1976) 2010;15:924-8.
11. Yoshiiwa T, Miyazaki M, Notani N, et al. Analysis of the relationship between ligamentum flavum thickening and lumbar segmental instability, disc degeneration, and facet joint osteoarthritis in lumbar spinal stenosis. Asian Spine J 2016;10:1132-40.
12. Hashimoto K, Aizawa T, Kanno H, et al. Adjacent segment degeneration after fusion spinal surgery—a systematic review. Int Orthop 2019;43:987-93.
13. Okuda S, Yamashita T. Adjacent Segment Disease After Posterior Lumbar Interbody Fusion : A Case Series of 1000 Patients. Glob Spine J 2018;8:722-7.
14. Hong CH, Park JS, Jung KJ, et al. Measurement of the Normal Lumbar Intervertebral Disc Space Using Magnetic Resonance Imaging. Asian Spine J 2010;4:1-6.
15. Tunset A, Kjaer P, Chreiteh SS, et al. A method for quantitative measurement of lumbar intervertebral disc structures : an intra- and inter-rater agreement and reliability study. Chiropr Man Therap 2013;21:26.
16. Hamid RS, Akhtar W, Shamim MS, et al. Original Article Observer variation in MRI evaluation of patients with suspected lumbar disc herniation and nerve root compression : Comparison of Neuroradiologist and Neurosurgeon ' s interpretations. J Pak Med Assoc 2012;62:826-9.
17. Horng MH, Kuok CP, Fu MJ, et al. Cobb angle measurement of spine from x-ray images using convolutional neural network. Comput Math Methods Med 2019;2019: 6357171.
18. Lim YS, Mun JU, Seo MS, et al. Dural sac area is a more sensitive parameter for evaluating lumbar spinal stenosis than spinal canal area: A retrospective study. Med (United States) 2017;96:19-21.
19. Jain P KM. Prediction of biomechanical behavior of lumbar vertebrae using a novel semi-rigid stabilization device. Proc Inst Mech Eng H 2019;233:849-57.
20. Otani K, Kikuchi S, Yabuki S, et al. Lumbar Spinal Stenosis Has a Negative Impact on Quality of Life Compared with Other Comorbidities : An Epidemiological Cross-Sectional Study of 1862 Community-Dwelling Individuals. ScientificWorldJournal 2013;2013:1-9.

21. Cristofolini L, Brandolini N, Danesi V, et al. Strain distribution in the lumbar vertebrae under different loading configurations. Spine J 2013;13:1281-92.
22. Glattes RC, Bridwell KH, Lenke LG, et al. Proximal Junctional Kyphosis in Adult Spinal Deformity Following Long Instrumented Posterior Spinal Fusion Incidence , Outcomes , and Risk Factor Analysis 2005;30:1643-9.
23. Kreiner DS, Shaffer WO, Baisden JL, et al. An evidence-based clinical guideline for the diagnosis and treatment of degenerative lumbar spinal stenosis (update). Spine J 2013;13:734-43.
24. Watters WC, Baisden J, Gilbert TJ, et al. Degenerative lumbar spinal stenosis : an evidence-based clinical guideline for the diagnosis and treatment of degenerative lumbar spinal stenosis. Spine J 2008;8:305-10.
25. Lange T, Schulte TL, Gosheger G, et al. Effects of multilevel posterior ligament dissection after spinal instrumentation on adjacent segment biomechanics as a potential risk factor for proximal junctional kyphosis: A biomechanical study. BMC Musculoskelet Disord 2018;19:4-11.
26. Natarajan RN, Andersson GBJ. Lumbar disc degeneration is an equally important risk factor as lumbar fusion for causing adjacent segment disc disease. J Orthop Res 2017;35:123-30.
27. Bruno AG, Anderson DE, D'Agostino J BM. The effect of thoracic kyphosis and sagittal plane alignment on vertebral compressive loading. J Bone Min Res 2012;27:2144-51.
28. Huang YP, Du CF, Cheng CK, et al. Preserving posterior complex can prevent adjacent segment disease following posterior lumbar interbody fusion surgeries: A finite element analysis. PLoS One 2016;11:1-13.
29. Ma Z, Huang S, Sun J, et al. Risk factors for upper adjacent segment degeneration after multi-level posterior lumbar spinal fusion surgery. J Orthop Surg Res 2019;14:1-7.
30. Broberg K. On the mechanical behaviour of intervertebral discs. Spine (Phila Pa 1976) 1983;8:151-65.
31. Moore RJ. The vertebral endplate: Disc degeneration, disc regeneration. Eur Spine J 2006;15:333-7.
32. Anandjiwala J, Seo JY, Ha KY, et al. Adjacent segment degeneration after instrumented posterolateral lumbar fusion: A prospective cohort study with a minimum five-year follow-up. Eur Spine J 2011;20:1951-60.
33. Sterba M, Aubin C-éric, Wagnac E, et al. Effect of impact velocity and ligament mechanical properties on lumbar spine injuries in posterior-anterior impact loading conditions : a finite element study. Med Biol Eng Comput 2019;57:1381-92.
34. Rohlmann A, Boustani HN, Bergmann G, et al. Effect of a pedicle-screw-based motion preservation system on lumbar spine biomechanics : A probabilistic finite element study with subsequent sensitivity analysis. J Biomech 2010;43:2963-9.
35. Throckmorton TW, Hilibrand AS, Mencio GA, et al. The Impact of Adjacent Level Disc Degeneration on Health Status Outcomes Following Lumbar Fusion. Spine (Phila Pa 1976) 2003;28:2546-50.
36. Bredow J, Löhrer L, Oppermann J, et al. Pathoanatomic Risk Factors for Instability and Adjacent Segment Disease in Lumbar Spine: How to Use Topping Off? Biomed Res Int 2017;2017: 2964529.
37. Bushell GR, Ghosh DP, Taylor TK, et al. The effect of spinal fusion on the collagen and proteoglycans of the canine intervertebral disc. J Surg Res 1978;25:61-9.