Ann Med Res

Current issue list available at AnnMedRes

Annals of Medical Research

journal page: www.annalsmedres.org

Comparison of self-expanding metal stent results in esophagogastrostomy and esophagojejunostomy anastomotic leak: a three-center retrospective analysis

Ali Kemal Kayapinar[a,*], Erkan Oymaci[b], Suleyman Gunay[c], Durmus Ali Cetin[a], Korhan Tuncer[a], Bulent Calik[b], Kemal Erdinc Kamer[a], Mehmet Yildirim[b]

[a] *University of Health Sciences, Izmir Tepecik Training and Research Hospital, Department of General Surgery, Izmir, Türkiye*
[b] *University of Health Sciences, Izmir Bozyaka Training and Research Hospital, Department of General Surgery, Izmir, Türkiye*
[c] *Katip Celebi University, Ataturk Training and Research Hospital, Department of Gastroenterology, Izmir, Türkiye*

ARTICLE INFO

Keywords:
Esophageal cancer
Gastric cancer
Esophageal anastomotic leak
Self-expanding metal stents

Received: Dec 10, 2021
Accepted: Apr 07, 2022
Available Online: June 24, 2022

DOI:
10.5455/annalsmedres.2021.12.653

Abstract

Aim: Our aim was to compare the efficacy and complications of self-expanding metal stents (SEMS) in anastomotic leaks related to esophagogastrostomy (EG) and esophagojejunostomy (EJ).

Materials and Methods: Demographic characteristics, types of surgery, anastomotic leak detection time, clinical findings, diagnostic methods, radiological and endoscopic findings, biochemical findings, efficacy and complications of SEMS, morbidity, and mortality rates of 17 patients who underwent SEMS due to EG (8 cases) or EJ (9 cases) anastomotic leakage after esophageal and gastric tumor resection between 2013 and 2019 were compared. Mann-Whitney U test was used in the analysis of quantitative variables, Fisher Exact and Fisher-Freeman-Holton tests were used in the analysis of categorical variables.

Results: While early term SEMS migration was not observed in the EG group, it was observed in 5 (55.5%) cases in the EJ group (p=0.564). In the EJ group, laceration in the jejunal loop due to SEMS migration was observed in 1 (11.1%) case, and intestinal perforation was observed in 1 (11.1%) case. The amount of anastomotic leakage after SEMS was significantly decreased in the EG group compared to the EJ group (p=0.028). C-reactive protein values were lower and albumin levels were higher in the EG group compared to EJ group (p=0.093, p=0.078, respectively). Mortality was seen in 1 (12.5%) patient in the EG group and in 5 (55.5%) patients in the EJ group (p=0.131). The mean age of those who developed mortality was higher than those who did not (p=0.015).

Conclusion: While SEMS is effective in EG anastomotic leakage, its success rate is low in EJ anastomotic leakage.

Copyright © 2022 The author(s) - Available online at www.annalsmedres.org. This is an Open Access article distributed under the terms of Creative Commons Attribution-NonCommercial-NoDerivatives 4.0 International License.

Introduction

The rate of anastomotic leakage was reported between 8-26% in patients who underwent resection and esophagogastrostomy (EG) for esophageal cancer, and 6-12% in those who underwent total gastrectomy and esophagojejunostomy (EJ) for gastric cancer [1,2]. Until recently, methods such as adequate drainage with reoperation, primary repair of the defect in the anastomosis or redo surgery were used in anastomotic leaks. However, mortality after surgical intervention can be as high as 50% [3-5]. In recent years, technological advancements lead to development of endoscopic minimally invasive interventions (self-expanding metal stents (SEMS), endoscopic clip, endoscopic suture, vacuum assisted therapy (EVT), fibrin glue injection) that close the anastomotic defect and reduce the reoperation rate [3]. Although today, there is no standardized treatment option for esophageal anastomotic leaks, SEMS is the most preferred non-operative method [4-6]. In the literature, the success rate of SEMS in closure of esophageal anastomotic leaks has been reported to vary between 54-77%. However, migration was the most common complication in fully covered SEMS, while tissue embedding was found prevalent in semi-covered SEMS [6,7]. The articles published on the indications and results of endoscopic interventions are limited due to relatively low rate of esophageal anastomotic leakage. Therefore, there is little knowledge about the effectiveness of treatment modalities applied in esophageal anastomotic leaks and no consensus

*Corresponding author:
Email address: alikemalkayapinar@gmail.com (Ali Kemal Kayapinar)

has yet been reached on an effective treatment plan [3,7,8]. There are limited studies comparing the success rate of SEMS in occlusion of EG and EJ anastomotic leaks [6]. Our aim was to compare the efficacy and complications of SEMS used in EG and EJ anastomotic leaks.

Material and Methods

A total of 17 patients whose treatment included SEMS due to esophageal anastomotic leakage in tertiary centers between 2013 and 2019 were included in the study. Eight (47.1%) patients underwent SEMS due to anastomotic leak after partial esophagectomy, proximal gastrectomy and intrathoracic EG for esophageal tumor (EG group) and 9 (52.9%) patients underwent SEMS due to anastomotic leak after total gastrectomy and intra-abdominal EJ anastomosis for gastric tumor and cardioesophageal junction tumor (EJ group). Patients' demographic features, comorbid diseases, tumor localization, neoadjuvant chemoradiotherapy status, type of surgery, tumor stage, clinical findings suggestive of anastomotic leak, diagnostic methods used for the diagnosis of anastomotic leak, endoscopic findings, characteristics of stents, pre-procedural biochemical values, and change in the amount of drained fluid in one hour during 24 hours after SEMS insertion compared to the amount before the procedure, length of hospital stay, complications, and mortality rates were obtained retrospectively from the hospital registry system with the approval of the local ethics committee (decision no: 2019/18-35, date 26.12.2019). Patients with suspected anastomotic leakage were first given methylene blue for diagnostic purposes. Then, oral contrast-enhanced abdominal computed tomography (CT) was performed. This was followed by endoscopy where the size of the defect and the extent of ischemia in the anastomosis loops were evaluated. Of the 17 patients with esophageal anastomotic leaks, 14 (82.4%) underwent fully covered SEMS (Figure 1A) and 3 (17.6%) underwent semi-covered (Figure 1B) SEMS with guided endoscopy. Daily direct radiographs were taken to determine if the SEMS was in place. Endoscopy was repeated when there was no decrease in tube drainage in the area of anastomotic leakage after SEMS or when stent slippage was detected on direct X-ray. After the SEMS was inserted, the records of the amount of fluid from the anastomotic drainage were obtained from daily observation records. When evaluating the SEMS effect, since the fluid from the tube does not come only from the anastomotic leak (reactive fluid), the change in the amount of drainage within 24 hours after SEMS compared to the amount before the procedure was expressed as a percentage. Complications were evaluated as SEMS migration and problems related to SEMS. Deaths due to a sepsis related to anastomotic leakage within the first 30 days before the patient was discharged from the hospital were considered as mortality.

Statistical analyses

SPSS 25.0 program was used in the analysis of the variables. The normal distribution of the data was evaluated with the Shapiro-Wilk francia test, while the homogeneity of variance was evaluated with the Levene test. Independent-Samples T test was used together with the Bootstrap results in the comparison of two independent groups according to quantitative data, while the Mann-Whitney U test was used together with the Monte Carlo results. In the comparison of categorical variables with each other, Fisher Exact and Fisher-Freeman-Holton tests were used with Monte Carlo Simulation technique and column ratios were compared with each other and expressed according to Benjamini-Hochberg corrected p-value results. Quantitative variables were expressed as mean (standard deviation) and median (minimum / maximum) and in the tables, while categorical variables were shown as n (%). Variables were analyzed at 95% confidence level, and p value less than 0.05 was considered significant.

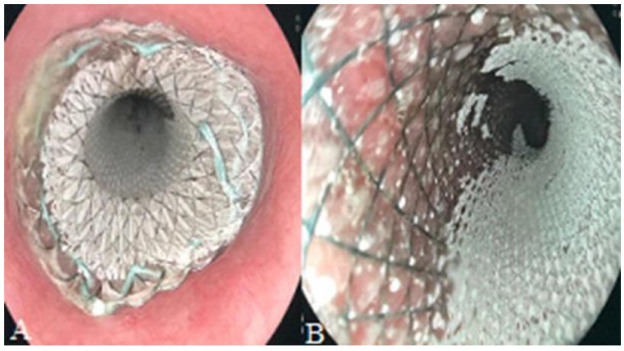

Figure 1. A) Fully covered self-expanding metal stents (SEMS) B) Semi-covered SEMS.

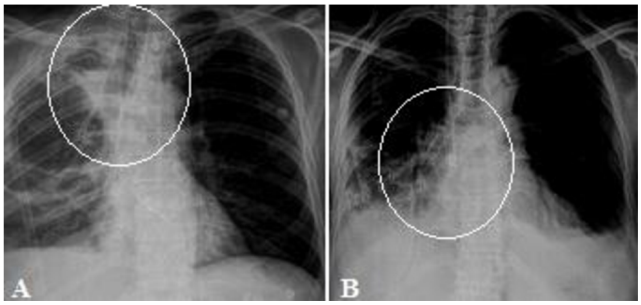

Figure 2. A) Self-expanding metal stents (SEMS) in esophagogastrostomy anastomotic leak B) SEMS in esophagojejunostomy anastomotic leak.

Results

In the study, which included 17 patients who developed esophageal anastomotic failure and underwent SEMS, 10 (58.8%) patients were male and 7 (41.2%) were female. The distribution of patients in terms of tumor localization was as follows: middle esophagus in 4 (23.5%) patients, distal esophagus in 4 (23.5%) patients, cardioesophageal junction in 6 (35.3%) patients, and proximal stomach in 3 (17.6%) patients. Histopathologically, 11 (64.7%) patients had adenocarcinoma and 6 (35.3%) patients had squamous carcinoma. Eight (47.1%) of these patients received neoadjuvant chemoradiotherapy (Table 1). Eight (47.1%) patients had EG anastomotic leakage, and 9 (52.9%) patients had EJ anastomotic leakage. The mean age was 58.00 ± 13.34 years in the EG group and 62.89± 7.25 years in the

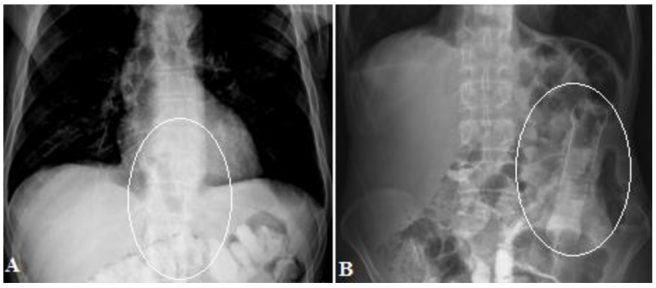

Figure 3. A) Self-expanding metal stents (SEMS) migration in esophagojejunostomy anastomosis B) SEMS migration to the small intestines.

EJ group. There was no significant difference in age between the two groups (p=0.374), (Table 2). Mean time to diagnose a leak was 7.5 (5-19) days in the EG group and 4 (2-10) days in the EJ group. This difference was not significant (p=0.077). The distribution of clinical findings before diagnosis in EG and EJ groups were as follows: deterioration in general condition in 5 (62.5%) patients from the EG group and 6 (66.7%) patients from the EJ group, tachycardia in 6 (75.0%) patients from the EG group and 8 (88.9%) patients from the EJ group, and tachypnea in 4 (50.0%) patients from the EG group and 5 (55.6%) patients from the EJ group. There was no significant difference between the two groups in terms of these parameters (p=0.999) (Table 3). No acute abdomen manifestation was detected in the examination of both groups. In the thoracoabdominal CT performed due to the suspicion of leakage revealed pleural effusion in 6 (75.0%) patients from the EG group and in 8 (88.8%) patients from the EJ group. Parenchymal consolidation was seen in 7 (87.5%) patients in the EG group and in 7 (77.8%) patients in the EJ group. Pneumatic infiltration was detected in 1 (12.5%) patient in the EG group and 7 (77.8%) patients in the EJ group, while free fluid in the abdomen was seen in 1 (12.5%) patient from the EG group and in 4 (44.4%) patients from the EJ group(p>0.05). Among these findings, intraabdominal free fluid and pneumatic infiltration were higher in the EJ group than in the EG group. However, these differences were not significant (p=0.298) (Table 3). Anastomotic leak was detected in 3 (37.5%) patients in the EG group and in 5 (55.5%) patients in the EJ group in the contrast-enhanced oral CT that was performed during the investigations performed for suspected anastomotic leakage. Anastomotic leakage was observed in 3 (37.5%) patients in the EG group and 3 (33.3%) patients in the EJ group, after patients were administered methylene blue. On endoscopy, anastomotic defect was found in 5 (62.5%) patients in the EG group and 6 (66.6%) patients in the EJ group. There was no difference in diagnostic methods between the groups (p=0.999) (Table 3). In the 24-hour evaluation of the drainage amount in the anastomosis site after SEMS placement, no reduction was seen in 3 (33.3%) patients from the EJ group, while there was less than 50% reduction in 5 (55.6) patients and more than 50% reduction in 1 (11.1%) patient. In the EG group, a decrease in drain drainage was observed in 8 (100%) patients. More than 50% reduction was observed in 6 (75%) of these patients, and less than 50% reduction was observed in 2 (25%) of them. The decrease in the leakage rate with SEMS in the EG group was significant compared to the EJ group (p=0.028) (table 3). The hospitalization times of both groups were similar, with 37.5 (21-60) days, 33 (3-61) days for EG and EJ groups, respectively (p= 0.503) (Table 3). No ischemia was observed in the anastomotic loops of any of the patients in endoscopy. In the EJ anastomosis, the size of the defect was <1 cm in 2 (22.2%) patients, while in the rest of the EG and EJ patients the size of the defect was 1-3 cm. While the fully covered SEMS migration was not observed in the EG group, it was seen in 5 (55.5%) patients in the EJ group [Figure 2 (A,B), Figure 3(A,B)]. Complication of the fully covered SEMS developed in 2 (22.2%) patients in the EJ group. One of the complications (11.1%) was perforation in the jejunal loop, and the other (11.1%) was laceration in the intestinal mucosa. There was no significant difference between the two groups in terms of the fully covered SEMS migration and complications (p=0.564) (table 3). In these 2 (22.2%) patients who developed complications, SEMS was fixed to the ear with the fully covered SEMS placement with a silk suture to prevent migration (Shim technique) [9] However, external fixation of the stent did not prevent migration. Shim technique was used in 2 (22.2%) patients from the EJ group. While the patient who developed perforation

Table 1. Patient's characteristics.

	Mean (SD.) Median (min - max)	
Age	60.59 (10.51) 61 (40 - 80)	
		n (%)
Gender		
	Male	10 (58.8)
	Female	7 (41.2)
Tumor location		
	Gastric tumor	3 (17.6)
	Distal esophagus tumor	4 (23.5)
	Cardioesophageal junction tumor	6 (35.3)
	Middle esophagus tumor	4 (23.5)
Type of surgery		
	Esophagogastric anastomosis	8 (47.1)
	Esophagojejunal anastomosis	9 (52.9)
Histological type		
	Adenocarcinoma	11 (64.7)
	Squamous cell carcinoma	6 (35.3)
Comorbidities		
	Diabetes mellitus	8 (38.1)
	Cardio-vascular diseases	6 (28.6)
	Heart diseases	1 (4.8)
	Kidney diseases	1 (4.8)
	Hypertension	5 (23.8)
Neoadjuvant therapy		
	Yes	8 (47.1)
	No	9 (52.9)

SD: Standard Deviation

Table 2. Comparison of patient, tumor and self-expanding metal stents characteristics in esophagogastrostomy and esophagojejunal groups.

		Type of surgery		
		EG (n=8)	EJ (n=9)	p
		mean (SD.)	mean (SD.)	
Age		58.00 (13.34)	62.89 (7.25)	0.374 t
Gender		n%	n%	0.335^{f}
	Male	6 (75.0)	4 (44.4)	
	Female	2 (25.0)	5 (55.6)	
Localization				0.013^{ff}
	Gastric tumor	0 (0.0)	3 (33.3)	
	Distal esophagus tumor	3 (37.5)	1 (11.1)	
	Cardioesophageal junction tumor	1 (12.5)	5 (55.6)	
	Middle esophagus tm	4 (50.0) b	0 (0.0)	
Comorbidities				0.620^{f}
	Absent	3 (37.5)	2 (22.2)	
	Present	5 (62.5)	7 (77.8)	
Histologic type				0.002^{f}
	Adenocarcinoma	2 (25.0)	9 (100.0) a	
	Squamous cell carcinoma	6 (75.0) b	0 (0.0)	
Neoadjuvant therapy				<0.001^{f}
	Absent	0 (0.0)	9 (100.0) a	
	Present	8 (100.0) b	0 (0.0)	
Stage				0.505^{ff}
	I	1 (12.5)	1 (11.1)	
	II	6 (75.0)	4 (44.4)	
	III	1 (12.5)	4 (44.4)	
Length of stent (cm)				0.784^{ff}
	10	5 (62.5)	7 (77.8)	
	12	2 (25.0)	2 (22.2)	
	18	1 (12.5)	0 (0.0)	
Diameter of the stent				0.133^{ff}
	20	3 (37.5)	3 (33.3)	
	22	2 (25.0)	6 (66.7)	
	24	3 (37.5)	0 (0.0)	

t: Independent Samples T Test (Bootstrap), ^{ff}:Fisher Freeman Halton test (Monte Carlo), ^{f}: Fisher Exact Test (Monte Carlo), SD.: Standard deviation, a: Expresses that it is significant compared to the EG group b: Expresses that it is significant compared to the OJ group, EG: esophagogastrostomy; EJ: esophagojejunostomy.

died, SEMS was removed in the patient who developed mucosal laceration. This patient was discharged after 2 months of supportive treatment. It was determined that the stent did not close the anastomotic defect in 2 (25%) patients in the EG group and in 1 (11.1%) patient in the EJ group. In these patients, a new fully covered SEMS was inserted into the previously inserted SEMS to close the defect. After this intervention, it was determined that the amount of drain decreased by more than 50%. No stent complication developed in these patients. Mortality developed in 1 (12.5%) patient from the EG group and in 5 (55.6%) patients from the EJ group. While mortality was higher in the EJ group, this difference was not significant (p= 0.131) (Table 3). One out of 7(87.5%) patients in the EG group that did not develop migration died and in the remaining 5(62.5%) patients, the fully covered SEMS was removed with the help of endoscopy between 4 and 6 weeks later. Since the semi-covered SEMS was embedded in the tissue in the other 2(25%) patients, the stent-in-stent method [10] was used for removal with the help of endoscopy at the 8th and 10th weeks. In 1 of 4 (44.4%) patients who did not develop mortality in the EJ group, the

Table 3. Comparison of clinical and radiological findings in esophagogastrostomy and esophagojejunostomy groups.

		Type of surgery		
		EG (n=8)	EJ (n=9)	
		n%	n%	p
ASA				0.573^{ff}
	II/II	2 (25.0)/3 (37.5)	0 (0.0)/4 (44.4)	
	III/IV	3 (37.5)/0 (0.0)	4 (44.4)/1(11.1)	
Clinical findings				0.999^{ff}
	Deterioration in general condition	5 (62.5)	6 (66.7)	
	Tachycardia	6 (75.0)	8 (88.9)	
	Tachypnea	4 (50)	5 (55.6)	
CT findings				0.298^{ff}
	Bilateral pleural effusion	6 (75.0)	8 (88.8)	
	Pneumatic infiltration	1 (12.5)	7 (77.8)	
	Parenchymal consolidation	7 (87.5)	7 (77.8)	
	Free fluid in the abdomen	1 (12.5)	4 (44.5)	
Anastomotic leak diagnosis				0.999^{ff}
	CT	3 (37.5)	5 (55.5)	
	Methylene blue	3 (37.5)	3 (33.3)	
	Endoscopy	5 (62.5)	6 (66.6)	
Reoperation				0.206^{ff}
	Absent	8 (100.0)	6 (66.7)	
	Present	0 (0.0)	3 (33.3)	
How much did the drain flow decrease after the drain was installed?				0.028^{ff}
	None	0 (0.0)	3 (33.3)	>0.05
	>50%	6(75.0)	1 (11.1)	0,008
	<50%	2 (25)	5 (55.6)	>0.05
SEMS external detection				0.206^{f}
	Absent	8 (100.0)	6 (66.7)	
	Present	0 (0.0)	3 (33.3)	
SEMS complications				0.564^{ff}
	Absent	6 (75.0)	4 (44.4)	
	Migration	0 (0.0)	2 (22.2)	
	Migration+ mucosal laceration	0 (0.0)	1 (11.1)	
	Migration+ perforation	0 (0.0)	1 (11.1)	
	Burial in the mucosa	2 (25.0)	1 (11.1)	
	Stenosis	2 (25.0)	1 (11.1)	
SEMS repositioning				0.279^{ff}
	Absent	6 (75.0)	4 (44.4)	
	Present	0 (0.0)	2 (22.2)	
2^{nd}SEMS placement (nested)		2 (25.0)	1 (11.1)	
SEMS change		0 (0.0)	2(22.2)	
Mortality				0.131^{f}
		7 (87.5)	4 (44.4)	
		1 (12.5)	5 (55.6)	
		Median (min-max)	Median (min-max)	
Suspected anastomotic leak (days)		7.5 (5 - 19)	4 (2 - 10)	0.077^{u}
Time to SEMS application (days)		8 (5 - 20)	7 (3 - 44)	0.999^{u}
Time to SEMS follow up (days)		4 (0 - 10)	2 (0 - 10)	0.414^{u}
Length of hospital stay (days)		37.5 (21 - 60)	33 (3 - 61)	0.503^{u}

^{ff} Fisher Freeman Halton test (Monte Carlo), ^{f} Fisher Exact Test (Monte Carlo), ^{u} Mann Whitney u test (Monte Carlo), EG: esophagogastrostomy; EJ: esophagojejunostomy; SEMS: Self-expanding metal stents.

Table 4. Comparison of biochemical values in esophagogastrostomy and esophagojejunostomy groups.

	Type of surgery		
	EG (n=8)	EJ (n=9)	p
	Mean (SD.)	Mean (SD.)	
WBC (x 103/µl)	14.28 (6.50)	14.23 (6.61)	0.987 [t]
Albumin (g/dl)	2.63 (0.25)	2.33 (0.38)	0.078 [t]
	Median (min-max)	Median (min-max)	
CRP (mg/l)	24.62 (12 - 275)	197 (15 - 440)	0.093 [u]
Procalcitonin (ng/ml)	0.54 (0.09 - 2)	1.04 (0.001 - 28.7)	0.165 [u]
Urea (mg/dl)	31 (16 - 64)	37 (19 - 289)	0.324 [u]
Creatinine (mg/dl)	0.725 (0.4 - 1)	0.9 (0.45 - 2.8)	0.131 [u]

[t] Independent Samples T Test (Bootstrap), [u] Mann Whitney u test (Monte Carlo), EG: esophagogastrostomy; EJ: esophagojejunostomy; CRP: C-reactive protein; WBC: white blood cell.

fully covered SEMS was removed early by endoscopy due to mucosal laceration. In 1 of the other 2 patients, the fully covered SEMS was removed with the help of endoscopy at 6 weeks before discharge. In the other, fully covered SEMS migrated out of the anal canal. In 1(11.1%) patient, the semi-covered SEMS was embedded in the tissue and thus was removed by the stent-in-stent method at the 10th week. In both groups, anastomotic stenosis developed in 3 (17.6%) patients who had embedded the semi-covered SEMS. Endoscopic balloon dilatation was performed in patients who developed anastomotic stenosis. The evaluation of pre-procedure blood biochemistry results indicated that albumin was higher and C-reactive protein was lower in the EG group compared to EJ group (p= 0.078, p= 0.093) (Table 4). However, this difference was not significant. Other biochemical values are summarized in the Table 4. The mean age of patients who developed mortality was 68.67± 8.43 years. The mean age of those who did not develop mortality was lower with 56.18 ± 8.99 years. This difference was significant (p= 0.015). It was observed that the patient, tumor and stent characteristics had no effect on the development of mortality. These features are summarized in Table 5.

Discussion

Mortality after surgical intervention is high in upper gastrointestinal anastomotic leaks. Since the use of SEMS in this group of patients decreases the mortality and length of hospital stay compared to surgical intervention, its use is increasing [3]. However, the effectiveness of SEMS in esophageal anastomotic leakage has not been clarified. In our study, while SEMS was effective in controlling EG anastomotic leakage, the success rate in controlling EJ anastomotic leakage was found to be low. In the study of Bohle et al. [11], the success rate of SEMS in esophageal anastomotic leakage was 76% and the mortality was 20%. In our study, the success rate in esophageal anastomotic leakage was 64.8% and the mortality rate was 35.2%. While the mortality rate was 12.5% in the EG group, it was 55.6% in the EJ group. In addition, while SEMS was 87.5% successful in the EG group, the success rate was 33.3% in the EJ group. Although this difference was not significant, it is seen that the success is higher in the EG group. After the insertion of SEMS, more than 50% reduction in the amount of leakage was seen in 75% of EG group and in 11.1% of the EJ group. In addition, no significant difference was observed in clinical findings and radiological images in both groups. However, although not significantly different, thoracic CT revealed that pneumonic infiltration was seen in 77.8% of the EJ group, which was higher than that of the EG group (12.5%). These findings suggest that SEMS is more effective in closing the EG anastomotic defect than in closing the EJ anastomotic

Table 5. Comparison of patient, tumor and self-expanding metal stents characteristics in patients who did and did not develop mortality.

	Alive (n=11)	Exitus (n=6)	p
Age, mean (SD.)	56.18 (8.99)	68.67 (8.43)	0.015 [t]
Gender, n(%)			0.162 [f]
Male	8 (72.7)	2 (33.3)	
Female	3 (27.3)	4 (66.7)	
Localization			0.825 [ff]
Gastric tumor	2 (18.2)	1 (16.7)	
Distal esophagus tumor	3 (27.3)	1 (16.7)	
Cardioesophageal junction tumor	3 (27.3)	3 (50.0)	
Middle esophagus tumor	3 (27.3)	1 (16.7)	
Surgery type			0.131 [f]
OG	7 (63.6)	1 (16.7)	
OJ	4 (36.4)	5 (83.3)	
Comorbidities			0.600 [f]
Absent	4 (36.4)	1 (16.7)	
Present	7 (63.6)	5 (83.3)	
Histologic type			0.333 [f]
Adenocarcinoma	6 (54.5)	5 (83.3)	
Squamous cell carcinoma	5 (45.5)	1 (16.7)	
Neoadjuvant therapy			0.131 [f]
Absent	4 (36.4)	5 (83.3)	
Present	7 (63.6)	1 (16.7)	
Stage			0.810 [ff]
I	2 (18.2)	0 (0.0)	
II	6 (54.5)	4 (66.7)	
III	3 (27.3)	2 (33.3)	
Stent length (cm)			0.235 [ff]
10	6 (54.5)	6 (100.0)	
12	4 (36.4)	0 (0.0)	
18	1 (9.1)	0 (0.0)	
Stent diameter (cm)			0.107 [ff]
20	5 (45.5)	1 (16.7)	
22	3 (27.3)	5 (83.3)	
24	3 (27.3)	0 (0.0)	

[t] Independent Samples T Test (Bootstrap), [ff] Fisher Freeman Halton test (Monte Carlo), [f] Fisher Exact Test (Monte Carlo).

defect. As a result, this effect may have decreased development of pulmonary pneumatic infiltration in the EG group. In our study, the time before the leak was detected in the EG group was approximately twice that of the EJ group. Despite this, mortality and complication rates were lower in the EG group compared to the EJ group. Leakage fluid drains more easily in intrathoracic anastomosis, because in the thorax there are not many cavities and organs to trap the fluid as in the abdomen. These findings explain the later development of intrathoracic anastomotic leak clinic compared to intra-abdominal anastomotic leak. On the other hand, since the EG anastomosis forms a continuous tube, the SEMS is surrounded by the esophagus and jejunum in all 360 degrees. This may have caused complete closure of the anastomotic leak and a decrease in the migration rate. On the other hand, the gap in the jejunal conduit region in the EJ prevents the SEMS from 360-degree wrapping without interruption. In addition, as SEMS bends (concave) as it passes from the esophagus to the jejunum, it causes a gap in the corner of the anastomosis. This may have caused high SEMS migration rate and the stent not able to fully close the opening. On the other hand, if the fluid escaping into the abdomen in the intra-abdominal anastomosis is not adequately drained, the fluid is dispersed between the organs and in the intra-abdominal spaces. In the early postoperative period, most of the fluid is absorbed by the omentum and peritoneum. Therefore, in the early period, collection may not occur in the abdomen. As a result, it may delay the detection of the leak. In our study, it was observed that intraabdominal free fluid collection was not a finding that strengthened the diagnosis in EJ anastomotic leakage. Similarly, Makuuchi et al. [5] stated that the abdominal findings in EJ anastomotic leaks are faint, which supports our hypothesis. On the other hand, Hoeppner et al.'s [6] study does not align with our study regarding the effectiveness of SEMS in EJ and EG anastomotic leaks. They suggested that the high intra-abdominal pressure reduces the leakage by wrapping the surrounding organs around the intra-abdominal anastomosis. In our study, it was observed that high pressure in the abdominal organs and abdomen did not reduce the risk of anastomotic leakage. Despite the use of SEMS in anastomotic leakage, clinical and laboratory improvement did not occur in 1 (12.5%) patient in the EG group and in 5 (55.6%) patients in the EJ group. These patients died as a result of multiple organ failure. It was observed that SEMS did not close the leak site in EJ anastomotic leakage and SEMS migration developed in the early period. In addition, with the expectation that SEMS will close the anastomotic leak, the chance of early surgical intervention may be missed. In our study, it was determined that the mean age of patients who developed mortality was higher than those who did not develop mortality. Elderly patients seem to be more affected by this condition. In early surgical intervention, intra-abdominal washing can reduce the bacterial load on the peritoneal face and abdominal cavities due to leakage [3]. Thus, the pathway to sepsis can be prevented. Due to the few clinical studies on esophageal anastomotic leakage and the lack of randomized controlled studies, a standard treatment protocol for esophageal anastomotic leakage has not been established [5]. It is important to have adequate drainage in esophageal anastomotic leaks. Therefore, it is recommended that drains be placed close to the EJ anastomosis area [3,5]. Previous studies and our study highlight the importance of ensuring adequate drainage in the abdomen and to maintain clinical stability in intra-abdominal EJ anastomotic leakage. Otherwise, endoscopic interventions may not be effective. Studies have reported SEMS migration rate to vary between 19-53% and mortality rate to vary between 0-28% [3, 6, 12-14]. Esophagotracheal fistula, intestinal perforation, pulmonary artery and thoracic aorta erosion due to intrathoracic SEMS have been reported [15-17]. In Feith et al.'s study, SEMS migration was seen in 49% of EG and 61% of EJ cases. They also reported that intestinal obstruction due to SEMS migration developed in 3% and intestinal perforation developed in 1%. Moreover, the rate of anastomotic stenosis was 12%, while the mortality rate was 9% [13]. In our study, while SEMS migration was not observed in the EG anastomosis, it was observed at a rate of 44.4% in the EJ anastomosis, with 11.1% mucosal laceration due to SEMS migration, 11.1% SEMS perforation and 11.1% mortality. It was determined that anastomotic stenosis, which was seen at a rate of 17.6%, developed after the embedding of the semi-covered stents. In our study, the Shim technique was used to prevent SEMS migration in two patients with EJ anastomotic leakage [9]. Although SEMS was fixed to the ear in both patients, it was observed that it did not prevent migration and the suture broke in one patient. SEMS-related perforation and mucosal laceration developed in 2 cases in which the stent was externally fixed. This result may be due to insufficient SEMS control due to the expectation that external fixation will prevent migration. Choi et al. [18] reported that Shim technique prevented SEMS migration at 100%. In the literature, it has been observed that methods such as an over-the-scope clip (OTSC), semi-covered SEMS, and endoluminal suture reduce SEMS migration but do not fully prevent it [19-21]. In another study, SEMS was fixed to the esophagus and intestine with full-thickness sutures in 4 patients who developed sepsis and SEMS did not migrate in any of these patients and all of them recovered [22]. As seen in Feith et al. 's [13] and our study, SEMS migration is more common in the EJ anastomosis and serious complications may develop due to migration. These results suggest that suturing SEMS to full-thickness tissue, especially in the EJ anastomosis, can prevent SEMS migration. In the literature, it has been found that the sensitivity of CT with oral contrast is low in detection of gastrointestinal anastomotic leaks [23]. It was also low in our study (46.1%). Combining oral methylene blue and endoscopic examination increased the diagnosis rate to 100% in our study. Studies have found elevated leukocyte and C-reactive protein levels to support clinical uncertainty seen in esophageal anastomotic leaks [24,25]. In our study, the CRP value was higher in the EJ group compared to the EG group. Albumin has an independent predictive value for morbidity in the evaluation of critically ill patients [26]. In our study, the albumin value in EG group was higher, albeit not significantly, compared to EJ group. When all results are evaluated, it is seen that the inflammatory process is

more severe in the EJ group. While clinical symptoms specific to esophageal anastomotic leaks have not been clarified in the literature, tachycardia, tachypnea, and fever findings are emphasized in some studies [3-5,27]. Similarly, in our study, tachycardia and tachypnea were early and common clinical signs in both EG and EJ anastomotic leakage. Limitations of our study are the retrospective nature of the study and the small number of patients. In conclusion, in our study, tachycardia and tachypnea came to the forefront as clinical findings in intrathoracic and intra-abdominal esophageal anastomotic leaks. Radiologically, pleural effusion and parenchymal consolidation were commonly observed. While SEMS was effective in intrathoracic anastomotic leakage, it did not completely close the defect in intra-abdominal EJ anastomotic leakage. The misconception that SEMS closes the anastomosis may cause the chance of surgical intervention to be lost. SEMS migration is the most common complication and the effectiveness of the techniques used to prevent migration is low.

Ethics approval

Ethical approval was obtained for this study from the non-interventional ethics committee of the University of Health Sciences, Izmir Tepecik Health Practice Research Center (decision no: 2019/18-35, date 26.12.2019).

References

1. Blencowe NS, Strong S, McNair AG, et al. Reporting of short-term clinical outcomes after esophagectomy: a systematic review. Annals of surgery. 2012; 255(4) : 658-666.
2. Lang H, Piso P, Stukenborg C, Raab R, Jähne J. Management and results of proximal anastomotic leaks in a series of 1114 total gastrectomies for gastric carcinoma. European journal of surgical oncology. 2000; 26(2): 168-171.
3. Cereatti F, Grassia R, Drago, A, Conti CB, Donatelli G. Endoscopic management of gastrointestinal leaks and fistulae: What option do we have? World Journal of Gastroenterology. 2020; 26(29): 4198–4217.
4. Siddiqi S, Schraufnagel DP, Siddiqui HU, et al. Recent advancements in the minimally invasive management of esophageal perforation, leaks, and fistulae. Expert review of medical devices. 2019; 16(3):197-209.
5. Makuuchi R, Irino T, Tanizawa Y, et al. Esophagojejunal anastomotic leakage following gastrectomy for gastric cancer. Surgery today. 2019; 49(3): 187-196.
6. Hoeppner J, Kulemann B, Seifert G, et al. Covered self-expanding stent treatment for anastomotic leakage: outcomes in esophagogastric and esophagojejunal anastomoses. Surgical endoscopy. 2014; 28(5): 1703-1711.
7. Persson S, Rouvelas I, Kumagai K, et al. Treatment of esophageal anastomotic leakage with self-expanding metal stents: analysis of risk factors for treatment failure. Endoscopy international open. 2016; 4(04): E420-E426.
8. Verstegen MH, Bouwense SA, van Workum F, et al. Management of intrathoracic and cervical anastomotic leakage after esophagectomy for esophageal cancer: a systematic review. World Journal of Emergency Surgery. 2019; 14(1): 1-12.
9. Shim CS, Cho YD, Moon JH, et al. Fixation of a modified covered esophageal stent: its clinical usefulness for preventing stent migration. Endoscopy. 2001; 33(10): 843-848.
10. Swinnen J, Eisendrath P, Rigaux J, et al. Self-expandable metal stents for the treatment of benign upper GI leaks and perforations. Gastrointestinal endoscopy. 2011; 73(5): 890-899.
11. Bohle W, Louris I, Schaudt A, et al. Predictors for Treatment Failure of Self-Expandable Metal Stents for Anastomotic Leak after Gastro-Esophageal Resection. Journal of Gastrointestinal & Liver Diseases. 2020; 29(2): 145-149.
12. Swinnen J, Eisendrath P, Rigaux J, et al. Self-expandable metal stents for the treatment of benign upper GI leaks and perforations. Gastrointestinal endoscopy. 2011; 73(5): 890-899.
13. Feith M, Gillen S, Schuster T, et al. Healing occurs in most patients that receive endoscopic stents for anastomotic leakage; dislocation remains a problem. Clinical Gastroenterology and Hepatology. 2011; 9(3): 202-210.
14. Fischer A, Bausch D, Richter-Schrag HJ. Use of a specially designed partially covered self-expandable metal stent (PSEMS) with a 40-mm diameter for the treatment of upper gastrointestinal suture or staple line leaks in 11 cases. Surgical endoscopy. 2013; 27(2): 642-647.
15. Speer E, Dunst CM, Shada A, et al. Covered stents in cervical anastomoses following esophagectomy. Surgical endoscopy. 2016; 30(8): 3297-3303.
16. Licht E, Markowitz AJ, Bains MS, et al. Endoscopic management of esophageal anastomotic leaks after surgery for malignant disease. The Annals of thoracic surgery. 2016; 101(1): 301-304.
17. Schaheen L, Blackmon SH, Nason KS. Optimal approach to the management of intrathoracic esophageal leak following esophagectomy: a systematic review. The American Journal of Surgery. 2014; 208(4): 536-543.
18. Choi CW, Kang DH, Kim HW, et al. Full covered self-expandable metal stents for the treatment of anastomotic leak using a silk thread. Medicine. 2017; 96(29): e7439.
19. Irani S, Baron TH, Gluck M, et al. Preventing migration of fully covered esophageal stents with an over-the-scope clip device (with videos). Gastrointestinal endoscopy. 2014; 79(5): 844-851.
20. John A, Chowdhury SD, Kurien RT, et al. Self-expanding metal stent in esophageal perforations and anastomotic leaks. Indian Journal of Gastroenterology. 2020; 39(5): 445-449.
21. Law R, Prabhu A, Fujii-Lau L, et al. Stent migration following endoscopic suture fixation of esophageal self-expandable metal stents: a systematic review and meta-analysis. Surgical endoscopy. 2018; 32(2): 675-681.
22. Raimondo D, Sinagra E, Facella T, et al. Self-expandable metal stent placement for closure of a leak after total gastrectomy for gastric cancer: report on three cases and review of the literature. Case reports in gastrointestinal medicine. 2014; 2014:1-5.
23. Aday U, Gündeş E, Çiyiltepe H, et al. Examination of anastomotic leak with aqueous contrast swallow after total gastrectomy: Should it be carried out routinely?. Contemporary oncology. 2017; 21(3): 224–227.
24. Migita K, Takayama T, Matsumoto S, et al. Risk factors for esophagojejunal anastomotic leakage after elective gastrectomy for gastric cancer. Journal of Gastrointestinal Surgery. 2012; 16(9): 1659-1665.
25. Tu RH, Lin JX, Zheng CH, et al. Development of a nomogram for predicting the risk of anastomotic leakage after a gastrectomy for gastric cancer. European Journal of Surgical Oncology (EJSO). 2017; 43(2): 485-492.
26. Yu Y, T Liu J, Hu B, et al. Expert consensus on the use of human serum albumin in critically ill patients. Chinese Medical Journal. 2021; 134(14): 1639–1654.
27. Isik A, Firat D, Peker K, et al. A case report of esophageal perforation: Complication of nasogastric tube placement. The American journal of case reports. 2014; 15: 168.