Ann Med Res 2020;28(1):215-20

Annals of Medical Research

DOI: 10.5455/annalsmedres.2020.05.507

Original Article

Surgical and clinical management of neutropenic enterocolitis seen in hematological and solid organ malignancies

Server Sezgin Uludag[1], Emre Tunc[1], Ahmet Necati Sanli[1], Tugrul Elverdi[2], Mehmet Velidedeoglu[1], Osman Simsek[1], Salih Pekmezci[1], Abdullah Kagan Zengin[1]

[1]Department of General Surgery, Cerrahpasa Medical Faculty, Istanbul University-Cerrahpasa, Istanbul, Turkey
[2]Department of Hematology, Cerrahpasa Medical Faculty, Istanbul University-Cerrahpasa, Istanbul, Turkey

Copyright@Author(s) - Available online at www.annalsmedres.org
Content of this journal is licensed under a Creative Commons Attribution-NonCommercial 4.0 International License

Abstract

Aim: Ileocecal syndrome also called typhilite; It is defined as inflammation of the cecum and surrounding tissues seen in immunosuppressed patients. Typhilite is a serious disease in the ileum, cecum, and ascending colon with segmental inflammation and necrosis due to ulceration. The disease has difficulties in its diagnosis, treatment, and surgery. We aimed to examine the difficulties in diagnosis and treatment in this disease, which has high morbidity and mortality.

Materials and Methods: Patients who have hematological or solid organ malignancies, diagnosed with neutropenic enterocolitis between January 2014 and December 2019 were included in the study. The demographic information, malignancies, chemotherapy treatments, follow-ups, clinical symptoms, laboratory, and radiology findings of the patients were examined.

Results: A total of 7 patients were identified between the dates indicated, 4 were male and 3 were female. The mean age was 58.5. Six of these patients had hematological and one had solid organ malignancy. All patients had the typical fever (above 38), non-migratory abdominal pain localized to the right lower quadrant, and neutropenia (<0.5 x10³/mm³). The mean value of Neutrophil at the time symptoms began was 0.15x10³/mm³. Intestinal wall thickening, mesenteric inflammation findings were present in all patients, and pneumocystis intestinalis and perforation were detected in one patient. As presented patients, with increased experience, most of the patients were demonstrated to be treated with consisting of aggressive fluid resuscitation, correction of electrolyte imbalance, bowel rest, and wide-spectrum antibiotics. Two patients died due to severe fungal infection.

Conclusion: It is hard to make a common algorithm for diagnosis for NE because NE is a pre-diagnosis. Due to its clinical heterogeneity, treatment modality ranges from surgical treatment to conservative approach. As a result of higher success rates of conservative management, supportive care, and close follow up have replaced surgery in the treatment of this disease.

Keywords: Chemotherapy; ileocecal syndrome; neutropenia; neutropenic enterocolitis; surgery; typhilite

INTRODUCTION

Ileocecal syndrome which is also known as typhlitis is defined as neutropenic enterocolitis (NE) seen in immunosuppressed patients. Although its true incidence is not known (1), a systematic review in 2005 suggested its incidence as 5.6% in patients with solid organ and hematological malignancies (2). The incidence was found as 10-24% in the autopsies of children who died due to acute leukemia (3,4).

Typhlitis is one of the gastrointestinal complications which have high mortality in neutropenic patients. This severe complication of neutropenia with necrosis at ileum, cecum and ascending colon due to segmental inflammation and ulceration (2) was first described in the leukemic pediatric patients. The cecum is frequently involved in NE patients, and ascending colon and descending colon may also be affected depending on the extent of the disease (4,5).

Although its pathogenesis is not fully elucidated, NE is thought to be due to bacterial translocation associated with neutropenia and mucosal injury in immunosuppressed patients (5,6). Gram-negative rods, gram-positive cocci, enterococci, fungi, and viruses are frequently detected in the damaged mucosa although this is not considered as a diagnostic criterion.

Chemotherapeutic agents can cause mucosal injury, intestinal distention and necrosis. So they can change intestinal motility. Its pathogenesis may include mucosal or full-thickness edema, focal hemorrhage, and necrosis (4).

Received: 19.05.2020 **Accepted:** 23.11.2020 **Available online:** 27.01.2021
Corresponding Author: Server Sezgin Uludag, Department of General Surgery, Cerrahpasa Medical Faculty, Istanbul University-Cerrahpasa, Istanbul, Turkey **E-mail:** sszgn.uludag@gmail.com

Chemotherapeutic agents with cytotoxic effects may cause complications by affecting the epithelia of the gastrointestinal system. NE cases may be detected firstly due to Taxane drugs, also frequently due to treatment with cytosine arabinoside (ARA-C) (1,5), gemcitabine, vincristine, anthracyclines, (doxorubicin, daunorubicin), cyclophosphamide, methotrexate, prednisone, and nafcillin treatments. NE cases become symptomatic generally 10-14 days after the chemotherapy regime (1,5,8).

The disease clinic involves right lower quadrant pain and fever which may be accompanied frequently by nausea and vomiting. Peritoneal irritation findings and sepsis may also occur. Intestinal perforation should be considered in NE patients when these findings present. Differential diagnosis of the disease includes appendicitis, pseudo-obstruction of the colon, inflammatory bowel disease, infectious colitis, pseudomembranous enterocolitis, and diverticulitis (1).

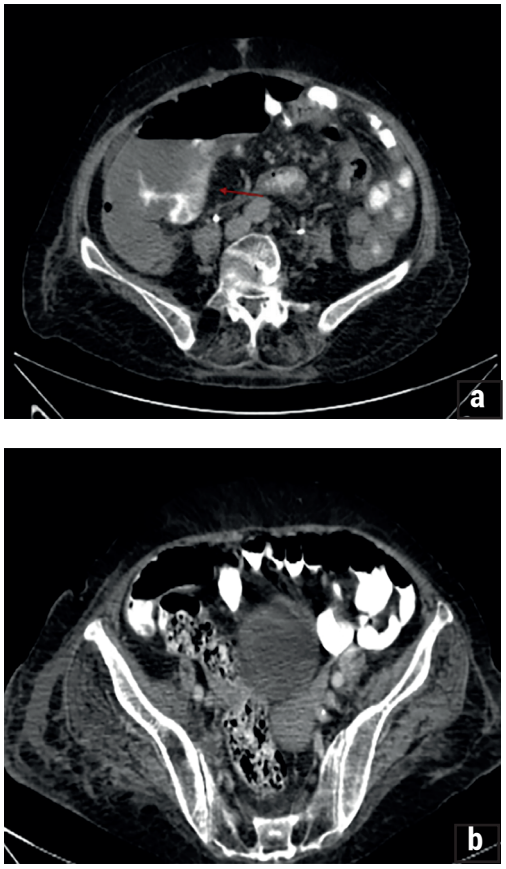

Figure 1. a,b. Dilatation and mesenteric contamination starting from distal ileal loops

The diagnosis is made with diagnostic imaging studies performed following high clinical suspicion. Ultrasonography (USG) is helpful to rapidly exclude other diagnoses in the pathogenesis of NE such as appendicitis, cholecystitis, pancreatitis, and intussusception. Increased bowel wall thickness, mesenteric contamination, cecal dilatation, and pneumatosis in computed tomography (CT) are the main radiological findings of NE (Figure 1a, 1b) (10). The exact diagnosis is made by pathological confirmation but it may be observed in surgeries and autopsies. Wade et al (5) pathologically detected NE only in 53% of 22 patients who were diagnosed clinically.

Treatment options with a mortality rate up to 50% due to intestinal perforation and sepsis, include a wide spectrum from nonsurgical follow-up to surgery (1,4,8,10).

The aim of this study is to examine the primary oncological diagnosis, imaging findings, neutropenia level and duration, and treatment methods as well as demographic, clinical and laboratory features of patients diagnosed with NE.

MATERIALS and METHODS

Patients diagnosed with NE between January 2014 and December 2019 and followed with hemaotology / oncology and general surgery consensus were included in the study. All patients had known malignancies. All patients had known malignancies and all received chemotherapy. Clinical symptoms (fever, abdominal pain, hematochezia), physical examination findings, laboratory findings and abdominal CT features were evaluated. In addition, other causes of acute abdomen (appendicitis, pancreatitis, etc.) were excluded from the examination findings and radiologically. Blood (ELISA) and / or stool (Toxin A / B) were sampled from all patients for *Clostridium difficile* exclusion. During follow-up, hemogram and arterial blood gas samples were routinely examined. Patients who were clinically progressed and developed sepsis continued their follow-up and treatment in the intensive care unit. The primary hematogic-oncological treatments of the patients who became asymptomatic were continued. Descriptive statistical methods (mean, standard deviation, median, frequency, ratio, minimum, maximum) were used when evaluating the study data.

RESULTS

A total of 7 cases, 4 males and 3 females, were included in this study. The average age of our patients diagnosed with NE was 58.5 years (min: 40, max: 67). Three of the patients were receiving chemotherapy for lymphoma, two for leukemia, one for myelodysplastic syndrome and one for ovarian carcinoma. Six of these patients had hematological and one had solid organ malignancy. Fever, abdominal pain, and hematochezia were considered significant in terms of NE. NE symptoms appeared on average 6.7±2.4 days (min:3, max:11 days) after starting chemotherapy. The demographic characteristics, diagnoses, symptoms, laboratory findings and culture samples of the patients are detailed in Table 1.

All patients had typical fever (above 38), non-migratory abdominal pain localized to the right lower quadrant and neutropenia (<0.5 x10^3 / mm^3). In addition to these symptoms, hematochezia was present in three cases. The mean value of Neutrophil at the time symptoms began was 0.15 x10^3 / mm^3 (min: 0.1 x10^3, max: 0.4 x10^3 / mm^3) In addition, all patients had leukopenia (<15x10^3 / mm^3), thrombocytopenia (<55x10^3 / mm^3) and anemia. *Clostridium Difficile* Toxin A-B was not detected in stool samples of any patients.

Table 1. Demographic features and oncological data of the patients

	Age	Gender	BMI	Diagnosis	Chemotherapy	Culture	Neutrophil value when symptoms begin	Symptoms	Starting date of symptoms (after chemotherapy)	G-CSF
Case 1	67	F	28,9	Diffuse B cell lymphoma	CODOX-M	Acinetobacter spp(urineculture)	0,1 x10³ /mm³	Fever, abdominal pain	10th day	+
Case 2	40	M	25,4	Diffuse B cell lymphoma	R-SHOP	Gr (+) diplococcus (urine culture)	0,1 x10³ /mm³	Fever, abdominal pain, hematochezia	8th day	+
Case 3	60	F	27,8	Myelodysplastic syndrome	ARA-C and idarubicin	Viridans streptococci (blood culture)	0,4 x10³ /mm³	Fever, abdominal pain	3rd day	+
Case 4	67	M	29,6	AML-M4	Cytarabine and idarubicin	S.haemolyticus, E. faecium (Endotracheal aspirate)	0,1x 10³ /mm³	Fever, abdominal pain, hematochezia, tachypnea	6th day	+
Case 5	63	M	24,5	Diffuse B cell lymphoma	R-SHOP	culture negative	0,1x 10³ /mm³	Fever, abdominal pain	3rd day	+
Case 6	54	F	29,4	Ovarian carcinoma	Paclitaxel	culture negative	0,2x 10³ /mm³	Fever, abdominal pain	6th day	+
Case 7	59	F	33,3	AML-M2	Cytarabine and idarubicin	E.faecium (blood culture)	0,1x 10³ /mm³	Fever, abdominal pain, hematochezia,	11th day	+

R-CHOP: Rituximab, Cyclophosphamide, Doxorubicin, Vincristine, Prednisone, CODOX-M: Cyclophosphamide, Vincristine, Doxorubicin, Methotrexate

Ultrasound (US) scanning and computed tomography (CT) were performed to the patients for diagnosis. Pathologies detected in patients on CT imaging; intestinal wall thickening (n: 7), mesenteric inflammation findings (n: 7), pneumotosis intestinal (n: 1) and perforation (n: 1) (Figure 2a,2b). The mean wall thickness of the cecum was 10.5 mm (min: 6, max: 14) in patients (Figure 3a,3b).

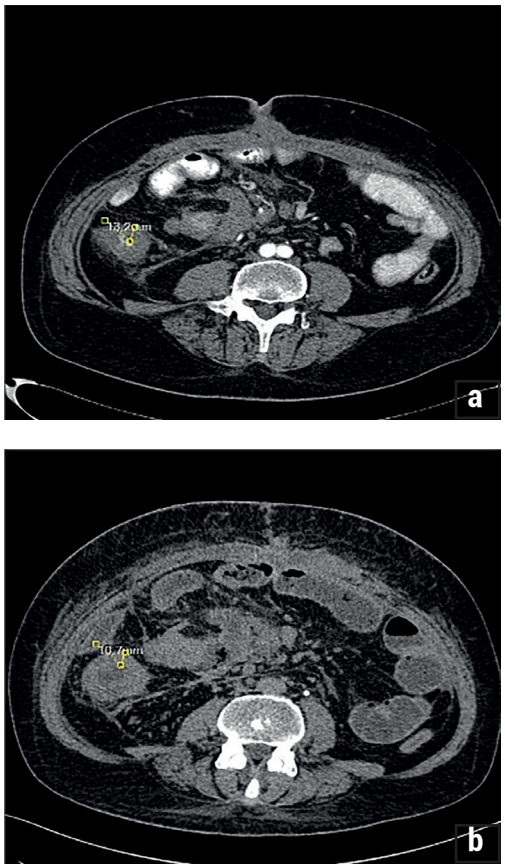

Figure 2. a,b. Increased wall thickness at terminal ileum and cecum

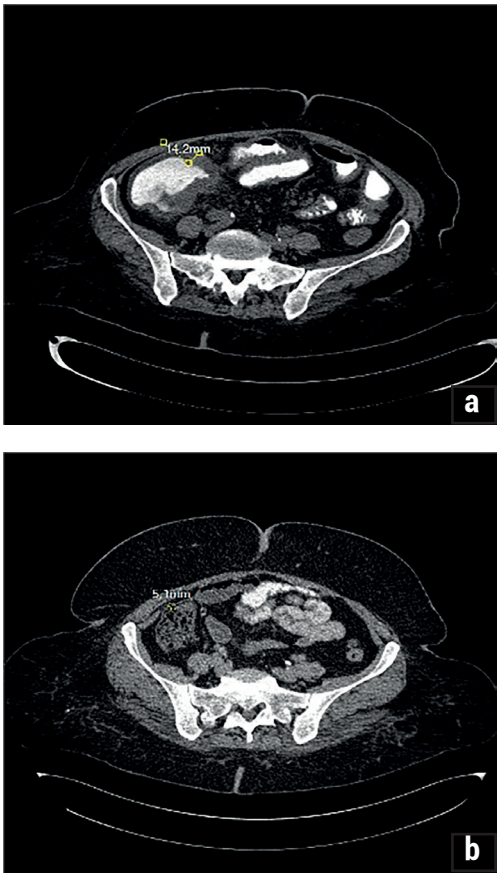

Figure 3. a,b. Contamination around cecum, ascending colon, and at mesentery and a caecal wall thickness of 6 mm

Conservative treatment was applied in six of the patients. Broad spectrum antibiotics, total parenteral nutrition, transfusion and granulocyte colony stimulating factor (G-CSF) were used in the treatment. Anaerobic antibiotherapy was given in all cases. The treatment and CT image features of the patients are explained in detail in Table 2. The transition time of the living cases to the

asymptomatic period was an average of 8.4 days (min: 4, max:13), and it took an average of 23.8 days (min:13, max:47) to return to their oncological treatment (Table 2).

Only one case was operated due to the development of peritonitis and its general condition. Ileocecal resection, abdominal washing, and double-barrel ostomy procedures were applied to the patient. In the thorax tomography taken on the second day of the follow-up of the patient, who was taken to the intensive care unit after the operation, a severe fungal infection image was detected. The patient died on the sixth postoperative day due to sepsis and severe fungal infection. The patient died on the sixth postoperative day due to sepsis and severe fungal infection. One of the patients who were followed up conservatively died in the intensive care unit due to severe fungal infection in the lung and multi-organ failure.

Table 2. Follow-up, treatment and radiological data of patients

	Age	Sex	Atibiotherapy	Becoming asymptomatic	Starting chemotherapy again	CT findings	Cecum wall thickness (mm)	Complication	Mortality
Case 1	67	F	Piperacillin-Tazobaktam,	13th day	47th day	Cecum and terminal ileum wall thickening, mesenteric edema	11 mm		No
Case 2	40	M	Metronidazole	12th day	25th day	Cecum and terminal ileum wall thickening, mesenteric edema	14 mm		No
Case 3	60	F	Piperacillin-Tazobaktam, Metronidazole	4th day	16th day	Cecum and terminal ileum wall thickening, mesenteric edema	6 mm		No
Case 4	67	M	Piperacillin-Tazobaktam, Metronidazole	-	-	Cecum and terminal ileum wall thickening, mesenteric edema	9 mm	Sepsis, fungal infection in the lung	Yes
Case 5	63	M	Meropenem, Teicoplanin, Amphotericin B	6th day	13th day	Cecum and terminal ileum wall thickening, mesenteric edema	12 mm		No
Case 6	54	F	Piperacillin-Tazobaktam, Metronidazole	7th day	18th day	Cecum and terminal ileum wall thickening, mesenteric edema	11 mm		No
Case 7	59	F	Tigecycline	-	-	Pneumostasis intestinalis in ascending colon, perforation	11 mm	Sepsis, fungal infection in the lung	Yes

DISCUSSION

Symptoms occur due to an inadequate inflammatory response with neutropenia and leukopenia. NE patients usually become symptomatic 2 weeks after the initiation of the chemotherapeutic agent (1,5,8). In the presented cases, the patients became symptomatic on the first 8 days of the chemotherapy regimens.

Although some authors have demonstrated *Clostridium difficile* toxin in stool samples when disease symptoms become prominent (10), we couldn't demonstrate toxin A or B in the stool during the symptomatic period. Song et al (8) sent stool samples for *Clostridium difficile* toxin test for 14 patients and the results were negative in 9 of them. Blood culture results were positive for Escherichia coli in 2 patients. Piperacillin-tazobactam which also has anaerobic efficiency can be initiated. Antibiotherapy choice is regulated due to culture results. When *Clostridium difficile* can't be excluded, metronidazole or vancomycin should be added to the treatment regime (11). Initial empirical treatment for fungal agents is not routinely recommended but they may be considered when the response to treatment is not adequate (11).

No growth was detected in blood cultures of our patients. *S.haemolyticus* and *E.faecium* growths were observed in endotracheal aspiration fluid only in the last patient. This patient died on the 10th day of intensive care unit stay.

As the presented cases were clinically stable and their differential diagnoses were wide, CT was performed for diagnostic purposes. Mortality in patients whose bowel wall thickness is more than 10 mm in CT is approximately 10 %, while it reduces to 4.2 % in patients who have bowel wall thickness less than 10 mm. (1). Patients whose cecum wall thickness is more than 10 mm may benefit from surgical treatment (12). More than 10 mm bowel wall thickness in ultrasonography is a poor prognostic sign (3,5). It should be kept in mind that USG may help CT during follow-up. Cecum wall thickness was 14 mm only in the second patient and the treatment response of the patient was adequate. He continued chemotherapy without a need for laparotomy.

Pneumatosis intestinalis is a CT image specific to ischemic colitis and typhlitis (1). Increased bowel wall thickness and mesenteric contamination were observed in all patients, but pneumatosis intestinalis was not detected in any of them (Figure 4a,4b,4c).

It is impossible to form international guidelines of treatment strategies as there is lack of multicentric randomized prospective studies (1).

In the light of gaining higher success rates of conservative management, surgical treatment should be spared to the patients with extensive disease, sepsis or acute abdomen (2,3,11,12). The optimal treatment method is not clear yet.

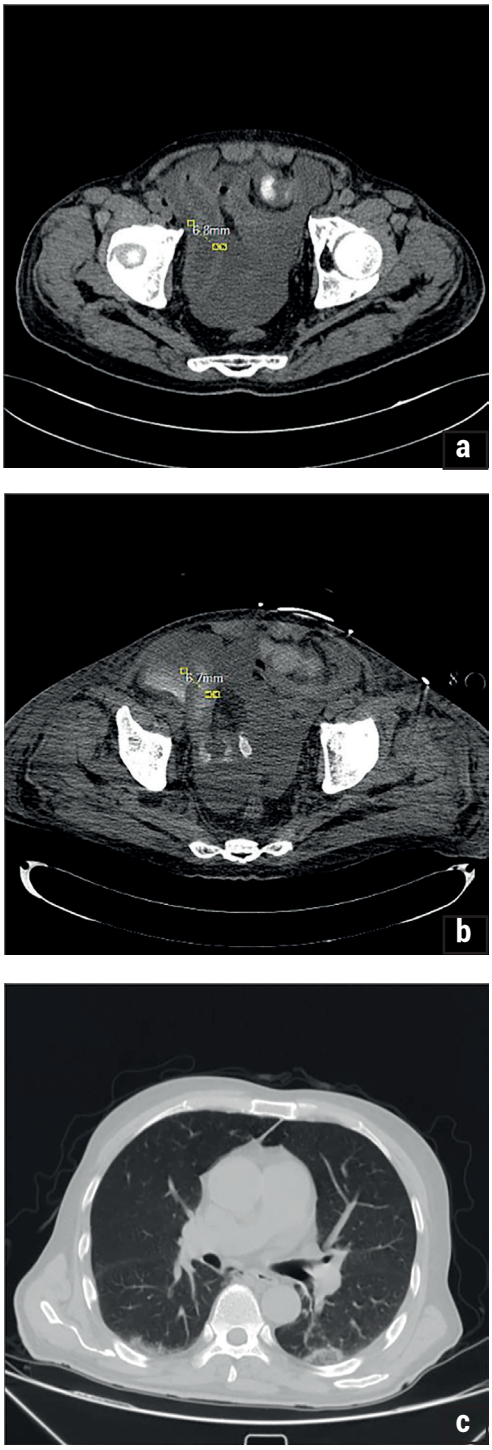

Figure 4. a,b,c. Increased wall thickness at the walls of terminal ileum and cecum, edema at peripheric mesentery, contamination and bilateral parapelvic effusion. Cecal wall thickness was 6-7 mm, bronchopneumonic infiltrations

The treatment should be tailored for each patient (2, 12)and should be continued until clinical findings disappear (2). Some authors suggest that the use of the gastrointestinal system may be continued in selected patients (2, 6).

Close follow up includes repeated physical examinations, monitorization, repeated laboratory work-ups, and radiological imaging. Four of our patients were followed with daily physical examination and laboratory evaluations. In a patient with NE diagnosis, first, a complication that requires emergency surgical intervention should be excluded. Any surgery was not planned for all of our patients when they were symptomatic, because they were deeply neutropenic and had bowel ischemia. The spectrum of their antibiotic therapies was extended and oral intake was stopped. The follow- up was provided by daily physical examination, laboratory controls, and intermittent radiological examinations.

Surgical treatment was not shown to increase mortality in patients with thrombocytopenia and neutropenia due to a hematological malignancy (12). Therefore, the reasons for neutropenia and thrombocytopenia should be explained. Routine and periodic use of G-CSF and thrombocyte transfusions are not recommended to improve neutropenia and thrombocytopenia (12), but it is still an important therapeutic option.

In patients where C. difficile can't be excluded, Metronidazole or Vancomycin should be added to the treatment regime (11). Although antimycotic agents are not routinely recommended for empirical coverage, if a good response can't be obtained after the first 72 hours, antifungal agents may be added to the treatment; (11). For patients who have long-term (>7 days) neutropenia or have a history of prior wide-spectrum antibiotic use, antifungal agents should be considered in the initial treatment (2).

Saillard et al. performed a systematic review and meta-analysis including 385 patients during the neutropenic period and demonstrated that surgery during the neutropenic period had not changed prognosis, which suggests that surgery should not be delayed. Some patients who were included in the meta-analysis had undergone surgery during periods of septic shock and multiple organ failure. Despite these severe conditions, laparotomy was not found to be associated with increased mortality. These findings suggest that the effects of surgery can be underestimated (12).

One of the present cases died in the ICU due to fungal pneumonia. The other 3 cases were followed by close medical treatment. Any pathology requiring surgery did not occur in our patients. The patients could receive maintenance chemotherapy regimens.

CONCLUSION

It is hard to make a common algorithm for diagnosis for NE because NE is a pre-diagnosis. It has a heterogeneous clinical picture, as underlying malignancies are variable, and the level of immunosuppression changes among patients. As a result of higher success rates of conservative management, supportive care, and close follow up have replaced surgery in the treatment of this disease. Further research about NE is warranted because current reports about this life-threatening condition are retrospective mono-center case reports.

Conflict of interest : The authors declare that they have no competing interest.

Financial Disclosure: There are no financial supports.

Ethical approval: Istanbul University Cerrahpasa Faculty of Medicine (Date: 11.03.2020 No: 41300).

REFERENCES

1. Katz JA, Mahoney Jr DH, Fernbach DJ, et al. Typhlitis. An 18-year experience and postmortem review. Cancer 1990;65:1041-7.
2. Urbach DR, Rotstein OD. Typhlitis. Can J Surg 1999;42:415-9.
3. Wade DS, Nava HR, Douglass HO. Neutropenic enterocolitis. Clinical diagnosis and treatment. Cancer 1992;69:17-23.
4. Kaste SC, Flynn PM, Furman WL. Acute lymphoblastic leukemia presenting with typhlitis. Med Pediatr Oncol 1997;28:209-12.
5. Bibbo C, Barbieri RA, Deitch EA, Brolin RE. Neutropenic enterocolitis in a trauma patient during antibiotic therapy for osteomyelitis. J Trauma 2000;49:760-3.
6. Davila ML. Neutropenic enterocolitis. Curr Opin Gastroenterol 2006;22:44-7.
7. Gorschlüter M, Mey U, Strehl J, et al. Neutropenic enterocolitis in adults: systematic analysis of evidence quality. Eur J Haematol 2005;75:1-13.
8. Song HK, Krisel D, Canter R, et al. Changing presentation and management of neutropenic enterocolitis. Arch Surg 1998;133:979-82
9. Sloas MM, Flynn PM, Kaste SC, et al. Typhlitis in children with cancer: a 30-year experience. Clin Infect Dis 1993;17:484-90.
10. Pokorney BH, Jones JM, Shaikh BS, et al. Typhlitis: a treatable cause of recurrent septicemia. JAMA 1980;243:682-3.
11. Rodrigues FG, Dasilva G, Wexner SD. Neutropenic Enterocolitis. World J. Gastroenterol 2017;23:42-7.
12. Saillard C, Zafrani L, Darmon M, et al. The prognostic impact of abdominal surgery in cancer patients with neutropenic enterocolitis: a systematic review and meta-analysis, on behalf the Groupe de Recherche en Réanimation Respiratoire du patient d'Onco-Hématologie (GRRR-OH). Ann Intensive Care 2018;8:47.