JARSS 2020;28(4):231-8
doi: 10.5222/jarss.2020.88598

Evaluation of Different Ultrasonography Techniques for Confirmation of Laryngeal Mask Airway (LMA) Placement in Pediatric Patients

Osman Mücahit Tosun
Alper Kılıçaslan
Funda Gök
Sevgi Pekcan
Ruhiye Reisli

Çocuklarda Laringeal Maske Airway (LMA) Yerleştirilmesinin Doğrulanmasında Farklı Ultrasonografi Tekniklerinin Değerlendirilmesi

ABSTRACT

Objective: *It is likely that laryngeal mask airway (LMA) is frequently misplaced because of the anatomical differences in children's airways. Our aim is to assess the feasibility of different ultrasonography (USG) techniques for the confirmation of the accurate placement of LMA in pediatric population.*
Method: *After a local ethics committee approval and written informed consents were obtained, 50 children aged 1-12 years were consecutively included into this prospective, observational study. After the anesthetic induction, the position of LMA was evaluated by clinical tests and real-time upper airway USG in three planes (at the level of tongue base, the larynx and upper end of the esophagus). The symmetry of the cuff shadows at the tongue base and arytenoid cartilages was assessed by USG (arytenoid grade). The presence of cuff tip in the esophagus and the shape of the cuff (regular or distorted) was recorded. Fiberoptic bronchoscopy (FOB) was performed to confirm the position of LMA (FOB grade). The Spearman correlation coefficient and Fisher's exact tests were used to test the relationship between FOB and sonographic parameters.*
Results: *The rate of accurate LMA placement through clinical tests was determined as 82% at the first attempt. The rate of recognizing the glottic opening was also found as 74% with FOB. The result showed a statistically significant association between the asymmetry of cuff shadow at the tongue base and FOB LMA grade (Fisher's exact test, p<0.001). The correlation was also statistically significant between FOB grade and USG arytenoid grade (r=0.672, p<0.001).*
Conclusion: *USG can be used to identify the accurate placement and repositioning of LMA as a non-invasive, rapid and reliable method not requiring interruption of the ventilation. Further detailed studies are required to compare the different USG techniques for the confirmation of correct placement of LMA.*

Keywords: *Child, flexible fiberoptic bronchoscopy, laryngeal mask airway, ultrasonography*

ÖZ

Amaç: *Çocuklarda, solunum yollarındaki anatomik farklılıklar nedeniyle laringeal maske (LMA) yanlış yerleştirme ihtimali daha yüksektir. Amacımız, çocuk hastalarda LMA yerini belirlemek için, farklı ultrasonografi (USG) tekniklerinin etkinliğini değerlendirmektir.*
Yöntem: *Yerel etik kurul onayı ve ebeveynlerden yazılı bilgilendirilmiş onam alındıktan sonra bu prospektif, gözlemsel çalışmaya 50 çocuk (1-12 yaş) hasta dahil edildi. Yerel etik kurul onayı ve ebeveynlerden yazılı bilgilendirilmiş onam alındıktan sonra bu prospektif, gözlemsel çalışmaya 50 çocuk (1-12 yaş) hasta dahil edildi. Anestezi indüksiyonundan sonra, LMA pozisyonu klinik testler ve gerçek zamanlı üst havayolu USG ile üç düzlemde (dil tabanı, larinks ve özofagusun üst ucu seviyesinde) değerlendirildi. Dil tabanı ve aritenoid kıkırdaklardaki kaf gölgelerinin simetrisi USG (aritenoid derecesi) ile değerlendirildi. Özefagusta kaf ucunun varlığı ve kafın şekli (düzgün veya bozuk) kaydedildi. LMA pozisyonu fiberoptik bronkoskopi (FOB) ile doğrulandı (FOB derecesi). FOB ve sonografik parametreler arasındaki ilişki için Spearman korelasyon ve Fisher's exact testleri kullanıldı.*
Bulgular: *İlk denemede klinik testler yoluyla doğru LMA yerleştirme oranının % 82 olduğu belirlenmiştir. Hastaların % 74'ünde FOB ile glottik açıklık görüntülenebildi. FOB görüntü derecesi ile dil tabanında kaf gölgelerinin asimetri varlığı arasında istatistiksel ilişki olduğu saptandı (Fisher's exact test, p<0.001). FOB görüntü derecesi ile USG aritenoid derecesi arasındaki korelasyon istatistiksel olarak anlamlıydı (r=0.672, p<0.001).*
Sonuç: *İnvaziv olmayan, hızlı, güvenilir bir yöntem olan USG ile ventilasyon kesilmesine gerek duyulmadan LMA yerleştirilmesini doğrulamak ve yeniden konumlandırmak mümkün olabilir. LMA yerleştirilmesini doğrulamada farklı USG tekniklerini karşılaştırmak için daha ayrıntılı çalışmalara ihtiyaç vardır.*

Anahtar kelimeler: *Çocuk, fleksibl fiberoptik bronkoskopi, laringeal maske, ultrasonografi*

© Telif hakkı Anestezi ve Reanimasyon Uzmanları Derneği. Logos Tıp Yayıncılık tarafından yayınlanmaktadır.
Bu dergide yayınlanan bütün makaleler Creative Commons 4.0 Uluslararası Lisansı ile lisanslanmıştır.

© Copyright Anesthesiology and Reanimation Specialists' Society. This journal published by Logos Medical Publishing.
Licenced by Creative Commons Attribution 4.0 International (CC)

Received/Geliş: 20 July 2020
Accepted/Kabul: 11 September 2020
Publication date: 27 October 2020

Cite as: Tosun OM, Kilicaslan A, Gok F, Pekcan S, Reisli R. Evaluation of different ultrasonography techniques for confirmation of laryngeal mask airway (LMA) placement in pediatric patients. JARSS 2020;28(4):231-8.

Alper Kılıçaslan
Necmettin Erbakan Üniversitesi
Meram Tıp Fakültesi, Anesteziyoloji ve Reanimasyon Anabilim Dalı,
Konya - Türkiye
dralperkilicaslan@gmail.com
ORCID: 0000-0002-2570-5854

O.M. Tosun 0000-0001-7318-3475
F. Gök 0000-0002-4968-1420
R. Reisli 0000-0002-1616-5497
Necmettin Erbakan Üniversitesi,
Meram Tıp Fakültesi, Anesteziyoloji ve Reanimasyon Anabilim Dalı,
Konya, Türkiye

S. Pekcan 0000-0002-8059-902X
Necmettin Erbakan Üniversitesi,
Meram Tıp Fakültesi Çocuk Sağlığı ve Hastalıkları Anabilim Dalı,
Konya, Türkiye

INTRODUCTION

In the modern practice of anesthesia, laryngeal mask airway (LMA) is frequently used for the short-term surgeries in pediatric cases. Although the placement of LMA is relatively easy, the repositioning rate (13%-49%) is also high [1-3].

An anesthesiologist should be able to recognize quickly whether LMA is placed accurately in order to avoid such complications as mucosal damage, gastric insufflation, requirement for reinsertion, insufficient ventilation or hypoxemia [4-7]. On the other hand, LMA may be placed correctly while an airway obstruction might occur for any reason. In the routine practice of anesthesia, the confirmation of whether LMA is accurately placed is determined by capnogram, bilateral chest movements, leakage test and airway pressure [8]. However, even if all these clinical tests are considered to be within normal limits, LMA may not be placed correctly [4,6,9]. Therefore, the fiberoptic examination is considered the gold standard for the confirmation of accurate placement of LMA, although it is an invasive and relatively expensive method requiring interruption of the ventilation [5].

Ultrasonography (USG) is being utilized increasingly in the airway management due to advantages as its noninvasive, portable, rapid and real-time imaging features [10-12].

Several studies using different methods have recently been reported about sonographic examination of the different airway structures so as to ascertain the placement of LMA [4,5,11]. However, there is no consensus on which method is more effective. In the present study, therefore, it was aimed to evaluate the different techniques of USG in the confirmation of the accurate placement of LMA in pediatric population.

MATERIAL and METHOD

After an approval from the ethics committee of the medical faculty (Reg. no: 2017828) and a written parental informed consent was obtained for each children, the study was performed according to the principles of the sixth version of the World Medical Association (WMA) Declaration of Helsinki adopted in Edinburgh in 2000. 50 children between 1-12 years of age hospitalized in the Department of Pediatric Pulmonology and scheduled for bronchoscopy under general anesthesia within elective conditions, were enrolled into the study, and all children included were assessed in terms of the American Society of Anesthesiologists (ASA) physical status I or II.

The patients with operation time >1 hour, anticipated airway difficulties, restricted mouth opening and airway malformation, and those with active upper respiratory tract infections, the history of airway stenosis, hyperthyroidism, goiter, airway mass, gastroesophageal reflux and aspiration of gastric contents were excluded from the study.

No premedications were administered to the patients, and they were taken to the operation room in company with a parent. By placing a rolled cotton pad under the patient's shoulder, each patient was laid in supine position with the neck extended slightly. After applying routine monitoring (pulse oximetry, electrocardiogram (ECG), noninvasive blood pressure measurements) and preoxygenation, the anesthesia induction was performed with sevoflurane inhalation (6-8%) in 100% oxygen through a facial mask. After loss of eyelash reflex, a peripheral venous cannula was placed, and the combination of 1 µg kg^{-1} fentanyl and 1-2 µg kg^{-1} propofol (1%) was administered in order to complete the induction.

The size of LMA was selected according to the manufacturer's recommendations and based on the clinical evaluation of the attending anesthesiologist. An experienced anesthesiologist (OMT) in the field of pediatric anesthesia inserted a reusable classical LMA (Intavent Direct, Maidenhead, UK) with a fully deflated cuff using the standard method [13,14]. The cuff was inflated with air, adjusting to the pressure of 60 cm H_2O using a cuff inflator pressure manometer.

Evaluation of LMA placement

Each successful placement of LMA was evaluated primarily by such clinical tests as the assessmnt of chest movement with manual ventilation, absence of air leakage at 20 cm H_2O of airway pressure and capnogram. If the first attempt was evaluated as the

misplacement through the clinical tests, LMA was reinserted, and up to three attempts were allowed in case the procedure was unsuccessful. Therefore, the volume-controlled ventilation was started with 8-9 mL kg^{-1} and an $ETCO_2$ between 30-40 mmHg. Anesthesia was maintained with sevoflurane (1.0 -1.5 MAC in 50% oxygen) and remifentanil infusion (0.1-0.25 µg kg^{-1}). After five ventilation cycles, the peak airway pressure was recorded. Subsequently, the fiberoptic bronchoscope (FOB) and USG examinations were implemented simultaneously by two different practitioners in order to evaluate the position of LMA. The USG images were recorded by an experienced anesthesiologist behind a drape for blind evaluation using the USG device (Mindray Bio-Medical Electronics, Shenzhen, China) as described below, and then scored by another researcher not participating in the study.

1. In the transverse plane, the asymmetrical cuff shadows were recorded at the level of the tongue base (just above the hyoid bone) (Figures 1A and 1B).

2. In the transverse plan, the arytenoids were evaluated at the level of glottis, and the images were recorded. Asymmetrical elevation of an arytenoid was scored as described previously [4]. The glottic opening was divided into three sections by a horizontal line connecting the two arytenoids and three parallel lines above it (Figure 2). Given the elevated arytenoid between the anterior and posterior commissures, the scoring was performed from 0 to 3 (USG arytenoid grade).

3. In the transverse plan, whether the tip of the cuff of LMA was seen at the esophageal level or not was recorded (Figure 1C).

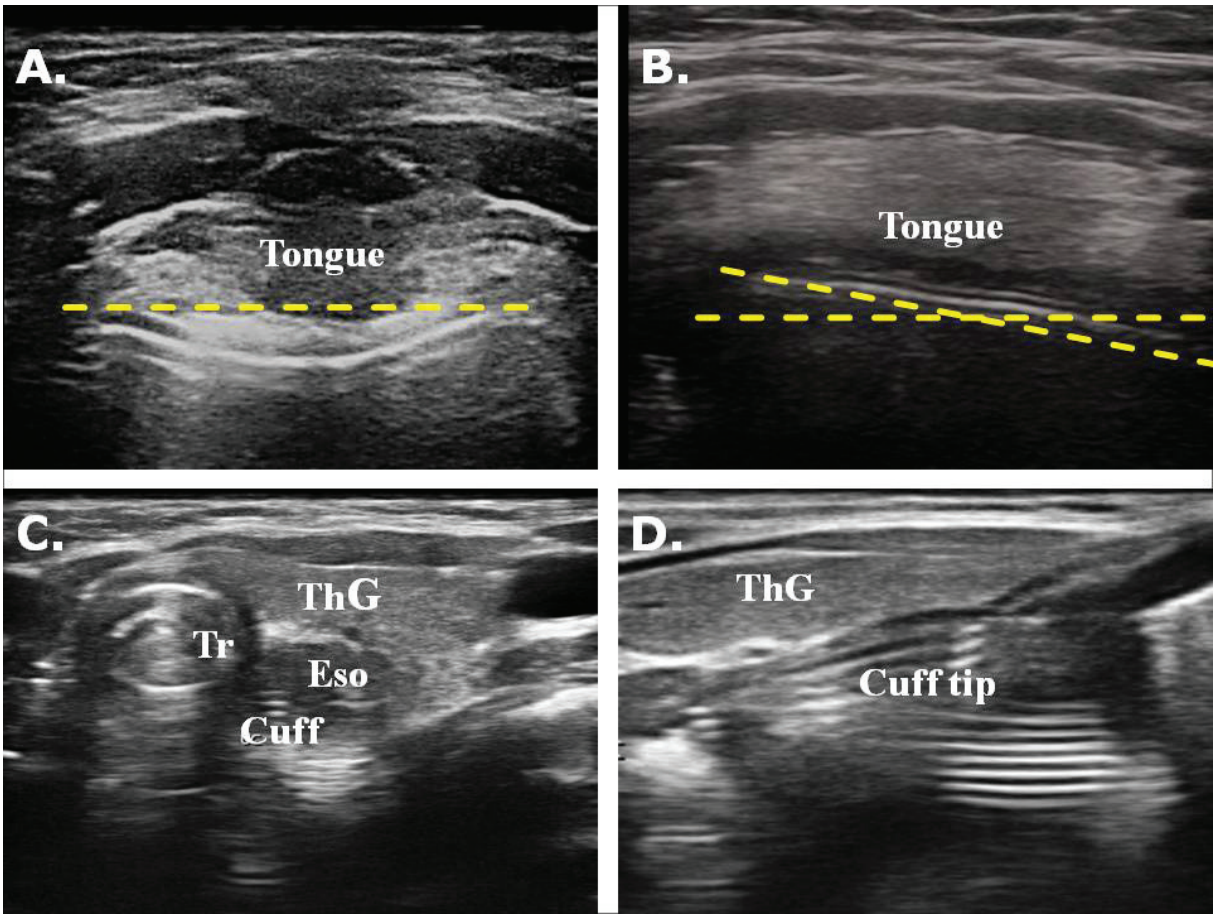

Figure 1. A) Symmetric and B) asymmetric sonographic views of the cuff shadow at the level of the tongue base above the hyoid bone. C) Transverse and D) longitudinal ultrasound images of esophagus after LMA placement at the anterior neck. ThG=Thyroid gland, Eso=Esophagus, Tr=Trachea

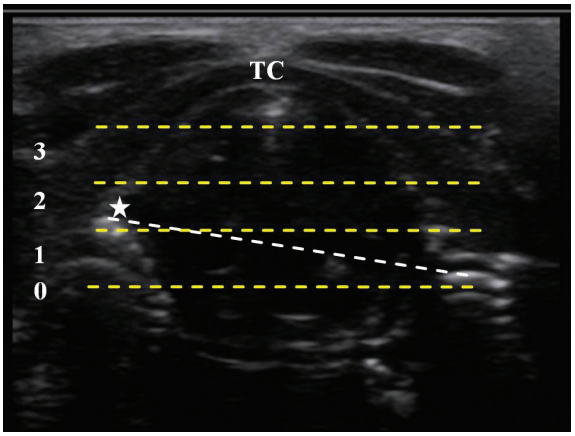

Figure 2. Transverse sonogram of the glottis. The asymmetrical elevation of an arytenoid cartilage was scored from 0 (bilateral symmetrical arytenoids) to 3 (in the upper one-third range of) in the reference to the dashed sections between the anterior and posterior commissures. The star* indicates the arytenoid elevation grade.
TC=Thyroid cartilage

4. In the parasagittal plan, the edge of the cuff tip and the shape of the cuff were assessed (plump and regular or distorted and irregular) (Figure 1D).

The fiberoptic (Olympus, Tokyo, Japan) examination was carried out through the classic LMA to assess the position. Then, FOB was advanced just proximal to the inner opening to evaluate the position of LMA (Figure 3). The FOB grade was recorded with the use of the 4-point scale (1, only larynx is visible; 2, epiglottis and larynx are visible; 3, epiglottis impinging on the grille of LMA and larynx are visible by the manipulation of the fiberscope; 4, larynx not visible), as described in previous studies [2,3]. The association between the FOB grade and the sonographic evaluations at different levels was investigated. If the grade of FOB was scored or determined as ≥3, LMA was repositioned to be the grade 1.

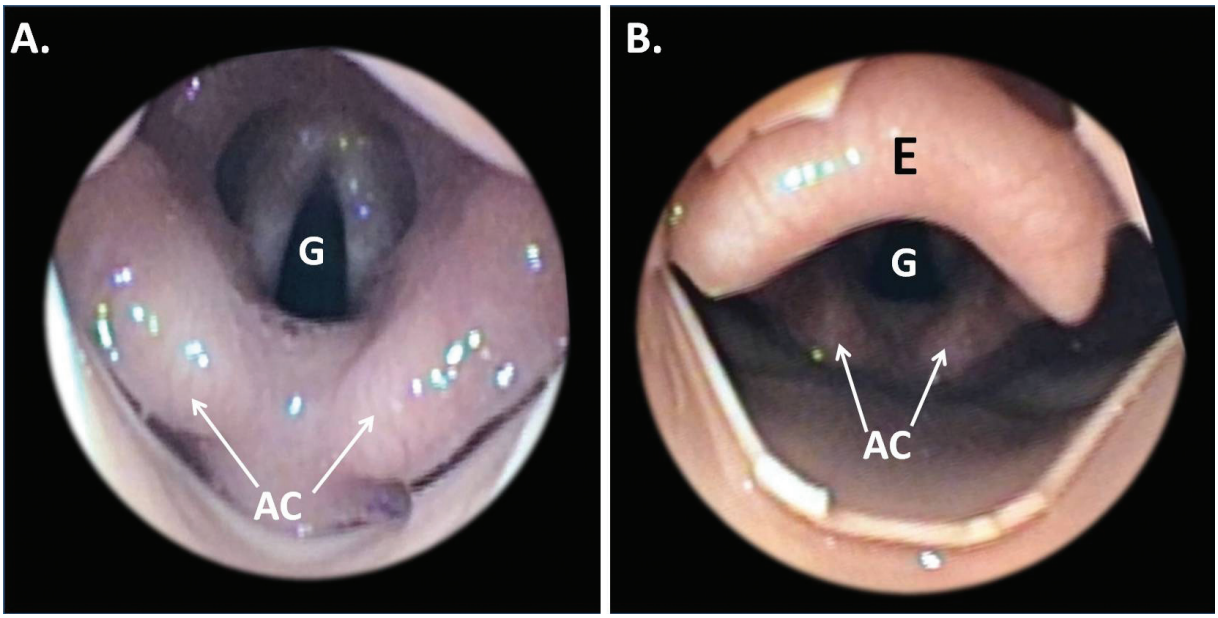

Figure 3. The examples of the grades of laryngeal views by fiberscope through a laryngeal mask airway (LMA). A) Grade 1: Only the larynx visible, B) Grade 2: The epiglottis and larynx visible. E=Epiglottis, G=Glottis, AC=Arytenoid cartilage

Statistical analysis

The sample size was calculated as 50 with a 2-tailed significance level, an alpha value of 0.05 and a statistical power of 80%. The analysis was conducted using the Statistical Package for Social Sciences-SPSS, version 17.0 (Chicago, IL, USA), while the data were tested with the Kolmogorov-Smirnov test for normal distribution. The statistical analysis was also performed using the Spearman correlation coefficient, Pearson's $\chi 2$ and the Fisher's exact tests. A P value <0.05 was considered to be significant. The numerical data were expressed as mean±standard deviation (SD), and the categorized data were reported as percentages.

RESULTS

A total of 50 children, 26 male and 24 female, were

recruited into the study. While the mean age was detected as 41.1±26.1 months, the mean weight was found to be 15.7±4.8 kg, and the mean height was also determined as 94.6±16.7 cm. Although LMA was placed at the first attempt in 47 cases, the insertion was achieved at the second attempt in three cases. The anesthesiologist evaluated the placement of LMA as easy-to-place in 44, and easy-to-moderately difficult in six cases. The peak airway pressure was measured as <20 cmH_2O in 41, 20-30 cmH_2O in six and >30 cmH_2O in three patients. The results showed a statistically significant association between the symmetry degree of the cuff shadows at the tongue base and the FOB LMA grade (Fisher's exact tests, p<0.001) (Table I). There was also an association between the FOB grade and USG arytenoid grade, and the association was also statistically significant (r=0.672, p<0.001) (Table II). It was impossible to see the cuff tip in esophagus in five (10%) patients. There was no statistical signifant correlation between the FOB grade and the image of the cuff tip seen in the esophagus (p=0.387). However, the cuff edge was observed to be distorted and irregular in four (8%) patients. There was no statistical signifant correlation between the FOB grade and that of the image shape of the cuff tip (p=0.065). In addition, a correlation was found between the airway pressure and the USG arytenoid grade (r=0.590, p<0.001) (Table III).

Table I. The presence of symmetry/asymmetry of cuff shadows at the tongue base and fiberoptic grade of LMA position

		FOB Grade			
Tongue Base Cuff Shadow	**n**	**1**	**2**	**3**	**4**
Symmetrical	24 (48%)	6 (25%)	5 (21%)	11(46%)	2 (8%)
Assymetrical	26 (52%)	13 (50%)	13 (50%)	0	0
Total	50	19 (38%)	18 (36%)	11 (22%)	2 (4%)

Data are presented as the number of patients (%). FOB grade=Fiberoptic grade of LMA position

Table II. The sonographic arytenoid grade and fiber optic grade of LMA position

		USG Arytenoid Grade			
FOB Grade	**n**	**0**	**1**	**2**	**3**
1	19 (38%)	11(58%)	7 (37%)	1 (5%)	0
2	18 (36%)	5 (28%)	12 (67%)	1 (5%)	0
3	11 (22%)	0	2 (18%)	7 (64%)	2 (18%)
4	2 (4%)	0	0	2 (100%)	0
Total	50	16 (32%)	21 (42%)	11 (22%)	2 (4%)

Data are presented as the number of patients (%). FOB grade=Fiberoptic grade of LMA position. USG arytenoid grade=Ultrasonographic grading of elevated arytenoid cartilage.

Table III. The sonographic arytenoid grade and peak airway pressures

		Peak Airway Pressure (cm H_2O)		
USG Arytenoid Grade	**n**	**<20**	**20-30**	**>30**
0	16 (32%)	16	0	0
1	21 (42%)	20	1	0
2	11 (22%)	5	4	2
3	2 (4%)	0	1	1
Total	50	41 (82%)	6 (12%)	3 (6%)

Data are presented as the number of patients (%). USG arytenoid grade=Ultrasonographic grading of elevated arytenoid cartilage.

The rate of accurate LMA placement through the clinical tests was determined to be 82% at the first attempt, including peak airway pressure <20 cmH_2O and breathing sound symmetrically accompanied by the chest. The glottic aperture was viewed using FOB in 74% of the children. LMA was repositioned in two cases where the misplacement was confirmed by FOB. The value of peak airway pressure was determined to be >20 cmH_2O in two cases, where the correct LMA position was confirmed by FOB. The laryngospasm detected in both patients disappeared after the depth of anesthesia was increased.

DISCUSSION

In the present observational study, it was investigated whether the position of LMA confirmed by FOB could be determined by USG in pediatric patients. We found out that the misplacement of LMA could be detected by noting asymmetrical cuff shadows at the level of the larynx and tongue base. It is important to immediately evaluate the location of LMA for the continuation of adequate ventilation. In daily clinical practice, correct LMA position is generally evaluated by the ventilation of the lungs and airway pressure [8]. However, this method has some disadvantages, such as the dependence on the clinician's experience, loss of time in the evaluation phase and late development of inadequate ventilation. In addition, airway pressure can be associated with the conditions to cause false positive and negative evaluations, arising from lung pathologies, broncho/laryngospasm, foreign bodies and secretions in the

airway [1,2,4]. In several studies conducted with pediatric population, although correct placement is determined by clinical assessment, the misplacement was detected at a rate between 12.8% to 49% after evaluation with FOB [1,2,15]. There may be several reasons for such a high rate of misplacements in pediatric cases. First, most of the pediatric LMAs used in daily practice are the miniaturized version of the adult prototype, but the children's airway is different from that of adults [4]. Another reason may also be related to the differences in the techniques used for the insertion and confirmation. Finally, a misplaced LMA can provide the ventilation initially, but the likelihood of the displacement is also increased during the surgery.

In the present study, the rate of accurately placed LMAs at the first attempt was found to be 82% through clinical tests. However, although the peak airway pressure was <20 cmH_2O in one case, the FOB image was found as grade 4. In a previous study, the rate of accurate LMA placement was found to be 75.8% at the first attempt [16]. Even so, another study reported the success rate for LMA placement as 95.9% [17].

FOB is considered to be the gold standard in the determination of LMA placement. In our study, the rate at which the glottic opening was seen with FOB after the placement of LMA was determined as 74%. In a previous study, glottic opening was precisely seen with FOB in 49% of pediatric patients [7]. In another study, the rotation was detected in 43% of LMAs using FOB without any change in peak airway pressure [4].

Some authors reported that smaller LMAs were more commonly associated with the misplacement of LMA, compared with bigger ones [6,13]. This entity may be due to the fact that the epiglottis may close the grille of small LMA, and so the likelihood of LMA replacement increases. We agree with such an assertion. Therefore, a larger size of LMA was preferred for those at age limits in our study. A well-placed LMA allows the laryngeal opening to be seen, although the epiglottis is in slightly retroflexed position. On the other hand, if the size of LMA is too large for the patient, the tip of LMA cannot be advanced to the esophageal entrance, and the frontal surface of the epigotis can be seen in FOB.

Compared with clinical tests, FOB and USG can provide detailed anatomical information, but there are also some differences between them. USG is a noninvasive, rapid and reliable device that does not intervene with the ventilation [4,5,8]. Several studies demonstrated that USG can be utilized to predict difficult intubation, and to confirm the position of endotracheal tube [10,18-20]. Similarly, some of the risk factors for the difficult ventilation via a supraglottic airway device (e.g. short thyromental distance) can be evaluated by upper airway USG [21]. In addition, evaluation of the symmetry of the arytenoid cartilages or cuff shadows can be used in patients with anticipated difficult LMA placement. However, current studies are insufficient, and so further researches are needed to elucidate the use of USG in cases with difficult LMA placement.

There are also some limiting outcomes of the evaluation with USG. The aging-related ossification of cartilages and male patients with prominent Adam's apple can make the assessment with USG difficult [12,20]. In addition, the enlarged epiglottis and preepiglottic fat may sometimes prevent the clear images of the airway [10,22]. The airway structures do not require to be analyzed in detail in confirming the location of LMA. By evaluating the image of the cuff of LMA, information can be acquired about the position of LMA. If LMA is moved away from the midline and not placed in the esophagus entrance, it can be easily detected with USG.

In the present study, we demonstrated that there was a strong association between LMA malposition and the asymmetric elevation of an arytenoid cartilage [4]. However, the imaging of arytenoid cartilage is difficult in men at older age [12,20]. In a previous study, the imaging of the cuff shadows between hyoid bone and thyroid cartilage in transverse plane had been investigated in the pharynx [5]. However, we realized that this area was narrow, and it was difficult to insert the probe in pediatric patients. We consider that USG scanning of the tongue base (just above the hyoid bone) is a more rapid and relatively easy method in pediatric patients. However, further studies are needed to elucidate which of both modalities is more effective.

Our study has also several limitations. Firstly, since

the clearest image was attempted to obtain, the position and angle of USG probe could not be standardized. Secondly, we only used classic LMAs in the study. Therefore, our results are not generalized or may be incompatible with the other supraglottic airway devices of different generations and different shapes. As another limitation, we enrolled a relatively small number of subjects; however, we still think that we achieved significant results.

In conclusion, the immediate confirmation of the location of LMA after its placement is important in order to prevent the complications to occur in pediatric patients. However, the clinical tests used in daily practice may be inadequate. Evaluation of the symmetry of the arytenoid cartilages or cuff shadows by USG can be used to identify the accurate placement and repositioning of LMA. Upper airway USG is a noninvasive, rapid and reliable method, not requiring the interruption of ventilation. Further detailed studies are required to compare the different US techniques for the confirmation of correct placement of LMA.

Acknowledgement: Authors thank Numan Duran for language editing.

Ethics Committee Approval: The Clinical Research Ethics Committee approval was received (Reg. Number: 828/2017).

Conflict of Interest: None.

Funding: None.

Informed Consent: A parental written consent was obtained for each patient.

REFERENCES

1. Lopez-Gil M, Brimacombe J, Alvarez M. Safety and efficacy of the laryngeal mask airway. A prospective survey of 1400 children. Anaesthesia. 1996;51:969-72. https://doi.org/10.1111/j.1365-2044.1996.tb14968.x
2. Tsujimura Y. Downfolding of the epiglottis induced by the laryngeal mask airway in children: a comparison between two insertion techniques. Paediatr Anaesth. 2001;11:651-5. https://doi.org/10.1046/j.1460-9592.2001.00749.x
3. Ghai B, Ram J, Makkar JK, WigJ. Fiber-optic assessment of LMA position in children: a randomized crossover comparison of two techniques. Paediatr Anaesth. 2011;21:1142-7. https://doi.org/10.1111/j.1460-9592.2011.03632.x
4. Kim J, Kim JY, Kim WO, Kil HK. An ultrasound evaluation of laryngeal mask airway position in pediatric patients: an observational study. Anesth Analg. 2015;120:427-32. https://doi.org/10.1213/ANE.0000000000000551
5. Song K, Yi J, Liu W, Huang S, Huang Y. Confirmation of laryngeal mask airway placement by ultrasound examination: a pilot study. Journal of Clinical Anesthesia. 2016;34:638-46. https://doi.org/10.1016/j.jclinane.2016.06.019
6. Von Ungern-Sternberg BS, Wallace CJ, Sticks S, Erb TO, Chambers NA. Fibreoptic assessment of paediatric sized laryngeal mask airways. Anaesth Intensive Care. 2010;38:50-4. https://doi.org/10.1177/0310057X1003800110
7. Daya H, Fawcett WJ, Weir N. Vocal fold palsy after use of the laryngeal mask airway. J Laryngol Otol. 1996;110:383-4. https://doi.org/10.1017/S0022215100133699
8. Zhou ZF, Xia CZ, Wu M, et al. Comparison of three methods for the confirmation of laryngeal mask airway placement in female patients undergoing gynecologic surgery. Ultrasound Med Biol. 2015;41:1212-20. https://doi.org/10.1016/j.ultrasmedbio.2014.12.002
9. Keller C, Brimacombe JR, Keller K, Morris R. Comparison of four methods for assessing airway sealing pressure with the laryngeal mask airway in adult patients. Br J Anaesth. 1999;82:286-7. https://doi.org/10.1093/bja/82.2.286
10. Sustic, A. Role of ultrasound in the airway management of critically ill patients. Crit Care Med. 2007;35:173-7. https://doi.org/10.1097/01.CCM.0000260628.88402.8A
11. Gupta D, Srirajakalidindi A, Habli N, Haber H. Ultrasound confirmation of laryngeal mask airway placement correlates with fiberoptic laryngoscope findings. Middle East J Anaesthesiol. 2011;21:283-7.
12. Kristensen, MS. Ultrasonography in the management of the airway. Acta Anaesthesiol Scand. 2011;55:1155-73. https://doi.org/10.1111/j.1399-6576.2011.02518.x
13. Loke GP, Tan SM, Ng AS. Appropriate size of laryngeal mask airway for children. Anaesth Intensive Care. 2002;30:771-4. https://doi.org/10.1177/0310057X0203000609
14. Mizushima A, Wardall GJ, Simpson DL. The laryngeal mask airway in infants. Anaesthesia. 1992;47:849-51. https://doi.org/10.1111/j.1365-2044.1992.tb03144.x
15. Shimbori H, Ono K, Miwa T, Morimura N, Noguchi M, Hiroki K. Comparison of the LMA-ProSeal and LMA-Classic in children. Br J Anaesth. 2004;93(4):528-31. https://doi.org/10.1093/bja/aeh238
16. Joshi S, Sciacca RR, Solanki DR, Young WL, Mathru MM. A prospective evaluation of clinical tests for placement of laryngeal mask airways. Anesthesiology. 1998;89:1141-6. https://doi.org/10.1097/00000542-199811000-00014
17. Keskin G, Akın M, Şenaylı Y, et al. Laryngeal Mask Airway Application During Flexible Fiberoptic Bronchoscopy in Pediatric Patients: Evaluation of 125 Cases. JARSS. 2019;27:100-5. https://doi.org/10.5222/jarss.2019.36025
18. Werner SL, Jones RA, Emerman CL. Sonographic assessment of the epiglottis. Acad Emerg Med. 2004;11:1358-60.

https://doi.org/10.1197/j.aem.2004.05.033
19. Arens C, Weigt J, Schumacher J, Kraft M. Ultrasound of the larynx, hypopharynx and upper esophagus. HNO. 2011;59:145-54. https://doi.org/10.1007/s00106-010-2211-x
20. Kilicaslan, A, Topal, A, Erol A, Gök F. Ultrasonographic assessment of the airway anatomy and clinical use. Selçuk Tıp Derg. 2015;31:88-94.
21. Saito T, Liu W, Chew STH, Ti LK. Incidence of and risk factors for difficult ventilation via a supraglottic airway device in a population of 14 480 patients from South-East Asia. Anaesthesia. 2015;70:1079-83. https://doi.org/10.1111/anae.13153
22. Tsui BC, Hui CM. Challenges in sublingual airway ultrasound interpretation. Can J Anaesth. 2009;56:393-4. https://doi.org/10.1007/s12630-009-9077-y