Ann Med Res 2021;28(6):1143-9

Annals of Medical Research

DOI: 10.5455/annalsmedres.2020.05.455

Original Article

Coronary CT Angiography Findings with 64-Detector CT

Cansu Ozturk[1], Elif Ergun[2], Behice Kaniye Yilmaz[3], Pinar Nercis Kosar[2]

[1]Department of Radiology, Kecioren Training and Research Hospital, Ankara, Turkey
[2]Department of Radiology, Ankara Training and Research Hospital, Ankara, Turkey
[3]Department of Radiology, Haseki Training and Research Hospital, Istanbul, Turkey

Copyright@Author(s) - Available online at www.annalsmedres.org
Content of this journal is licensed under a Creative Commons Attribution-NonCommercial 4.0 International License.

Abstract

Aim: This study aims to determine the coronary artery variations, anomalies, and pathologies that could be detected in coronary computed tomography angiography (CCTA).

Materials and Methods: Between March 2007 and December 2008, 1180 patients were referred to our clinic with CCTA requests. Coronary artery anatomy, the presence of variations and anomalies, coronary artery disease, proximal and distal anastomosis levels, stenosis and/or occlusion of by-pass grafts, stent patency, or stenosis were examined and recorded for all cases.

Results: Total of 1118 cases included in the study. The left main coronary artery (LM) was not observed in 9 (0.80%) patients. In one case (0.08%), the circumflex artery (LCx) artery was originated from the right sinus of Valsalva (RSV) with a retro-aortic course and then reached its typical trace. The LM originated from the RSV in 2 patients (0.17%). The right coronary artery (RCA) originated from the left sinus of Valsalva (LSV) in 4 cases (0.35%). Coronary artery disease (CAD) in any stage was found in 100 patients with zero scores, and 27 (4.48%) had stenotic CAD according to CCTA. There was a moderate correlation between age and CAD stage, and age and calcium (Ca) score.

Conclusion: In conclusion, 64-MDCT coronary angiography is a suitable method for the noninvasive evaluation of coronary arteries. Coronary artery anomalies are observed with a non-rare frequency. There is a moderate correlation between age and CAD stage, and age and Ca score. There is a high correlation between Ca score and the CAD stage, but zero Ca score cannot exclude CAD.

Keywords: Coronary angiography; coronary artery disease; coronary vessel anomalies

INTRODUCTION

Cardiovascular diseases are among the leading causes of death both worldwide and in our country. Therefore, the recognition of these diseases and determining the correct treatment are essential. Catheter angiography is the gold standard method for the diagnosis of coronary artery disease and imaging of the coronary arteries; however, it is an invasive procedure, requires hospitalization and has a mortality rate of 0.1% to 0.55% (1). Also, approximately 20% of this high-cost examination is diagnostic. Because of these disadvantages, various studies have been conducted for noninvasive imaging of coronary arteries. With the development of multi-detector CT systems, scanning time became shorter, and an increase in spatial and temporal resolution has been achieved, and thereby, CT has come into use for imaging of the coronary arteries. In the studies, coronary CT angiography (CCTA) was shown to have high sensitivity and specificity values, especially in 64-detector systems in anatomic imaging of coronary arteries and in determining the presence and extent of coronary artery disease (2).

This study aims to determine the coronary artery variations, anomalies, and pathologies that could be detected in coronary CT angiography.

MATERIALS and METHODS

The study was approved by the institutional ethics committee (Ethics Committee of Ankara Training and Research Hospital; 2007-1864), and all procedures were performed under the ethical standards of the Helsinki Declaration.

Patients

Between March 2007 and December 2008, 1180 patients were referred to our clinic with the request of CCTA. CT angiography could not be performed in 62 (5.2%) patients due to the inability to establish vascular access, high calcium score, arrhythmia, tachycardia, history of contrast agent allergy, and inability to hold breath, and these patients were excluded from the study. The mean age of the remaining 1118 cases was 56 years, while 546 (48.8%) were male, and 572 (51.1%) were female. Twenty-six (2.3%) patients had coronary bypass and 42 (3.7%)

Received: 09.05.2020 **Accepted:** 27.07.2020 **Available online:** 23.06.2021
Corresponding Author: Cansu Ozturk, Department of Radiology, Kecioren Training and Research Hospital, Ankara, Turkey
E-mail: cnsozt@yahoo.com

had coronary stents. Coronary calcium (Ca) scoring was performed just before the CCTA, apart from the patients with by-pass and stents (1050 cases in total).

MDCT Technique and Evaluation

CCTA imaging was performed by using a 64-detector CT device (Toshiba Aquilion 64, Tokyo) with retrospective ECG gating. Screening from the tracheal bifurcation to the heart base was performed. Field of view (FOV) was enlarged in patients with by-pass, and the CT scan images were initiated was from the thoracic inlet. Unlike routine protocol, the sharp kernel was used in patients with stents. The protocol is shown in Table 1. Unless there was no contraindication for beta-blockers, 40 mg oral propranolol was administered an hour before scanning to all patients with heart rate >65 beats/min. Ca channel blockers were used in the cases, whereas beta-blockers were contraindicated. 0.4 mg sublingual nitroglycerin spray (Nitrolingual Pumpspray, G. Pohl- Boskamp GMBH& Co, Germany) was given just before the scan for CAC scoring. For CCTA 80–85 ml contrast material (Omnipaque 350 mg I/ml, GE Healthcare, Princeton, New Jersey, Ultravist 370 mg I/ml, Schering AG, Germany) was injected through the right antecubital vein with a flow rate of 5 ml/s. 20 ml saline was injected both before and after the injection of the contrast agent with the same flow rate. Optimal scan time was detected by an automated bolus tracking method by placing the region of interest over the descending aorta and setting the trigger threshold to 180 HU.

Table 1. CCTA Protocol

64- DETECTOR CCTA PROTOCOL	
Voltage (Kv)	120
mAs	400
Slice Thickness (mm)	0.5
FOV	200-270
Gantry rotation time	400 ms
ECG gating	Retrospective

*CCTA: Coranary CT Angiography

Reconstructions were created from the source images obtained in various phases of the cardiac cycle. Reconstructed images were evaluated at the workstation (Vitrea 2, vital image INC., Plymouth, Minnesota, USA) using source images and post-processing methods by one experienced radiologist. Coronary artery anatomy, variations and anomalies, coronary artery disease, and accompanying pleural, parenchymal, and pericardial pathologies were recorded for all cases. Proximal and distal anastomosis levels and graft stenosis and/or occlusions were evaluated in patients who had by-pass graft. In the evaluation of cases who had a stent, contrast agent filling of the stent was assessed in favor of stent patency, while pathologies within the 5 mm proximal and distal part of the stent were evaluated in favor of stent re-stenosis/occlusion, alongside with the intra-stent pathologies.

Table 2. *CAD Classification

*CAD CLASSIFICATION
Stage 0: Normal, patent
Stage 1: 1-19% stenosis, the involvement of the segment below 2 cm, 1 or 2 arteries involvements
Stage 2: 20-49% stenosis, the involvement of the segment more than 2 cm, 3 arteries involvements, or com-bination of these
Stage 3: 50-69% stenosis in arteries other than LM, more than 3 arteries involvements
Stage 4: Stenosis of 70% and above, stenosis of 50% and above in LM

*CAD: Coronary artery disease

In the evaluation of coronary artery disease (CAD), the cases were classified into five groups according to the presence, prevalence, and severity of stenosis (Table 2). Stage 3 and 4 diseases were considered as stenotic coronary artery disease.

Ca score was calculated by the Agatston method, and staging was classified into five groups according to the Agatston score.

Statistical Analysis

The qualitative variables were given with descriptive measures such as numbers and percentages. The correlation between age- Ca score, Ca score - presence and severity of CAD, and age -presence, and severity of CAD were evaluated by the Spearman correlation test. Statistical analysis was performed using SPSS software package (SPSS 11.5 for windows, SPSS Corp.; Chicago, IL).

RESULTS

Of the 1118 cases included in the study, 546 (48.83%) were male, and 572 (51.16%) were female, while their ages ranged from 17 to 86 years (with a mean age of 56 years). Twenty-six (2.32%) patients underwent by-pass, and 42 (3.75%) had stent insertion.

Coronary Anatomy-Variation-Anomaly

As a result of the coronary anatomy and presence of variation-anomaly evaluation, right dominance was detected in 890 (79.60%) cases, left dominance in 93 cases (8.31%), and co-dominance in 135 cases (12.07%).

The conus artery was the first branch of the RCA in 872 (77.99%) cases, whereas it was observed to originate from the right sinus Valsalva with an ostium in 240 (21,46%) cases. The double conus artery originating from the right sinus Valsalva with ostium was observed in 6 (0.53%)

cases (Figure 1). Sinoatrial nodal artery originated from RCA in 883 cases (78,98%), LCx artery in 223 cases (19,94%), LM in 8 cases (0.71%) (Figure 2), while it was branched from a different ostium from right sinus Valsalva in 4 cases (0.35%). There were ramus intermedius arteries in 335 cases (29.96%) (Figure 2). Myocardial bridging was observed in a total of 344 segments in 220 patients (19.67%). It was observed in one segment in 115 patients (52.27%), in two segments in 62 patients (28.18%), three segments in 33 patients (15.00%), four segments in 9 patients (4.09%), and in one patient (0.45%) it was present in five segments. The distribution of myocardial bridging, according to the arteries, is shown in Table 3.

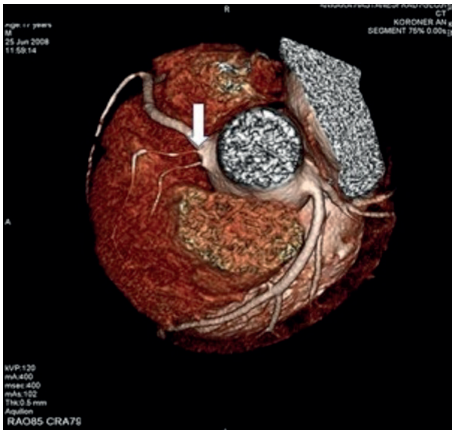

Figure 1. 3D VR, image shows double conus artery (white arrow) which originated from right sinus valsalva

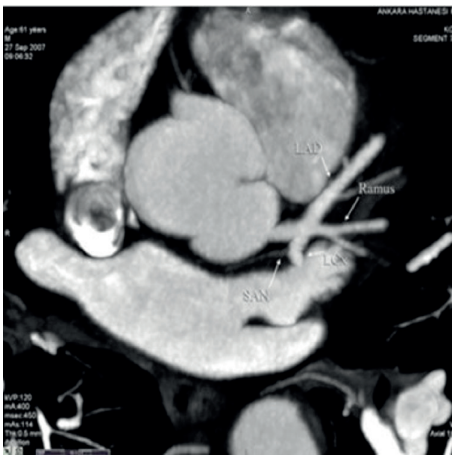

Figure 2. Oblique MIP images shows SAN and ramus intermedius branch to originate from LCx

Table 3. Distribution of myocardial bridging according to arteries

The arteries of myocardial bridging	Number of segments (344)
LAD artery	79 (%22.96)
1. Diagonal artery	65 (%18.89)
2. Diagonal artery	18 (%5.23)
3. Diagonal artery	1 (%0.29)
LCx artery	68 (%19.76)
1. Obtus marginal artery	99 (%28.77)
2. Obtus marginal artery	14 (%4.06)

In 10 patients (0.89%), the left main coronary artery (LM) was shorter than usual (mean length of 3 mm), whereas in 8 patients (0.71%), the left main coronary artery was longer than usual (mean length of 25 mm). In 5 cases (0.44%), the left main coronary artery originated from the superior of the left sinus Valsalva and in 1 case (0.08%), the right coronary artery originated from the superior of the right sinus Valsalva. Diagonal arteries were not observed in 1 patient (0.08%), and Optus marginal arteries were not observed in 1 patient (0.08%). The left main coronary artery was not observed in 9 patients (0.80%), and LAD and LCx arteries were originated from different ostium on left sinus Valsalva (Figure 3). In one case (0.08%), the LCx artery was originated from the right sinus Valsalva, showed a retro-aortic course, and then reached its normal trace. The left main coronary artery originated from the right sinus Valsalva in 2 patients (0.17%). The right coronary artery originated from the left sinus Valsalva in 4 (0.35%) cases (Figure 4).

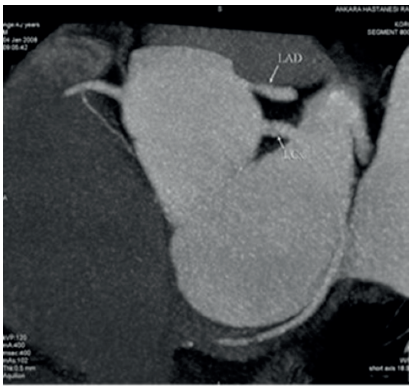

Figure 3. Oblique MIP image shows absent LM, the LAD artery is separated above the sinotubular junction (high take-off), and the LCx artery is separated from the left sinus valsalva with different ostiums

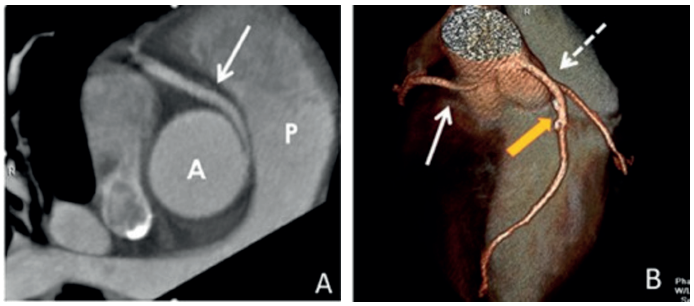

Figure 4. A,B The right coronary artery (arrow), adjacent to the left main coronary artery (dashed arrow) orifice, originates from the left sinus valsalva and proceeds between the ascending aorta (A) and the pulmonary trunk (P) and then to its normal trace

Coronary Atherosclerosis-Ca Scoring

The Ca score and CAD staging of the cases are shown in Tables 4 and 5.

The distribution of CAD stages, according to Ca scoring stages, is shown in Table 6.

Stenotic coronary artery disease in any stage was found in 100 (16.61%) patients with zero score, and 27 (4.48%) had stenotic coronary artery disease, according to CCTA (Figure 5). While the mean age of the zero-score patients

with positive CCTA findings was 55.8 years, the mean age of patients with stenosis, according to CCTA, was 56 years in this group. Of the patients with zero score (100 cases) who had positive CCTA findings, 13 had a genetic predisposition, 13 had DM, 24 had hyperlipidemia, and 43 had hypertension. There were stage 1 and 2 coronary artery diseases in 46 (28%) patients of the 164 patients with grade 3 and 4 Ca scores.

Table 4. Ca score distribution

Calcium Scoring Stage	Number of Cases (1050)
0	602 (%57.33)
1	95 (%9.04)
2	189 (%18.00)
3	108 (%10.28)
4	56 (%5.33)

Table 5. *CAD stage distribution

*CAD Stage	Number of Cases (1050)
0	504 (%48.00)
1	127 (%12.09)
2	176 (%15.74)
3	147 (%14.00)
4	96 (%9.14)

*CAD: Coronary artery disease

There was a moderate correlation between age and CAD stage, and age and Ca score. Correlation coefficient was r: 0.403 and r: 0.460, respectively. There was a high correlation between Ca score and the CAD stage, and the correlation coefficient was r: 0.816.

Table 6. *CAD stage distribution

Ca Scoring Stage	*CAD Stage				
	0	1	2	3	4
0	502 (%83.38)	37 (%6.14)	36 (5.98)	21 (%3.48)	6 (%0.99)
1	2 (%2.10)	44 (%46.31)	34 (%35.78)	12 (%12.63)	3 (%3.15)
2	0	42 (%22.22)	64 (%33.86)	51 (%26.98)	32 (%16.93)
3	0	3 (%2.77)	32 (%29.62)	43 (%39.81)	30 (%27.77)
4	0	1 (%1.78)	10 (%17.85)	20 (%35.71)	25 (%44.64)

*CAD: Coronary artery disease

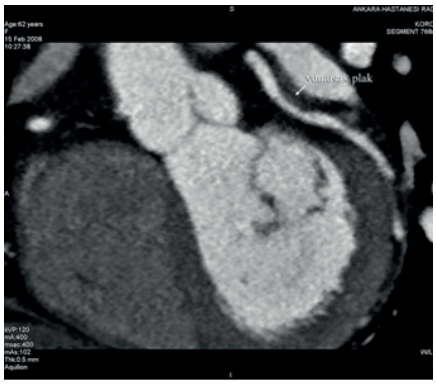

Figure 5. The oblique VR image shows a soft plaque causing stenosis of more than 50% in the LAD artery in the patient with 0 score and chest pain

By-pass-Stent

In our series, 26 patients (2.32%) had by-pass grafts, and 42 patients (3.75%) had stents. In 26 patients with by-pass graft, there were 28 saphenous vein grafts (51.85%), 23 LIMA grafts (42.59%), two radial artery grafts (3.70%), and 1 RIMA graft (1.85%). Therefore, the total number of by-pass grafts was 54. Of these patients, the graft was observed to be patent in 41 cases (75.92%). On the other hand, there were atherosclerotic changes in the graft body as wall irregularities and thickening in 1 patient (1.85%), stenosis in the proximal anastomosis line in 3 cases (5.55%), stenosis in the distal anastomosis line in 3 cases (5.55%), stenosis in the graft body in 3 cases (5.55%) and occlusion in 3 grafts (5.55%). There was a total of 64 stents in 42 patients with stents (25 patient (59.52%) had one stent, 13 patient (30.95%) had two stents, three patient (7.14%) had three stents, one patient (2.38%) had four stents; 43 (67.18%) of them had patent stents, 2 (3.12%) had intimal thickening, 17 (26.56%) had stenosis, and 2 (3.12%) had occlusion.

DISCUSSION

Selective catheter angiography remains the gold standard method for the evaluation of coronary artery anatomy and pathologies. However, because of the known disadvantages, it has become inevitable to develop new methods regarding the noninvasive evaluation of coronary arteries. Coronary CT angiography is the most prominent test in this sense.

CCTA sets a course for interventional procedures in addition to the evaluation of CAD. Informing cardiovascular surgeons and cardiologists about the existing anatomy and the actual variation and anomalies would reduce the complication rates, which might occur during operation or DSA and shorten the procedure time. The first step for the evaluation of coronary anatomy is the determination of dominance. In the population, the prevalence of right dominance was reported to be 80-85%, left dominance 7-9%, and co-dominance 7-8% (3,4). In our series, 79% of

the patients had right dominance, 8.3% left dominance, and 12% co-dominance. The rate of co-dominance in our series was slightly above the rates reported in the literature, which may be explained by the various opinions on the definition of co-dominant circulation. In this study, the originating of PDA from the right coronary artery and the posterolateral branches from the LCx artery were accepted as co-dominant circulation.

Following the determination of dominance, coronary circulation anatomy should be examined. The conus artery, as the first branch of the right coronary artery, separates from the right sinus Valsalva with a separate ostium in varying proportions from 22% to 50%(3). In our series, the conus artery originating from the right sinus Valsalva with a separate ostium was observed at a rate of 22%. Although this variation does not cause a hemodynamic disturbance, the detection of it before a surgical procedure is important due to the risk of arterial injury. The presence of ramus intermedius is one of the most frequently observed variations, and its incidence has been reported to be in the range of 30-37% (5). In our series, the ramus intermedius branch was observed in 30% of the cases in accordance with the literature. Variations of the left main coronary artery such as short-course (<5 mm), long-course (> 2 cm), or agenesis may not cause a hemodynamic deterioration but may cause difficulty in catheterization and interventional procedures (6). In a study conducted by Cademartiri et al. (3), long-course LM was detected at a rate of 7%, and the average length of LM was 11.2 ± 5.5 cm. In our series, the rate of LM with a course of less than 5 mm was 0.8%, and the rate of LM with a course longer than 2 cm was 0.7%. The absence of the left main coronary artery has been reported in the literature at a rate of 0.41-0.52% (7,8). In our patient group, the left main coronary artery was not observed in 0.8% of the cases; in 1 of these cases, LAD and LCx arteries were shown to be high take-off. Myocardial bridging was reported to be observed in catheter angiography at rates ranging from 0.5% to 2.5%, while it has been reported to occur at the rate of 15-85% in autopsy series (7). The gold standard method for the detection of this anomaly is autopsy studies. This rate was 20% in our series, which was consistent with the autopsy series; besides, Zeina et al. (9) showed similar bridging in their study with MDCT. In the literature, the most common myocardial bridging has been reported to occur in the middle segment of the LAD artery (7). The bridging was most frequently seen in the OM1 artery and secondly in the LAD artery in our series.

Coronary artery anomalies are less common than variations and are seen in 0.3% to 5.6% of the population (10). In our series, 17 cases (1.5%) had a coronary artery anomaly. In the detection of coronary artery anomalies, catheter angiography, which is accepted as the reference method, is used (11). However, the visualization of coronary artery anomalies by catheter angiography is difficult, and even if they were, the interpretation of the course of the anomalous vessel correctly becomes challenging. In a study by Shi et al. (12), the vascular structure with an anomaly was successfully opacified with catheter angiography in only 63% of the patients, and catheter angiography was able to detect anomalies correctly in only 53% of the cases. The most common anomalies which cause severe symptoms hemodynamically are the anomalies of origin, especially the ones with an interarterial course (7). The incidence of origin anomalies with an interarterial course in the general population is 0.44-0.64% (6, 13). The anomalies of the right coronary artery originating from the left sinus Valsalva have been reported in the population at a rate of 0.03-0.33%, and these anomalies are mostly observed to be interarterial (6, 13). In our series, this anomaly was determined in 4 cases (0.35%), and the interarterial course of RCA was observed in 3 cases (75%). Anomalies of the left main coronary artery originating from the right sinus Valsalva have been reported in the population at a rate of 0.09-0.12% (6,13). In this study, LM was originating from the right sinus Valsalva in 2 cases (0.17%). The interarterial course was reported to be at a rate of 75% in the anomalies of left main coronary artery originating from the right sinus Valsalva; as 1 of our cases (50%) had an interarterial course. The anomalies of the LCx or LAD artery originating from the right sinus Valsalva have been reported as 0.32-0.67% (6, 14). The LCx artery originating from the right sinus Valsalva has been often reported to have a retro aortic course (7). In our series, one patient (0.08%) had LCx artery originating from the right sinus Valsalva and showed a retro aortic course.

Many studies have shown that calcium scoring has a superior effect on predicting cardiovascular events, independent of traditional risk factors, and increases with age (15). In our study, a significant positive correlation was observed between calcium score and age, in accordance with the literature (r:0,460). In the literature (16), it has been reported that most of the acute coronary syndromes are due to plaques that cause stenosis less than 50% which are not adequately detected by current invasive methods; therefore, the absence stenosis is not a sign of good prognosis. Today, it is emphasized that the extensiveness of the disease is more important than the level of stenosis in the treatment of atherosclerotic disease. In this sense, coronary calcium scoring has a high value in predicting the presence and extensiveness of the disease. A very high correlation was found between the calcium score and the extensiveness of coronary artery disease (r: 0.816) in our study. However, although people with high Ca scores are believed more likely to have an occlusive disease, it is known that they do not provide specific information about the stenosis level (17,18). In a research conducted by Ho et al. (19), patients with a calcium score of >400 were reported to have an increased incidence of stenotic disease, and the incidence of stenotic disease in patients with a score higher than 400 was found to be two times higher than those with a score below 400. Another study (20), showed that as the Ca score increases, coronary events associated with coronary artery stenosis was increased. Similarly, in the study of Nappi et al. (21), significant perfusion abnormalities were found in patients

with a higher Ca score. In our study, the stenotic disease was detected in 46 (80.7%) of 57 patients with a score >400 by CT angiography, and stenotic disease was observed in 198 (19.9%) of 993 patients with a score below 400, and a high correlation was found between the stenotic disease and calcium score. There are data in the literature regarding that 0 scores cannot exclude obstructive or non-obstructive CAD (22,23). A non-calcified plaque was reported in 10% and stenotic plaque in 7-8% of patients with 0 or lower scores; besides, 5% of patients with acute myocardial infarction had no calcified plaques in their coronary arteries (22). In our study, 16.6% of 602 patients with 0 scores had CAD at any stage, and 4.4% had stenotic and diffuse (grade 3-4) coronary artery disease. Thus, CT angiography shows soft plaques that cannot be detected by coronary Ca scoring, more accurately demonstrates the presence and extensiveness of the disease, and identifies the disease at an earlier stage. In a study by Budoff et al., most of the patients with 0 score and CAD were reported to have a history of diabetes and smoking (24). Further studies are needed in this population to determine who could have the disease and needs additional examination in the 0-score group.

Catheter angiography is the reference standard method for graft evaluation after coronary by-pass surgery. However, it is known that 3DVR images are especially useful in the evaluation of complex graft anatomy. In this study, 3DVR images were found to be beneficial in the evaluation of by-pass grafts, determining the graft material used, and the anatomy changed as a result of the operation. Studies on the evaluability of by-pass grafts with 64-MDCT showed that the graft segments could be evaluated at rates ranging from 95 to 100% (25). Nevertheless, surgical sutures, metallic clips, and radiographic markers may cause difficulties in the evaluation of the graft by CT. Although no significant problems occurred in the evaluation of the proximal anastomosis and graft body in the present study, there were occasional difficulties in evaluating the distal anastomosis level due to thinning of the graft diameter, metallic clip and motion artifacts, and the evaluation of native vessels due to dense calcific plaques arisen from the advanced atherosclerotic disease.

In the evaluation of stent patency, the sensitivity of 93-100% and specificity of 89-100% have been reported in studies performed with 64-MDCT (26). Recent studies have shown that the diameter of the vascular structure in which the stent is placed is also effective regarding stent evaluation. In our study, although no problems occurred in the evaluation of large diameter stents within the proximal segment or saphenous vein graft, there was difficulty in the interpretation of metallic stents, which had thick wall structure causing more blooming artifact, located in the distal segments. In the study of Cademartiri et al. (27), 1500/300 HU value was used as the optimal window setting in the evaluation of stent lumen, and 1500-1600/200-300 HU level was used as the optimal window setting in the evaluation of stent lumen opening in our study. Also, the sharp kernel, which provides a decrease in blooming artifact with an increase in edge sharpness, was used in the evaluation of stent patency apart from the standard protocol. Besides, higher concentrations of iodine (400 mg I/ml) than those used in routine coronary CT angiography were preferred to increase lumen density and to visualize intra-stent pathologies.

LIMITATIONS

There are several limitations and strengths of the present study. First, the study was retrospective and included a single center. Secondly, there was no comparison with catheter angiography, which is the gold standard imaging method. Having a large patient series is the strength of our study.

CONCLUSION

In conclusion, 64-MDCT coronary angiography is a suitable method for the noninvasive evaluation of coronary arteries. Coronary artery anomalies are observed with a non-rare frequency. There is a moderate correlation between age and CAD stage, and age and Ca score. There is a high correlation between Ca score and the CAD stage, but zero Ca score cannot exclude CAD.

Competing interests: The authors declare that they have no competing interest.

Financial Disclosure: There are no financial supports.

Ethical approval: Ethics Committee of Ankara Training and Research Hospital; 2007-1864.

REFERENCES

1. Pruthi A, Rahalkar AM, Rahalkar M. To Study Coronary Artery Stenosis on CT in Comparison with Catheter Angiography. IJCMS 2019;4:118-23.
2. Menke J, Kowalski J. Diagnostic accuracy and utility of coronary CT angiography with consideration of unevaluable results: A systematic review and multivariate Bayesian random-effects meta-analysis with intention to diagnose. Eur Radiol 2016;26:451-8.
3. Cademartiri F, La Grutta L, Malago R, et al. Prevalence of anatomical variants and coronary anomalies in 543 consecutive patients studied with 64-slice CT coronary angiography. Eur Radiol 2008;18:781-91.
4. Kini S, Bis KG, Weaver L. Normal and variant coronary arterial and venous anatomy on high-resolution CT angiography. AJR Am J Roentgenol 2007;188:1665-74.
5. Dewey M, Kroft LJM. Coronary CT Angiography. Dewey M, editor. Berlin: Springer; 2009. 11-26 p.
6. Gräni C, Benz DC, Schmied C, et al. Prevalence and characteristics of coronary artery anomalies detected by coronary computed tomography angiography in 5634 consecutive patients in a single centre in Switzerland. Swiss Med Wkly 2016;146:14294.
7. Earls JP. Coronary artery anomalies. Tech Vasc Interv Radiol 2006;9:210-7.

8. Montaudon M, Latrabe V, Iriart X, et al. Congenital coronary arteries anomalies: review of the literature and multidetector computed tomography (MDCT)-appearance. Surg Radiol Anat 2007;29:343-55.
9. Zeina AR, Odeh M, Blinder J, et al. Myocardial bridge: evaluation on MDCT. AJR AJR Am J Roentgenol 2007;188:1069-73.
10. Angelini P. Coronary artery anomalies--current clinical issues: definitions, classification, incidence, clinical relevance, and treatment guidelines. Tex Heart Inst J 2002;29:271-8.
11. Kim SY, Seo JB, Do KH, et al. Coronary artery anomalies: classification and ECG-gated multi-detector row CT findings with angiographic correlation. Radiographics. 2006;26:317-33; discussion 33-4.
12. Shi H, Aschoff AJ, Brambs HJ, et al. Multislice CT imaging of anomalous coronary arteries. Eur Radiol 2004;14:2172-81.
13. Angelini P, Cheong BY, Lenge De Rosen VV, et al. High-Risk Cardiovascular Conditions in Sports-Related Sudden Death: Prevalence in 5,169 Schoolchildren Screened via Cardiac Magnetic Resonance. Tex Heart Inst J 2018;45:205-13.
14. Harky A, Noshirwani A, Karadakhy O, et al. Comprehensive literature review of anomalies of the coronary arteries. J Card Surg 2019;34:1328-43.
15. Santos RD, Nasir K. Insights into atherosclerosis from invasive and non-invasive imaging studies: Should we treat subclinical atherosclerosis? Atherosclerosis 2009;205:349-56.
16. Oikonomou EK, Marwan M, Desai MY, et al. Non-invasive detection of coronary inflammation using computed tomography and prediction of residual cardiovascular risk (the CRISP CT study): a post-hoc analysis of prospective outcome data. Lancet. 2018;392:929-39.
17. O'Rourke RA, Brundage BH, Froelicher VF, et al. American College of Cardiology/American Heart Association Expert Consensus Document on electron-beam computed tomography for the diagnosis and prognosis of coronary artery disease. J Am Coll Cardiol 2000;36:326-40.
18. Moradi M, Nouri S, Nourozi A, et al. Prognostic Value of Coronary Artery Calcium Score for Determination of Presence and Severity of Coronary Artery Disease. Pol J Radiol 2017;82:165-9.
19. Ho JS, Fitzgerald SJ, Stolfus LL, et al. Relation of a coronary artery calcium score higher than 400 to coronary stenoses detected using multidetector computedtomographyandtotraditionalcardiovascular risk factors. Am J Cardiol 2008;101:1444-7.
20. Iwasaki K, Matsumoto T. Relationship between coronary calcium score and high-risk plaque/significant stenosis. World J Cardiol 2016;8:481-7.
21. Nappi C, Nicolai E, Daniele S, et al. Long-term prognostic value of coronary artery calcium scanning, coronary computed tomographic angiography and stress myocardial perfusion imaging in patients with suspected coronary artery disease. J Nucl Cardiol 2018;25:833-41.
22. Akram K, O'Donnell RE, King S, et al. Influence of symptomatic status on the prevalence of obstructive coronary artery disease in patients with zero calcium score. Atherosclerosis 2009;203:533-7.
23. Senoner T, Plank F, Beyer C, et al. Does coronary calcium score zero reliably rule out coronary artery disease in low-to-intermediate risk patients? A coronary CTA study. J Cardiovasc Comput Tomogr 2020;14:155-61.
24. Budoff MJ, Nasir K, McClelland RL, et al. Coronary calcium predicts events better with absolute calcium scores than age-sex-race/ethnicity percentiles: MESA (Multi-Ethnic Study of Atherosclerosis). J Am Coll Cardiol 2009;53:345-52.
25. Jones CM, Chin KY, Yang GZ, et al. Coronary artery bypass graft imaging with 64-slice multislice computed tomography: literature review. Semin Ultrasound CT MR 2008;29:204-13.
26. Jones CM, Chin KY, Hamady M, et al. Coronary stent assessment with 64-slice multislice computed tomography: a literature review. Semin Ultrasound CT MR 2008;29:214-22.
27. Cademartiri F, Mollet N, Lemos PA, et al. Usefulness of multislice computed tomographic coronary angiography to assess in-stent restenosis. Am J Cardiol 2005;96:799-802.