Surgical treatment of congenital right coronary artery aneurysm and fistula in a patient with previous aortic dissection repair

Aort disseksiyonu tamiri geçiren hastada konjenital sağ koroner anevrizma ve fistülün cerrahi tedavisi

Ersin Erek, MD, Yusuf Kenan Yalçınbas, MD, Ece Salihoğlu, MD, Tayyar Sarıoğlu, MD

Cardiovascular Surgery Department, Acıbadem Bakırköy Hospital, İstanbul, Turkey

The patient was a 58 year-old man who had supracoronary graft replacement 13 years ago due to aortic dissection type I. He had been suffering from exertional dyspnea and chest pain for 1 year with increasing severity. Treadmill exercise test revealed inferolateral myocardial ischemia. Moderate to severe mitral and moderate tricuspid valve regurgitation with enlargement of all cardiac chambers were detected on echocardiographic examination. The patient underwent coronary angiography. Left ventriculography confirmed moderate mitral regurgitation and dilated left ventricular cavity. Left coronary arteries were normal, but retrograde filling of the distal right coronary artery (RCA) through left anterior descending artery was noticed. Right coronary artery injection revealed 3x5 cm, in size coronary artery aneurysm and right atrial fistula at the midportion of the RCA (Fig 1).

The patient underwent reoperation. Cardiopulmonary bypass was commenced with right femoral artery and bi-caval cannulation. A one cm orifice was detected at the superior part of the atriotomy incision. Aneurysmal sac of the RCA fistula was located behind the orifice and near atrioventricular groove (Fig 2). The roof of the coronary artery fistula on the RCA course was opened longitudinally. Two fistula orifices, which have relationship with the aneurysmal sac were identified at the posterior part of the RCA incision. These two orifices were closed primarily and re-roofing of the RCA incision was performed with peri-

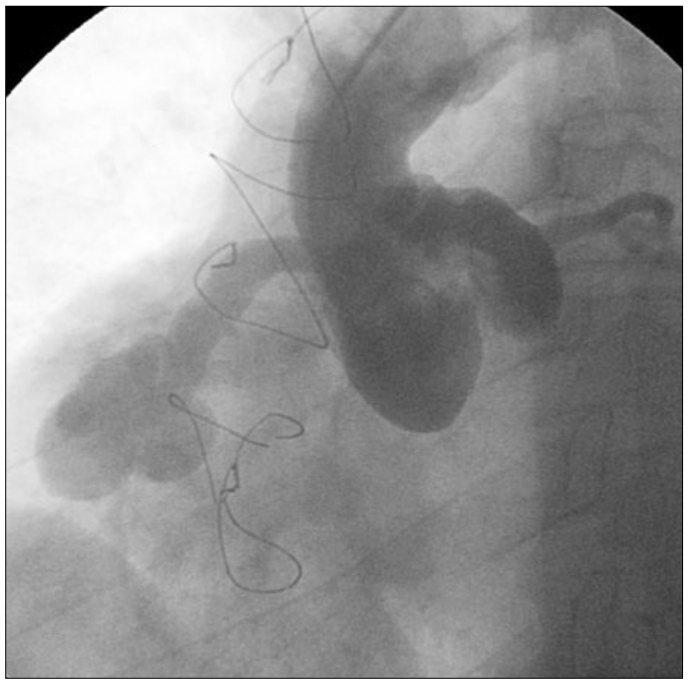

Figure 1. Coronary angiography view of the right coronary artery aneurysm and fistula in the right atrium

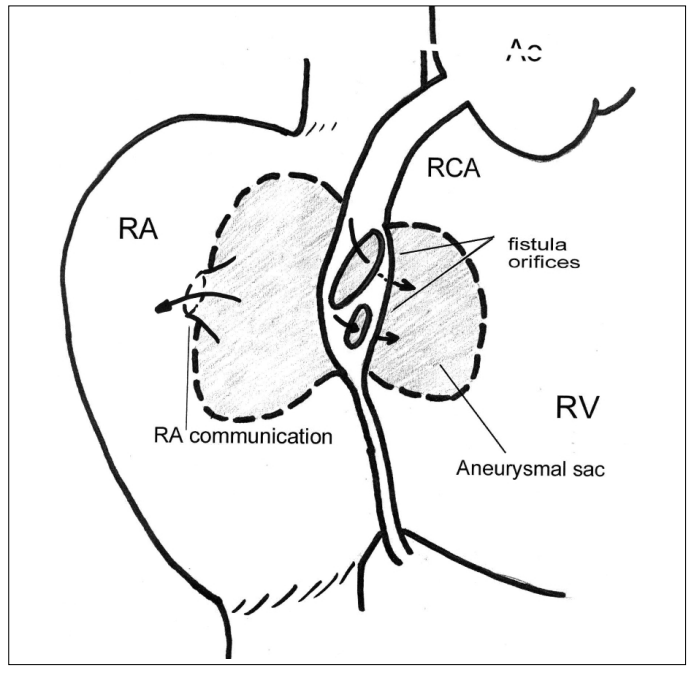

Figure 2. Location of the aneurysmal sac and its relationship with the fistula orifices (Ao: Aorta; RA: right atrium; RCA: right coronary artery, RV: right ventricle)

Address for Correspondence: Tayyar Sarıoğlu, MD, Chief of Cardiovascular Surgery Department, Acıbadem Bakırköy Hospital
Halit Ziya Uşaklıgil Cad. No.1, 34140, Bakırköy, İstanbul, Tel: 0 212 414 4408, Fax: 0 212 414 5111, e-mail: tsarioglu@asg.com.tr

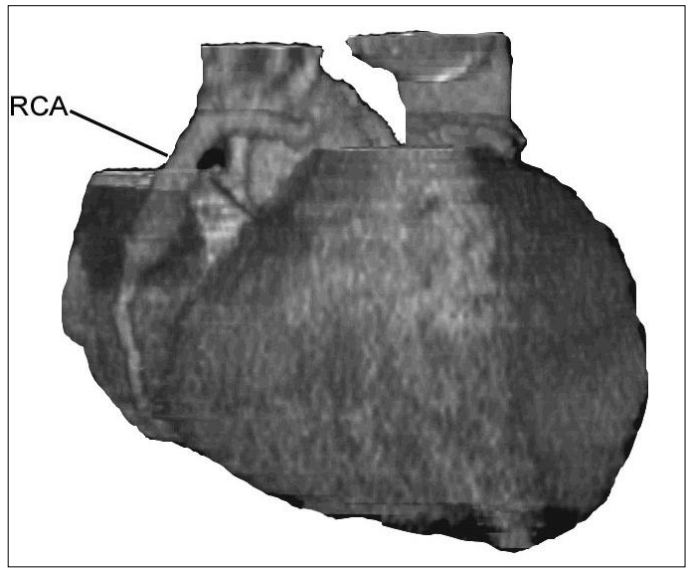

Figure 3. Electron beam tomography demonstrated no aneurysm or fistula formation on the first postoperative month.
(RCA: right coronary artery)

cardial patch. The aneurysmal sac was incorporated with the right atrium by cutting the edges of the sac from inside of the right atrium. Once fistula repair was completed, mitral ring annuloplasty and tricuspid de Vega plasty were performed.

Postoperative course of the patient was uneventful. Electron beam tomography examination revealed patent RAC without aneurysm and fistula on the first postoperative month (Fig 3).

Congenital coronary artery fistula is a rare congenital anomaly, which can be complicated by intracardiac shunts, endocarditis, myocardial ischemia, rupture and sudden death (1). To our knowledge, this patient is the first report of a case with coronary artery fistula and aneurysm formation with a history of aortic dissection repair, except for one case with annuloaortic ectasia and left coronary artery aneurysm and fistula (2).

References

1. Özer S, Özkutlu S, Sarıoğlu T, Sarıkayalar F, Ertuğrul A, Bilgiç A. Konjenital koroner arter fistülleri. Çocuk Sağlığı ve Hastalıkları Dergisi 1985;28:135-44.
2. Kazui T, Washiyama N, Muhammad BA, Yamashita K, Takinami M, Miura K. Surgical treatment of annuloaortic ectasia with coronary aneurysm and fistula. Ann Thorac Surg 2001;71 : 2018-9.

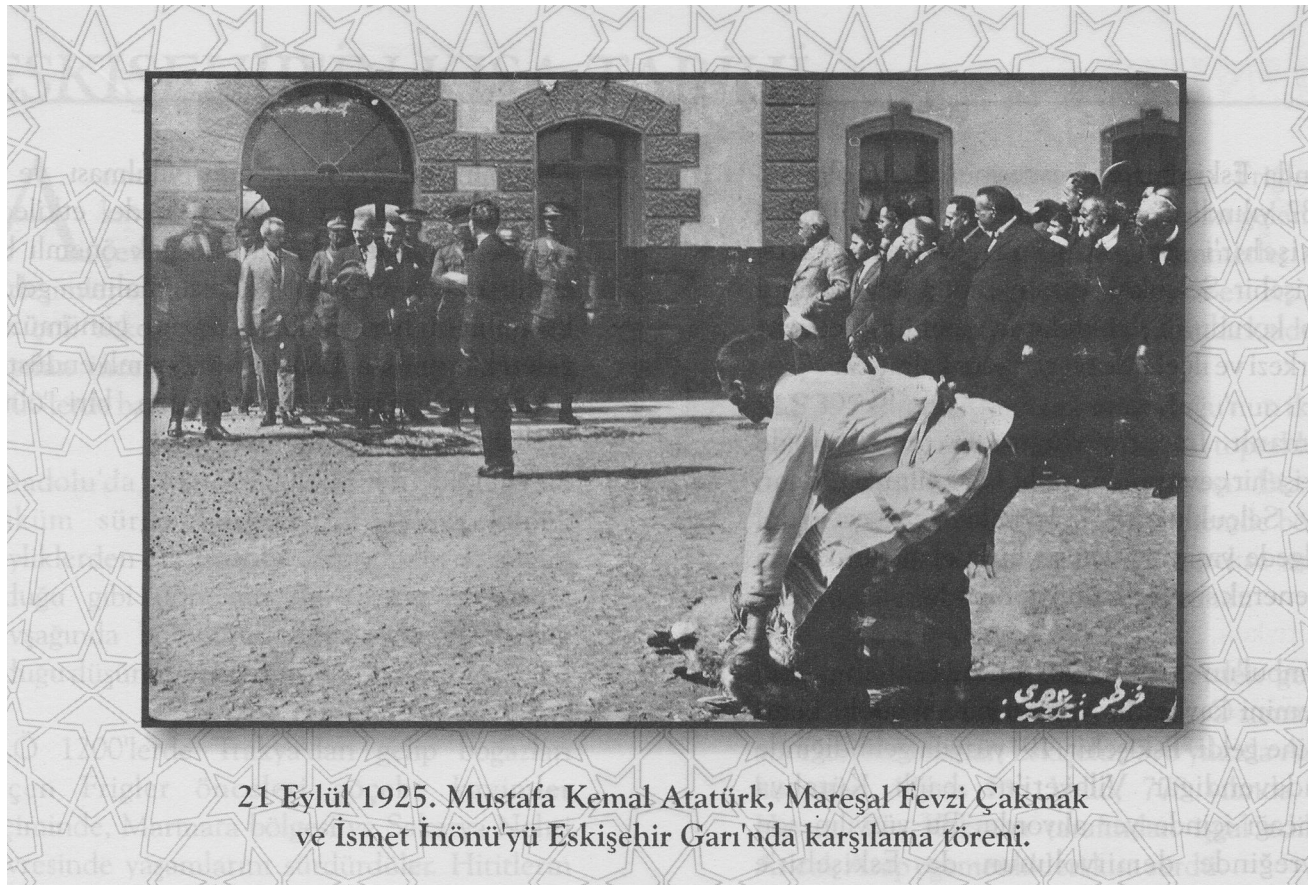

21 Eylül 1925. Mustafa Kemal Atatürk, Mareşal Fevzi Çakmak ve İsmet İnönü'yü Eskişehir Garı'nda karşılama töreni.