doi: 10.5505/abantmedj.2015.93723

Abant Medical Journal

Olgu Sunumu / *Case Report*

Volume Cilt 4 *Issue* Sayı 4 *Year* Yıl 2015

Left Free Wall Dual Accessory Pathway in Wolf Parkinson White Syndrome; A Rare Entity

Sol Serbest Duvarda Çift Aksesuar Yolun Olduğu Wolf Parkinson White Sendromunun Nadir Bir Antitesi

Mesut Aydın, Abdulkadir Yıldız, Murat Yüksel, Mehmet Zihni Bilik, Yahya İslamoğlu

Dicle Üniversitesi Tıp Fakültesi, Kardiyoloji Anabilim Dalı, Diyarbakır

Özet

Wolff-Parkinson-White sendromu ile bir erkek hasta başvurdu. Elektrofizyolojik çalışma yapıldı. Sol ventrikülde posterolateral ve lateral olmak üzere iki aksesuar yol tespit ettik. Radyofrekans enerji ile çift aksesuar yol ablasyonu başarılı bir şekilde yaptık. Elektrokardiyografi aksesuar yolun yerini tespit etmede en önemli invaziv olmayan tek araçtır. Bizim vakamızda EKG'de V1-6, I, II, aVL (+) olarak gördük. Sol taraflı aksesuar yol olduğunu gösteriyordu. Posterolateral yol aksesuar yol ablasyonu yapıldıktan sonra aVL'nin negatif olduğunu gördük bu da sol lateral aksesuar yol olduğunu gösteriyordu. Çoklu aksesuar yollar belli kombinasyonlarda bulunur fakat çoklu aksesuar yollar arasında sağ posteroseptal ve sağ serbest duvar aksesuar yolların birlikte bulunması daha sıktır. Bizim olgumuzun özelliği çift yolun sol serbest duvarda olmasıydı.

Anahtar Kelimeler: Wolf Parkinson White sendromu, aksesuar yol, elektrokardiografi.

Abstract

A seventeen year-old male presented with Wolff-Parkinson-White syndrome. Electrophysiology study was performed. Two accessory pathways were detected at left ventricle lateral and posterolateral locations. We performed a successful radiofrequency ablation to these dual accessory pathways. Electrocardiography is the single most important noninvasive tool for identifying the presence of an accessory pathway. In our case, V1-V6, I, II, aVL were positive on baseline ECG. This was a sign of left sided accessory pathway. After elimination of posterolateral accessory pathway, aVL was negative indicating a left free wall accessory pathway. Multiple pathways are found in any combination but there is a higher incidence of right free wall and posteroseptal pathway coexistence in patients with multiple pathways than in those with a single pathway. Otherwise, in our case both of the accessory pathways were in left free wall.

Keywords: Wolf Parkinson White syndrome, accessory pathway, electrocardiography.

Introduction

Wolff-Parkinson-White (WPW) syndrome is a common cause of supraventricular tachycardia. The WPW syndrome is a reentrant tachycardia with an anatomically defined circuit that consists of two distinct pathways, the normal atrioventricular (AV) conduction system and an AV accessory pathway (AP), linked by common atrial and ventricular tissues. It has associated morbidity and mortality over the years (1). There is a well-established relationship between the presence of symptoms and the risk of sudden death. Catheter ablation is the therapy of choice in symptomatic patient with WPW syndrome (2). This management requires precise mapping of the AP and identification of other pathways. Failure to recognize the existence of multiple pathways can result in recurrent tachycardia after catheter ablation. Multiple APshave been reported in many previous studies (2,3). Here, we are reporting a case of WPW syndrome with dual accessory pathway who underwent successful radiofrequency (RF) catheter ablation.

Case report

A 17-year-old male presented with episodes of palpitation. He had short episodes of palpitation for five years. However, duration and frequency of palpitation episodes are increasing and accompanying shortness of breath and atypical chest pain developed for a few months. On physical examination his blood pressure was 105/60 mmHg and he had regular pulse rhythm (65 beats/min). Lung auscultation was normal. On electrocardiogram (ECG) a short PR interval and a wide QRS wave with delta waves in 12leadswere noticed (Figure 1).On this ECG, delta wave was positive (+) in

İletişim Bilgisi / Correspondence

Yard. Doç. Dr. Mesut Aydın, Dicle Üniversitesi Tıp Fakültesi, Kardiyoloji Anabilim Dalı, Diyarbakır

E-mail: hekimmesut@yahoo.com

Geliş tarihi / *Received*: 25.08.2014 **Kabul tarihi / Accepted:** 09.09.2014 **Çıkar Çatışması / Conflict of Interest:** Yok / None

aVL lead which excluded left lateral accessory pathway. On transthoracic echocardiography, normal cardiac function was observed. He was not using any medicines. Electrophysiology study (EPS) was performed at our institution. Quadripolar electrode catheters were inserted percutaneously under local anesthesia after premedication, through the right femoral vein and were positioned at high right atrium and the coronary sinus. Intracardiac electrograms and 12-lead surface ECG were continuously monitored. Standard baseline AH, HV intervals were obtained. Measured AH, and HV intervals were 82, and 0 milliseconds, respectively. Location of the AP was detected by intracardiac mapping and successful ablation was peformed in the left anterior oblique projection. Ventricular activation appeared earliest at lateral and posterolateral location. Multiple APs were considered to be present only if the distance between 2 APs was >1 cm (4). Two APs were detected at left ventricule lateral and posterolateral locations. The RF catheter was inserted through aorta retrogradely to the left ventricle. Firstly, RF ablation was performed by applying RF pulses of 50 watt output and 55-60°C at posterolateral location. The adjacent AV was splitted at posterolateral location but AV was persisting at lateral location and pre-exitation was decreased on ECG (Figure 2, 3). Secondly, RF ablation was performed at lateral location (Figure 4). The AV was splitted completely and pre-excitation was lost on ECG (Figure 5).RF ablation was performed for a total of 180 seconds. The scopy time was 35 minutes. During RF application, catheter position was continuously monitored with fluoroscopy. PR, QRS, AH and HV intervals were 156, 96, 82 and 41 miliseconds, respectively. The patient was observed for 30 minutes after successful ablation, and programmed electrical stimulation was repeated to confirm that the AP was interrupted before the removal of the catheters. Atropine was intravenously administered to reveal AP conduction recurrence. While ventriculoatrial conduction wasn't present, no tachycardia was induced. No complication developed during the procedure and aspirin was given for the next four weeks. He was examined a month later in outpatient clinics with a normal ECG and experiencing no palpitation for this period (Figure 6).

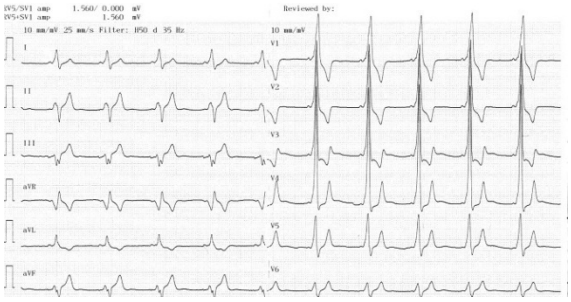

Figure 1: Baseline electrocardiography.

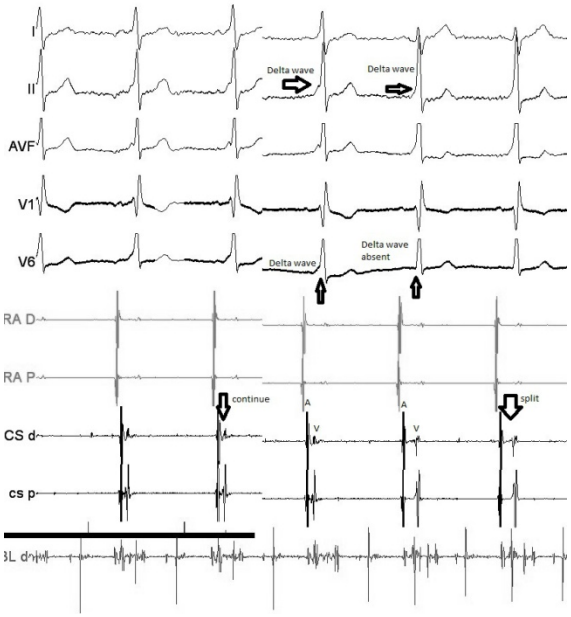

Figure 2: The ablation of posterolateral accessory pathway. Simultaneous recordings of surface leads together with high rigth atrium, coronary sinus and ablation catheter electrogram. A: atrial depolarization; V: ventricular depolarization; CSp, and CSd: proximal, and distal coronary sinus electrograms; RA: right atrial electrogram; BLd: ablation electrogram.

Discussion

The AV node generally forms the sole connection between atrial and ventricular tissues, with the remainder of these structures separated by the fibrous annulus that forms the scaffolding for the mitral and aortic valves. Accessory pathway cause another connection between atrial and ventricular tissues. Detailed clinicopathologic studies have shown that APs comprise microscopic strands of

morphologically normal myocardium that are located along the cardiac annulus or septum (5). Accessory pathways can usually conduct in both directions, from atrium to ventricle and from ventricle to atrium.

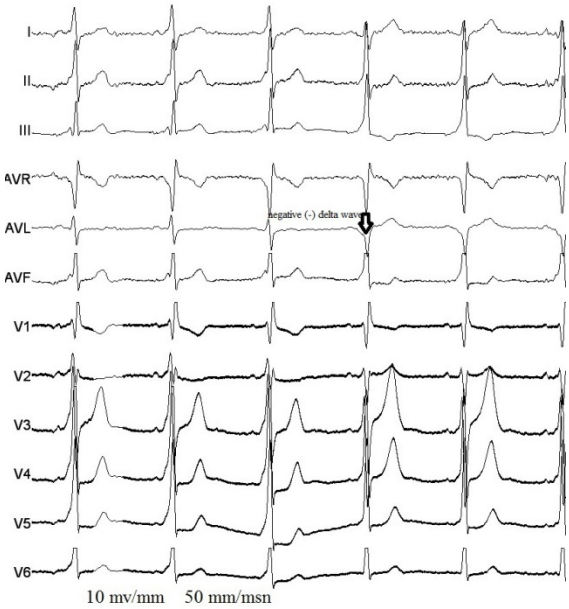

Figure 3: The electrocardiography of lateral accessory pathway, after ablation posterolateral accessory pathway.

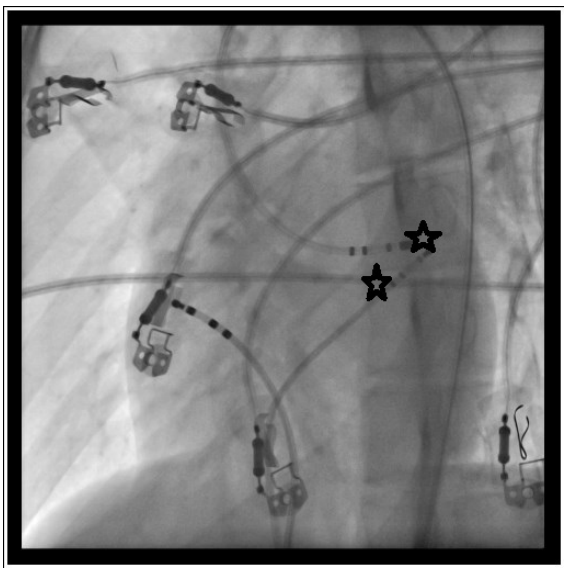

Figure 4: Fluoroscopic image is obtained in the left anterior oblique orientation. Stars: Locations of accessory pathway and ablation.

The WPW syndrome is a special type of AVRT. This is a manifest form of AVRT. Patients with the WPW pattern on ECG have a short PR interval and a slurred upstroke of the QRS complex (delta wave) but may never have any arrhythmias. Those who have WPW syndrome have both the WPW ECG pattern and paroxysmal tachyarrhythmia's (1).

There is a well-established relationship between the presence of symptoms and the risk of sudden death. On the other hand, in asymptomatic WPW patients, sudden death rate is low and is estimated to be about 1 per 1000 patient-years (1). Ventricular fibrillation has been reported to occur in 2.2% of symptomatic WPW patients over a 16-year period (6).

Multiple APs are reported to occur in 3% to 22% of patients with WPW syndrome (2,3). In this series, multiple pathways were found in any combination but there was a higher incidence of right free wall and posteroseptal pathway coexistence in patients with multiple pathways than in those with a single pathway. Otherwise, in our case both of the accessory pathways were in left free wall.

ECG is the single most important noninvasive tool for identifying the presence of an AP. In a patient with a right-sided AP the QRS complex will be negative in V1 and positive in the lateral leads V5, V6, I, and aVL. Conversely, in a patient with a left-sided AP QRS complex will be positive in V1. If the AP is located at lateral wall of the mitral annulus, the delta wave will be negative in I and aVL due to ventricular depolarization traveling away from this area. If the AP is located more inferiorly and closer to the septum delta waves will be negative in inferior leads (II, III, and aVF) (7). More than 50% of APs are located at left free wall, 20-30% at posteroseptum, 10-20% at right free wall, and 5-10% at anteroseptum (8). In our case, V1-V6, I, II, aVL were positive on baseline ECG (Figure 1). This was a sign of leftsided AP. After elimination of posterolateral AP, aVL was negativeindicating a left free wall AP (Figure3). Catheter-based ablative techniques using RF energy have been used extensively to eliminate APs effectively and safely (9). Based on recommendations from 2003 American College of Cardiology/American Heart Association/European Society of Cardiology guidelines, asymptomatic preexcitation is associated with a class IIa indication for

catheter ablation (10). We performed a successful RF ablation to these dual APs.

Especially in symptomatic patients with WPW syndrome catheter ablation is the treatment of choice for relieving palpitation and risk of sudden death. Presence of multiple APs should be kept in mind during RF ablation.

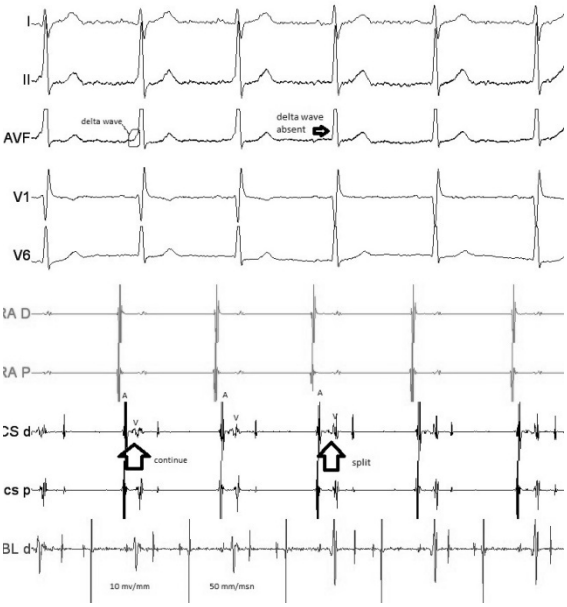

Figure 5: The ablation of lateral accessory pathway. Simultaneous recordings of surface leads together with high rigth atrium, coronary sinus and ablation catheter electrogram. A: atrial depolarization; V: ventricular depolarization; CSp, and CSd: proximal, and distal coronary sinus electrograms; RA: right atrial electrogram; BLd: ablation electrogram.

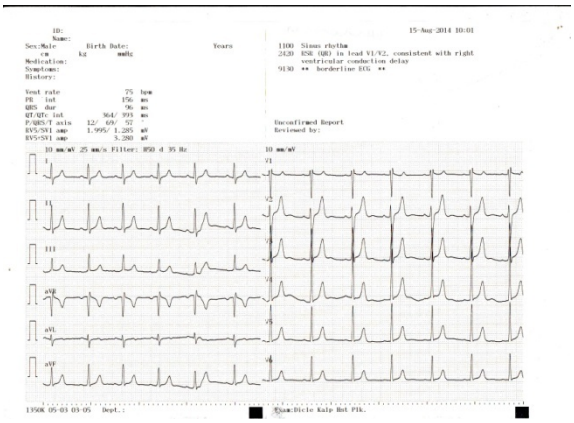

Figure 6: Electrocardiography with sinus rhythm.

References

1. Fitzsimmons PJ, McWhirter PD, Peterson DW, Kruyer WB.The natural history of Wolff-Parkinson-White syndrome in 228 military aviators: a long-term follow-up of 22 years. Am Heart J 2001;142:530-6.
2. Calkins H, Langberg J, Sousa J, el-Atassi R, Leon A, Kou W, Kalbfleisch S, Morady F. Radiofrequency catheter ablation of accessory atrioventricular connections in 250 patients. Abbreviated therapeutic approach to Wolff-Parkinson-White syndrome. Circulation 1992;85:1337–46.
3. Colavita PG, Packer DL, Pressley JC, Ellenbogen KA, O'Callaghan WG, Gilbert MR, German LD. Frequency, diagnosis and clinical characteristics of patients with multiple accessory atrioventricular pathways. Am J Cardiol 1987; 59:601–6.
4. Weng KP, Wolff GS, Young ML.Multiple accessory pathways in pediatric patients with Wolff-Parkinson-White syndrome.Am J Cardiol 2003; 91:1178-83.
5. Peters NS, Rowland E, Bennett JG, Green CR, Anderson RH, Severs NJ. The Wolff-Parkinson-White syndrome: the cellular substrate for conduction in the accessory atrioventricular pathway. Eur Heart J 1994;15:981-7.
6. Kusomoto F. Understanding Intracardiac EGMs and ECGs. Mayo Clinic. 2010;107-31
7. Timmermans C, Smeets JL, Rodriguez LM, Vrouchos G, van den Dool A, Wellens HJ. Aborted sudden death in the Wolff-Parkinson-White syndrome. Am J Cardiol 1995;76:492-4.
8. Wellens HJ, Atie J, Penn OC, Gorgels AP, Brugada P, Smeets JL. Diagnosis and treatment of patients with accessory pathways. Cardiol Clin 1990;8:503-21.
9. Jackman WM, Wang XZ, Friday KJ, Roman CA, Moulton KP, Beckman KJ, et al. Catheter ablation of accessory atrioventricular pathways (Wolff-Parkinson-White syndrome) by radiofrequency current. New Engl J Med 1991;324:1605-11.
10. Blomstrom-Lundqvist C, Scheinman MM, Aliot EM, Alpert JS, Calkins H, Camm AJ, et al. ACC/AHA/ESC guidelines for the management of patients with supraventricular arrhythmias—executive summary. A report of the American College of Cardiology/American Heart Association task force on practice guidelines and the European Society of Cardiology committee for practice guidelines (writing committee to develop guidelines for the management of patients with supraventricular arrhythmias) developed in collaboration with NASPE-Heart Rhythm Society. J Am Coll Cardiol 2003;42:1493-531.