Turkish Journal of Thoracic and Cardiovascular Surgery 2020;28(4):708-724
http://dx.doi.org/doi: 10.5606/tgkdc.dergisi.2020.19614

***Review** / Derleme*

Minimal access in cardiac surgery

Kalp cerrahisinde minimal erişim

Burak Onan

Depatment of Cardiovascular Surgery,
University of Health Sciences, Mehmet Akif Ersoy Thoracic and Cardiovascular Surgery Hospital, Istanbul, Turkey

ABSTRACT

Over the past two decades, minimally invasive cardiac surgery has been adopted with the use of endoscopic methods in 1990s and advanced robotic surgery since the early 2000s. In parallel with technological developments, surgical experience has increased and several cardiac operations are able to be performed using different mini-incisions. In this review, we discuss approaches to minimally invasive cardiac surgery, incisions, technical details, and suggestions.

Keywords: Minimally invasive cardiac surgery, surgical approach, surgical incision.

ÖZ

Minimal invazif kalp cerrahisi, 1990'lı yıllarda endoskopik yöntemlerin uygulanmaya başlanması ve ardından 2000'li yılların başından itibaren robotik cerrahinin hız kazanmasıyla son 20 yıldır gelişim göstermiştir. Teknolojik gelişmelerle birlikte cerrahi deneyim artmış ve de farklı mini-insizyonlar ile birçok kardiyak ameliyat yapılabilir hale gelmiştir. Bu derlemede, minimal invazif kalp cerrahisinde kullanılan yaklaşımlar, insizyonlar, teknik detaylar ve öneriler sunulmaktadır.

Anahtar sözcükler: Minimal invazif kalp cerrahisi, cerrahi yaklaşım, cerrahi insizyon.

Traditionally, cardiac operations have been performed through a sternotomy incision and this approach has led to the accumulation of knowledge, experience, and new techniques in the armamentarium of cardiovascular surgery community.[1-3] Following the development of new techniques, the first procedures were minimally invasive aortic valve procedures through parasternal incisions through the third intercostal space with division of the ribs.[4-6] These procedures were followed by mitral valve and myocardial revascularization procedures through thoracotomy and hemi-sternotomy incisions. Since the mid-1990s, minimally invasive cardiac surgery (MICS) has rapidly gained popularity through pioneers in the field, such as F.J. Benetti and H. Vanermen.[1,4] After 2000s, minimal incisions have gained popularity in the community.[1-6] Minimally invasive port-access surgery has proved its safety and feasibility worldwide.[6,7] Finally, robotically-assisted totally endoscopic surgery has been widely used during the last two decades.[8-20] Minimally invasive cardiac surgery provides reduced surgical trauma, less complication, better rehabilitation period, as well as a higher patient comfort and cosmesis.[1-20]

In MICS, cardiac surgeons treat a variety of complex conditions through small incisions (Table 1). These approaches provide maximum benefit for patients with preoperative comorbidities such as advanced age, renal failure, obstructive lung disease, or neurological events.[1-7] Although surgeons may sometimes hesitate to perform routine cardiac procedures through alternative mini-incisions, the outcomes of such patients would be higher in the postoperative period compared to the use of full median sternotomy incision. Although every patient is not a candidate for MICS, the minimally invasive treatment teams decide to whether minimally invasive surgery can be an alternative option.

Received: March 04, 2020 *Accepted*: May 01, 2020 *Published online*: October 21, 2020

Correspondence: Burak Onan, MD. SBÜ Mehmet Akif Ersoy Göğüs Kalp ve Damar Cerrahisi Eğitim ve Araştırma Hastanesi, Göğüs Cerrahisi Kliniği, 34303 Küçükçekmece, İstanbul, Türkiye. Tel: +90 553 - 622 38 78 e-mail: burakonan@hotmail.com

Cite this article as:
Onan B. Minimal access in cardiac surgery. Turk Gogus Kalp Dama 2020;28(4):708-724

©2020 All right reserved by the Turkish Society of Cardiovascular Surgery.
This is an open access article under the terms of the Creative Commons Attribution-NonCommercial License, which permits use, distribution and reproduction in any medium, provided the original work is properly cited and is not used for commercial purposes (http://creativecommons.org/licenses/by-nc/4.0/).

Table 1. Operations, mini-incisions, and alternative approaches in minimally invasive cardiac surgery

Operations	Incisions	Surgical approach
Mitral valve repair and replacement	Mini-thoracotomy (right-sided) Mini-sternotomy	Direct vision Video-assisted (port-access) Robotic surgery
Tricuspid valve repair and replacement	Mini-thoracotomy (right-sided) Mini-sternotomy	Direct vision Video-assisted (port-access) Robotic surgery
Aortic valve replacement	Mini-sternotomy (upper partial) Mini-thoracotomy (right anterior)	Direct vision
Ascending aorta and arch surgery	Mini-sternotomy (upper partial)	Direct vision
Coronary artery bypass surgery	MIDCAB, mini-thoracotomy (left-sided) MICS, mini-thoracotomy (left-sided) Robotic surgery	Direct vision Robotic TECAB
Atrial septal defect and patent foramen ovale closure	Mini-thoracotomy (right-sided) Mini-sternotomy (lower partial)	Direct vision Video-assisted (port-access) Robotic surgery
Cardiac tumor resection	Mini-thoracotomy (right-sided) Mini-sternotomy (upper partial) Video-assisted or robotic surgery	Direct vision Video-assisted (port-access) Robotic surgery
Maze procedure for atrial fibrillation	Mini-thoracotomy, Mini-sternotomy Video-assisted or robotic surgery	Direct vision Video-assisted (port-access) Robotic surgery

MIDCAB: Minimally invasive direct coronary artery bypass; MICS: Minimally invasive cardiac surgery; TECAB: Totally endoscopic coronary artery bypass grafting.

HOW TO START

The number of patients who request to have MICS with a smaller incision have increased during the last decade. This tendency of population has eventually led to some changes in daily practice and surgical approaches. Cardiac surgeons are also willing to perform MICS procedures; however, they should go step-by-step into the depths of MICS.

There are some massages below for surgeons who desire to start a minimally invasive program.

1. "Safety first." This is the first rule. Do not hesitate for conversion, if a major complication occurs. Do not insist on completing the procedure you are performing using an unfamiliar incision, instruments, and technique for the initial cases.
2. Cardiac surgery centers should have considerable experience in daily surgical practice in various procedures before starting a minimally invasive program.
3. Preoperative decision making for surgical strategy is reasonable. You should decide what you would do (repair or replacement), think which incision is good for exposure and how you can reach your target anatomy.
4. Use a check list for the availability of surgical instruments before the procedure.
5. Start with a larger incision for uncomplex or simple pathology in the beginning of your initial experience. To illustrate, it is better to perform atrial septal defect closure through a mini-thoracotomy rather than a complex mitral repair or replacement.
6. Minimally invasive operations with partial sternotomy or larger thoracotomy of 6 to 10-cm long can be performed using conventional tools or less complex toolset. For instance, aortic valve replacement through a J-sternotomy can be done using conventional instruments.
7. If you use a smaller thoracotomy incision of 4 to 6-cm in the anterior axillary line, you need specialized instruments such as long-shafted scissor, needle holders, knot-pusher, hook, long-shafted cautery blade, and soft-tissue retractors (Figure 1, Table 2). A long shafted cardioplegia needle and atraumatic vascular bulldog clamps can be also used.

Soft-tissue retractors and trocars | **Long-shafted instruments for MICS** | **Instruments for robotic surgery**

Figure 1. Instruments for minimally invasive cardiac surgery.

8. A Chitwood® clamp (ESTECH Inc., CA, USA) is mostly used during mini-thoracotomy procedures.
9. Do not forget defibrillation pads.
10. Decide what kind of plegia solution you would use during the procedures (blood cardioplegia for every 20 min, Custodiol® (Methapharm Inc., Brantford, ON, Canada) for 120 min + second dose or del Nido solution for 60 min + second dose).
11. Proctoring in the learning curve. It is recommended to have a proctor ready for initial 20 to 30 cases.
12. The team should include an experienced cardiac anesthesiologist for transesophageal echocardiography (TEE) which is essential for

Table 2. Basic list of long-shafted instruments for MICS via mini-thoracotomy incision or robotic surgery

No	Instruments
1	MICS atraumatic de Bakey forceps (Length: 360 mm curved dia. 5 mm)
2	MICS scissor (Length: 360 Mm)
3	MICS needle holder (Length: 360 Mm, Curved)
4	Three-dimensional atrial retractor with articulated blades (3 Blades: 35×40 Mm & 35×50 Mm & 45×50 Mm)
5	MICS knot pusher (Length: 360 mm, adjustable or fixed length)
6	Rib retractor, curved blades with various size
7	MICS suture catcher (Length: 280 mm)
8	MICS transthoracic aortic clamp (Length: 320 mm, Jaws: 68 mm)
9	MICS nerves & vessel double hook (Length: 300 mm)
10	MICS suture ruler (Length: 380 mm)

MICS: Minimally invasive cardiac surgery
Notes:
1. This is a basic list and revision is optional, when necessary.
2. Sizes and lengths of instruments are optional.
3. Additional instruments should be available (optional) in case of contamination or fall from the operating table.

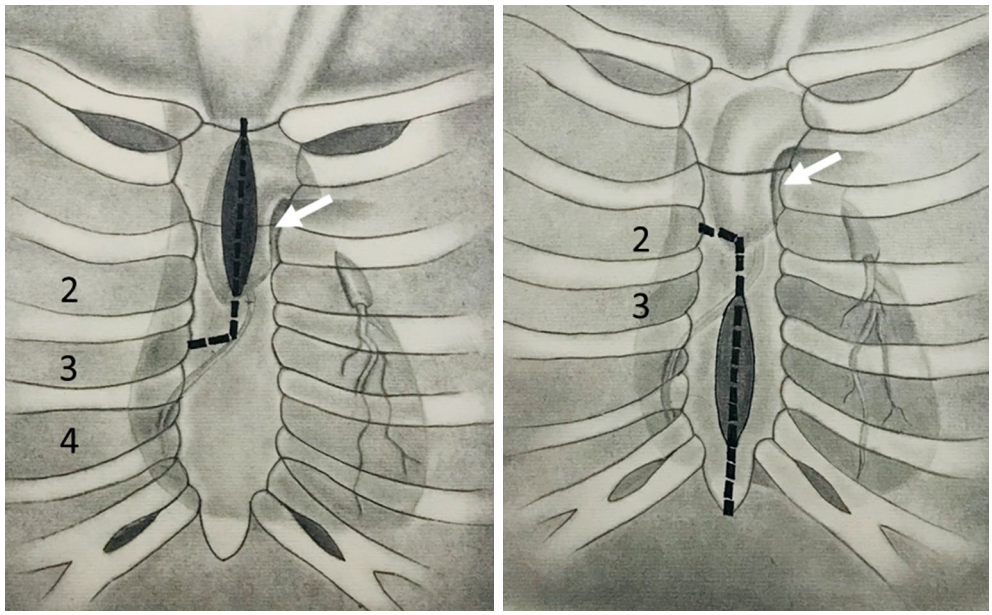

Figure 2. Illustrations of upper (left view) and lower (right view) partial sternotomy.

preoperative analysis of cardiac pathology and peripheral cannulation.

13. Transesophageal echocardiography is essential during weaning from cardiopulmonary bypass (CPB), as the surgeon does not see the heart and cardiac functions at the end of closed chest cardiac procedures. Be aware that the heart is hypovolemic or has poor contractility and needs inotropic support.
14. Be patient and open to new techniques, read the recent literature, be aware of the cutting-edge technology.
15. Collect the data of your patients for academical purposes.

OPERATIVE TECHNIQUES AND INCISIONS

Technically, five major incisions have been widely utilized in MICS: upper hemi-sternotomy, lower hemi-sternotomy, right anterior mini-thoracotomy (RAT), right anterolateral mini-thoracotomy and robotic-assisted totally endoscopic approach.[1-22] Additionally, a left-sided mini-thoracotomy incision is utilized during minimally invasive direct coronary artery bypass grafting (MIDCAB).[15,17] Totally endoscopic robotic coronary revascularization is completely different approach that uses 1 to 1.5 cm port incision without a thoracotomy incision.

UPPER MINI-STERNOTOMY

Currently, this is the most preferred incision for minimally invasive aortic valve surgery.[21-23] The technique is the J-shaped upper mini-sternotomy incision (Figures 2 and 3). The outcomes of this approach are almost equivalent to those of traditional aortic valve surgery done in experienced centers.[21-23] Reduced pain, less bleeding, shorter hospital stay, and reduced costs are associated with J-sternotomy aortic valve procedures. Early mobilization and rehabilitation

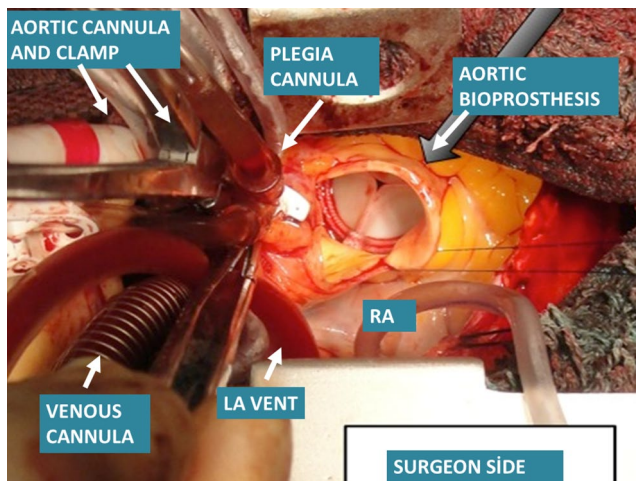

Figure 3. J-sternotomy for aortic valve replacement.
RA: Right anterior; LA: Left anterior.

is a major advantage. Herein, I will give some surgical details for aortic valve replacement via J-sternotomy.

Principal steps

1. The patient lies in supine position with the sternum elevated. Place a soft bag between both scapulae.
2. Perform a 6 to 8-cm skin incision in the midline and define the 3rd or 4th intercostal space on the right. A right-sided sternal incision is useful in most cases.
3. Incise the sternum between the jugular area and the 3rd intercostal space on the right. The 4th intercostal space can be used according to preoperative location of the aortic valve.
4. The internal thoracic artery (ITA) can be clipped and divided to prevent postoperative bleeding.
5. After J-sternotomy, a minimally invasive sternal retractor is placed, the substernal fats are dissected, and the pericardium is opened.
6. The pericardium is pulled up with stay sutures, which allow excellent exposure.
7. The surgical procedure can be performed with central or peripheral cannulation.
8. Introduce a long-shafted clamp just below the xiphoid and place a straight 32-F chest tube below the xiphoid process immediately after starting CPB.
9. Use continuous carbon dioxide (CO_2) insufflation to minimize the risk of air embolism.
10. The left atrium is vented through the right upper pulmonary vein or pulmonary artery.
11. After aortic clamping, antegrade cardioplegia is delivered and arrest is established.
12. Aortic valve is replaced using conventional instruments.
13. Epicardial pacing wires are placed before the removal of the aortic cross-clamp.
14. Sternal closure is achieved with three to five stainless steel wires, and the subcutaneous tissue and skin are closed.

Pearls and pitfalls

1. Have a considerable experience in routine aortic valve replacement before doing this. You must have the skills to manage potential complications of aortic surgery. Be tolerant, take your time, and do not hurry.
2. The initial patients can be non-obese male patients with a good anatomy.
3. The whole sternum should be accessible in case of an emergency sternotomy. It is helpful to mark anatomical landmarks such as the jugular area, sternum, and xiphoid process preoperatively.
4. Prepare the groin area for the possibility of peripheral cannulation, if the anatomy is unsuitable for central cannulation.
5. An oscillating sternal saw used in reoperations can be used.
6. A left-sided partial sternotomy can be done, if the aortic valve is placed on the left side of the sternum. Use preoperative chest X-rays and computed tomography (CT) to define the place of the aortic valve.
7. Use the 4th intercostal space for J-incision in case of low-lying aortic valve.
8. Always check the ITA and vein that can be injured during sternal retraction. Despite no bleeding at the end of the procedure due to spasm, any injury to these structures may cause exploration postoperatively.
9. To have a better exposure, fixate pericardial stay sutures to the skin on both sides pulling the pericardial edges, and then re-replace the retractor. This helps for exclusion of subcutaneous tissues from the surgical field.
10. Blood pressure may decrease due to pulling the heart and disturbance of preload. In such cases, cooperate with your anesthesiologist.
11. Peripheral cannulation can be a reasonable choice for a better exposure. If venous drainage is unsatisfactory, cannulation of the superior vena cava (SVC) is simple with this incision.
12. If central cannulation will be done, peripheral artery cannulas (those for the femoral arteries) can be used with the Seldinger technique. Soft malleable two-staged venous cannulas can be preferred to achieve a good exposure.
13. Pulling the two-stage venous cannula after fixation to the snare may provide a better exposure of the aortic valve.

14. Place mediastinal chest tube immediately after CPB, since it would not be possible at the end of the operation due to a beating heart. First, make a skin incision in the midline below the xiphoid, feel the xiphoid process with the tip of the clamp, insert the clamp gently sliding the cartilage, use the second finger of your left hand through the J-incision for safety during clamp insertion to the pericardial space, and then hold the chest tube via sternal incision and take it out.
15. Aortic clamp can be placed after elevating the ascending aorta for a better exposure.
16. The aortic valve orifice or pulmonary artery can be used for venting of the left heart.
17. Cardioplegia strategy is important. In aortic stenosis, antegrade delivery of plegia is simple and safe, whereas it would be difficult to place a retrograde plegia cannula in aortic regurgitation. Instead, direct osteal plegia cannulas can be used to deliver plegia solution.
18. Alternative cardioplegia solutions such as del Nido or Custodiol® can be used.
19. Put pledgeted sutures first on the annulus of the right coronary sinus for a better exposure. Gentle traction also helps.
20. During sternal wiring, you can use a spoon via the incision. The lowest wire should be placed diagonally to decrease the tangential forces on the mobile segment.

Limitations and handicaps

As we all know, the superiority of mini-incisions is controversial at some situations. In J-sternotomy, concomitant procedures can be a limitation or need experience. This technique can be challenging in patients undergoing aortic surgery and concomitant coronary revascularization, mitral or tricuspid valve surgery. Although concomitant aortic and mitral valve procedure is possible with J-sternotomy, surgeons may use this incision after having an extensive experience with this approach. Aortic root should be evaluated in detail according to the surgical plan. In the learning curve period, extensive reconstruction procedures should not be preferred. Similarly, root infections, abscess and intracardiac shunts may be a candidate for open surgery. Chest wall deformities such as pectus excavatum or scoliosis can be a limitation. Ascending aorta aneurysms and proximal arch pathologies can be treated using this incision in experienced centers.[21-23] Reoperation cases can be preferred in the later stages of surgical experience. Patients with a porcelain aorta should be excluded.

Take-home messages

A J-sternotomy incision is a good, feasible, and safe alternative to median sternotomy for aortic valve replacement and aortic surgery. The use of specially designed instruments is not needed; conventional instruments can be used during J-sternotomy procedures. Technically, the surgeons need to know how to give a better exposure and myocardial protection during these procedures. Therefore, previous experience on routine procedures and proctoring can be beneficial for the safety reasons in the initial cases.

LOWER MINI-STERNOTOMY

A lower mini-sternotomy incision is a less commonly used incision for mitral valve repair or replacement, tricuspid vale procedures, atrial septal defect closure, or cardiac tumor excision (Figures 2 and 4).[24] The preservation of the upper sternum provides a better stability of the thoracic wall, improved respiratory functions, and faster rehabilitation period. The major advantage of this approach is the ability to directly cannulate and cross-clamp the aorta. The operative set-up and technique are similar to full sternotomy. It does not need extensive experience on MICS, either. Traditional instruments are used. The advantages of this incision is the preservation of the upper sternum, the angle of Louis, and the manubrium in elderly patients with osteoporotic sternal bone, as well as in adults with obstructive lungs.

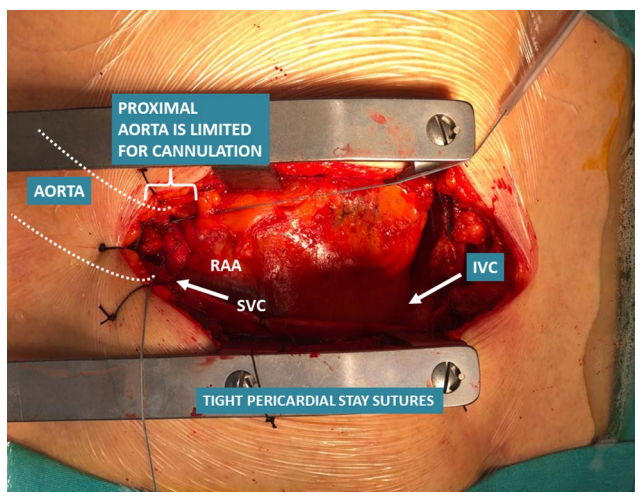

Figure 4. Lower partial sternotomy incision.
RAA: Right atrial appendage; SVC: Superior vena cava; IVC: Inferior vena cava.

Principal steps

1. No need for specialized instruments.
2. Supine positioning and chest elevation are helpful.
3. Mark the anatomical landmarks including intercostal spaces, jugular area, and xiphoid process.
4. A 6 to 8-cm skin incision is done between the level of the 3rd or 4th intercostal space and the xiphoid process.
5. The upper end of sternal incision is extended into the right 2nd or 3rd intercostal space. The manubrium is kept intact.
6. After reverse J-sternotomy, a minimally invasive sternal retractor is placed, the substernal fats are dissected, and the pericardium is opened.
7. The surgical exposure is enhanced using pericardial stay sutures which pull the heart up gently.
8. The surgical approach to the heart is similar to the conventional technique.
9. Central cannulation can be done using traditional cannulas. However, remember that a short segment of the proximal ascending aorta would be available in surgical field for cannulation, clamping and cardioplegia needle placement. Thus, peripheral cannulation can be another alternative.
10. Placement of the cardioplegia needle is done at the level of the sinotubular junction or just above this level.
11. After CPB, right or left atriotomy is feasible.
12. Following hemostasis, a chest tube is placed, pacing wires are put, pericardium is approximated, and the sternum is closed.
13. Closure of the sternotomy is done with sternal wires or plates.

Pearls and pitfalls

1. The intercostal space just below the angle of Louis is the 2nd space and the upper end of partial sternotomy begins below this level.
2. Use a sternal oscillating saw that is used for redo cases.
3. Use the 2nd or 3rd intercostal space on the right for reverse J-incision. Leave a segment of sternal bone below the angle of Louis to keep the stability of manubriosternal junction.
4. Always check the ITA and vein that can be injured during sternal retraction.
5. A classical sternal retractor with a single blade is helpful (no need for extra instruments).
6. In case of limited exposure of the ascending aorta, the use of femoral artery cannulas under TEE guidance is helpful.
7. Straight silicon venous cannulas can be used for SVC, rather than the angled metal tip venous cannulas. Cannulation of the right internal jugular vein should be kept in mind before surgery.
8. Angled aortic clamps can be helpful for your set-up.
9. Placement of the cannula into the SVC can be difficult; therefore, first make cannulation of the inferior vena cava (IVC), go on CPB, and then cannulate the SVC. At the end, first take the cannula of the SVC immediately before ending CPB, and then wean from the bypass.
10. Pulling the heart with right-sided pericardial stay sutures and with snares may help exposure of the mitral valve via left atriotomy.
11. CO_2 insufflation help de-airing process at the end of the procedure.
12. Remember that the left heart would not be in the surgical field and, thus, TEE support is needed during weaning from CPB.
13. Place the pacing wires before declamping.
14. Check the right pleura for pneumothorax before the closure of the sternum.

Limitations and handicaps

This incision is safe and feasible approach for mitral/tricuspid valve operations and cardiac tumor excision. Revascularization of the right coronary system and distal circumflex artery can be done with this incision. Although this incision seems to be superior to full sternotomy, aortic surgery and valve replacement can be a relative contraindication due to difficult exposure and limited surgical access. Regarding surgical set-up and cannulation, there are some technical handicaps. First, you have a limited segment of aorta for manipulations.

Clamping and cannulation of the ascending aorta can be challenging, if the ascending aorta is located caudally under the intact sternal bone. Placement of cardioplegia cannula or cannulation of the SVC may be also challenging. The surgeons should be away from the sinuses of Valsalva during all cannulation procedures.

Take-home messages

An inferior partial sternotomy incision is a feasible, but less commonly used technique. It offers preservation of the sternal stability with a good postoperative rehabilitation and fast mobilization. This approach is easy to perform in mitral/tricuspid surgery or tumor excisions. In particularly, elderly patients with obstructive lungs may benefit from this incision, compared to full sternotomy.

RIGHT ANTERIOR MINI-THORACOTOMY

Currently, a new minimal access incision, namely RAT incision, via the right 2nd or 3rd intercostal space, has been described for aortic valve replacement (Figure 5). The favorable outcomes of the procedures have been reported in the literature.[25-29] This technique can be feasible, if the aortic valve is located posterior to the sternum or toward the right hemithorax. In such cases, RAT results in excellent exposure. However, preoperative planning of surgical strategy is essential to avoid technical difficulties of limited surgical exposure. Echocardiography and CT imaging help the surgeon for decision making preoperatively.[26] The use of this incision can be potentially beneficial for the protection of the sternal stability in young patients, elderly patients, and those with multiple comorbidities such as diabetes, renal failure, obstructive lung disease, and increased body mass index. This MICS incision allows early mobilization in elderly patients.

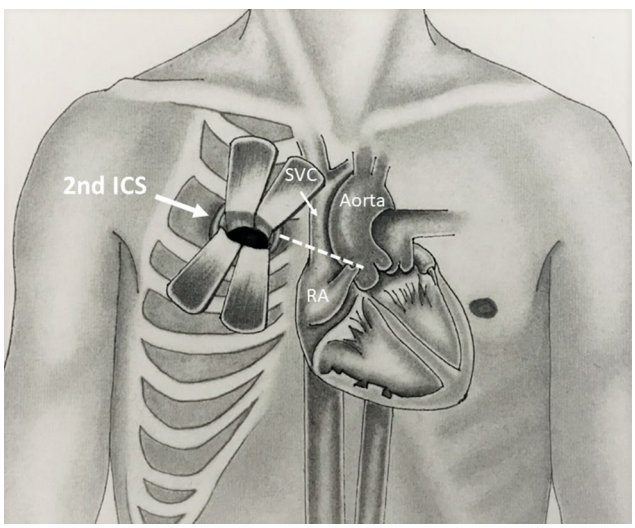

Figure 5. Right anterior mini-thoracotomy incision.
SVC: Superior vena cava; ICS: Invasive cardiac surgery; RA: Right anterior.

Principal steps

1. Single- or double-lumen endotracheal intubation with right lung isolation is performed.
2. The patient is draped according to the institutional protocol (whole sternum accessible) with a transparent film covering the skin.
3. First, cannulate the femoral vessels for CPB. If the access is not suitable, central cannulation can be used or vice versa.
4. Do not forget marking the patient before draping.
5. The mini-thoracotomy is performed via the 2nd or 3rd intercostal space with a 6 to 7-cm long skin incision (Figure 3).
6. Identify the right ITA and vein and divide them with hemoclips.
7. A soft tissue retractor is placed, and the use of thoracotomy retractor is usually unnecessary with the use of long-shafted surgical instruments.
8. The pericardium is opened parallel and superior to the right phrenic nerve and retraction sutures are placed. If the retraction sutures are pulled toward the surgeon and fixated, the aorta and the aortic valve become closer to the surgical incision.
9. Central or peripheral cannulation can be instituted. The femoral artery, ascending aorta, or axillary artery can be used for arterial access. The right atrium, SVC or femoral vein are alternative sites for venous access.
10. Left atrium is vented through the right upper pulmonary vein and CO_2 insufflation is utilized.
11. Aortic clamping can be done using the transthoracic Chitwood® clamp or malleable aortic clamps.
12. Before clamping, soft tissues behind the aorta is dissected.
13. Myocardial protection is done using traditional blood cardioplegia, del Nido solution or Custodiol® cardioplegia.

14. After aortotomy incision, the aortic leaflets are resected.
15. Long-shafted instruments are used via a small working port.
16. An endoscope and headlight are used in the surgical field.
17. With this technique, various types of prosthesis can be implanted including mechanical, biological, and sutureless valves.
18. Pacing wires are put before declamping.
19. Aortotomy is closed traditionally and the patients wean off from CPB.
20. Place pericardial and chest drains.

Pearls and pitfalls

1. In this technique, after thoracotomy incision, you do not need to enter the right hemithorax. Instead directly go into the pericardial space and work inside the pericardial cavity. Therefore, the RAT technique can be used in obstructive lungs, pulmonary hypertension, right pleural pathology, and previous right thoracotomy.
2. Do not use this technique in patients with leftward displacement of the aorta. The aorta would be far away from your surgical field and exposure would be difficult.
3. Be careful with the ascending aorta which is located adjacent to the sternum. In such a case, exposure would be limited. The aorta should be in the midline, not adjacent to it.
4. Use double-lumen intubation. If so, right lung deflation and positive end-expiratory pressure to the left lung may enhance the surgical exposure.
5. Do not forget defibrillation pads and intraoperative echocardiography.
6. Use the femoral vessels for the first access site for CPB. Vacuum-assisted drainage can be used rarely.
7. In some cases, disarticulation of costochondral junction of the adjacent ribs may enhance the surgical exposure, if the intercostal space is narrow for manipulation.
8. Pericardial stay sutures are fixated by pulling the heart toward thoracotomy incision. The heart would come closer to you.
9. Cannulation of the SVC for specially designed, two-stage venous cannulas makes surgical exposure better during operation.
10. When you enter the chest and directly see the right upper pulmonary vein, you are in the right place to reach the aorta.
11. Crystalloid cardioplegia solutions with longer protection times can be reasonable instead of using intermittent delivery of blood cardioplegia. The valve and coronary orifices are away from the surgeon which makes optimal surgical exposure difficult to obtain.
12. If the surgeon implants a stented-valve, knot-tying becomes an important issue. The length of a finger may be limited and, therefore, knot-pushers or automatic knot fixation instruments are needed.
13. CO_2 insufflation is important for deairing.
14. Fixate the cartilage to the sternum with an absorbable suture in case of disarticulation.

Limitations and handicaps

The RAT incision for aortic valve replacement and aorta is a different from J-sternotomy approach regarding its limitations. In the community, there is still no consensus on the superiority of RAT to J-sternotomy incision. Limitations are mostly related to technical aspects and patient selection. Preoperative anatomical assessment of patients is required for the feasibility of RAT incision for aortic valve replacement. The curvature of the ascending aorta or the plane of the aortic annulus should be assessed. The aortic valve should be beneath the sternum or make a rightward displacement to the sternum. If the valve makes a leftward deviation, the exposure would be extremely limited. Other limitations include the inability to cannulate the patient and porcelain aorta. Patients who need valve sparing aortic root procedures should be also excluded. Many reports have shown the feasibility of RAT with sutureless aortic valves. Nevertheless, the exposure of the aortic annulus, particularly the right and left sinus of Valsalva area, can be difficult. In such cases, suture placement and knot tying can be a limitation during mechanical or biological valve replacement. The surgeon may need to use long-shafted instruments or knot-tying apparatus. Although these instruments are time-saving, they add to the cost of the procedure.

Take-home messages

This is a novel technique and still needs evolution. Surgeons should be able to manage peripheral cannulation and its complications. Many details of the procedure should be focused, and this requires a professional approach to MICS. This technique is

slightly more complex and needs advanced experience in cardiac surgery; therefore, it is not the first procedure during the learning curve.

RIGHT ANTEROLATERAL MINI-THORACOTOMY

A right anterolateral mini-thoracotomy incision has been a commonly used approach in MICS for mitral valve procedures. The procedures provide less bleeding, less infection, and improved cosmesis.[1,2,6,7] Mitral valve surgery can be performed under direct vision or endoscopically, namely port-access operations. In direct vision operations, minimally invasive rib retractors are used through 6 to 8-cm thoracotomy incisions and operations can be done using conventional instruments. However, in endoscopic true port-access surgery, the operations are performed through the working port using long-shafted minimally invasive instruments without using a rib retractor. Port access surgery is a non-rib-spreading procedure, and all surgical maneuvers are done through a working port of 4 to 6-cm long (Figure 6).

Principal steps

1. Double endotracheal tube intubation with lung isolation or traditional single-lumen endotracheal tube intubation can be used.
2. Isolation of the right lung can improve the surgical view or exposure and facilitate surgical maneuvers during hemostasis.
3. The patient lies in the supine position with a left lateral deviation and external defibrillation pads are applied (Figure 7).
4. Transesophageal echocardiography is performed in all patients for monitoring heart and valve function.
5. The right chest is elevated with a soft bag under the right scapula and the right arm is flexed beside the operation table.
6. The patient is draped with a transparent film covering the skin and the whole sternum should be accessible.
7. Peripheral cannulas are placed percutaneously under TEE guidance. A 17-F cannula is usually enough for drainage of the jugular vein. Also, vacuum-assisted drainage can be used.
8. The incision of 4 to 6-cm long is performed in the 4th intercostal space anterolaterally.
9. In direct vision MICS cases, surgical exposure through a thoracotomy incision is enhanced by rib retractors. A head lamp may be useful with this technique.
10. In video-assisted true port-access surgery, a soft tissue retractor is placed without rib retraction through a 4 to 6-cm long incision. Endoscopic view is used during procedure.

Figure 6. Right anterolateral mini-thoracotomy for port-access procedures without rib retraction.

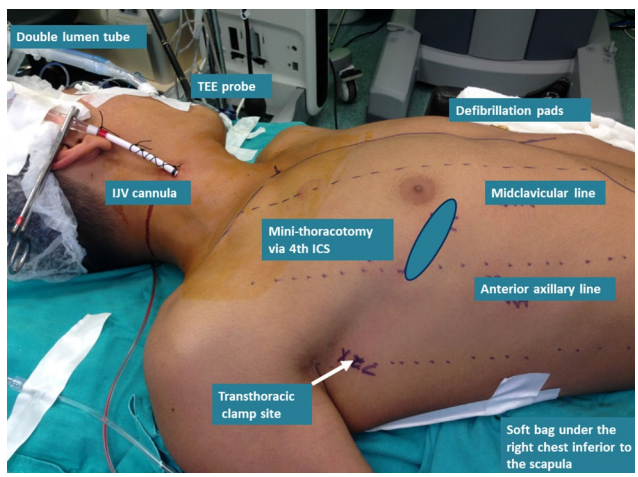

Figure 7. Surgical set-up for port-access and robotic surgery.
IJV: Internal jugular vein; TEE: Transesophageal echocardiography; ICS: Invasive cardiac surgery.

11. CO_2 insufflation is used at 2 to 3 L/min gas flow.
12. The atrial retractor post is placed through the 4th intercostal space and medially to the working port. Port placement is performed for endoscope, aortic clamp, and CO_2 insufflation.
13. The pericardiotomy can be done 1 cm above the right phrenic nerve.
14. Pericardial stay sutures are placed for retraction and exposure.
15. Gentle aortic clamping or endo-aortic balloon occlusion is followed by antegrade cardioplegia or retrograde cardioplegia, if used.
16. Cardioplegia is delivered with a puncture needle or long-shafted cardioplegia cannula placed on the ascending aorta.[8-10]
17. After cardiac arrest, left atriotomy is traditionally performed below the interatrial groove, namely Sondergaard's groove.
18. Atrial retractor is placed, and the mitral procedures are done.
19. Shafted instruments and use of an auto-knotting device facilitate the procedure.
20. Additional procedures may be performed such as atrial fibrillation ablation, left atrial appendage closure, and tricuspid valve repair.
21. After closure of left atriotomy, patients are weaned from CPB.
22. Pacing wires are placed before declamping of the aorta.
23. Pericardium is approximated, chest tubes are placed, and hemostasis is done.
24. The skin incision is closed in a usual way.

Pearls and pitfalls

1. Always use a check list and talk to your scrub and perfusionist before operations.
2. The use of single-lumen endotracheal tubes can be used and prevents iatrogenic complications associated with double-lumen intubation. Anesthesia and skin incision time is less with single-lumen tubes.
3. Transesophageal echocardiography is essential during peripheral cannulation and weaning from CPB.
4. Jugular vein cannulation should be done before draping. In patients with a body surface area above 2.1 m^2, 19F jugular cannulas may help venous drainage or vacuum-assistance is needed, if femoral vein drainage is insufficient.
5. Selection of a larger size venous cannula may potentially disturb drainage during CPB. Thus, proper femoral venous cannula should be selected for adequate drainage.
6. The tip of the SVC cannula should be positioned 2 to 3 cm caudally from the cava-atrial junction. This provides a better venous drainage and improved exposure of the mitral valve.
7. The tip of femoral venous cannula should be away from the tip of the SVC cannula and below the IVC-right atrium junction to prevent re-circulation.
8. In general, the amount of suction should not exceed 40 mmHg. If adequate decompression of the right atrium is not possible with addition of vacuum, the venous cannula is repositioned.
9. Keep the tips of both venous cannulas away from each other to avoid recirculation.
10. In the initial cases, mini-thoracotomy incision can be larger. In males, the nipple can be included in the incision line with a better healing and cosmesis. In females, the submammary line is the landmark for the incision.
11. Use a larger incision in the initial cases.
12. Be careful during atrial retractor insertion to avoid injury to the right ITA.
13. Iatrogenic injuries to the lung and diaphragm should be avoided during insertion of the instruments into the chest.
14. Retraction of the dome of the left diaphragm can be done with pledgeted or Teflon reinforced sutures to enhance exposure of the heart, if needed. Take small and superficial bites to prevent injury to the liver.
15. Avoid unnecessary retraction to the pericardium with stay sutures that may cause tension and injury to the right phrenic nerve.
16. Retraction of the right atrial appendage help exposure of the aorta during placement of cardioplegia cannula (Figure 8a).
17. Aortic clamp is easily placed through the transverse sinus with its inner curve facing cranially. Avoid injury to the left atrial appendage and pulmonary artery during clamping.

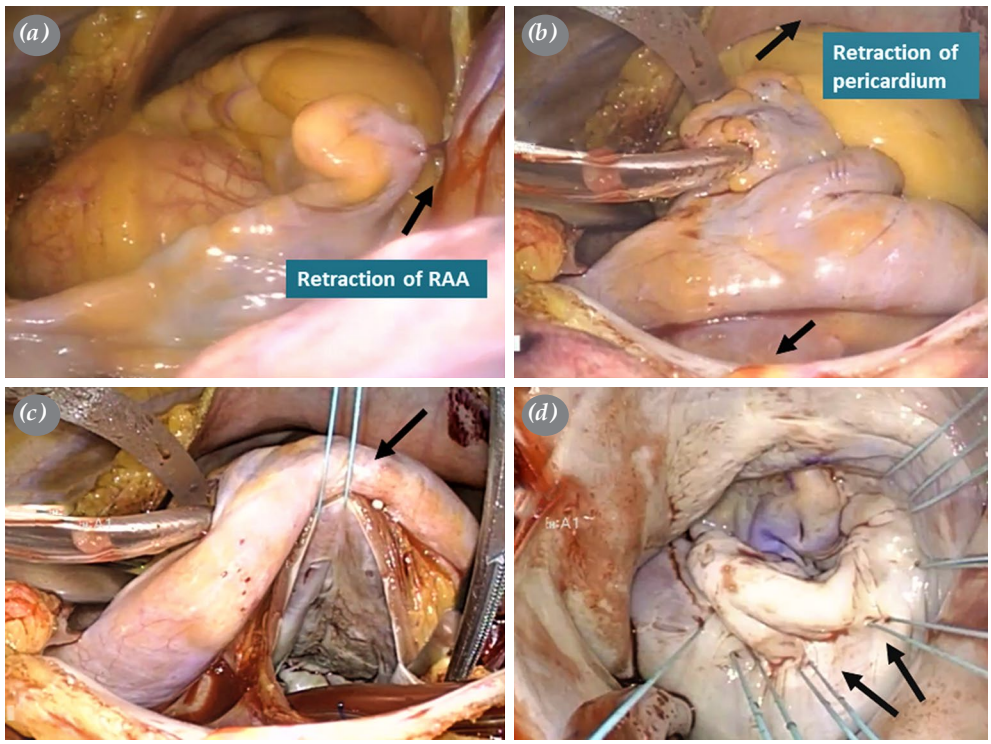

Figure 8. Basic tips and tricks for a better exposure during port-access mitral valve surgery. **(a)** Retraction suture to the right atrial appendage; **(b)** pericardial stay sutures; **(c)** Retraction of the left atrial incision; **(d)** Exposure for mitral valve repair.

RAA: Right atrial appendage.

18. A retraction suture to the anterior edge of the atriotomy may facilitate placement of the atrial retractor (Figure 8c).
19. Placement of several annular sutures to the P2-P3 segment enhances intracardiac exposure during repair procedure (Figure 8d).
20. Occlusion of both vena cavae can be done using traditional technique or using atraumatic vascular bulldog clamps, if the right atrium would be opened (Figure 9).
21. Place pacing wires before declamping.
22. Put a 28F curved or blake drain into the posterior pericardium and approximate the edges of the pericardium superiorly to avoid herniation and cardiac torsion postoperatively.

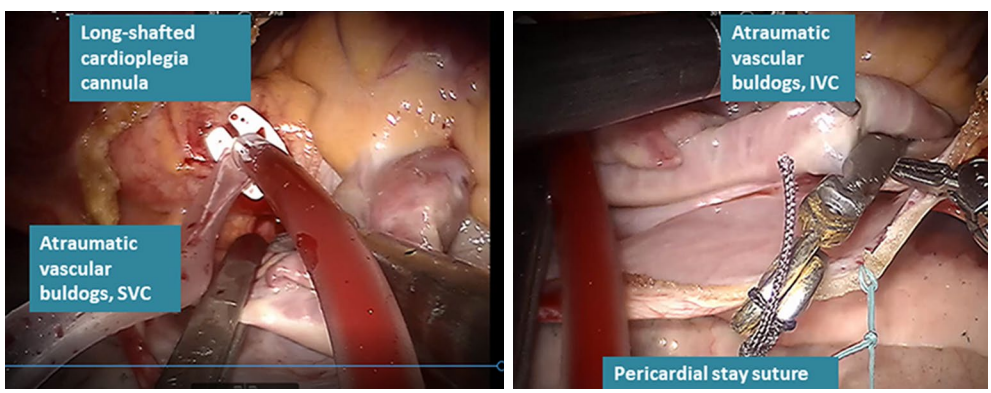

Figure 9. Atraumatic vascular bulldog clamps for vena cava occlusion.

SVC: Superior vena cava; IVC: Inferior vena cava.

23. Before the initial cases, make some exercise with long-shafted instruments and knot-pusher.
24. Do the initial cases with proctoring.

Limitations and handicaps

This incision is a reasonable incision for the mitral valve procedures, but has some technical limitations during procedures. First, the surgeon should be familiar with the use of minimally invasive long instruments. Preoperative exercise improves your manipulation and decreases operative times. Second, in the initial cases, proctoring is important to avoid iatrogenic injuries and to have a roadmap and pitfalls. Third, the use of a small incision for a surgeon who is unfamiliar with the technique is a handicap. I believe that the surgeons should use larger thoracotomy incision in the learning curve. On the other hand, patients with previous right thoracotomy, radiotherapy, pericarditis, previous cardiac surgery chest wall deformity such as scoliosis or peripheral artery disease can be considered to have relative contraindications for this approach. However, porcelain aorta and severe peripheral artery disease are actual contraindications according to our experience. Clinically, the outcomes of the operations have been reported previously; however, their superiority to the sternotomy incision is comparable.[1,2,6,7] However, there are surgeons who still prefer to use sternotomy incision in mitral valve repair or replacement. They avoid the risk of potential complications of retrograde perfusion via peripheral bypass and longer operative times.

Take-home messages

The young surgeons should be open to new techniques. I believe that this incision is the first approach to learn MICS. Surgeons should be capable of making efficient instrumentation with longer surgical instruments and to have experience in peripheral cannulation techniques. Simple cases and larger thoracotomy incision should be selected for the initial cases during the learning curve period, until uneventful procedures are achieved. Therefore, proctoring is beneficial in the initial cases.

LEFT ANTEROLATERAL MINI-THORACOTOMY

A left anterolateral mini-thoracotomy incision has been successfully used for coronary revascularization in MICS.[15,30,31] Since 2000s, the da Vinci® (Intuitive Surgical Inc., CA USA) robotic surgery system has been used for single or bilateral ITA harvesting in MIDCAB procedures.[30,31] Totally endoscopic coronary artery bypass (TECAB) is completely a different procedure, but it has gained limited popularity due to technical difficulties and its cost.[30] The MIDCAB procedures are performed through 6 to 8-cm mini-thoracotomy incisions using off-pump or on-pump technique (Figures 10 and 11). These procedures

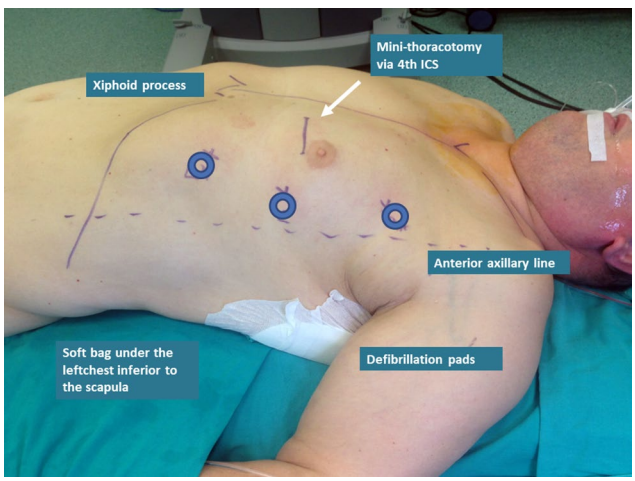

Figure 10. Position and skin landmarks for minimally invasive direct coronary bypass.
ICS: Invasive cardiac surgery.

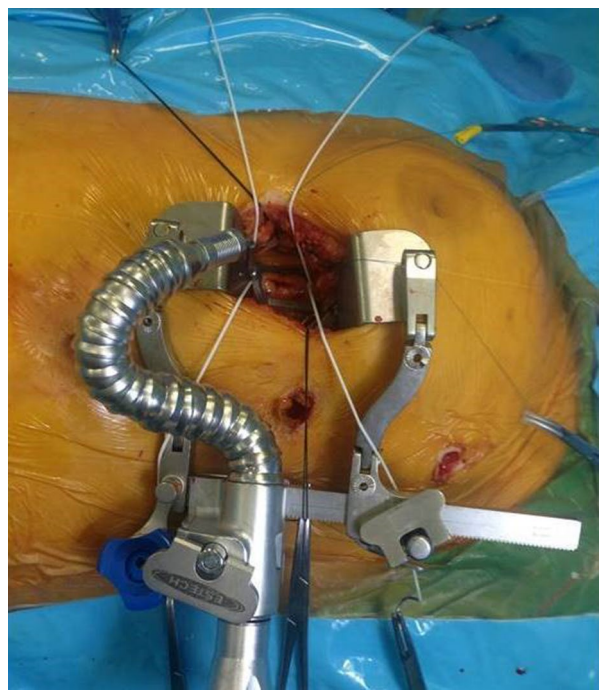

Figure 11. Left anterior mini-thoracotomy for minimally invasive direct coronary bypass grafting.

can be done using traditional instruments and the learning curve is relatively shorter, compared to the other incisions of MICS. During off-pump or on-pump MIDCAB procedures, the ITAs can be harvested using direct vision using a headlight, video-endoscopically or robotically-assisted techniques.

Principal steps of left ITA harvesting, direct vision

1. Single-lung ventilation is mostly used during the operation using a double-lumen tube or bronchial blockers.
2. The patients must be placed in supine position with an inflatable bag below the left hemithorax.
3. The patient's left arm is slightly suspended beside the operating table.
4. External defibrillating pads are placed on the chest wall.
5. A 4 to 6-cm intercostal incision is made on the left chest keeping two-thirds of its extension lateral to the midclavicular line.
6. Subcutaneous tissue is dissected with fibers of pectoralis major muscle.
7. The left ITA is harvested between the 4th or 5th intercostal space and its proximal segment. Some surgeons clip and divide the left ITA at the 4th intercostal space following thoracotomy incision.
8. A specialized rib spreading chest retractor is used for exposure of the left ITA.
9. Pedicled or semi-skeletonization technique is used. The left ITA exposure is accomplished using a reusable rib-retractor with a specially designed thoracotomy retractor (Medtronic ThoraTrak™ MICS Retractor System, Medtronic, MN, USA) and the lift systems (Rultract® Skyhook Surgical Retractor System, Pemco Inc., GA, USA).
10. A 20-cm long electrocautery handle and thoracoscopic clips are used to harvest the left ITA up to the first intercostal branch close to the subclavian vein.
11. Mediastinal branches are divided to provide optimum long-term graft patency.

Principal steps of left ITA harvesting, robotic surgery

1. Single or double-lumen endotracheal intubation is utilized.
2. A closed chest procedure that is done under CO_2 insufflation.
3. Three trocars are placed for robotic instrumentation. These are inserted through the 3rd, 5th, and 7th intercostal spaces. Then, the patient-side unit and surgeon console are prepared.
4. The ITA conduit is harvested with its full length and all side-branches can be easily exposed and ligated safely (Figure 12).
5. Endothoracic fascia is decorticated before mobilization of the left ITA.
6. The ITAs can be harvested in a semi or full-skeletonized fashion with hemoclips.
7. After ITA harvesting, pericardiotomy is done.

Pearls and pitfalls

1. Give some Fowler's position to make the intercostal space larger.
2. The right arm can be extended for radial artery harvesting.
3. Single-lumen endotracheal tubes can be used during robotic ITA harvesting (not used in direct vision technique).
4. Adequate hydration is important to keep the hemodynamics stable during robotic ITA harvesting under CO_2 insufflation into the right hemithorax. It is also vital during off-pump technique.
5. Do not forget defibrillation pads.
6. Only the left ITA is harvested in direct vision technique. If you desire to harvest bilateral ITAs, robotic surgery is superior.

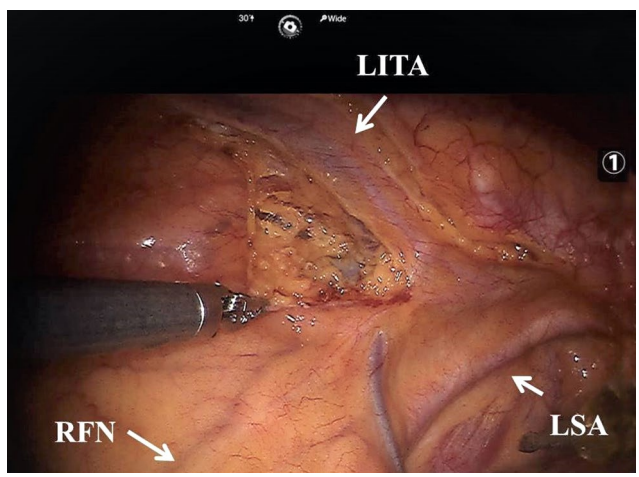

Figure 12. Robotic endoscopic harvesting of the LITA.
LITA: left internal thoracic artery; RFN: Right phrenic nerve; LSA: Left subclavian artery.

7. Its harvesting should be done between the distal bifurcation and the subclavian artery. Therefore, robotic ITA harvesting is superior to direct vision technique in terms of full-length ITA harvesting and clipping of the mediastinal side-branches, as well as the first intercostal branch of the left ITA.
8. Robotic technique provides a gentle and delicate manipulation of the left ITA during harvesting.

Comments

Single or multivessel MIDCAB procedures can be done through a mini-thoracotomy incision. If these procedures are done off-pump, both a coronary stabilizer and a heart positioner are mandatory for the operations. These devices are specially designed, fixated to the surgical bed, and consist of a 30-cm shaft whose tip is connected to a suction cup. In robotic surgery, semi-skeletonization or full skeletonization of ITA is much feasible and simple compared to direct-vision technique. Also, harvesting of the right ITA is a superiority of robotic surgery. The use of bilateral ITAs with various alternatives such as T- or Y-graft techniques is possible and complete arterial revascularization can be done using robotic approach. All these approaches are alternative to conventional and percutaneous techniques with better long-term graft patency rates.

TOTALLY ENDOSCOPIC ROBOTIC SURGERY

Robotic-assisted cardiac surgery has become increasingly used as a minimally invasive approach for mitral valve disease and atrial septal defects.[8-20] With innovations, robotic approach can be a reasonable and comparable alternative to percutaneous techniques.[32,33] Totally endoscopic robotic procedures remain an extraordinarily complex procedure, which require experience with several non-routine operative steps. As a MICS technique, the main advantages of robotic surgery are less pain, shorter hospital stay, faster recovery, and improved cosmesis.[8-20] The procedures are done in a totally endoscopic way through the working port of 1.5 to 2-cm and 8 to 10-mm ports for the instruments. Relative contraindications include moderate-to-severe aortic regurgitation and severe adhesions in the right hemithorax.

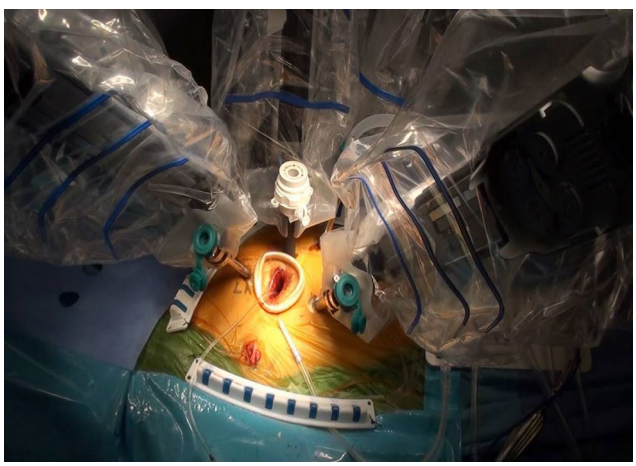

Figure 13. Robotic set-up for intracardiac procedures.

Currently, the da Vinci® SI robotic surgery system is used. Peripheral cannulation is used. The working service port (2-cm long) is opened on the anterior axillary line in the 4th intercostal space (Figure 13). The camera was inserted anteriorly in the same intercostal space. The robotic arms are placed in the 3rd and 5th intercostal spaces. The atrial retractor is inserted through the 5th intercostal space. During the operation, CO_2 (2 to 4 L/min) is insufflated into the operative field. After docking of robotic system, CPB is started and the lungs are deflated. Pericardium is opened anteriorly to the right phrenic nerve and stay sutures are placed. Endo-aortic balloon or transthoracic aortic clamp can be used for occlusion. A single puncture can be done on the ascending aorta or long-shafted cardioplegia needle can be used for antegrade delivery of cardioplegia solution. Aortic cross-clamp was inserted through the third intercostal space in the mid-axillary line. Diastolic arrest was established with isothermic blood cardioplegia. A right or left atriotomy incision is done for intracardiac procedures.

In conclusion, six established methods of performing MICS and totally endoscopic robotic approach have been described. These include upper mini-sternotomy, lower mini-sternotomy, right anterior mini-thoracotomy, right anterolateral mini-thoracotomy, left anterolateral mini-thoracotomy, and totally endoscopic robotic approaches. In the current era, these approaches should be in the armamentarium of all cardiac surgeons. The community as well as all experienced surgeons should encourage new generations and junior surgeons to establish MICS program in their centers. Therefore, these approaches are safe and feasible methods in cardiac surgery and provide a better recovery period with an uneventful postoperative course.

Acknowledgements

I would like to thank to Ebru Arli who is a cardiovascular surgery nurse in our hospital for drawings of surgical approaches.

Declaration of conflicting interests

The author declared no conflicts of interest with respect to the authorship and/or publication of this article.

Funding

The author received no financial support for the research and/or authorship of this article.

REFERENCES

1. Vanermen H, Farhat F, Wellens F, De Geest R, Degrieck I, Van Praet F, et al. Minimally invasive video-assisted mitral valve surgery: from Port-Access towards a totally endoscopic procedure. J Card Surg 2000;15:51-60.
2. Lehr EJ, Guy TS, Smith RL, Grossi EA, Shemin RJ, Rodriguez E, et al. Minimally Invasive Mitral Valve Surgery III: Training and Robotic-Assisted Approaches. Innovations (Phila) 2016;11:260-7.
3. Bush B, Nifong LW, Alwair H, Chitwood WR Jr. Robotic mitral valve surgery-current status and future directions. Ann Cardiothorac Surg 2013;2:814-7.
4. Benetti FJ, Mariani MA, Rizzardi JL, Benetti I. Minimally invasive aortic valve replacement. J Thorac Cardiovasc Surg 1997;113:806-7.
5. Cosgrove DM 3rd, Sabik JF, Navia JL. Minimally invasive valve operations. Ann Thorac Surg 1998;65:1535-8.
6. Casselman FP, Van Slycke S, Wellens F, De Geest R, Degrieck I, Van Praet F, et al. Mitral valve surgery can now routinely be performed endoscopically. Circulation 2003;108 Suppl 1:II48-54.
7. Kızıltan HT, İdem A, Salihi S, Demir AS, Korkmaz AA, Güden M. Mitral valve surgery using video-assisted right minithoracotomy and deep hypothermic perfusion in patients with previous cardiac operations. J Cardiothorac Surg 2015;10:55.
8. Senay S, Gullu AU, Alhan C. Robotic mitral valve replacement for rheumatic mitral disease. Ann Cardiothorac Surg 2017;6:64-6.
9. Onan B, Aydin U, Kadirogullari E, Onan IS, Sen O. Totally Endoscopic Robotic-Assisted Cardiac Surgery in Children. Artif Organs 2019;43:342-9.
10. Onan B, Aydin U, Kadirogullari E, Onan IS, Sen O, Kahraman ZĞ. Robotic repair of partial anomalous pulmonary venous connection: the initial experience and technical details. J Robot Surg 2020;14:101-7.
11. Aydin U, Sen O, Kadirogullari E, Kahraman Z, Onan B. Robotic Mitral Valve Surgey Combined with Left Atrial Reduction and Ablation Procedures. Braz J Cardiovasc Surg 2019;34:285-9.
12. Onan B, Kadirogullari E, Kahraman Z, Sen O. Robotic Septal Myectomy Without Anterior Leaflet Incision during Mitral Valve Repair. Innovations (Phila) 2019;14:281-5.
13. Onan B, Kahraman Z, Erturk M, Erkanli K. Robotic resection of giant left ventricular myxoma causing outflow tract obstruction. J Card Surg 2017;32:281-4.
14. İyigün T, Kaya M, Gülbeyaz SÖ, Fıstıkçı N, Uyanık G, Yılmaz B, et al. Patient body image, self-esteem, and cosmetic results of minimally invasive robotic cardiac surgery. Int J Surg 2017;39:88-94.
15. Sagbas E, Akpinar B, Sanisoglu I, Caynak B, Guden M, Ozbek U, et al. Robotics in cardiac surgery: the Istanbul experience. Int J Med Robot 2006;2:179-87.
16. Kadiroğulları E, Onan B, Aydın Ü, Başgöze S, Şen O. A comparison of robotically-assisted endoscopic versus sternotomy approach for myxoma excision: A single-center experience. Turk Gogus Kalp Dama 2020;28:450-9.
17. Sağbaş E, Sanisoğlu İ, Güden M, Çaynak B, Akpınar B. Üç olguda robot yardımı ile tam endoskopik koroner arter bypass cerrahisi. Turkish J Thorac Cardiovasc Surg 2008;16:254-6.
18. Güllü AÜ, Şenay Ş, Koçyiğit M, Alhan C. Robotic-assisted double valve intervention: the first national experience. Turk Gogus Kalp Dama 2013;21:743-5.
19. Onan B, Kadiroğulları E, Aydın Ü, Güner Y, Erkanlı K. Totally endoscopic robotic atrial septal defect closure in an adult with Down syndrome. Turk Gogus Kalp Dama 2017;25:450-4.
20. Güllü AÜ, Şenay Ş, Koçyiğit M, Ökten EM, Dumantepe M, Karabulut H, et al. The feasibility of robotic-assisted concomitant procedures during mitral valve operations. Turk Gogus Kalp Dama 2019;27:478-83.
21. Mikus E, Calvi S, Campo G, Pavasini R, Paris M, Raviola E, et al. Full sternotomy, hemisternotomy, and minithoracotomy for aortic valve surgery: Is there a difference? Ann Thorac Surg 2018;106:1782-8.
22. Kirmani BH, Jones SG, Malaisrie SC, Chung DA, Williams RJ. Limited versus full sternotomy for aortic valve replacement. Cochrane Database Syst Rev 2017;4:CD011793.
23. Bakir I, Casselman FP, Onan B, Van Praet F, Vermeulen Y, Degrieck I. Does a minimally invasive approach increase the incidence of patient-prosthesis mismatch in aortic valve replacement? J Heart Valve Dis 2014;23:161-7.
24. McClure RS, Cohn LH, Wiegerinck E, Couper GS, Aranki SF, Bolman RM 3rd, et al. Early and late outcomes in minimally invasive mitral valve repair: an eleven-year experience in 707 patients. J Thorac Cardiovasc Surg 2009;137:70-5.
25. Bouchot O, Petrosyan A, Morgant MC, Malapert G. Technical points for aortic valve replacement through right anterior minithoracotomy. Eur J Cardiothorac Surg 2018;53(suppl_2):ii24-ii6.
26. Balmforth D, Harky A, Lall K, Uppal R. Is ministernotomy superior to right anterior minithoracotomy in minimally invasive aortic valve replacement? Interact Cardiovasc Thorac Surg 2017;25:818-21.
27. Li Y, Lin H, Zhao Y, Li Z, Liu D, Wu X, et al. Del Nido Cardioplegia for Myocardial Protection in Adult Cardiac Surgery: A Systematic Review and Meta-Analysis. ASAIO J 2018;64:360-7.
28. Hummel BW, Buss RW, DiGiorgi PL, Laviano BN, Yaeger NA, Lucas ML, et al. Myocardial Protection and Financial Considerations of Custodiol Cardioplegia in Minimally Invasive and Open Valve Surgery. Innovations (Phila) 2016;11:420-4.
29. Göde S, Aksu T, Kadiroğulları E, Demirel A, Başgöze S, Erkanlı K et al. Early- and mid-term results of sutureless aortic valve replacement in high-risk patients: our single-center experience. Turk Gogus Kalp Dama 2016;24:446-53.

30. Kofler M, Schachner T, Reinstadler SJ, Stastny L, Dumfarth J, Wiedemann D, et al. Comparative analysis of perioperative and mid-term results of tecab and MIDCAB for revascularization of anterior wall. Innovations (Phila) 2017;12:207-13.
31. Ezelsoy M, Caynak B, Bayram M, Oral K, Bayramoglu Z, Sagbas E, et al. The comparison between minimally invasive coronary bypass grafting surgery and conventional bypass grafting surgery in proximal LAD lesion. heart surg forum 2015;18:E042-6.
32. Kadirogullari E, Onan B, Timur B, Birant A, Reyhancan A, Basgoze S, et al. Transcatheter closure vs totally endoscopic robotic surgery for atrial septal defect closure: A single-center experience. J Card Surg 2020;35:764-71.
33. Onan B. Coronary revascularization in robotic cardiac surgery. Cardiovasc Surg Int 2018;5:48-59.