Available online at www.medicinescience.org

CASE REPORT

Medicine Science International Medical Journal

Medicine Science 2022;11(1):399-402

Insidental COVID-19 cases

Bilgehan Demir, Mustafa Safa Pepele, Muhammed Ekmekyapar, Ramazan Avcu

Turgut Ozal University, Malatya Training and Research Hospital, Emergency Medicine Clinic, Malatya, Turkey

Received 23 June 2021; Accepted 20 August 2021
Available online 15.01.2022 with doi: 10.5455/medscience.2021.06.216

Copyright@Author(s) - Available online at www.medicinescience.org
Content of this journal is licensed under a Creative Commons Attribution-NonCommercial 4.0 International License.

Abstract

We wanted to present the upper respiratory tract infection originating from an RNA virus, which appeared in Wuhan, China, in December 2019 and was named the COVID-19 pandemic by the World Health Organization (WHO) (1), and the possibility of variable clinical pictures in people who caught it. These patients usually present to emergency departments with complaints of fever, sweating, respiratory distress, and fatigue. However, in our case series, we presented patients who did not have the previously mentioned symptoms but presented to emergency departments due to various reasons and were then diagnosed with COVID-19(CoV) (2). Since this disease, which is transmitted through inhalation, also exists without the manifestation of its clinical symptoms, we tried to raise awareness that all individuals could be infected in countries to which the pandemic spread and they should take precautions accordingly.

Keywords: Electric shock, Nidovirales, appendicitis

Introduction

CoV has brought new arrangements to the standards of living with a pandemic worldwide since December 19, 2019. The whole world has made and continues to make intensive efforts for the eradication of the disease. Therefore, studies have been conducted both for vaccination and to diagnose the disease early and as soon as possible with new kits and tests. The CoV, a cause of the disease, belongs to the Nidovirales group and has the largest Ribo Nücleic Acid (RNA) genome [1]. As a result of its frequent mutation, the virus has also brought about difficulties in scientific studies. The frequent mutation of the virus has led to changes in symptoms observed since the beginning of the disease (such as fever, sweating, cough, shortness of breath, headache, conjunctivitis, and gastrointestinal problems) [2] and the patient's clinical picture. Although the changing clinical picture has been observed more often recently, CoV cases have presented to emergency departments with completely different clinical pictures since the beginning. The presence of these different clinical pictures proves how careful we should be in fighting the disease. In our article,we wanted to present patients with clinical pictures which varied independently of the afore-mentioned virus-related symptoms, were completelyfar from the findings of a viral disease, but we diagnosed with CoV.

Cases

Case-1: A CoV case admitted to the emergency department due to trauma as a result of electric shock

A 22-year-old male patient was brought to the emergency department due to electric shock in the high-voltage line and a fall. In the physical examination, abraded areas were observed on the molar surfaces of the hands and feet, and there were pain and tenderness in the left ankle and both knees. After the examinations, hemogram values were found to be normal, and the following biochemistry values were obtained: Aspartate Aminotransferase:

219 U/L, Alanine Aminotransferase: 168 U/L, Alkaline Phosphatase: 149 U/L, Lactase Dehydrogenase: 1030 IU/L, and Creatine Kinase: 735 U/L. In the thoracic Computed Tomography (CT) performed due to trauma, consolidated areas adjacent to the pleura in the right lung were observed, and contusion secondary to trauma was considered (Figure-1). However, it was not forgotten that the consolidated areas could indicate CoV pneumonia. For CoV retraction, a Polymerase Chain Reaction (PCR) sample was taken, and the patient whose PCR test result was positive was hospitalized in the CoV intensive care unit, followed up, and treated. The patient, who did not have any complaints and

***Corresponding Author:** Bilgehan Demir, Turgut Ozal University, Malatya Training and Research Hospital, Emergency Medicine Clinic, Malatya, Turkey
E-mail: bilgehandemir44@gmail.com

symptoms after follow-up and treatment, was discharged with isolation recommendations for CoV.

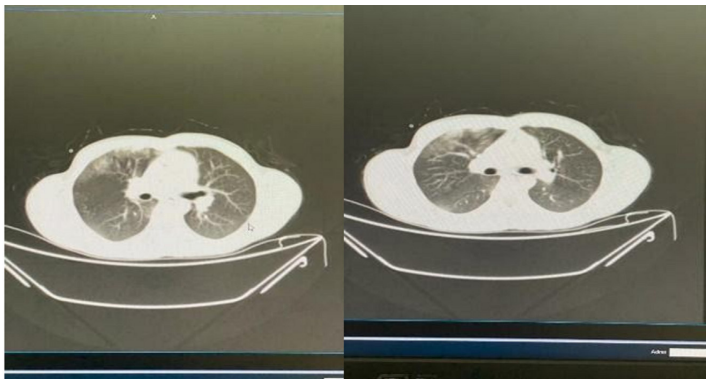

Figure 1. CoV pneumonia in the thoracic CT performed due to trauma as a result of electric shock.

Case-2: CoV with urinary tract infection

A 70-year-old male patient who had diabetes mellitus, benign prostatic hyperplasia, and Parkinson's disease was brought to the emergency department by his relatives with complaints of clouding of consciousness and dysuria. During the examination, the patient's fever was 38.3 °C, blood pressure was 100/75 mmHg, and pulse was 88/min. The patient's skin color was pale. He was also sweaty and had an intermittent dry cough. The patient had the following laboratory values: creatinine 1.74 mg/dl, urea 71.5 mg/ dl, CRP 9.81 mg/dl, leukocyte 21.1 10^3/uL, blood gas ph 7.36, bicarbonate 24.3 mmol/L, pCO2 44.5 mmHg, and leukocyte 30 HPF, erythrocyte 267 HPF in urine tests. In the patient with high fever, focal ground-glass areas were observed in the posterior segment of the upper lobe of the left lung and the middle lobe on the thoracic CT performed to detect the focus of infection (Figure-2). The patient was hospitalized in the service for suspected CoV. A PCR sample was taken for CoV retraction. Although CoV pneumonia was considered in the CT scan of the patient, the patient's PCR test result was negative. In the following days, the patient whose general condition worsened along with respiratory distress was taken to the intensive care unit. The patient, who was intubated and connected to a mechanical ventilator, died on the 4th day of his admission to the intensive care unit. Despite his negative PCR test result, the patient's clinical picture deteriorated rapidly, and his CT finding was evaluated in favor of pneumonia. Therefore, it was thought that the patient died of COVID-19 infection.

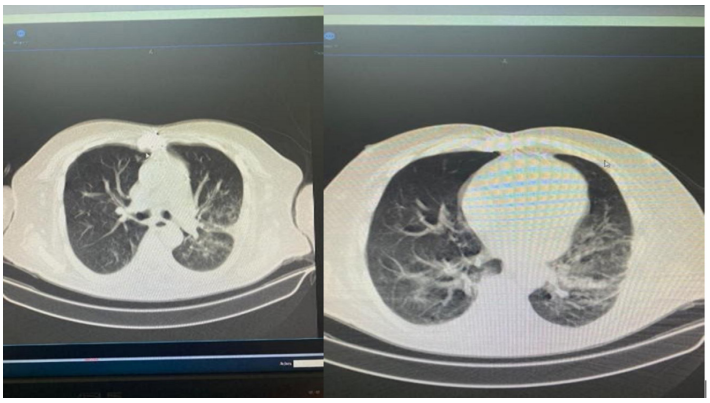

Figure 2. COVID-19 pneumonia in thoracic CT

Case-3: COVID-19 with acute appendicitis

A 27-year-old man presented to the emergency department with abdominal pain. Due to tenderness in the right lower quadrant in the physical examination, abdominal ultrasonography was requested for the patient, and his appendicitis was measured as 8 mm. The patient had no abnormal laboratory results other than leukocyte 13.3 10^3/uL and CRP (C-reactive protein) 4.5 mg/dl. The Department of General Surgery was consulted for the patient, and hospitalization was planned for his surgery. Pre-operative posteroanterior (PA) chest radiography was performed for surgical preparations, and no pathology was detected (Figure-3). A PCR sample was taken for COVID-19. The patient's PCR test result was positive. The patient was operated in compliance with isolation conditions and followed up in the COVID-19 intensive care unit after surgery. After the completion of his follow-up and treatment, the patient was discharged.

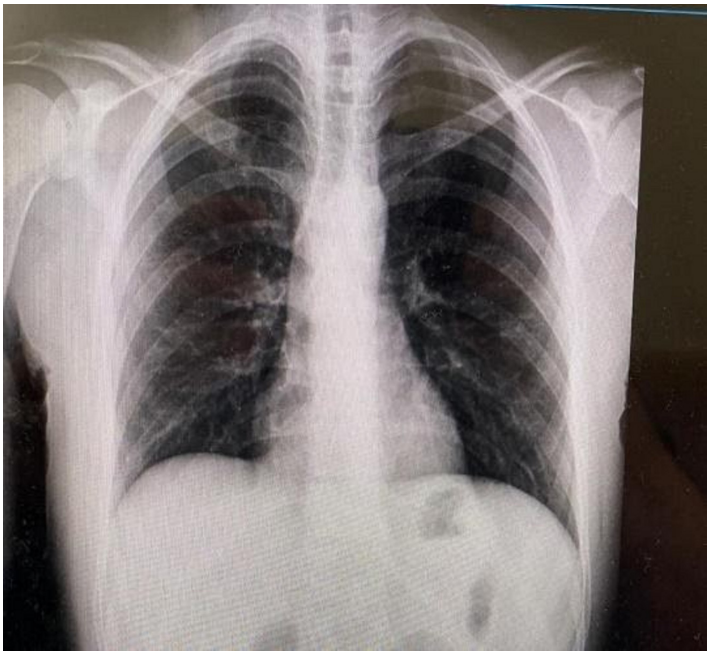

Figure 3. Pre-operative normal PA chest radiography

Case-4: CoV with a Chronic Obstructive Pulmonary Disease (COPD) attack

A 55-year-old male patient with known COPD disease was brought to the emergency department with respiratory distress by 112. In the patient's physical examination, he was confused, drowsy, cyanotic, and his expiration was long. His laboratory results were as follows: pH: 7.25, pCO_2: 113 mmHg, pO_2: 33.2 mmHg, oxygen saturation 64%, bicarbonate 48 mmol/L, CRP 3.2 mg/dl, leukocyte 10.810^3/uL, and neutrophil 8.1 10^3/uL. Infiltration areas were observed in the patient's thoracic CT. Upon the interpretation of viral pneumonia by the Department of Radiology, a PCR sample was taken from the patient. His PCR test result was negative. Since the patient, who was relieved after treatment, did not agree on hospitalization, his signature was taken for the refusal of hospitalization, and he was given CoV isolation recommendations. Afterward, he was discharged. In this patient, we wanted to show that CoV disease could also be observed in COPD attack patients, who had CT findings compliant with CoV pneumonia but negative PRC test results, in addition to their normal disease, which we frequently encounter in emergency departments.

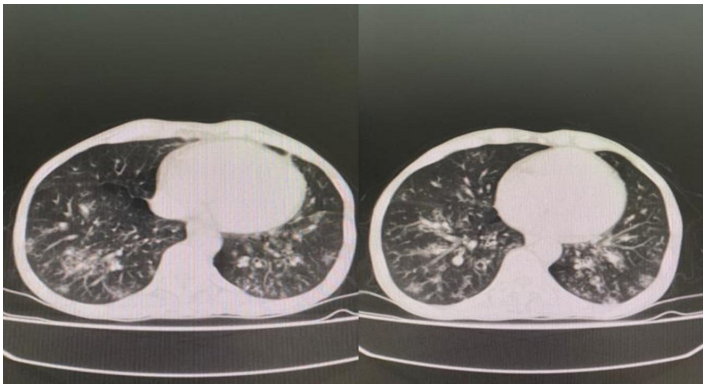

Figure 4. Suspicious viral pneumonia view on thoracic CT

Discussion

Since all patients followed up by Doctor Li Wenliang in Wuhan, China, in December 2019 had the same clinical findings (fever and respiratory distress), he thought that this was a disease different from the upper respiratory tract infection (URTI) and took the first step in diagnosing CoV [3]. This was then referred to as a coronavirus, under the name CoV, by the WHO on January 7, 2020, and defined as a pandemic due to the disease it caused worldwide [4]. CoV was derived from the word 'corona,' which means 'crown' in Latin [5]. It leads to a series of respiratory tract infections ranging from a mild cold to severe respiratory distress [6]. Since the first day of the pandemic, the clinical picture appeared with mild flu symptoms in patients and caused respiratory distress, including Acute Respiratory Distress Syndrome (ARDS) [4]. Most patients were followed up in the intensive care unit due to ARDS. Some patients died as a result of the severe continuation of this clinical picture. Therefore, PCR tests were carried out for diagnosis in people who exhibited symptoms in countries where the pandemic manifested itself, and people who contacted those who exhibited symptoms and had positive PCR test results were considered contacts. Diagnostic tools that have been available so far are based on viral gene detection, human antibody detection, and viral antigen detection. Of these, viral gene detection with the Reverse Transcription Polymerase Chain Reaction (RT-PCR) has been found to be the most reliable technique [5].

Although detections seem easy in symptomatic patients, the spread of the pandemic is fast as it is difficult to establish a diagnosis in asymptomatic patients. Since the cases we have presented are people with whom we can often be side by side in daily life, in other words, who are asymptomatic cases, we can become infected by contacting these patients. Therefore, the number of infected people is higher. CoV can be diagnosed when these patients usually present to the hospital randomly or with complaints different from those of URTI. In other words, if there had been no other emergencies, they would have continued to stay in the community and spread the infection to other people.

One of the most important reasons for not being able to bring the pandemic under control is the inability to isolate patients who are not predicted to be contagious (asymptomatic). Asymptomatic patients can easily be overlooked. In a study conducted in China on this subject, according to the information system for infectious diseases, 889 asymptomatic patients, corresponding to only 1.2% of all patients, were identified among 72,314 patients [7]. In our country, A. Gur et al. In a study they conducted, they identified 42 patients with covid despite being in different clinics [8]. Therefore, we should consider all individuals as infected people during the pandemic and implement personal isolations accordingly.

This article aims to show that people with a simple clinical picture and no signs of viral infection can also be infected with CoV because these individuals either do not know that they are sick or do not realize that their symptoms are related to any disease. Since they think they are not sick, they do not follow the personal isolation rules. This situation is the main reason for the rapid spread of the pandemic. Thus, we wanted to show how important it is to consider people around us as symptomatic or asymptomatic patients and to take precautions accordingly during the pandemic. A pandemic is a social problem, and it can only be controlled through the maximum compliance of all individuals with the isolation rules.

Main Points

•Most of the CoV patients detected incidentally are detected in emergency.

•Can be seen together in different diagnoses in CoV patients

•All healthcare professionals should take the necessary precautions by considering all patients as potential carriers of CoV.

Conclusion

We should consider every individual as an infected person and continue to comply fully with the personal isolation conditions until the definitive treatment of the disease is found or the vaccine reaches all people, and the disease is eradicated. Probably, we live together with more people than those we have exemplified. Keeping this in mind, changing our lifestyle is also our citizenship duty toward society.

Conflict of interests

The authors declare that they have no competing interests.

Financial Disclosure

All authors declare no financial support.

Informed Consent

Written consent was obtained from the patient and his parents.

References

1. Cui J , Li F , Shi ZL. Origin and evolution of pathogenic coronaviruses. Nat Rev Microbiol. 2019;17:181–92.

2. Giuseppe P, Alessandro S, Chiara P, et al. CoV diagnosis and management: a comprehensive review. J Intern Med. 2020;288:192-206.

3. Weiss SR , Navas-Martin S Coronavirus pathogenesis and the emerging pathogen severe acute respiratory syndrome coronavirus. Microbiol Mol Biol Rev. 2005;69:635–64.

4. Heymann DL , Shindo N, WHO scientific and technical advisory group for infectious hazards. COVID-19: what is next for public health? Lancet. 2020;395:542–5.

5. Meral Y ,Elif F, Korin GÖ. CoV diagnosis —A review of current methods Biosens Bioelectron. 2021;172:112752.

6. Zhonghua Liu Xing Bing Xue Za Zhi. (The Novel Coronavirus Pneumonia Emergency Response Epidemiology Team). The epidemiological characteristics of an outbreak of 2019 novel CoV in China. 2020;41:145-51.

7. Zhonghua Liu Xing Bing Xue Za Zhi, The epidemiological characteristics of an outbreak of 2019 novel coronavirus diseases (COVID-19) in China. 2020;41:145-51.

8. Gür A, Tekin E, Özlü İ. Analysis of incidentally diagnosed patients with coronavirus disease 2019 at the Emergency Department: single-center clinical experience. Eurasian J Med. 2021;53:114-7