Available online at www.medicinescience.org

ORIGINAL ARTICLE

Medicine Science 2022;11(1):274-9

Medicine Science International Medical Journal

Treatment of planovalgus foot in cerebral palsy with lateral column lengthening using titanium cubic cage

Ozan Ali Erdal[1], Baris Gorgun[1], Ilker Abdullah Sarikaya[1], Ali Seker[2], Mustafa Incesu[3], Muharrem Inan[1]

[1]Ortopediatri Istanbul, Academy of Pediatric Orthopaedics, Istanbul, Turkey
[2]Istanbul University Cerrahapasa, Faculty of Medicine, Department of Orthopaedics and Traumatology, Istanbul, Turkey
[3]Izmir Tepecik Education and Research Hospital, Department of Orthopaedics and Traumatology, Izmir, Turkey

Received 23 November 2021; Accepted 23 December 2021
Available online 05.02.2022 with doi: 10.5455/medscience.2021.11.382

Copyright@Author(s) - Available online at www.medicinescience.org
Content of this journal is licensed under a Creative Commons Attribution-NonCommercial 4.0 International License.

Abstract

High complication rates were reported with the graft usage when performing lateral column lengthening in cerebral palsy patients. In order to overcome such technical difficulties, we designed a titanium cubic cage and the purpose of this study was to describe this new fixation method and report results after calcaneal lengthening osteotomy using this new implant. Used in 86 feet of 55 patients. Average patient age was 11.6 years, and mean follow-up was 42.6 months. Clinical examination was performed preoperatively and in follow-up. In the anteroposterior radiographs, the talonavicular coverage and the talus-first metatarsal angles and in the lateral radiographs, the talocalcaneal and the talus-first metatarsal angles were measured. Forefoot abduction improvement and medial longitudinal arch was successfully reestablishment were detected in almost all of the patients. All patients showed significant improvement in mean talonavicular coverage, anterior talus-first metatarsal, lateral talocalcaneal, and lateral talus-first metatarsal angles. Our results show that TCC provides significant correction and stable fixation and reduced complication rates compared in CP.

Keywords: Flatfoot, cerebral palsy, planovalgus foot, calcaneal lengthening, calcaneal osteotomy

Introduction

Planovalgus foot deformity is a major source of disability in children with cerebral palsy (CP), with an incidence as high as 25% [1]. It is caused by many factors, including overactivity and subsequent shortening of the gastrocnemius-soleus complex and peroneal muscles [2, 3]. Subsequently, the heel deforms to valgus position, and the forefoot is abducted and pronated [4]. Planovalgus foot is clinically associated with pain, depression of the medial longitudinal arch, walking disabilities, callosities, and ulcerations [5, 6]. If clinical symptoms are present, correction of the deformity and reconstruction of the medial longitudinal arch will become necessary.

Treatment options in planovalgus deformity are orthotic applications, peroneal muscle lengthening, calcaneal lengthening, subtalar fusion, and triple arthrodesis [7, 8]. Evans [2] introduced calcaneal lengthening procedure to correct planovalgus deformity in ambulatory children with CP. He achieved correction by giving forefoot adduction, internal rotation and supination [9]. Although high success rates have been reported since then, complications have occurred too, such as early graft displacement, loss of correction, donor site morbidity, nonunion, and delayed union [4]. To avoid loss of correction or recurrence, plate or K-wire fixation methods have been proposed. However, K-wires offer insufficient stability, and plate fixation is related to hardware problems due to poor soft tissue coverage and irregular shape of the calcaneus [4, 10]. To keep the osteotomy site distracted or calcaneus lengthened, autologous bone grafting has been commonly used. The iliac crest is the most common donor site. However, donor site complications are not rare, which are infection, hematoma formation, iliac wing fracture, neural or vascular injuries, chronic donor site pain, hernias, and scarring [11, 12].

A recently designed titanium cubic cage (TCC) is a novel alternative to graft in the calcaneal lengthening procedure to prevent graft-related problems, correction loss, and recurrence. Our primary

***Corresponding Author:** Ozan Ali Erdal, Ortopediatri Istanbul, Academy of Pediatric Orthopaedics, Dikilitas Mah. Hakkı Yeten Cad. No10/D Besiktas,Istanbul, Turkey E-mail: ozanaerdal@icloud.com

aim is to describe this new fixation method and report results after calcaneal lengthening osteotomy using this new implant.

Materials and Methods

Institutional Review Board and Ethical Committee approval (decision No: 139) was obtained before initiation of this retrospective study. 55 children (86 feet) with a diagnosis of spastic CP who had undergone lateral column lengthening for pes planovalgus with a TCC were included to the study. Thirty-one children had bilateral and 24 children had unilateral procedures. Thirty-three of the patients were male, 22 were female, and the average age at the time of surgery was 11.6 (range, 7–22) years. The mean follow-up period was 42.6±13.5 (range, 22–92) months.

The patients included in this study had a diagnosis of either mild, or moderate planovalgus foot deformity accompanying CP. Major complaints were pain and callus on the foot resistant to conservative management. All patients were reported as having a foot flexible enough to be manually corrected to near-alignment in a non-weight-bearing position (Figure 1). Patients with specific conditions, e.g accessory navicular bone, arthritis and patients who need additional surgical procedures for midfoot or hindfoot (medial column shortening, subtalar arthrodesis etc.) which can affect the foot alignment, were excluded.

Figure 1. A-C. Preoperative images of a 13-year-old cerebral palsy patient with pes planovalgus deformity: Anterior (A), posterior (B) and lateral (C) view

The cages were provided by the manufacturer (Tasarimmed, Istanbul, Turkey) and were commercially available. TCC's have widths of 7-13 mm and length of all implants was 14 mm (Figure. 2). The centrally placed screw allows for further adjustment after, if needed.

Figure 2. Images of a titanium cubic cage. There is a central screw which expands the cage when tightened

The patients were placed in supine position under general anesthesia. Evans's intra-calcaneal osteotomy technique was performed, as described by Mosca [2, 13]. Between the anterior and middle facets of the calcaneus at 10–20 mm proximal to the calcaneocuboid joint a transverse osteotomy was created with the help of an oscillating saw, while leaving the medial cortex intact. The medial corner of the calcaneus was osteotomized with an osteotome. The osteotomy area was distracted with a lamina spreader, until the medial longitudinal arch of the foot was reestablished clinically (Figure 3). Under fluoroscopy, alignments of the calcaneocuboid and talonavicular joints were evaluated (Figure. 4). More than 75% talar head coverage as well as normal transverse tarsal joint alignment were aimed to confirm the desired correction. Then, an appropriately sized TCC was inserted into the distracted osteotomy site just in between the lateral cortices of the calcaneus (Figure. 5). TCC allows for further adjustment after insertion, if needed, via tightening a centrally placed screw.

Figure 3. Views of a patient with pes planovalgus deformity during the operation. Distraction of the calcaneal osteotomy and simultaneous formation of the medial longitudinal arch is seen on the left. On the right, medial view of the foot is seen after the procedure. The patient also underwent percutaneous Achilles lengthening

Figure 4. Fluoroscopic view of the foot during the operation. The osteotomy site is distracted with the lamina spreader. Improvement in talonavicular coverage is confirmed

After the correction, the tension in the gastro-soleus muscle complex was assessed. Achilles tendon lengthening was indicated if ankle dorsiflexion was minus 10 degrees or less with the knee flexed up to 90 degrees. A percutaneous triple stab incision for slide lengthening was performed to obtain 20 degrees of dorsiflexion at the ankle. After the surgical procedure, a short leg plaster cast was applied with the foot in neutral position. Weight-bearing as tolerated was allowed postoperatively. After six weeks, the cast was removed, passive range-of-motion exercises were started and use of an ankle-foot orthosis was initiated for another six weeks.

Figure 5. Image of an titanium cubic cage inserted into the osteotomy site

Patient files were searched in detail for any concomitant surgeries. Anteroposterior and lateral radiographies before and after the surgery were evaluated by the same physician (Figure 6–8). In the anteroposterior radiographies, the talonavicular coverage and the talus-first metatarsal angles were measured. Talonavicular coverage was used to determine the alignment of the midfoot, and the anteroposterior talus-first metatarsal angle was used as a determinant of forefoot abduction. In the lateral weight-bearing views, the talocalcaneal and the talus-first metatarsal angles were measured. Both were used to define midfoot planus [3, 4, 9, 11]. Bone union status was assessed via follow-up radiographies.

The patients were called for the final control to determine whether forefoot abduction, depressed medial longitudinal arch, or hindfoot valgus had recurred. The results were compared with preoperative examination photos and assessed as either "improvement" or "unchanged." This functional assessment was performed using the Gross Motor Function Classification System preoperatively and at last follow-up.

Figure 6. Anteroposterior and lateral X-ray views of a planovalgus foot before correction

Figure 7. Anteroposterior and lateral X-ray views of the foot early after calcaneal lengthening osteotomy using titanium cubic cage

Figure 8. Anteroposterior and lateral X-ray views of the foot two years after calcaneal lengthening osteotomy using titanium cubic cage

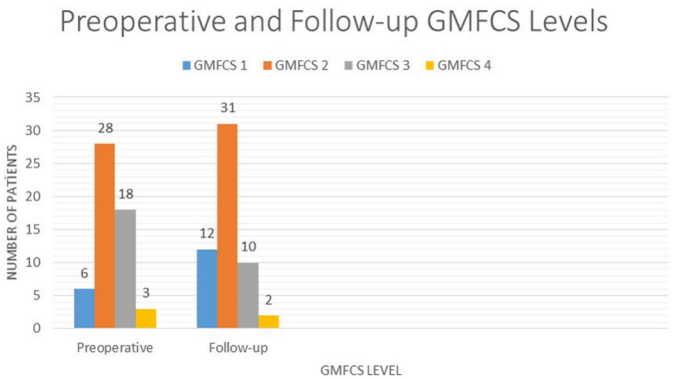

Figure 9. Preoperative and follow-up Gross Motor Function Classification System (GMFCS) levels

Intraoperative, postoperative, and follow-up complications such as infection, failure, delayed union, nonunion, were recorded in addition to reoperation rates and reasons. Delayed union was defined as a failure to reach bony union by six months postoperatively. Nonunion was defined when nine months had elapsed with no healing progress for three months.

Statistical analysis was performed with statistical package for the social sciences (SPSS) version 15 (SPSS Inc., Chicago, IL). Data for continuous variables were reported as mean ± standard deviation (minimum-maximum) and data for categorical variables reported frequency. The Wilcoxon rank test for binary comparisons was used to compare the continuous variables at different times. The results were evaluated at a 95% confidence interval and a significance level of $p < 0.05$.

Results

All patients had concomitant surgery, and Table 1 shows these concomitant surgical procedures. The radiographic measurements of the talonavicular coverage angle, talus-first metatarsal angle, lateral talocalcaneal angle and lateral talus-first metatarsal angle showed significant improvement (p=0.0001) after the operation (Table 2).

Table 1. The concomitant surgical procedures

Concomitant surgery	Number of cases
Adductor tenotomy	1
Hallux valgus surgery	16
Achilloplasty	61
Iliopsoas tenotomy	10
Tibia derotation osteotomy	3
Supracondylar femur extension osteotomy	20
Tibialis anterior transfer	5
Hamstring tenotomy	17
Femur varization derotation osteotomy	5
Pronator tenotomy	5
Flexor carpi ulnaris transfer	5
Rectus transfer	2
Plantar fasciotomy	1
Patellar tendon advancement	4
Tibialis posterior transfer	1

Table 2. The preoperative and follow-up radiographic measurements

	Preoperative	Follow-up
Talo-navicular Coverage	22.3º (±9.2º)	8.2º (±5.3º)
Talus-First Metatarsal Angle (AP)	17.2º (±8.5º)	7.3º (±3.6º)
Talo-calcaneal Angle (Lateral)	36.4º (±7.1º)	27.9º (±7.2º)
Talus-First Metatarsal Angle (AP)	14.3º (±6.2º)	7.1º (±3º)

Forefoot abduction improved in 74 cases. Medial longitudinal arch was successfully established while bearing weight in 72 cases. Hindfoot valgus had recurred in 11 cases. Figure 9 shows the preoperative and follow-up GMFCS levels: GMFCS levels improved in 18 patients.

Complete bone union was detected in all cases, and there was no delayed union, nonunion, infection or implant failure. Wound dehiscence was observed after cast removal in two patients. All patients were treated successfully with simple wound care. There were three calcaneocuboid joint subluxations; however, the patients did not receive any operation due to lack of symptoms. Also, five patients (four patients unilateral and one patient bilateral) experienced midfoot collapse at the first-year follow-up visit. The patients undergone revision calcaneal lengthening with the same procedure.

Discussion

The decision making out of treatment strategies for planovalgus foot deformity in CP patients is challenging due to indefinite course of CP and a lack of published data that clearly define the treatment algorithm [4, 13, 14]. Evans [2] presented the results of 56 feet that underwent lateral column lengthening. The author found that this procedure was inappropriate for the CP population; importantly, no detailed analysis of the results was available. However, in other studies calcaneal lengthening was found to be an effective method for treating planovalgus foot deformity in CP patients [15, 16, 17]. In another study, the failure rate was as high as 30–40% due to non- or delayed union and early reduction loss4 Furthermore, iliac bone harvesting was shown to possibly result in significant complications and morbidity [18, 19]. The newly developed TCC implant was anticipated to avoid early correction loss, recurrence, and graft-related problems. This study demonstrated that in planovalgus foot deformity of CP patients, calcaneal lengthening with TCC provides adequate correction.

Some studies in the literature have presented radiographic results of calcaneal lengthening for planovalgus foot deformity, especially in CP patients [4, 13, 14]. In a study of 26 patients, Philbin et al [20] reported that talonavicular coverage improved by 58% with lateral column lengthening, which was a powerful sign of forefoot correction. The talonavicular coverage angle in our study improved by 63% with TCC. Klaue et al [21] operated 26 planovalgus feet and found that the talocalcaneal angle in the lateral radiograph, a sign of hindfoot valgus, improved by 15% through lateral column lengthening. In our study, the talocalcaneal angle in the lateral radiograph improved by 23% with TCC. In short, significant improvements in radiographic parameters were achieved using TCC.

In a study of Yoo et al [3], after operating 92 planovalgus feet of 56 CP patients, they stated that correction of forefoot abduction, heel valgus, and restoration of the medial longitudinal arch were remarkably predictive clinical parameters for the treatment of planovalgus foot deformity in CP patients. They found clear correlations between these parameters and the talocalcaneal angle and the talus-first metatarsal angles. In our study, we observed that the improvements in forefoot abduction, medial longitudinal arch formation, and hindfoot valgus were better with the TCC. Additionally, GMFCS levels improved in 18 patients.

Danko et al [5] reported a significant improvement in radiographic measurements after lateral column lengthening using allografts to treat planovalgus foot deformity in CP patients. However, 30% of

the 58 cases experienced graft collapse, and the author suggested using a plate to shield the graft from stress. Likewise, Conti et al [22] reported an almost 50% failure rate when using autografts for lateral column lengthening. One possible cause is inadequate bone quality. Because children with CP have deficient bone growth and propensity for osteoporosis [23]. We also believe that it is difficult to harvest appropriately sized autografts from the osteoporotic iliac bones of CP patients. Because of different available sizes of TCC and their ability to expand, surgeons can obtain an adequate osteotomy gap size in the calcaneus to correct the planovalgus deformity. During follow up, only six midfoot collapse and loss of correction occurred. The lateral column lengthening procedure was repeated with a TCC. Therefore, we postulate that early correction loss due to graft collapse can be avoided with the use of TCC.

The iliac crest is a common donor site for autologous bone grafting. Reported complications include varying degrees of chronic donor site pain, local tissue collapse, avulsion fracture of the anterior superior iliac spine, and deformation at the iliac area. Muscle or visceral organ herniation and gait abnormalities may also arise in cases of large graft harvests [18–24]. On the other hand, major concerns about allografts include the well-documented risk of transmitting infectious agents as well as malignant cells, mechanical insufficiency of the harvested tissue, adverse reactions to products used for allograft processing, and a collapse rate of up to 30% [5, 25, 26]. In addition to their higher costs, some patients refuse to accept cadaveric allografts. Using the cages described in the current study eliminates complications or concerns about either autogenous or allogenic bone grafting. Complete bone union was found in all our TCC cases. Thus, the study also showed that use of TCC presents no disadvantage to bone healing when compared with autografts.

De Orio [10] reported that instrumentation prominence following lateral column lengthening can be problematic when a metallic implant is used, both with and without a graft. We believe that the TCC also has eliminated the risk when the cage is inserted properly into the osteotomy site, between cortices. If the TCC is not fitted beyond the anterior articular surface or the lateral cortex of the calcaneus, instrumentation prominence does not occur in either the subtalar joint or the lateral surface of the calcaneus.

Mosca [13] reported that calcaneocuboid subluxation of the distal calcaneal fragment during distraction of the osteotomy site can lead to osteoarthritic changes later; thus, he recommended stabilization of the calcaneocuboid joint with pinning. However, Adams et al [27] showed that Steinmann pin stabilization of the calcaneocuboid joint reduced neither the incidence nor the extent of calcaneocuboid subluxation. He recommended using Kirschner wire pinning to gain stable fixation of the joint and correction. However, Kirschner wire fixation is inherently a temporary method and once removed, risk of recurrence of the deformity ensues. While Andreacchio et al [4] suggested semi-tubular plate fixation against failure and joint instability, he reported a 25% failure rate as well as implant prominence. We believe that excessive distraction of the osteotomy gap causes calcaneocuboid subluxation independent of the surgical method, which can be avoided with intraoperative fluoroscopic control.

Our study population was limited to CP patients, and we did not have experience with TCC in other patient populations. However, this functionally homogeneous patient group provides better understanding of the technique and results. We believe that future studies should be conducted on this subject. In addition, our clinical measurement criteria based on subjective evaluation of the foot before and after the surgery. This is a common problem in the clinical evaluation of lateral column surgery results.

In conclusion, early results after correction of planovalgus foot deformity in CP patients with calcaneal lengthening using TCC showed that this technique provided sufficient correction with less complication. This treatment is potentially reproducible and preferable in other patient groups with osteoporotic bone and in those for whom allograft is unsuitable.

Conclusion

Early results after correction of planovalgus foot deformity in CP patients with calcaneal lengthening using TCC showed that this technique provided sufficient correction with less complication. This treatment is potentially reproducible and preferable in other patient groups with osteoporotic bone and in those for whom allograft is unsuitable.

Conflict of interests
Authors declare that they have no conflict of interest. No benefits in any form have been received or will be received from a commercial party related directly or indirectly to the subject of this article.

Financial Disclosure
The authors or the institution did not receive any funding for this research.

Ethical approval
Institutional Review Board and Ethical Committee approval (decision No: 139) was obtained before initiation of this retrospective study.

References

1. Bennet GC, Rang M, Jones D. Varus and valgus deformities of the foot in cerebral palsy. Dev Med Child Neurol. 1982:499–503.
2. Evans D. Calcaneo-valgus deformity. J Bone Joint Surg Br. 1975:70–8.
3. Yoo WJ, Chung CY, Choi IH, et al. Calcaneal lengthening for the planovalgus foot deformity in children with cerebral palsy. J Pediatr Orthop. 2005:781–85.
4. Andreacchio A, Orellana CA, Miller F, et al. Lateral column lengthening as treatment for planovalgus foot deformity in ambulatory children with spastic cerebral palsy. J Pediatr Orthop. 2000:501–5.
5. Danko AM, Allen B Jr, Pugh L, et al. Early graft failure in lateral column lengthening. J Pediatr Orthop. 2004:716–20.
6. Templin D, Jones K, Weiner DS. The incorporation of allogeneic and autogenous bone graft in healing of lateral column lengthening of the calcaneus. J Foot Ankle Surg. 2008:283–7.
7. Abel MF, Juhl GA, Vaughan CL, et al. Gait assessment of fixed ankle-foot orthoses in children with spastic diplegia. Arch Phys Med Rehabil. 1998:126–33.
8. Nather A, Fulford GE, Stewart K. Treatment of valgus hindfoot in cerebral palsy by peroneus brevis lengthening. Dev Med Child Neurol 1984:335–40.
9. Sands AK, Tansey JP. Lateral column lengthening. Foot Ankle Clin. 2007:301–8.
10. De Orio JK. Axial screw fixation in lateral column lengthening of the calcaneus. Techniques in Foot & Ankle Surgery. 2004:226–30.
11. Dimitriou R, Mataliotakis GI, Angoules AG, et al. Complications following autologous bone graft harvesting from the iliac crest and using the RIA: A systematic review. Injury. 2011:3–15.
12. Ahlmann E, Patzakis M, Roidis N, et al. Comparison of anterior and posterior iliac crest bone graft in terms of harvest-site morbidity and

functional outcomes. J Bone Joint Surg Am. 2002:716–20.

13. Mosca VS. Calcaneal lengthening for valgus deformity of the hindfoot. Results in children who had severe, symptomatic flatfoot and skewfoot. J Bone Joint Surg Am. 77:500–12.

14. Davitt JS, MacWilliams BA, Armstrong PF. Plantar pressure and radiographic changes after distal calcaneal lengthening in children and adolescents. J Pediatr Orthop. 2001:70–5.

15. Chi TD, Toolan BC, Sangeorzan BJ, et al. The lateral column lengthening and medial column stabilization procedures. Clin Orthop Relat Res. 1999:81–90.

16. Hintermann B, Valderrabano V, Kundert HP. Lengthening of the lateral column and reconstruction of the medial soft tissue for treatment of acquired flatfoot deformity associated with insufficiency of the posterior tibial tendon. Foot Ankle Int. 1999:622–9.

17. Trnka HJ, Easley ME, Myerson MS. The role of calcaneal osteotomies for correction of adult flatfoot. Clin Orthop Relat Res. 1999:50–64.

18. Missiuna PC, Gandhi HS, Farrokhyar F, et al. Anatomically safe and minimally invasive transcrestal technique for procurement of autogenous cancellous bone graft from the mid-iliac crest. Can J Surg. 2011:327–32.

19. Niu YF, An XF, Wu DJ, et al. Anatomical reconstruction of donor site after large iliac crest graft harvest with equivalent iliac crest allograft. A prospective controlled study. Eur Rev Med Pharmacol Sci. 2013:1951–7.

20. Philbin TM, Pokabla C, Berlet GC. Lateral column lengthening using allograft interposition and cervical plate fixation. Foot Ankle Spec. 2008:288–96.

21. Klaue K, Kaliyaperumal K, Swanson SA, et al. Central calcaneal osteotomy for correction of flexible pes planovalgus deformity. Foot Ankle Int. 2013:1079–89.

22. Conti SF, Wong YS. Osteolysis of structural autograft after calcaneocuboid distraction arthrodesis for stage II posterior tibial tendon dysfunction. Foot Ankle Int. 2002:521–9.

23. Houlihan CM, Stevenson RD. Bone density in cerebral palsy. Phys Med Rehabil Clin N Am. 2009:493–508.

24. Ovalioglu AO, Kilincer C, Ovalioglu TC, et al. Avulsion fracture of the anterior iliac crest after bone graft harvest: Case report and review of techniques, risk factors and treatment. Turk Neurosurg. 2011:423–6.

25. Hinsenkamp M, Muylle L, Eastlund T, et al. Adverse reactions and events related to musculoskeletal allografts: Reviewed by the World Health Organization Project NOTIFY. Int Orthop. 2012:633–41.

26. Kainer MA, Linden JV, Whaley DN, et al. Clostridium infections associated with musculoskeletal-tissue allografts. N Engl J Med. 2004:2564–71.

27. Adams SB Jr, Simpson AW, Pugh LI, et al. Calcaneocuboid joint subluxation after calcaneal lengthening for planovalgus foot deformity in children with cerebral palsy. J Pediatr Orthop. 2009:170–4.