THE ANATOLIAN JOURNAL OF CARDIOLOGY

Official journal of the TURKISH SOCIETY OF CARDIOLOGY

TricValve Pop-Out: Management of Transcatheter Caval Valve Migration

CASE REPORT

INTRODUCTION

Tricuspid valve disease, particularly tricuspid regurgitation (TR), has been a "neglected valvulopathy" for many years. In patients with left heart pathologies, chronic pressure overload on the right ventricle causes functional TR and is associated with a poor prognosis.[1] Treatment of severe symptomatic TR has usually been restricted to diuretics and mostly remained ineffective.[2] Moreover, patients undergoing surgical repair of isolated tricuspid valve disease have the highest mortality of all valves, due to advanced right ventricular dysfunction and coexisting comorbidities.[3] Thus, transcatheter tricuspid valve therapy (TTVT) has emerged as a novel strategy for patients with high or prohibitive surgical risk. In this case, we performed bicaval valve implantation using TricValve to reduce caval backflow on a symptomatic patient with severe functional TR and successfully managed device migration complications.

CASE REPORT

An 86-year-old male presented with dyspnea and abdominal distention to our cardiology clinic. He had aortic mechanical prosthesis and coronary bypass surgery 18 years earlier and is known to have persistent atrial fibrillation, chronic renal failure, and chronic obstructive pulmonary disease. He had a history of multiple hospitalizations due to decompensated heart failure over the last few years. His functional class was New York Heart Association (NYHA) IV. Physical examination was positive for ascites, bilateral pretibial edema, and jugular vein distention. The patient was refractory to medical therapy including a combination of intravenous loop diuretic, thiazide, mineralocorticoid antagonist, and acetazolamide. As the patient was considered at high risk for isolated tricuspid valve surgery, the TTVT decision was made by the local heart team. Further diagnostic tests including transthoracic echocardiography (TTE), transesophageal echocardiography (TEE), right heart catheterization, and computed tomographic angiography (CTA) were performed to decide on the most suitable TTVT strategy regarding patient's anatomical and pathophysiological status.

Transthoracic echocardiography and TEE revealed normal left ventricular function with an ejection fraction of 60%, normal functioning aortic mechanical valve, moderate mitral regurgitation, dilated right atrium and ventricle, preserved right ventricular systolic function with tricuspid annular plane systolic excursion (TAPSE) of 1.9 cm and tissue doppler S' of 10.2 cm/s. Tricuspid regurgitation was severe (vena contracta 15 mm, EROA-PISA 66 mm^2), tethering and coaptation deficit of leaflets were present (Figure 1A–C). Computed tomographic angiography provided information about the geometry of right heart structures, inferior and superior vena cava dimensions and angulations, and hepatic vein landing zone border (Figure 1D). A right heart catheterization revealed prominent retrograde V-wave and post-capillary pulmonary hypertension. Regarding the patient's imaging results and advanced tricuspid valve disease, the patient was considered not eligible for percutaneous annuloplasty, edge-to-edge repair, or orthotopic replacement. The final decision was the implantation of heterotopic caval valve using TricValve (Products&Features, Austria).

Copyright@Author(s) - Available online at anatoljcardiol.com.
Content of this journal is licensed under a Creative Commons Attribution-NonCommercial 4.0 International License.

Barkın Kültürsay [1]
Gülsüm Bingöl [2]
Barış Güven [3]
Ahmet Yıldız [3]
Barış Ökçün [3]

[1]Department of Cardiology, Kartal Koşuyolu Training and Research Hospital, İstanbul, Turkey
[2]Department of Cardiology, Memorial Bahçelievler Hospital, İstanbul, Turkey
[3]Department of Cardiology, İstanbul University-Cerrahpaşa, Institute of Cardiology, İstanbul, Turkey

Correspondence author:
Barkın Kültürsay
bkultursay@gmail.com

Cite this article as: Kültürsay B, Bingöl G, Güven B, Yıldız A, Ökçün B. TricValve pop-out: Management of transcatheter caval valve migration. Anatol J Cardiol 2022;26(5):414-418.

DOI:10.5152/AnatolJCardiol.2021.1247

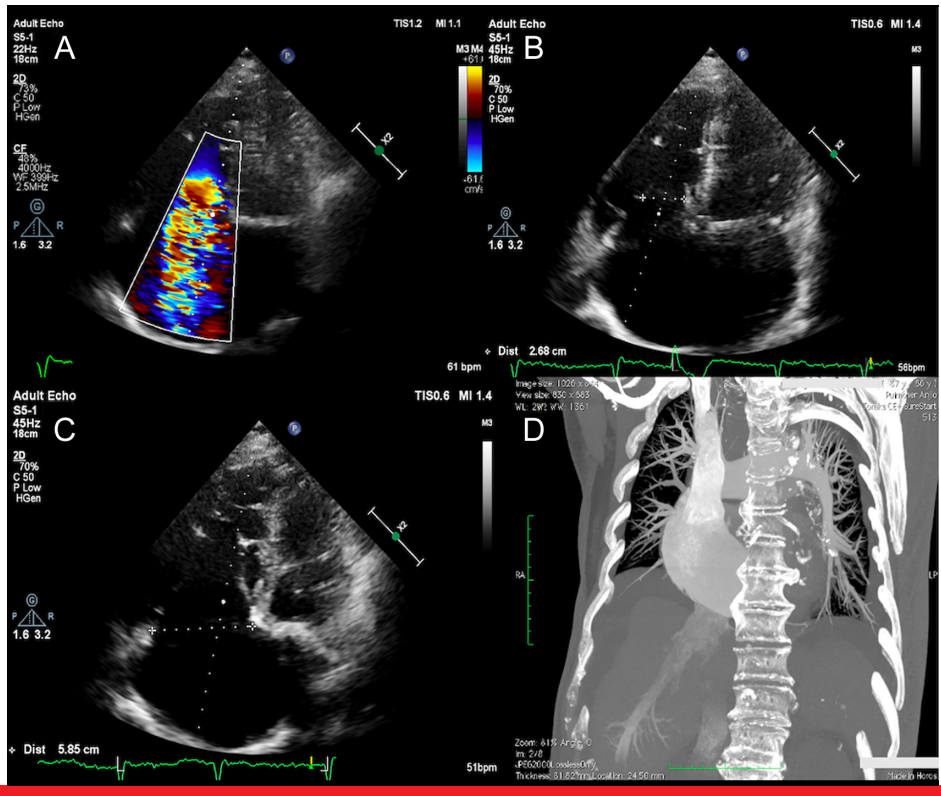

Figure 1. (A) Severe functional tricuspid regurgitation on TTE. (B) The coaptation gap measured 2.68 cm. (C) Dilated tricuspid annulus measured 5.85 cm. (D) CTA shows right heart structures, inferior and superior vena cava dimensions, angulations, hepatic vein landing zone border. CTA, computed tomographic angiography; TTE, transthoracic echocardiography.

The procedure began with an Amplatz J-tip wire advancing through the right femoral vein and right atrium into the right internal jugular vein. Then, an angiogram of the superior vena cava and the right subclavian vein was obtained. Before superior caval valve implantation, a catheter was placed distally in the right pulmonary artery as a marker of inferior vena cava (IVC)-right pulmonary artery crossing. Devices were loaded into 27F catheters for sheathless implantation. The superior vena cava (SVC) valve was deployed just above the IVC-right pulmonary artery crossing with its distal end aligned at the level of left brachiocephalic vein inflow (Figure 2A and B). The IVC valve was planned to be deployed above the diaphragm with a small protrusion into the right atrium. A Judkins Right catheter was placed in IVC to demonstrate hepatic vein flow and to show the inferior border of the IVC valve landing zone (Figure 2C). At the time of deployment, the IVC valve migrated into the right atrium (Figures 2D and 3A, Video 1). There was no hemodynamical worsening after migration of the valve. Deployment of another IVC valve protruding into the right atrium and overlapping the popped-out valve was decided. By overlapping the valves, the popped-out valve could be fixed in a stable position and any possible paravalvular leak could be prevented (Figure 3B and C). After successful deployment of the second IVC valve, no paravalvular leak or caval backflow was observed on the final venous angiogram (Figure 3D, Video 2). The patient was discharged with warfarin 3 days after the procedure. On the first- and third-month visits, significant improvement in functional capacity was observed (Table 1).

DISCUSSION

Tricuspid valve disease, TR, has gained increased recognition with the growing advancements in the field of transcatheter valvular therapies. Functional tricuspid regurgitation (FTR) is a common etiology of TR and is primarily due to enlarged tricuspid annulus, right ventricle enlargement, and right ventricular dysfunction. Functional tricuspid regurgitation mostly results from left-sided heart diseases and is associated with increased left atrial pressure, pulmonary hypertension, and increased right ventricular afterload.[4]

Tricuspid regurgitation is associated with increased mortality risk independent of pulmonary pressures and right heart failure.[5] Not only severe TR is associated with an increased risk of mortality and morbidity, but there is also an increased risk of mortality associated with the progression of the severity of the disease.

Medical therapy of severe symptomatic TR is restricted to diuretics but is usually ineffective, and diuretic resistance is an important fact in the management of patients with symptomatic severe TR. Thus, a correction in the anatomical level of this disease along with medical therapy is of great importance, whether with surgery or TTVT. Surgery remains the cornerstone of severe tricuspid valve disease. It is indicated

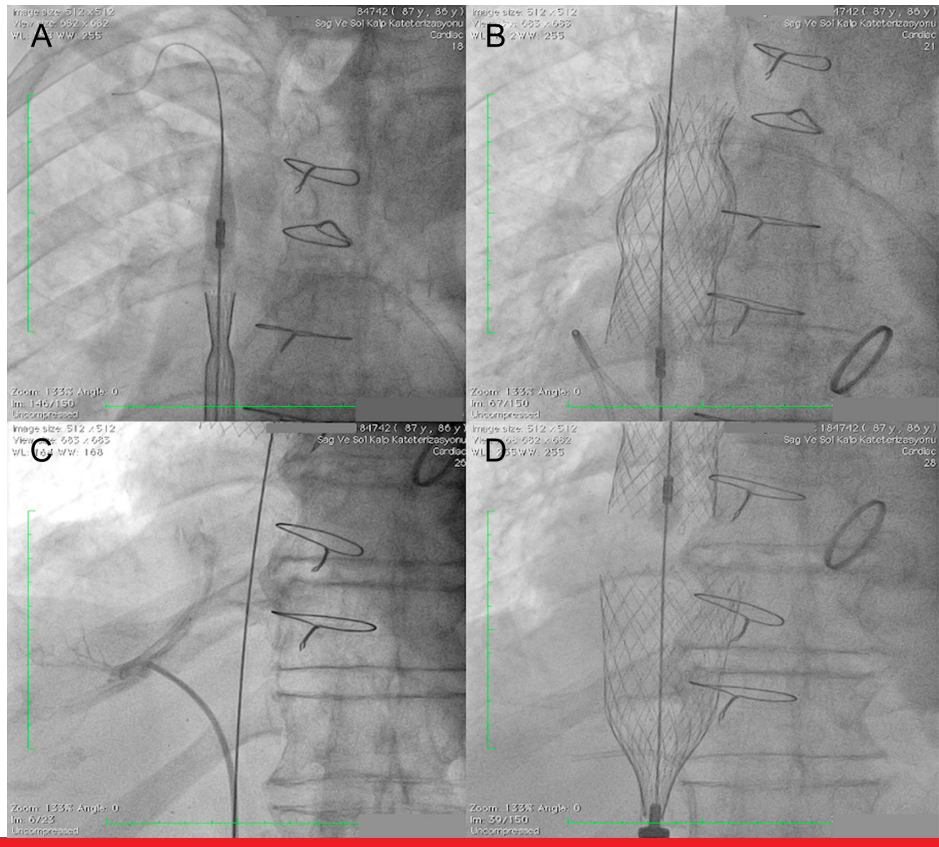

Figure 2. (A,B) The deployment of the SVC valve just above IVC-right pulmonary artery crossing with its distal end aligned at the level of left brachiocephalic vein inflow. (C) Angiogram demonstrating hepatic vein flow and shows the inferior border of the IVC valve landing zone. (D) Deployment of the IVC valve. IVC, inferior vena cava; SVC, superior vena cava.

in patients with severe FTR and moderate FTR with annular dilatation undergoing left-sided valve surgery with the recommendation of Class I-C and IIa-C, respectively. In patients with prior left-sided valve surgery, as represented in our case, surgery should be considered in the presence of symptoms or progressive right ventricular dilatation and dysfunction with the recommendation of Class IIa-C.[6] However, tricuspid valve surgery is associated with high mortality, primarily due to late referral of patients, which means patients having multiple coexisting comorbidities.[3] In this patient population, especially those at high or prohibitive risk of surgery, TTVTs have emerged as a new interventional concept.

Current TTVTs can be categorized into 4 groups in terms of mechanism of action: coaptation devices, annuloplasty devices, caval valve implantation (CAVI), and transcatheter tricuspid valve replacement.[7] Choosing the right strategy for the appropriate patient requires a multidisciplinary heart team evaluation of the patient's risk profile, anatomic suitability, and technical feasibility. In our case, we thoroughly evaluated our patient for choosing an appropriate TTVT option. Regarding current literature on TTVTs,[8] the patient's excessively dilated tricuspid annulus, and severely increased coaptation gap and length made our heart team consider coaptation devices, annuloplasty devices, and transcatheter valve replacement unsuitable. Intensively progressed disease pointed the decision on the most appropriate therapy option for this particular patient: heterotopic CAVI.

Heterotopic CAVI aims to reduce the caval backflow that occurs at the late stage of progressed TR by implanting balloon-expandable (SAPIEN Valve, Edwards Lifesciences) or specifically developed self-expandable valves [TricValve (P&F, Austria) and Tricento (NVT)] in vena cava inferior or in with the combination of superior vena cava. The First-in-Man study of CAVI was reported in 2018 and included 25 patients, and 6 of those patients were treated with TricValve, and others were treated with balloon-expandable SAPIENT XT/3. Procedural success was achieved in 96% and instant hemodynamic improvement was observed.[9]

Device embolization is a rare complication of transcatheter structural heart interventions. Although it is rare, it can lead to catastrophic consequences such as hemodynamic deterioration and sudden cardiac arrest.[10] Thus, an immediate, incorporated approach of both percutaneous techniques and surgical modalities is vital. As for peri- and postprocedural complications of CAVI, there were 2 device migrations. In one case, the SVC prosthesis was migrated just after deployment. In other cases, IVC prosthesis was migrated into the right atrium after several days after implantation. In both cases, valves were surgically recovered.[9] We evaluated

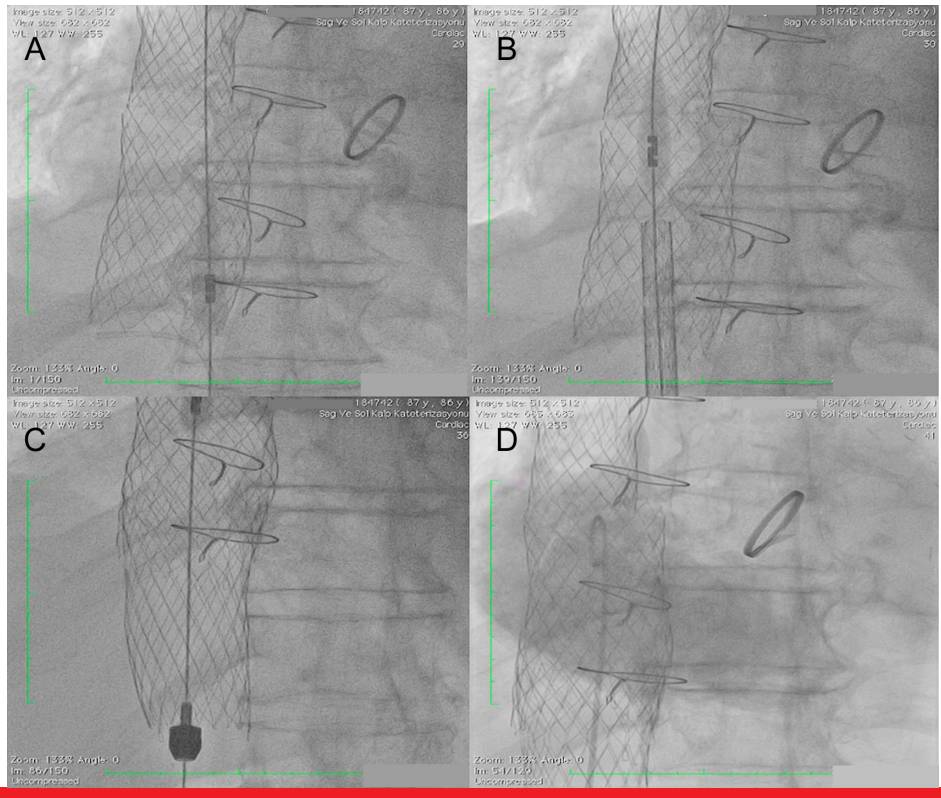

Figure 3. (A) Pop-out of the valve into the right atrium. (B) and (C) overlapping the popped-out valve by using another IVC valve. (D) Final angiogram shows no paravalvular leak or caval backflow.

our patient with CTA of venous structures for optimal sizing of TricValve 2 weeks prior to the procedure. Since the patients with severe TR have sensitive and variable fluid status, and as it is difficult to maintain euvolemic condition, device sizing especially for IVC could be a potential pitfall in such cases. Thus, device sizing should thoroughly be analyzed in a timely manner regarding patients' volume status before the procedure.

In our case, we successfully managed device migration complications non-surgically, by deploying a second IVC prosthesis to overlap with migrated valve, fixed and stabilized its position, and prevented the migrated valve from embolization or paravalvular leak. Thereby, we managed to avoid heart surgery on this high-risk patient. To date, this is the first case demonstrating successful percutaneous management of device migration of caval valve implantation.

Table 1. Hemodynamic, Echocardiographic, and Clinical Parameters Pre- and Post-intervention

	Baseline	Post-CAVI
Hemodynamics		
Pulmonary artery pressure, mm Hg (systolic/diastolic/mean)	40/25/15	56/31/17
Right atrial pressure, mm Hg (mean)	19	18
Vena cava inferior pressure, mm Hg (mean)	18	9
Vena cava superior pressure, mm Hg (mean)	17	8
Echocardiography		
Right atrial area, cm^2	53.2	56.5
Tricuspid annulus diameter, cm	5.85	5.9
TAPSE, cm	1.9	1.5
Clinical		
NYHA functional class	IV	II-III
6-minute walk test, m	148	210
NT-pro-BNP, pg/mL	7585	11 547

CAVI, caval valve implantation; TAPSE, tricuspid annular plane systolic excursion.

CONCLUSION

Tricuspid regurgitation is associated with increased morbidity and mortality. Surgery remains the cornerstone of symptomatic severe tricuspid valve disease. In patients with excessive risk for tricuspid valve surgery, transcatheter therapies are the preferred treatment. Caval valve implantation provides clinical and hemodynamical improvement in appropriately selected patients. Despite the advancements in transcatheter therapies, device embolization is still a rare but life-threatening complication. Since the patients with severe TR have a variable volume status, device sizing could be difficult and might result in device embolization. We demonstrated and reported the first successful percutaneous management of device migration complications during caval valve implantation.

Informed Consent: Written informed consent was obtained from the patient.

Acknowledgments: We thank Prof. Hans-Reiner Figulla, MD for mentoring; we thank Cüneyt Koçaş, MD for his contributions.

Video 1: IVC valve migrating into right atrium.

Video 2: Final angiogram showing no paravalvular leak or caval backflow

REFERENCES

1. Nath J, Foster E, Heidenreich PA. Impact of tricuspid regurgitation on long-term survival. *J Am Coll Cardiol*. 2004;43(3):405-409. [CrossRef]
2. Taramasso M, Vanermen H, Maisano F, Guidotti A, La Canna G, Alfieri O. The growing clinical importance of secondary tricuspid regurgitation. *J Am Coll Cardiol*. 2012;59(8):703-710. [CrossRef]
3. Zack CJ, Fender EA, Chandrashekar P, et al. National trends and outcomes in isolated tricuspid valve surgery. *J Am Coll Cardiol*. 2017;70(24):2953-2960. [CrossRef]
4. Prihadi EA, Delgado V, Leon MB, Enriquez-Sarano M, Topilsky Y, Bax JJ. Morphologic types of tricuspid regurgitation: characteristics and prognostic implications. *JACC Cardiovasc Imaging*. 2019;12(3):491-499. [CrossRef]
5. Wang N, Fulcher J, Abeysuriya N, et al. Tricuspid regurgitation is associated with increased mortality independent of pulmonary pressures and right heart failure: a systematic review and meta-analysis. *Eur Heart J*. 2019;40(5):476-484. [CrossRef]
6. Baumgartner H, Falk V, Bax JJ, et al. 2017 ESC/EACTS Guidelines for the management of valvular heart disease. *Eur Heart J*. 2017;38(36):2739-2791. [CrossRef]
7. Asmarats L, Taramasso M, Rodés-Cabau J. Tricuspid valve disease: diagnosis, prognosis and management of a rapidly evolving field. *Nat Rev Cardiol*. 2019;16(9):538-554. [CrossRef]
8. Laricchia A, Khokhar AA, Giannini F. New percutaneous options for tricuspid intervention: how to identify the good clinical candidate. *Front Cardiovasc Med*. 2020;7:583307. [CrossRef]
9. Lauten A, Figulla HR, Unbehaun A, et al. Interventional treatment of severe tricuspid regurgitation: early clinical experience in a multicenter, observational, first-in-man study. *Circ Cardiovasc Interv*. 2018;11(2):e006061. [CrossRef]
10. Alkhouli M, Sievert H, Rihal CS. Device embolization in structural heart interventions: incidence, outcomes, and retrieval techniques. *JACC Cardiovasc Interv*. 2019;12(2):113-126. [CrossRef]