Turkish Archives of Pediatrics

SCIENTIFIC LETTER
DOI: 10.5152/TurkArchPediatr.2022.2301

A Case with Preterm Ovarian Hyperstimulation Syndrome: The Importance of the Physical Examination in Differential Diagnosis of Ambiguous Genitalia

Ayşe Anık[1], Reyhan Deveci Sevim[2], Suzan Şahin[3], Abdullah Barış Akcan[1], Tolga Ünüvar[2], Ahmet Anık[2]

[1]Division of Neonatology, Department of Pediatrics, Aydın Adnan Menderes University, Faculty of Medicine, Aydın, Turkey
[2]Division of Pediatric Endocrinology, Department of Pediatrics, Aydın Adnan Menderes University, Faculty of Medicine, Aydın, Turkey
[3]Aydın Maternity and Child Health Hospital, Neonatal Intensive Care Unit, Aydın, Turkey

Preterm ovarian hyperstimulation syndrome (POHS) is a rare disease generally emerging between postconceptual age (PCA) 36 and 39 weeks in premature female babies. Clinically, the disease is characterized by edema in the vulva, hypogastrium, and upper leg region and at laboratory examination by high serum estradiol and gonadotropin levels and ovarian cysts. Since clitoral swelling can be seen in POHS patients, it can be confused with 46XX disorders of sexual development.[1-3]

A 3-month-old female infant (PCA 37 weeks) was transferred to our neonatal intensive care unit for further endocrinological evaluation. She was born at 25$^{3/7}$ weeks' gestation with a birth weight of 735 g. She had been hospitalized for 85 days in the neonatal intensive care unit due to morbidities related to prematurity. Gradually increasing edema involving the labium majus, vulva, and clitoris was found at a PCA of 32 weeks. Laboratory tests that were performed during nosocomial infection were as follows: serum estradiol: 47 pg/mL, dehydroepiandrosterone sulfate (DHEAS) > 1500 µg/dL, adrenocorticotropic hormone (ACTH): 28.6 pg/mL, and cortisol > 75 µg/dL. The patient was finally referred to our hospital with a preliminary diagnosis of generalized glucocorticoid resistance due to clitoromegaly, hypokalemia, and very high serum cortisol levels.

Physical examination on admission revealed swelling of labium majus, upper leg and hypogastric area, and clitoral swelling (clitoral length: 1.4 cm). No erectile tissue was palpated, and there were no signs of virilization except for clitoral swelling (Figure 1). Blood pressure was 72/40 mmHg. Laboratory results in our hospital were sodium: 139 mmol/L (N = 135-145), potassium: 5.2 mmol/L (N = 3.5-5.5), chloride: 111 mmol/L (N = 97-110), glucose: 70 mg/dL (N = 60-100), estradiol: 590 pg/mL (N = <56), follicle-stimulating hormone (FSH): 5.21 IU/L (N = 0.2-6.6 IU/L), luteinizing hormone (LH): 22.1 IU/L (N = 0.1-6 IU/L), DHEAS 3000 ug/dL (15-261), 17OH-progesterone: 17.47 ng/mL (N = 0.2-5.6), androstenedione: 7.74 ng/mL (N = 2.4-16.8), cortisol: 1.5 µg/dL (N = 4.6-22.8), and ACTH: 26 pg/mL (N = 15-60). Pelvic ultrasonography (USG) revealed pure cystic lesions of the bilateral ovaries (dimensions of right and left ovarian cysts were 19 × 29 mm and 13 × 22 mm, respectively, Figure 2). Generalized glucocorticoid resistance was excluded, and POHS was diagnosed with the clinical and laboratory findings. The patient was followed-up without any specific treatment and genital edema increased at PCA 39 weeks and moderately decreased at PCA 43 weeks, with simultaneously decreasing levels of gonadotropin, estradiol, and adrenal androgens (Table 1).

Preterm ovarian hyperstimulation syndrome is an extremely rare disorder. To the best of our knowledge, only 23 cases have been reported to date.[2,3] The characteristic signs of POHS are

Corresponding author:
Ahmet Anık
✉ahmet.anik@yahoo.com
Received: October 14, 2021
Accepted: December 1, 2021

Content of this journal is licensed under a Creative Commons Attribution-NonCommercial 4.0 International License.

Cite this article as: Anık A, Deveci Sevim R, Şahin S, Barış Akcan A, Ünüvar T, Anık A. A case with preterm ovarian hyperstimulation syndrome: the importance of the physical examination in differential diagnosis of ambiguous genitalia. *Turk Arch Pediatr.* 2022;57(2):244-246.

Figure 1. Edema of external genitalia and clitoral swelling.

vulvar, hypogastric, and leg edema detected at a median of 36.5 weeks of PCA (range: 30-39.6 weeks) with very high serum LH, FSH, and estradiol levels and ovarian cysts.[2,4] The etiology of POHS involves immaturity of the hypothalamic-pituitary-gonadal axis and a lack of negative feedback on the axis.[2] The hallmark of POHS is vulvar edema due to high levels of vascular endothelial growth factors secreted by ovarian cysts.[2]

The most common cause of clitoromegaly in infants is androgen exposure during fetal life, secondary to congenital adrenal hyperplasia. However, clitoromegaly that is not related to virilization syndrome is extremely rare.[5] Of the 22 patients with POHS reported in the literature, clitoral swelling was present in 14 (63.6%).[2,3] Clitoral swelling with external genital edema and no erectile tissue at palpation should raise a suspicion of POHS in preterm infants. In the present case, high serum cortisol was determined during nosocomial infection and was thought to be related to stress. Also, high levels of adrenal androgens (17OH-progesterone and DHEAS) were thought to be related to prematurity and/or stress.

In conclusion, clitoral swelling with genital edema is typical for POHS, especially with high gonadotropin and estradiol levels in preterm babies. Therefore, physical examination is essential for the diagnosis of POHS.

Peer-review: Externally peer-reviewed.

Author Contributions: Concept – A.A., A.A.; Design – A.A., R.D.S., S.Ş., A.B.A.; Supervision – A.A., A.A.; Resources – Materials – A.A., R.D.S., S.Ş., A.B.A., A.A.; Data Collection and/or Processing – A.A., R.D.S., S.Ş., A.B.A., T.Ü., A.A.; Analysis and/or Interpretation – A.A., D.D.S., S.Ş., A.B.A.; Literature Search – A.A., A.A.; Writing Manuscript – A.A., R.D.S., A.A.; Critical Review – A.B.A, T.Ü., A.A.

Conflict of Interest: The authors have no conflict of interest to declare.

Financial Disclosure: The authors declared that this study has received no financial support.

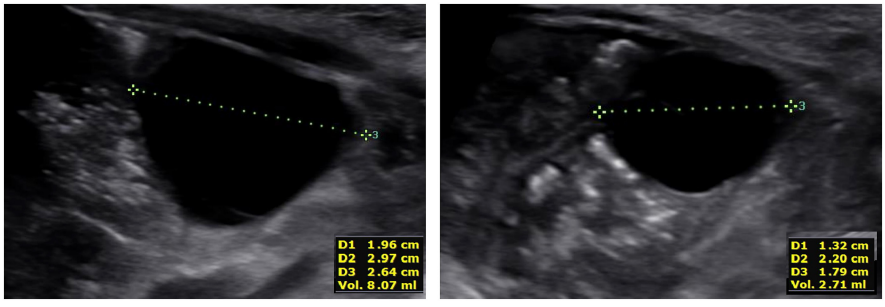

Figure 2. Bilateral large ovarian cysts.

Table 1. Laboratory Characteristics of the Patient

	Age (Postconceptual Weeks)					Normal Range
	34+5	38	38+5	39+1	42	
LH (mIU/mL)			38.1	22.1	5.5	0.1-6
FSH (mIU/ml)			13.3	5.2	3.4	0.2-6.6
E2 (pg/mL)	47		770	590	1.22	5-10
ACTH (pg/mL)	28.6	26				9-57
Cortisol (µg/dL)	>75	2.4		1.5		4.6-22.8
DHEAS (µg/dL)	>1500		>3000			15-261
17-OHP (ng/mL)		17.2		22.1	2.0	0.2-5.6
Androstenedione (ng/mL)		7.7				2.4-16.8
Plasma renin activity (ng/mL/h)		6.4				2.35-37
Aldosterone (ng/dL)		57.5				5-90

LH, luteinizing hormone; FSH, follicle stimulating hormone; E2, estradiol; ACTH, adrenocorticotropic hormone; DHEAS, dehydroepiandrosterone sulfate; 17-OHP, 17-hydroxyprogesterone.

REFERENCES

1. Sedin G, Bergquist C, Lindgren PG. Ovarian hyperstimulation syndrome in preterm infants. *Pediatr Res*. 1985;19(6):548-552. [CrossRef]
2. Sun Y, Chen C, Di T, et al. Clinical characteristics of preterm ovarian hyperstimulation syndrome: seven cases from China and 14 cases from the literature. *Gynecol Endocrinol*. 2019;35(9):819-824. [CrossRef]
3. Bayramoğlu E, Erdeve ŞS, Derinkuyu BE, Çelik İH, Çetinkaya S, Aycan Z. Clitoromegaly caused by ovarian stimulation in a preterm newborn: ovarian hyperstimulation syndrome of preterm babies. *Turk J Pediatr*. 2020;62(6):1088-1093. [CrossRef]
4. Esen I, Demirel F. Images in clinical medicine. Preterm ovarian hyperstimulation. *N Engl J Med*. 2015;372(24):2336. [CrossRef]
5. Iezzi ML, Lasorella S, Varriale G, Zagaroli L, Ambrosi M, Verrotti A. Clitoromegaly in childhood and adolescence: behind one clinical sign, a clinical sea. *Sex Dev*. 2018;12(4):163-174. [CrossRef]