Diagn Interv Radiol 2021; 27:694–702
© Turkish Society of Radiology 2021

ABDOMINAL IMAGING
ORIGINAL ARTICLE

Are the washout values currently accepted for lesion characterization in dedicated adrenal CT adequate for diagnosis?

Elif Gündoğdu
Mehmet Oğuzman
Emre Emekli
Mahmut Kebapçı

PURPOSE
We aimed to investigate the accuracy of density characteristics and washout values of lesions detected on computed tomography (CT) at the cutoff values obtained from the literature by taking the pathological results of adrenalectomy specimens as reference and to determine the cutoff values of parameters evaluated on CT for the differentiation of adenoma and nonadenoma lesions in the study group.

METHODS
Hospital records and standard CT imaging data (noncontrast early phase [65 s] and late phase [15 min]) of 84 patients with 87 lesions who underwent adrenalectomy between January 2012 and December 2018 were retrospectively reevaluated by two radiologists in consensus. The patients were categorized as having adenoma and nonadenoma lesions according to the pathology results. The sensitivity, specificity and diagnostic accuracy of CT parameters (density values and washout percentages) were evaluated. Differences in the CT parameters (size, noncontrast and early-late enhancement density and absolute and relative washout values) were investigated. The optimal cutoff values of CT parameters were determined by ROC analysis.

RESULTS
Noncontrast CT had a specificity of 87.75% and 95.9%, sensitivity of 60% and 48.6%, diagnostic accuracy of 77.7% and 89.47% for adenomas, at the cutoff values of ≤10 HU and ≤0 HU, respectively. For absolute washout value ≥ 60%, the sensitivity, specificity and accuracy were 64.7%, 52.38% and 56.75%, respectively; while these rates were 76.47%, 56.52% and 62.16%, respectively, for relative washout value ≥40%. Adenomas and nonadenomas showed significant difference in terms of size ($p < 0.0001$), unenhanced attenuation ($p < 0.0001$), relative washout ($p = 0.020$) and delay enhancement ($p < 0.001$). But there were no differences in terms of absolute washout ($p = 0.230$) and early enhancement ($p = 0.264$). The cutoff values for the differentiation of adenomas and nonadenomas were as follows: size ≤44 mm, noncontrast density <20 HU, early-phase density ≥45 HU, delayed-phase density ≤44 HU, absolute washout 74.83% and relative washout 57.76%.

CONCLUSION
The current washout criteria used in the differentiation of adenoma and nonadenoma lesions in dynamic CT imaging can give false negative and positive results. According to the existing criteria, the most reliable parameter in adenoma–nonadenoma differentiation is ≤ 0 HU noncontrast CT density value.

According to the autopsy studies, adrenal masses are among the most common tumors detected in humans (1). In autopsy series, this prevalence has been reported as 1% to 9.8% (1). With the advances in imaging techniques and their increasing use, there has also been a recent increase in radiologically reported adrenal masses (2–5), varying between 0.35% and 5% for CT examinations (6). Adenomas are the most common adrenal lesions in patients without primary malignancy (1, 7, 8). Although adrenal gland is a common site for distant metastases in patients with known malignancies, adenomas are more common than metastases in these patients. Since the majority of adrenal adenomas are benign and nonfunctional lesions, a clinical and radiological follow-up is sufficient. In nonadenoma lesions, a biopsy or direct surgical resection can be recommended

From the Department of Radiology (E.G. ✉ *elif_basbay@hotmail.com*), Eskişehir Osmangazi University, Faculty of Medicine, Eskişehir, Turkey.

Received 25 June 2020; revision requested 15 July 2020; last revision received 19 October 2020; accepted 29 October 2020.

Published online 13 October 2021.

DOI 10.5152/dir.2021.20508

You may cite this article as: Gündoğdu E, Oğuzman M, Emekli E, Kebapçı M. Are the washout values currently accepted for lesion characterization in dedicated adrenal CT adequate for diagnosis? Diagn Interv Radiol 2021; 27:694–702

according to the characteristics of the patient. Therefore, determination of whether a detected adrenal mass is an adenoma or nonadenoma is critically important in patient management and changes the form of treatment (9).

Computed tomography (CT) is the radiological method of choice in the characterization of adrenal mass lesions (8, 10). Adenomas have low density values in noncontrast CT scans due to their intracytoplasmic fat content (3, 6, 10, 11). However, as much as 30% of adrenal adenomas are poor in fat, thus making it impossible to distinguish them from other masses based on noncontrast CT density (8, 10). In this case, most authors reported that the washout character determined by dynamic contrast-enhanced CT examination differentiates adrenal adenomas from other lesions (10–13). Due to their rich capillary network, adenomas are stained early with the contrast agent, causing them to exhibit a high level of washout (8). However, some nonadenoma lesions, particularly pheochromocytoma, have been reported to show a similar washout pattern (4, 14–18). In the literature, there are many studies that investigated noncontrast and contrast-enhanced CT density and the washout criterion for the differentiation of adenoma and nonadenoma lesions (4, 6, 10–18). However, the scan parameters used in these studies, the characteristics of the devices, the time of wash-in and washout, contrast agent dose, and iodine concentration are not standard and show differences (e.g., 2.5–10 mm collimation; 3–5 mm reconstruction intervals; 80–140 kVp; 150–370 mA; 0.75–3:1 pitch; nonhelical, helical, or multi-slice device; 35–120 s wash-in time; 3–45 min washout time; 100–150 mL contrast agent dose; 300–370 mg/L iodine concentration). In a study using different minutes as washout criteria in the same lesions, different specificity and sensitivity values were found according to the washout time (19). In studies evaluating the effectiveness of adrenal CT in the literature, the reference method also differs. For these reasons, the available literature data is far from being standard. Nonadenoma lesions, which are evaluated as adenoma based on the available data, may cause serious problems in patient management.

In the current study, we aimed to investigate the accuracy of density characteristics and washout values of lesions detected on CT at the cutoff values obtained from the literature by taking the pathological results of adrenalectomy specimens as reference to determine the cutoff values of parameters evaluated on CT for the differentiation of adenoma and nonadenoma lesions in the study group.

Main points

- The current washout criteria used in the differentiation of adenoma and nonadenoma lesions in the dynamic contrast adrenal CT could give false results.
- In adenomas, delayed-phase CT density values are lower than nonadenomas. Therefore, in delayed-phase examinations, low density value can be used together with the washout criterion.
- In lesions with 0–10 HU density, adenoma–cyst differentiation is only possible through a contrast examination; noncontrast CT can be confusing in these lesions.

Methods

Local ethics committee approval was obtained for this study (no: 25403353-050.99-E.72970). The study was conducted in accordance with the principles of the Declaration of Helsinki. All image data used in this study were obtained from routine imaging at our institution. Datasets were evaluated retrospectively. Therefore, approval and informed consent were not necessary and waived by our local institutional review board.

Medical data and the CT images of patients that underwent adrenalectomy due to an adrenal mass between January 2012 and December 2018 were obtained from the image archive of the hospital and retrospectively reevaluated. A total of 144 patients were included in the evaluation. Patients were excluded from the study if they fulfilled any of the following criteria: a size less than 1 cm (n=3), unacceptable CT scans (n=51; single portal venous phase abdomen CT, n=6; delayed phase imaging time other than 15 min). The remaining 84 patients with 87 adrenal mass (n=3; bilateral mass) who met the inclusion criteria were enrolled in the study. The flowchart is represented in Fig.1.

Pathological results of adrenalectomy specimens were used as the gold standard reference. The patients were categorized as having adenoma and nonadenoma lesions according to the pathology results. Nonadenoma lesions were examined under subcategories according to the same results.

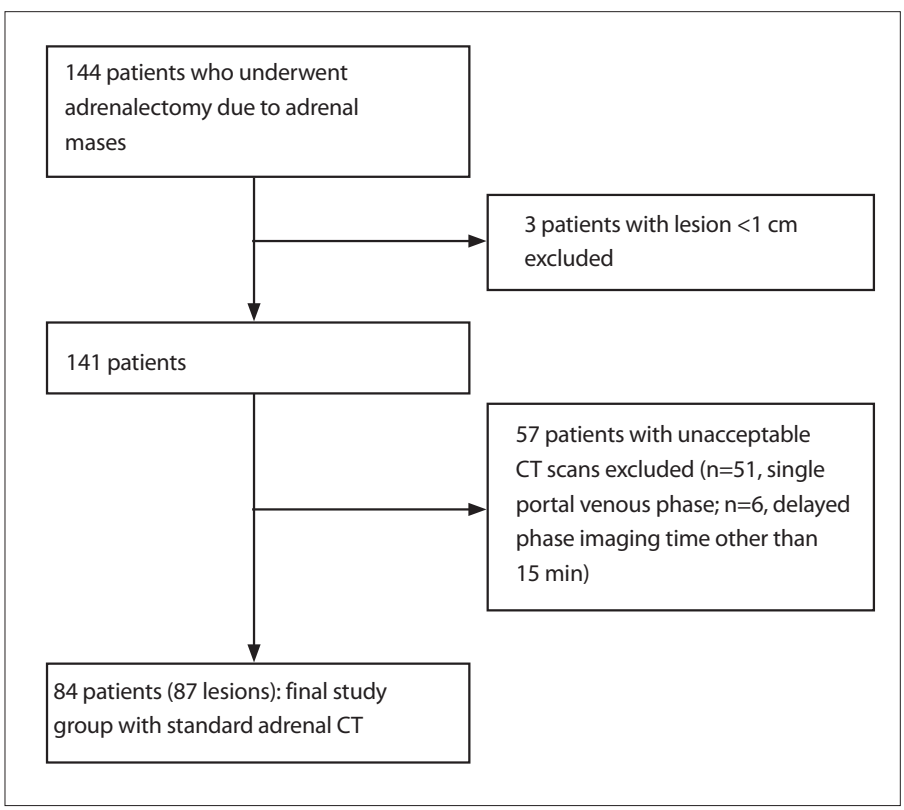

Figure 1. Recruitment scheme of the participants.

A separate evaluation from other nonadenoma lesions was undertaken for metastasis and pheochromocytoma, which are common in nonadenoma lesions and important in diagnosis.

CT examinations

CT imaging was performed using 64-slice (Toshiba, Aquillon) or 128-slice (GE, Revolution) multidetector CT scanners. All CT examinations were performed using a standard adrenal CT protocol.

The standard CT protocol applied in our clinic is as follows: Initially, CT covering the adrenal gland and lesion is performed without oral or intravenous contrast agent. The examination is ended without applying contrast agent in lesions with a density of ≤0 HU (n=22 patients with 22 lesions in this study). For lesions with a density >0 HU (n=62 patients with 65 lesions in this study), a two-phase dynamic contrast CT examination is undertaken, in which in addition to noncontrast scanning, early (65 s) and late (15 min) phase images are taken after the bolus administration of iodinated contrast agent intravenously.

The CT parameters were as follows: 1:1 pitch, 200–250 mAs, 120 kVp, 0.5–0.625 isotropic spatial resolution. Intravenous contrast agent (1.5 mL/kg; iopromide 370, Bayer Schering Pharma AG, or iohexol 350, GE Healthcare) was administered through the antecubital veins with an automatic injector at a rate of 3 mL/s.

Image analysis

The images were evaluated by two radiologists experienced in abdominal radiology, blinded to the pathological, clinical and laboratory results of the patients, using a dedicated workstation (GE, Advantage Workstation 4.3) based on consensus. All measurements of the investigated parameters were performed twice and averaged. To obtain the size of the lesion, the widest diameter in the axial plane was measured. A circular or elliptical region of interest (ROI) was used to measure CT attenuation. The ROI was placed in a central region away from the periphery to prevent a partial volume effect, covering 1/2 to 2/3 of the mass. Cystic, necrotic, calcified or hemorrhagic areas were not included in the measurement since they could affect the results. The ROI was placed in the same location in all phases. Absolute and relative washout values were calculated using the following formula:

Absolute washout = (Early-phase CT attenuation – Delayed-phase CT attenuation) × 100% /

(Early-phase CT attenuation – Noncontrast-phase CT attenuation)

Relative washout = (Early-phase CT attenuation – Delayed-phase CT attenuation) × 100% /

(Early-phase CT attenuation)

Twenty-two lesions with density ≤0 HU were evaluated by noncontrast CT. Contrast-enhanced examination was performed for 65 lesions in 62 patients with a density >0 HU.

In the dynamic contrast examination, according to their enhancement characteristics, the lesions were classified as nonenhancement plateau or progressive contrast enhancement, and showing washout. Lesions that did not change in density value or showed an increase in density of <10 HU in early- and late-phase images taken after contrast agent administration were evaluated as lesions that did not show enhancement. Lesions with an increased density of ≥10 HU were included in the enhancing lesions group. The lesions with late-phase density values of at least 10 HU lower compared to the early phase, were evaluated as lesions showing washout, while the remaining lesions were included in the category of plateau or progressive enhancing lesions. The lesions showing washout were classified as absolute and relative washout for the 60% and 40% thresholds, respectively.

Statistical analysis

SPSS software v. 22.0 (IBM Corp.) was used for statistical analysis. The normality analysis was performed with the Shapiro–Wilk test. Descriptive statistics of discrete data are given in the form of n (%). The sensitivity, specificity and accuracy rates of CT for the adenoma–nonadenoma differentiation were calculated at the cutoff values of ≤0 HU and ≤10 HU, and 40% relative and 60% absolute washout. Student t-test was used to compare all parameters (size, noncontrast and early-late enhancement density and absolute and relative washout values) of adenoma and nonadenoma lesions. The ANOVA test was conducted to compare the parameters between adenoma, metastasis, and pheochromocytoma subgroups. The post hoc analysis was performed after ANOVA test to determine which group caused the difference. A p value of less than 0.05 was considered significant. ROC analysis was undertaken to evaluate the efficacy of the parameters obtained from CT data in differentiating adenoma and nonadenoma lesions. The area under the curve (AUC) was used to determine the cutoff values. The optimal cutoff values were determined according to Youden J index (sensitivity+specificity-1). For each cutoff, 95% confidence interval, sensitivity, specificity, positive predictive value, negative predictive value, and accuracy rate were calculated.

Results

From the adrenalectomy specimens, 87 pathologically diagnosed masses of 84 patients (bilateral masses in three patients) (mean age 49.50±11.69 years, 18–73 years) were evaluated. The sample consisted of 53 female (63.09%, mean age 46.88±11.47 years, 18–73 years) and 31 male (36.90%, mean age 54.22±10.08 years, 34–73 years) patients. There were no age differences between the patient groups with adenoma and nonadenoma lesions (p = 0.770). Female sex was more frequent in the adenoma group than in the nonadenoma group (p = 0.007). The distribution of the lesions according to their pathological diagnoses, their localization, and demographic characteristics of the patients are summarized in Table 1.

The specificity, sensitivity and diagnostic accuracy rates of CT for adenomas according to the current literature suggestions (0 and 10 HU threshold for noncontrast CT, absolute washout 60% and relative washout 40%) are presented in Table 2.

Dynamic contrast examination (two-phase; 65 s and 15 min) was performed in 65 lesions; lesions were classified according to their enhancement characteristics as nonenhancing (n=9), plateau or progressive contrast enhancement (n=19), and showing washout (n=37). The group showing washout was also classified as <60% and ≥60% for absolute washout (n=16 and n=21, respectively), and as <40% and ≥40% for relative washout (n=14 and n=23, respectively). In the two-phase (65 s and 15 min) dynamic contrast CT examination in 65 lesions, cysts constituted all of the nonenhancement lesions (Fig. 2). Ganglioneuroma (Fig. 3), tuberculosis and lymphoma were in the plateau or progressive enhancement group. Lipid-poor adenoma, pheochromocytoma (Fig. 4), metastasis, adrenocortical carci-

Table 1. Clinical characteristics

Pathological diagnosis	Patient number n (%)	Location (Right/Left/Bilateral)	Age (years) mean±SD (range)	Sex (Female/Male)
Adenoma	35 (40.22)	14/21/0	49.94±10.69 (22–73)	28/7
Nonadenoma lesions				
Pheochromocytoma	18 (20.68)	8/6/2	48.43±11.87 (25–69)	7/9
Cyst[a]	11 (12.64)	4/7/0	44.63±11.65 (30–64)	9/2
Metastasis[b]	10 (11.49)	6/4/0	60.5±10.36 (40–73)	1/9
Oncocytic tumor	3 (3.44)	2/1/0	43±1.73 (41–44)	2/1
Myelolipoma	3 (3.44)	2/1/0	53.33±2.08 (51–55)	2/1
Ganglioneuroma	2 (2.29)	1/1/0	46.5±0.70 (46–47)	1/1
Adrenocortical carcinoma	2 (2.29)	2/0/0	26±11.31 (18–34)	2/0
Lymphoma	2 (2.29)	0/0/1	64	1/0
Tuberculosis	1 (1.14)	1/0/0	49	0/1
Total	87	40/41/3	49.50±11.69 (18–73)	53/31

[a]Cysts include four lymphangiomas, two endothelial cysts, five epithelial cysts; [b]Metastases include one malignant melanoma, one ureteral carcinoma, five lung adenocarcinomas, two squamous cell carcinomas of the lung, one small cell carcinoma of the lung.

Table 2. Specificity, sensitivity, and accuracy rate of CT imaging in diagnosis of adenoma

	Lesion number (n)	Specificity (%)	Specificity (95% CI)	Sensitivity (%)	Sensitivity (95% CI)	Diagnostic accuracy (%)
Noncontrast CT ≤0 HU	22	95.9	86.54–99.52	48.6	31.58–66.01	89.47
Noncontrast CT ≤10 HU	30	87.75	73.74–94.3	60	42.11–76.13	77.7
Contrast-enhanced CT Relative washout ≥40%	37	56.52	43.69–78.9	76.47	46.52–90.31	62.16
Contrast-enhanced CT Absolute washout ≥60%	37	52.38	43.69–78.9	64.7	35.75–82.7	56.75

CT, computed tomography; CI, confidence interval.

Figure 2. a–c. Histopathologically proven endothelial cyst. Axial precontrast **(a)**, early-phase **(b)**, and delayed-phase **(c)** CT images show a well-defined left adrenal mass. Low attenuation (mean 2 HU) on the precontrast image and no contrast enhancement on the postcontrast image are seen. These CT findings are consistent with a cyst.

noma, and oncocytic tumors (Fig. 5) were found in both washout group and plateau or progressive enhancement groups. The enhancement features and distribution according to the pathology of the lesions are shown in Table 3.

The CT features of adenoma and nonadenoma lesions (metastasis and pheochromocytoma as subgroups) are shown in Table 4.

Adenoma and nonadenoma lesions showed significant difference in terms of lesion size, noncontrast density, delayed-phase enhancement, and relative washout values (except for relative washout values in pheochromocytoma and metastasis subgroups, and lesion size in metastases subgroup). There was no difference in early-phase enhancement and absolute washout values between adenoma and nonadenoma lesions. The findings are summarized in Table 5.

The ROC analysis (Fig. 6) results evaluating the effectiveness of size, noncontrast CT, early phase CT, late phase CT, absolute and relative washout in differentiating adenoma and nonadenoma lesions are summarized in Table 6.

Discussion

We tested the CT criteria accepted for differentiation of adenoma and nonadenoma adrenal lesions in the current literature in our study group who underwent adrenalectomy due to detection of an adrenal mass.

Table 3. Enhancement pattern of lesions

	No contrast enhancement (n)	Plateau/ Progressive contrast enhancement (n)	<60% Absolute washout (n)	≥60% Absolute washout (n)	<40% Relative washout (n)	≥40% Relative washout (n)
Adenoma		1	6	11	4	13
Pheochromocytoma		4	8	6	7	7
Cyst	9					
Metastasis		7	2	1	2	1
Oncocytic tumor		1		2	1	1
Ganglioneuroma		2				
Adrenocortical carcinoma		1		1		1
Lymphoma		2				
Tuberculosis		1				
Total	9	19	16	21	14	23

n, number of lesions.

Figure 3. a–c. Histopathologically proven ganglioneuroma. Dedicated adrenal CT; axial precontrast **(a)**, axial early-phase **(b)**, and axial delayed-phase **(c)** CT images show a right-sided, homogeneous, well-defined adrenal mass with progressive contrast enhancement (37 HU, 52 HU, and 101 HU, respectively). The mass was evaluated as a nonadenoma lesion on CT.

Figure 4. a–c. Histopathologically proven pheochromocytoma. Axial precontrast **(a)**, early-phase **(b)**, and delayed-phase **(c)** CT images show a right-sided adrenal mass with attenuation values of 27 HU, 111 HU, and 58 HU, respectively. Absolute percent washout and relative percent washout were calculated as 63% and 47%, respectively. The lesion was evaluated as a lipid-poor adenoma preoperatively, but the pathological diagnosis was pheochromocytoma, indicating a false positive result due to the lesion mimicking an adenoma.

We found that the highest diagnostic accuracy parameter for adenoma was ≤0 HU noncontrast CT density value. In our study group, both the specificity and sensitivity values of the absolute and relative washout criteria were lower than the literature. We found that some nonadenoma lesions, especially pheochromocytoma, may show an absolute and relative washout value similar to that of fat-poor adenomas. Furthermore, some of the adenomas showed washout but they did not meet the cutoff values for the washout criteria and showed false negativity. Distinguishing cystic lesions from adenomas was possible only with contrast examination. The adenomas had smaller lesion size, higher relative wash value, lower noncontrast and late phase CT density compared with nonadenoma lesions.

In their meta-analysis of 10 studies, Boland et al. (20) found that for the differen-

Table 4. CT characteristics of the lesions

Pathological diagnosis	Size (mm)	Unenhanced attenuation (HU)	Absolute washout (%)	Relative washout (%)	Early enhancement (HU)	Delayed enhancement (HU)
Adenoma	31.37±8.97 (14–49)	4.17±16.44 (-23 to 33)	65.72±18.41 (30.77–85.07)	52.60±15.84 (20–72)	87.16±37.10 (46–180)	39.5±11.11 (24–67)
Nonadenoma lesions	51.17±23.73 (16–106)	20.71±25.11 (-80 to 46)	59.88±13.09 (34.55–83.33)	41.86±12.82 (20.78–64.36)	73.97±43.70 (26–176)	55.66±25.64 (30–114)
Pheochromocytoma	49.77±21.10 (16–98)	32.5±6.35 (23–46)	59.74±13.04 (37.21–83.33)	41.45±12.45 (20.78–64.36)	103.33±37.25 (56–176)	65.72±16.37 (36–96)
Metastasis	37.30±19.73 (10–72)	30.4±7.50 (15–41)	53.22±19.10 (34.55–72.73)	34.12±12.87 (21.84–47.52)	71.1±29.91 (26–116)	63.3±22.31 (30–114)

Data are presented as mean±standard deviation (range).
CT, computed tomography; HU, Hounsfield unit.

Figure 5. a–c. Histopathologically proven oncocytic tumor. Axial precontrast **(a)**, early-phase **(b)**, and delayed-phase **(c)** CT images show an adrenal mass measured to have attenuation of 29 HU, 123 HU, and 61 HU, respectively. Absolute percent washout and relative percent washout are 65% and 50%, respectively. These CT findings are consistent with a lipid-poor adenoma. This false positive result was due to the lesion mimicking the washout pattern of an adenoma.

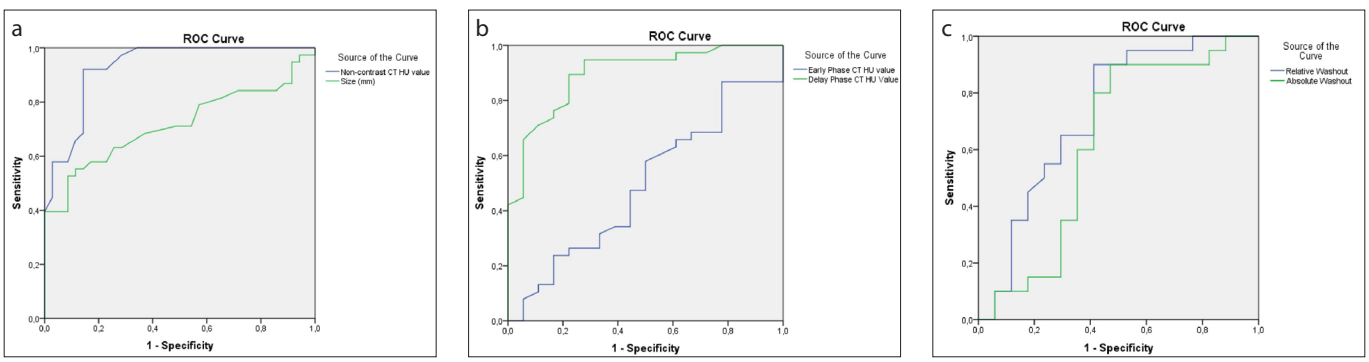

Figure 6. a–c. ROC analysis of effectiveness of CT imaging in differentiating adenoma and nonadenoma lesions: **(a)**, noncontrast CT (AUC=0.929); **(b)**, early phase CT (AUC=0.509), delayed phase CT (AUC=0.901); **(c)** relative washout (AUC=0.728), absolute washout (AUC=0.624).

tiation of benign and malignant lesions, noncontrast CT had a sensitivity and specificity of 41% and 100%, respectively, at the cutoff value of 0 HU and 71% and 98%, respectively, at the cutoff value of 10 HU. In another study evaluating 101 adrenal lesions, it was reported that benign lesions could be differentiated from malignant lesions with 89% sensitivity and 100% specificity at a cutoff value of 10 HU (10). In the current study, at the same cutoff, noncontrast CT had 87.75% specificity and 60% sensitivity in differentiating adenomas from nonadenomas. The lower level of sensitivity obtained from our study group can be explained by the presence of benign pathologies (e.g., cysts, tuberculosis, ganglioneuromas) in the nonadenoma group. Similar to our study, Kamiyama et al. (6) reported a specificity of 100% and sensitivity of 57%. Thirty percent of adenomas being poor in lipids is a factor that reduces sensitivity both in our study and in that of Kamiyama et al. (6).

Some researchers also evaluated the effectiveness of delayed-phase density value in differentiating adenomas from nonadenomas (3 ,11, 13). These studies used different times for the delayed-phase examination (10th and 15th min) and cutoff values (35–52 HU), reporting the sensitivity as 63.4%–96% and specificity as 89.3%–100%. In the current study, the sensitivity was calculated as 72.22% and specificity as 80% at the cutoff value of ≤44 HU. Both in the current study and that of Park et al. (3),

Table 5. Comparison of evaluation parameters between groups

Parameter	Adenoma–Nonadenoma *p*	Adenoma–Pheochromocytoma *p*	Adenoma–Metastasis *p*	Pheochromocytoma–Metastasis *p*
Size	<0.0001*	0.006*	1	0.540
Unenhanced attenuation	<0.0001*	<0.0001*	<0.001*	1
Absolute washout	0.230	1	ND	ND
Relative washout	0.020*	0.224	ND	ND
Early enhancement	0.264	1	1	0.146
Delay enhancement	<0.001*	0.002*	0.020*	1

ND, not determined. Since the number of washout lesions (n=3) in the metastasis group was insufficient, statistical analysis could not be performed.
* $p < 0.05$ indicates a statistically significant difference between groups.

Table 6. Optimal threshold value of size, CT attenuation and washout rate for detection of adenoma

CT parameters	Criteria	AUC	95% CI	Sensitivity	Specificity	PPV	NPV	Accuracy	*p*
Size (mm)	≤44	0.716	0.598–0.815	91.43	52.63	64.00	86.95	71.23	<0.0001
Noncontrast CT (HU)	≤20	0.929	0.844–0.976	85.71	92.11	90.90	87.50	89.04	<0.0001
Early phase CT (HU)	≥45	0.509	0.372–0.645	100.00	13.16	32.43	100.00	33.03	<0.0001
Late phase CT (HU)	≤44	0.901	0.803–0.952	72.22	80.00	59.09	87.80	77.77	<0.0001
Absolute washout (%)	74.83	0.624	0.449–0.777	90.00	52.94	81.81	69.23	72.97	=0.074
Relative washout (%)	57.76	0.728	0.557–0.861	90.00	58.82	83.33	72.00	75.67	=0.0008

CT, computed tomography; AUC, area under the curve; CI, confidence interval, PPV, positive predictive value; NPV, negative predictive value; HU, Hounsfield unit.

pathological diagnosis was taken as the reference method and the results were similar. However, these specificity and sensitivity values were lower than those reported by Szolar et al. (13). This difference may be due to the nonpathological examination techniques (clinical follow-up, stable CT findings) being taken as reference in the latter study. However, a common finding was that the delayed-phase density values were significantly lower in adenomas than nonadenomas on contrast-enhanced CT. Szolar et al. (13) did not determine a significant difference between metastases, pheochromocytomas and adrenocortical carcinomas in terms of delayed-phase CT density values. Similarly, we did not detect a significant difference between pheochromocytomas and metastases.

Many studies in the literature reported that the washout values determined by dedicated adrenal CT examinations had high sensitivity and specificity values in distinguishing adenoma and nonadenoma lesions (3, 10–13, 17). In these studies, the delayed-phase scanning time used for dynamic examination varied (10th and 15th min) and different percentages (40%, 50% or 55%) were used for relative and absolute washout values. The sensitivity for the differentiation of adenomas and nonadenomas was reported as 52.1%–100% and specificity as 92%–100%. In the current study, the sensitivity for adenoma was 64.7% and the specificity was 52.38% at the absolute washout value ≥60%, and these values were 76.47% and 56.52%, respectively for the relative washout value ≥40%. The lowest sensitivity rate reported in studies conducted to date belongs to a study by Sangwaiya et al. (17), which is similar to the sensitivity rate determined in our study. The lowest specificity value was obtained from our study. Except Park et al. (3), all other researchers used nonpathological diagnostic criteria as reference methods, such as a stable lesion size and a noncontrast CT density value of <10 HU. The time accepted in the stability criterion varies from one study to another. However, the slow growth trend of some nonadenoma lesions or the growth tendency of some adenomas make it questionable to use stability as a criterion. Therefore, in our study, we accepted the pathology specimen of adrenalectomy as a criterion. In addition to the reference method used, there are also some differences in the methodology in terms of study design and patient population. Sangwaiya et al. (17) classified the lesions as adenomas and nonadenomas, and further categorized adenomas as lipid rich and poor. The number of nonadenoma lesions is very low since incidental lesions are evaluated. In our study, the number and variety of nonadenomas were higher. Therefore, we chose to examine common pheochromocytoma and metastases among nonadenoma lesions under separate headings. Both Sangwaiya et al. (17) and other previous studies evaluated incidental lesions, and therefore the number of patients who underwent surgery was low (6, 11, 12, 17, 19). In daily practice, lesions that do not require adrenalectomy (benign lesions undergoing follow-up or metastases in oncologic patients) are observed more frequently than those that require this procedure. In our study, the examination of lesions requiring adrenalectomy clinically or radiologically caused the patient population to differ from the patient profile encountered in daily practice.

This may be one of the reasons why our sensitivity and specificity rates were relatively low. In addition, difference in scanning times (5–15 min) used for delayed-phase scanning have resulted in varying sensitivity and specificity values in the literature (19). Different time criteria can be used even in the same study, which is

a factor affecting the results. Furthermore, the differences in the numbers of adenoma and nonadenomas and variety of lesions can also explain the inconsistent values. In our study, using the adrenalectomy specimen alone as reference might also explain our different results. Since most benign and probably nonfunctional lesions that do not require surgery are adenomas, their exclusion from our sample might have reduced sensitivity and specificity in this study. This should be taken into account when interpreting our study results.

In the literature, some studies using late-phase images with different scanning times to differentiate adrenal lesions from adenoma and nonadenomas reported that images obtained at the 15th minute provide more accurate results (19). In addition, there are studies in which a single late-phase examination but a two-phase early examination (arterial and portal) were undertaken (21) or different times were used for the early and late phases (22). Foti et al. (21) used 35 and 80 seconds for the early phase examination and the 5th minute for the late-phase examination. The authors showed that biphasic early screening provided more accurate results because it allowed for the evaluation of peak enhancement in clinics where a 15-minute delay was too long due to the busy nature of the clinic. They found that in both adenomas and nonadenomas, the relative washout had the highest accuracy rate, and the number of peak enhancing lesions was higher in the portal-phase examination. Since we did not use different scanning times in our study, we were not able to evaluate peak contrast enhancement or compare different scanning times. However, we found that the relative washout rate was more accurate than the absolute washout rate. Foti et al. (22), evaluating different combinations for early- and late-phase CT, found that the best combination was between the portal phase and the 15-minute delayed phase. We used this protocol in the current study as we also do in our routine practice. Similar to our study, Foti et al. (22) also noted higher accuracy rates for relative washout compared to absolute washout. Therefore, it seems more rational to use the relative washout value in daily practice.

Although the washout criterion has been highly emphasized until recently, the latest research suggests that the true accuracy of imaging methods for adenoma characterization is lower than previously reported due to false positive and false negative lesions (18). Caoili et al. (12) found the absolute washout value to be greater than 60% in one pheochromocytoma, one renal cell carcinoma, and one adrenocortical carcinoma. In 45 lesions that were histopathologically analyzed, Park et al. (3) reported one oncocytic tumor, five pheochromocytomas and one pigmented nodular dysplasia, as false-positive adenoma diagnosis due to an absolute washout ≥60%. In the same study, the authors noted low density values that caused false positive adenomas in the noncontrast CT of three cases of adrenal hyperplasia and one endothelial cyst (3). Furthermore, one degenerated adenoma was evaluated as being a false-negative nonadenoma on both noncontrast and dynamic contrast-enhanced CT. In their meta-analysis of 10 studies evaluating a total of 114 pheochromocytomas, Woo et al. (4) indicated that approximately 35% of pheochromocytomas met the criteria for adenoma in CT examinations, and the CT adrenal washout had a high sensitivity (97%) but a relatively low specificity (67%) in differentiating adenomas from pheochromocytomas. In the current study, 50% and 42.85% of 14 pheochromocytomas satisfied the relative and absolute washout criteria, respectively, for an adenoma diagnosis, but it should be noted that we only focused on one aspect of dedicated adrenal CT; i.e., washout values. However, adrenal CT provides more information than washout percentage only. Pheochromocytomas are often inhomogeneous due to cystic change, hemorrhage and necrosis. They tend to be larger than adenomas and have worse border. In addition, criteria such as >130 or >110 HU in the venous phase have been reported to be highly specific for pheochromocytomas (23). Patients presenting with characteristic symptoms of pheochromocytomas (i.e., hypertension, diaphoresis) would be diagnosed easily with biochemical testing, but many adenomas are asymptomatic. For this reason, it may be possible to diagnose pheochromocytoma even if it shows washout in cases where all the components of adrenal CT are evaluated and the clinical characteristics of the patients are known. In the same study, the absolute washout values were compatible with adenomas in two of three oncocytic tumors, one of two adrenocortical carcinomas, and one lung cancer case (4). Although not included in our study group, hypervascular metastases, such as renal cell carcinoma and hepatocellular carcinoma metastases have been reported to mimic the washout characteristics of adenomas (24). Thirty-four of 35 adenomas in our study group were accurately diagnosed using noncontrast CT and dynamic contrast-enhanced CT. Only one adenoma received a false-negative result.

To the best of our knowledge, there are only a limited number of studies in the literature that took pathological findings exclusively as reference in the differentiation of adenoma and nonadenoma lesions (3, 14). Among these studies, ours constitutes the largest sample that underwent adrenalectomy. In the current study, the parameter with the highest accuracy in differentiating adenomas from nonadenomas was the density value on noncontrast CT. This result suggests that adenomas poor in lipids exhibit a dynamic contrast-enhancement pattern that can be confusing with nonadenoma lesions. In early-phase CT examinations, density values ≥45 HU are very sensitive for adenomas, but their specificity is low. In delayed-phase scans, low density values are very sensitive, especially for pheochromocytoma and metastases which are frequently encountered in differential diagnosis. It should be kept in mind that the absolute and relative washout values of lipid-poor adenomas may overlap with some nonadenoma lesions. Increasing the cutoff value for washout also increases the sensitivity but reduces the specificity.

There are some limitations to our study. First, this study has a retrospective design; our findings should be supported with prospective studies. Second, although the diversity of nonadenoma lesions is common, the relatively small number of patients, especially in some subgroups, may be a limitation. Although it was aimed to evaluate the CT contrast characteristics of adrenal lesions, the radiologists being blinded to the clinical and laboratory results of the patients during the evaluation can be considered as a limitation. Although the use of histopathological results as the gold standard in the study is a strength of the study, this situation also causes bias in patient selection. In daily practice, surgery for adenomas is rarely performed (e.g., functionality, suspicious imaging findings). The inclusion of only adenomas that were surgically removed may have led to the exclusion of most fat-rich adenomas. This condition affects the parameters of sensitivity, specificity and diagnostic accuracy.

In conclusion, the current washout criteria used in the differentiation of adenoma

and nonadenoma lesions in dynamic CT can give false-negative and false-positive results. According to the existing criteria, the most reliable parameter in adenoma–nonadenoma differentiation is ≤0 HU non-contrast CT density value.

Conflict of interest disclosure

The authors declared no conflicts of interest.

References

1. Barzon L, Sonino N, Fallo F, Palu G, Boscaro M. Prevalence and natural history of adrenal incidentalomas. Eur J Endocrinol 2003; 149:273–285. [Crossref]
2. Ctvrtlík F, Herman M, Student V, Tichá V, Minarík J. Differential diagnosis of incidentally detected adrenal masses revealed on routine abdominal CT. Eur J Radiol 2009; 69:243–252. [Crossref]
3. Park SW, Kim TN, Yoon JH et al. The washout rate on the delayed CT image as a diagnostic tool for adrenal adenoma verified by pathology: a multicenter study. Int Urol Nephrol 2012; 44:1397–1402. [Crossref]
4. Woo S, Suh CH, Kim SY, Cho JY, Kim SH. Pheochromocytoma as a frequent false-positive in adrenal washout CT: A systematic review and meta-analysis. Eur Radiol 2018; 28:1027–1036. [Crossref]
5. Guo YK, Yang ZG, Li Y et al. Uncommon adrenal masses: CT and MRI features with histopathologic correlation. Eur J Radiol 2007; 62:359–370. [Crossref]
6. Kamiyama T, Fukukura Y, Yoneyama T, Takumi K, Nakajo M. Distinguishing adrenal adenomas from nonadenomas: combined use of diagnostic parameters of unenhanced and short 5-minute dynamic enhanced CT protocol. Radiology 2009; 250:474–481. [Crossref]
7. Johnson PT, Horton KM, Fishman EK. Adrenal mass imaging with multidetector CT: pathologic conditions, pearls, and pitfalls. Radiographics 2009; 29:1333–1351. [Crossref]
8. Ozturk E, Sildiroglu OH, Kantarci M, et al. Computed tomography findings in diseases of the adrenal gland. Wien Klin Wochenschr 2009; 121:372–381. [Crossref]
9. Boland GW, Blake MA, Hahn PF, Mayo-Smith WW. Incidental adrenal lesions: principles, techniques, and algorithms for imaging characterization. Radiology 2008; 249:756–775. [Crossref]
10. Peña CS, Boland GW, Hahn PF, Lee MJ, Mueller PR. Characterization of indeterminate (lipid-poor) adrenal masses: use of washout characteristics at contrast-enhanced CT. Radiology 2000; 217:798–802. [Crossref]
11. Korobkin M, Brodeur FJ, Francis IR, Quint LE, Dunnick RE, Londy F. CT time-attenuation washout curves of adrenal adenomas and nonadenomas. Am J Roentgenol 1998; 170:747–752. [Crossref]
12. Caoili EM, Korobkin M, Francis IR et al. Adrenal masses: characterization with combined unenhanced and delayed enhanced CT. Radiology 2002; 222:629–633. [Crossref]
13. Szolar DH, Korobkin M, Reittner P et al. Adrenocortical carcinomas and adrenal pheochromocytomas: mass and enhancement loss evaluation at delayed contrast-enhanced CT. Radiology 2005; 234:479–485. [Crossref]
14. Park BK, Kim B, Ko K, Jeong SY, Kwon GY. Adrenal masses falsely diagnosed as adenomas on unenhanced and delayed contrast-enhanced computed tomography: pathological correlation. Eur Radiol 2006; 16:642–647. [Crossref]
15. Park BK, Kim CK, Kwon GY, Kim JH. Re-evaluation of pheochromocytomas on delayed contrast-enhanced CT: washout enhancement and other imaging features. Eur Radiol 2007; 17:2804–2809. [Crossref]
16. Patel J, Davenport MS, Cohan RH, Caoili EM. Can established CT attenuation and washout criteria for adrenal adenoma accurately exclude pheochromocytoma? Am J Roentgenol 2013; 201:122–127. [Crossref]
17. Sangwaiya MJ, Boland GW, Cronin CG, Blake MA, Halpern EF, Hahn PF. Incidental adrenal lesions: accuracy of characterization with contrast-enhanced washout multidetector CT-10-minute delayed imaging protocol revisited in a large patient cohort. Radiology 2010; 256:504–510. [Crossref]
18. Park JJ, Park BK, Kim CK. Adrenal imaging for adenoma characterization: imaging features, diagnostic accuracies and differential diagnoses. Br J Radiol 2016; 89:20151018. [Crossref]
19. Kebapci M, Kaya T, Gurbuz E, Adapınar B, Kebapci N, Demirustu C. Differentiation of adrenal adenomas (lipid rich and lipid poor) from nonadenomas by use of washout characteristics on delayed enhanced CT. Abdom Imaging 2003; 28:709–715. [Crossref]
20. Boland GW, Lee MJ, Gazelle GS, Halpern EF, McNicholas MM, Mueller PR. Characterization of adrenal masses using unenhanced CT: an analysis of the CT literature. AJR Am J Roentgenol 1998; 171:201–204. [Crossref]
21. Foti G, Faccioli N, Mantovani W, Malleo G, Manfredi R, Mucelli RP. Incidental adrenal lesions: Accuracy of quadriphasic contrast enhanced computed tomography in distinguishing adenomas from nonadenomas. Eur J Radiol 2012; 81:1742–1750. [Crossref]
22. Foti G, Malleo G, Faccioli N, Guerriero A, Furlani L, Carbognin G. Characterization of adrenal lesions using MDCT washout parameters: diagnostic accuracy of several combinations of intermediate and delayed phases. Radiol Med 2018; 123:833–840. [Crossref]
23. Northcutt BG, Raman SP, Long C et al. MDCT of adrenal masses: Can dual-phase enhancement patterns be used to differentiate adenoma and pheochromocytoma? AJR Am J Roentgenol 2013; 201:834–839. [Crossref]
24. Choi YA, Kim CK, Park BK, Kim B. Evaluation of adrenal metastases from renal cell carcinoma and hepatocellular carcinoma: use of delayed contrast-enhanced CT. Radiology 2013; 266:514–520. [Crossref]