DOI: 10.4274/tjh.galenos.2020.2020.0530
Turk J Hematol 2021;38:222-223

Extremity Necrosis Due to Intrauterine Arterial Ischemia

İntrauterin Arteriyel İskemiye Bağlı Gelişen Ekstremite Nekrozu

Serdar Beken[1], Kerim Sarıyılmaz[2], Eda Albayrak[3], Arzu Akçay[4], Ayşe Korkmaz[1]

[1]*Acıbadem University Faculty of Medicine, Department of Pediatrics, Neonatology Subdivision, İstanbul, Turkey*
[2]*Acıbadem University Faculty of Medicine, Department of Orthopedics, İstanbul, Turkey*
[3]*Acıbadem University Faculty of Medicine, Department of Pediatrics, İstanbul, Turkey*
[4]*Acıbadem University Faculty of Medicine, Department of Pediatrics, Pediatric Hematology Subdivision, İstanbul, Turkey*

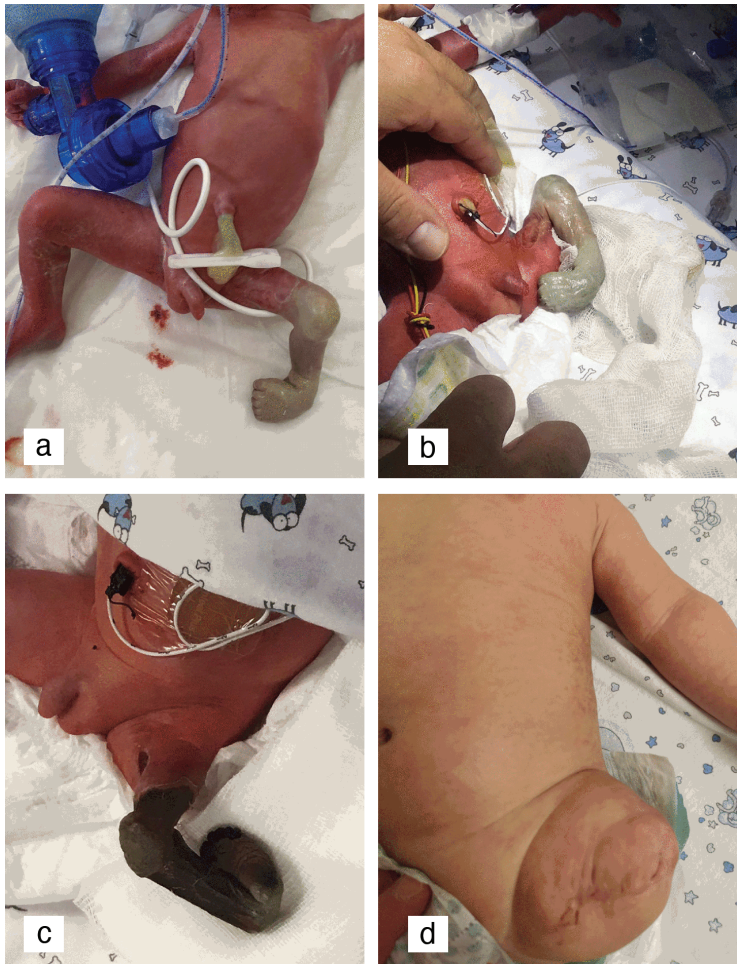

Figure 1. (a-d) Left lower extremity was rudimentary, pale, shorter than the right, and had a club-foot deformity. The demarcation line became clear on the 5th day and amputation was performed under the left hip joint.

©Copyright 2021 by Turkish Society of Hematology
Turkish Journal of Hematology, Published by Galenos Publishing House

Address for Correspondence/Yazışma Adresi: Serdar Beken, M.D., Acıbadem University Faculty of Medicine, Department of Pediatrics, Neonatology Subdivision, İstanbul, Turkey
Phone : +90 532 671 31 96
E-mail : serbeken@gmail.com ORCID: orcid.org/0000-0002-8609-2684

Received/Geliş tarihi: September 1, 2020
Accepted/Kabul tarihi: October 13, 2020

A preterm male infant weighing 1230 g was delivered by cesarean section at $32^{1/7}$ gestational weeks. His twin weighed 1300 g and neither required resuscitation. On physical examination, the left lower extremity was rudimentary, pale, shorter than the right, and had a club-foot deformity. Computerized tomographic angiography demonstrated a bluntly filled femoral artery with no distal passage. During follow-up, the demarcation line became clear on the 5th day and amputation was performed under the left hip joint (Figure 1).

Laboratory tests including homocysteine, folate, prothrombin time, activated partial thromboplastin time, protein C and S activity, fibrinogen, and antithrombin III activity were within normal limits according to gestational age, except for high D-dimer (4.13 mg/dL). Antiphospholipid and anticardiolipin antibodies were also negative. The patient was found to be homozygous for methylenetetrahydrofolate reductase C677T; thrombosis was not observed in histopathological examination. The patient was successfully discharged from the hospital on the 40th day of life.

Arterial ischemia of the limb can be seen after thromboembolic events or vascular interventions [1,2]. Ischemic changes present at birth suggested intrauterine onset causes that might be attributable to occlusive vascular disruption [3]. Diminished blood flow altered normal soft tissue and osseous growth and resulted in ischemia in fetal life, ending with limb loss.

Keywords: Newborn, Ischemia, Arterial

Anahtar Sözcükler: Yenidoğan, İskemi, Arteriyel

Informed Consent: It was received.

Authorship Contributions

Surgical and Medical Practices: S.B., K.S., E.A, A.A., A.K.; Literature Search: S.B., K.S., E.A, A.A., A.K.; Writing: S.B., K.S., A.K.

Conflict of Interest: No conflict of interest was declared by the authors.

Financial Disclosure: The authors declared that this study received no financial support.

References

1. Wang SK, Lemmon GW, Drucker NA, Motaganahalli RL, Dalsing MC, Gutwein AR, Gray BW, Murphy MP. Results of nonoperative management of acute limb ischemia in infants. J Vasc Surg 2018;67:1480-1483.
2. Bekmez S, Beken S, Dinç T, Dursun A, Zenciroğlu A, Dilli D, Okumuş N. Lower extremity amputation in a preterm infant due to MTHFR homozygosity. Genet Couns 2014;25:245-249.
3. Turnpenny PD, Stahl S, Bowers D, Bingham P. Peripheral ischemia and gangrene presenting at birth. Eur J Pediatr 1992;151:550-554.