CASE REPORT

TJG
The Turkish Journal of Gastroenterology

A rare complication of jejunostomy tube: Enteral migration

Volkan ÖZBEN, Adem KARATAŞ, Deniz ATASOY, Arife ŞİMŞEK, Resul SARIGÜL, Osman Baran TORTUM

Department of General Surgery, İstanbul University, Cerrahpaşa Medical School, İstanbul

Feeding jejunal tubes provide an excellent method for enteral nutritional support in cases where the oral route is impossible or insufficient for use. However, several complications may result from the placement of the tube. Detachment of the tube and migration through the intestine is a very rare complication. We report herein a 65-year-old male patient in whom a jejunal feeding tube (28-F Pezzer catheter) was placed two months before due to unresectable gastric cancer. He presented with disappearance of the tube and abdominal pain. Radiological investigations showed the tube localized in the lumen of the small intestine and its advancement through the gut. Conservative measures were taken as there was neither intestinal obstruction nor peritonitis. The tube passed spontaneously through the rectum 18 days later. One should be careful during the placement of jejunostomy tubes, and health care providers and patients should be instructed well in the care of feeding enterostomy tubes in order to prevent this complication.

Key words: Jejunostomy tube, enteral migration, conservative treatment

Jejunostomi tüpüne ait nadir bir komplikasyon: Bağırsak lümenine migrasyon

Beslenme jejunostomi tüpü oral yoldan beslenmenin yetersiz veya imkansız olduğu durumlarda enteral nütrisyon desteğinin sağlanması açısından mükemmel bir yöntemdir. Fakat, bu tüplerin yerleştirilmesine bağlı olarak bazı komplikasyonlar ortaya çıkabilmektedir. Tüpün yerinden çıkması ve bağırsak içerisine migrasyonu çok nadir görülen bir komplikasyondur. Unrezektabl mide tümörü nedeni ile jejunal beslenme tüpü yerleştirilen 65 yaşında erkek hasta iki ay sonra tüpün kaybolması ve karın ağrısı şikayetleri ile başvurdu. Radyolojik incelemelerde tüpün ince bağırsak içerisinde olduğu ve distale doğru ilerlediği izlendi. Takiplerinde bağırsak tıkanıklığı veya peritonit bulgusu gelişmemesi üzerine konservatif tedavi uygulanan hasta 18. günde tüpü kendiliğinden rektal yoldan çıkardı. Bu komplikasyonun önlenebilmesi için jejunostomi tüplerinin yerleştirilmesi sırasında dikkatli olunmalı, sağlık çalışanları ve hastalar enteral tüplerin bakımı hakkında eğitilmelidir.

Anahtar kelimeler: Jejunostomi tüpü, bağırsak içine migration, konservatif tedavi

INTRODUCTION

Enteral nutrition has become increasingly popular because of improved nutritional formulas, advances in catheter technology and the development of less invasive techniques for the placement of feeding tubes for this purpose. Jejunostomy tubes (JTs) are being used more frequently than before (1) in cases where the oral route is impossible or insufficient for use. As a result, complications of feeding JT (mechanical, infectious, gastrointestinal, and metabolic) have emerged (2). Among these, migration feeding JT into the gut is very rare. The purpose of this report is to present a patient with this complication.

CASE REPORT

A 65-year-old male patient presented to our emergency surgery clinic due to the disappearance of a feeding JT. He had no symptoms apart from a mild abdominal pain in the right lower quadrant. His medical history revealed an unresectable gas-

Address for correspondence: Volkan ÖZBEN
İstanbul University, Cerrahpaşa Medical School, Department of General Surgery, İstanbul, Turkey
Phone: + 90 462 747 07 07
E-Mail: volkanozben@yahoo.co.uk

Manuscript received: 03.11.2009 **Accepted:** 10.12.2009

Turk J Gastroenterol 2011; 22 (1): 83-85
doi: 10.4318/tjg.2011.0162

tric cancer with hepatic and transverse colonic invasions diagnosed on explorative laparoscopy two months prior to his admission. During this procedure, laparoscopy-assisted Stamm jejunostomy was performed for enteral nutrition using 28-F silicone Pezzer catheter (Silastic Malecot catheter, Dow Corning, Midland, MI, USA) with its mushroom-like tip removed. Physical examination revealed jejunostomy tract in the left upper quadrant without any JT in place. The skin site around this tract was eroded and there were no fixation sutures. There was mild tenderness in the right iliac fossa with no signs of peritonitis, intestinal obstruction or gastrointestinal bleeding. Laboratory findings were as follows: white blood cells (WBC): 9,700/mm^3 and hematocrit: 38.5%. Elevated liver enzymes and hyperbilirubinemia were consistent with the liver metastases. Abdominal computed tomography (CT) with oral contrast demonstrated the tube and the ampule, which was used by the patient to plug the external part of this tube between enteral feedings, within the distal ileum (Figure 1). Fistulography through the jejunostomy tract showed the passage of contrast material into the jejunum with no intra-abdominal leakage. Thus, a new JT was inserted through the previous tract. The patient was placed under close follow-up with liquid diet and Vaseline liquid was administered through the new JT intermittently to ease the journey of the tube through the intestine. Follow-up CT scan, performed nine days after his admission, showed that the migrated tube was lodged in the right colon with no sign of ileus (Figure 2). During follow-up, the ampule was passed spontaneously; however, the tube was observed to be impacted in the colon on serial abdominal radiographs. Colonoscopic retrieval, performed on the 17th day, was unsuccessful due to the kinking of the tube (Figure 3). However, it was possible to dislodge the end of the tube from the edematous mucosa with a snare. The patient passed the tube spontaneously along with feces on the 18th day (Figure 4) and he was discharged uneventfully.

DISCUSSION

In the setting of a functional and non-obstructed gut, maintenance of gut structure and function, nourishment of enterocytes, efficient use and safe administration of nutrients, and reduced infection rates in severely ill patients are the well-known advantages of enteral feeding in patients who are unable to be fed orally. Because of these advantages, placement of intestinal feeding tubes is com-

Figure 1. Abdominal CT scan with oral contrast at admission shows the intraluminal localization of the feeding jejunal tube (arrow) and the ampule (arrowhead) in the ileum.

monly indicated for those undergoing major sur-

Figure 2. Follow-up CT scan shows the impaction of the jejunal tube (arrow) in the right colon with no sign of ileus.

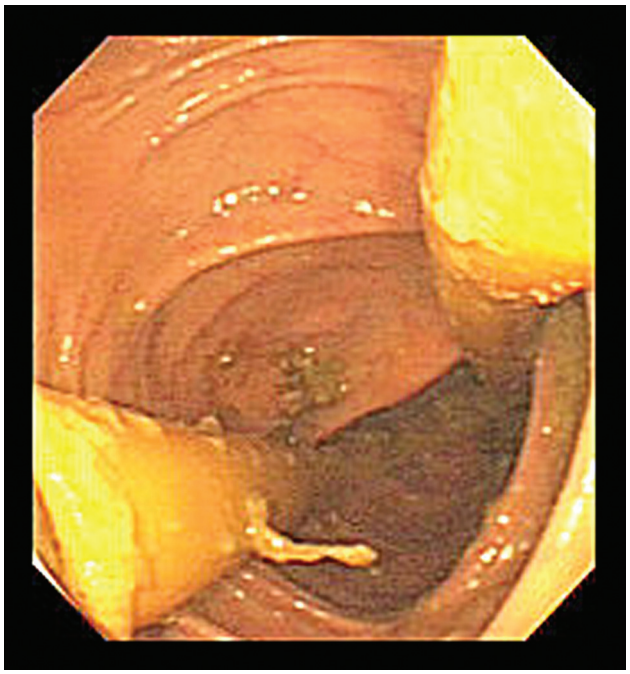

Figure 3. Colonoscopic view of the impacted jejunal tube due to kinking.

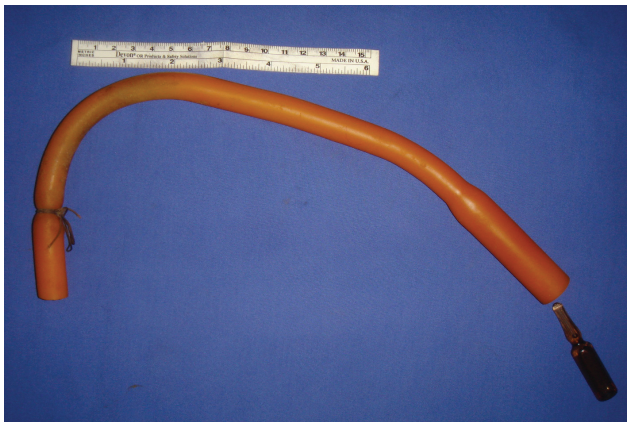

Figure 4. The feeding jejunal tube (28-F silicone Pezzer catheter) measuring 37 cm in length and the ampule that was used for plugging the external end of the tube.

gery of the upper digestive tract (2). Although feeding JT provides surgeons with an excellent method for providing nutritional support, there are several mechanical complications associated with this procedure, including complications resulting from the placement of these tubes and problems related to their location or function (3).

Detachment of an enteral feeding tube from the skin and migration into the intestine is a rare complication. In the literature, this potential complication was described in several case reports, which drew attention to the need for appropriate care of these tubes (4-7). Polychronidis et al. (6) reported a nearly identical case that concerned enteral migration of a 28-F Pezzer catheter two months after its insertion. Due to the patient's poor condition, conservative measures including administration of paraffin oil through the new JT were taken and the patient passed the catheter after five days. In our case, the patient was kept under close observation and liquid Vaseline was administered intermittently through the new JT after the patency of the fistulous tract was confirmed by fistulography with water-soluble contrast material. Serial plain abdominal radiographs demonstrated a steady progress of the tube through the gut until it reached the right hemicolon. Based on our experience, although colonoscopic retrieval was unsuccessful, dislodgement of the end of the tube from the edematous mucosal segment facilitated its journey, and the patient eventually passed the tube one day after the colonoscopy. The passage of an 18-F Levine's JT occurred on the 20th day in a similar case reported by Bose et al. (7).

What causes the migration of feeding JT into the intestinal lumen is not well documented in the literature. We speculate that inadequate suturing of the tube to the skin and/or skin erosion at the fixation suture site over time in the presence of hyperactive bowel may predispose the distal migration. To overcome this complication, Polychronidis et al. (6) recommended the use of an external retention disk and a retention ring over the catheter during the placement of feeding tubes. The use of ampules for plugging the tubes between the enteral feeding periods, as in our case, might complicate the clinical scenario even more, so this technique should be discouraged. Instead, we recommend the use of a plastic material for appropriate plugging of the external end of the Pezzer catheter.

Secure fixation of the tube to the skin should be performed at the end of the JT placement to prevent this rare, but potentially fatal complication of feeding JT migration. Patients and health care providers should be instructed well in the care of feeding enterostomy tubes. When this complication occurs, conservative treatment with close follow-up should be performed provided there are no signs of acute abdomen.

Acknowledgement: *This manuscript was presented in the 9th Endoscopic Laparoscopic surgery Congress and published in the abstract form.*

REFERENCES

1. Carucci LR, Levine MS, Rubesin SE, et al. Evaluation of patients with jejunostomy tubes: imaging findings. Radiology 2002; 223: 241-7.
2. Tapia J, Murguia R, Garcia G, et al. Jejunostomy: techniques, indications, and complications. World J Surg 1999; 23: 596-602.
3. Liao GS, Hsieh HF, Wu MH, et al. Knot formation in the feeding jejunostomy tube: a case report and review of the literature. World J Gastroenterol 2007; 13: 973-4.
4. Kamar M, Bar-Dayan A, Zmora O, Ayalon A. Small bowel obstruction from a dislodged feeding tube. Age Ageing 2004; 33: 81-2.
5. Prahlow JA, Barnard JJ. Jejunostomy tube failure: malnutrition caused by intraluminal antegrade jejunostomy tube migration. Arch Phys Med Rehabil 1998; 79: 453-5.
6. Polychronidis A, Karayiannakis AJ, Perente S, et al. Enteral migration of a Pezzer tube after a feeding jejunostomy: report of a case. Surg Today 2003; 33: 620-2.
7. Bose AC, Shankar RR, Kate V, Ananthakrishnan N. Spontaneous antegrade enteral migration of feeding jejunostomy tube. Indian J Gastroenterol 2005; 24: 74.