Turk J Gastroenterol 2007; 18 (2): 115-118

A case of herpes simplex hepatitis with hepatic nodules in an immunocompetent patient

‹mmunkompetan hastada karaci¤erde nodullerle seyreden HSV hepatit olgusu

Öznur AK[1], Oya UYGUR BAYRAMİÇLİ[2], Serdar ÖZER[1], Bedia YILMAZ[1]

Departments of [1]Infections Diseases and Clinical Microbiology, [2]Gastroenterology, Dr. Lütfi Kırdar Kartal Education and Training Hospital, İstanbul

Herpes simplex hepatitis is a rare cause of acute hepatitis in immunocompetent patients. Herpes hepatitis presents with nonspecific symptoms like fever, loss of appetite, vomiting, nausea and abdominal pain. Elevated transaminase values with leukopenia, relatively low bilirubin level and mucosal herpetic lesions often provide clues to the diagnosis. We describe an immunocompetent woman with herpes simplex hepatitis presenting with multiple hypodense lesions in the liver and mucocutaneous herpetic lesions.

Key words: Herpes hepatitis, hepatic nodules, mucocutaneous lesions

Herpes simpleks virüsler immunkompetan kişide nadiren akut hepatit sebebidir. Herpes hepatit ateş, iştahsızlık, bulantı-kusma, karın ağrısı gibi nonspesifik semptomlar ile başlar. Transaminaz yüksekliği, lökopeni, düşük bilirubin düzeyleri ve mukokutanöz lezyonların varlığı tanıda yol gösterici olabilir. Bu yazıda da karaciğerde multiple hipodens lezyonlar ve mokozal herpetik lezyonlarla karakterize bir herpes hepatit olgusu sunulmuştur.

Anahtar kelimeler: Herpes hepatit, karaci¤erde nodüller, mukozal lezyon

INTRODUCTION

Herpes simplex (HS) hepatitis is a rare cause of acute hepatitis in immunocompetent patients; it has been reported mostly in immunocompromised patients, in posttransplantation, together with corticosteroid treatment and in pregnant women (1, 2). HS hepatitis presents with nonspecific symptoms like fever, loss of appetite, vomiting, nausea and abdominal pain. Laboratory findings are leukopenia, elevation of transaminases and coagulopathy. The presence of mucocutaneous lesions is typical for HS virus (HSV) types 1 and 2, but might not be present in every case (2-4). In some cases, there can be multiple hypodense areas on computed tomography (CT) or magnetic resonance imaging (MRI), which must be differentiated from metastatic tumors and pyogenic abscesses (2, 5).

We report an immunocompetent patient with herpes hepatitis presenting with multiple hypodense lesions in the liver.

CASE REPORT

A 35-year-old woman presented in March 2002 at another institution with abdominal pain, and was hospitalized with the diagnosis of acute hepatitis. She developed deep jaundice, dark urine and dyspnea after three days and was referred to another hospital. She had hepatorenal syndrome with high fever, tachycardia, hypotension, deep jaundice, vesicles on the lips and oral mucosa, and hepatomegaly. Oral lesions were diagnosed as herpetic gingivostomatitis and she was given acyclovir topical therapy. Because of thrombocytopenia and prolongation of prothrombin time, fresh-frozen plasma and platelets suspension were given. Viral serology and autoantibodies were negative, and there was no history of hepatotoxic drug or herbal medicine usage. To exclude mechanic jaundice, imaging of the liver was performed, and multiple nodular lesions larger than 15 mm were seen in the liver on ultrasound and MRI (Figure 1). The patient was then referred to our hospital, which is specialized in oncology, with the diagnosis of liver

Address for correspondence: Öznur AK
Doğu Cad. Kral Sitesi A Blok D: 12 Rahmanlar, İstanbul, Turkey
Phone: +90 216 387 07 35
E-mail: akoznur@yahoo.com

Manuscript received: 14.06.2006 **Accepted:** 14.12.2006

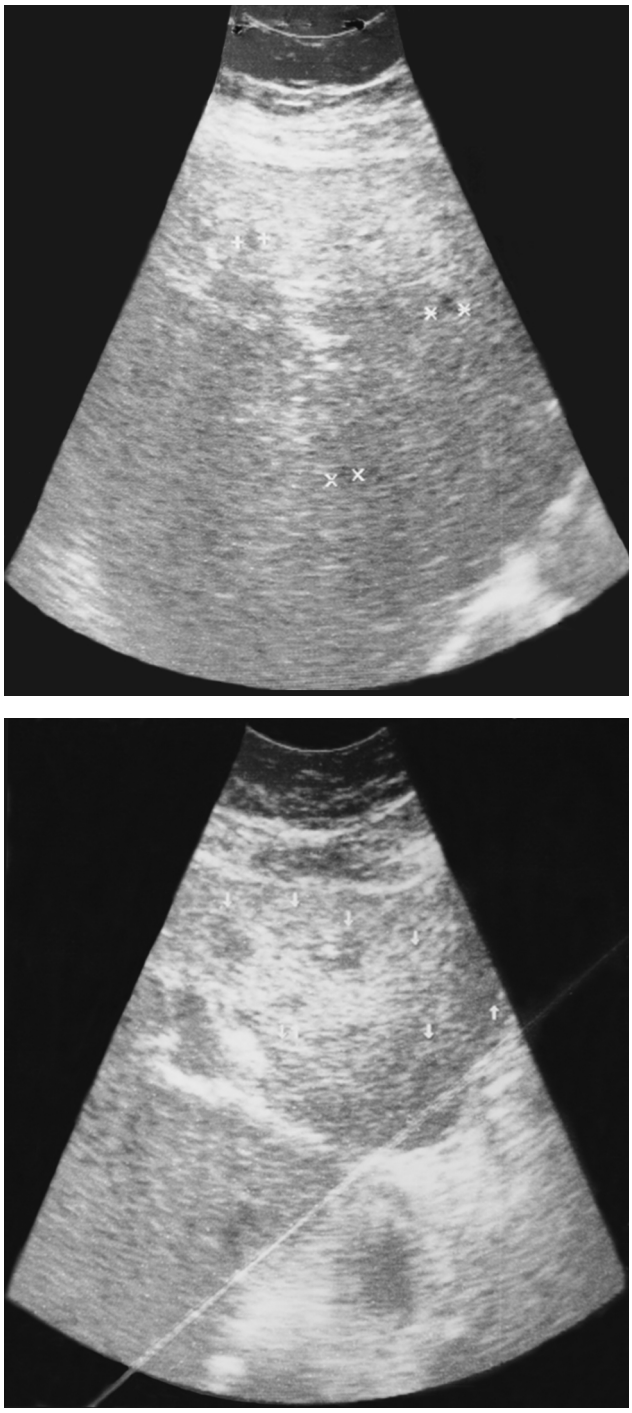

Figure 1-2. Ultrasonography findings of the liver in the patient

tumor. Physical examination was unremarkable except for severe hepatomegaly and oral mucocutaneous lesions. The initial and following laboratory values are shown in Table 1. *Entamoeba histolytica and Echinococcus granulosus* indirect hemagglutination (IHA) tests were negative, and tumors markers were normal. In order to obtain a pathological diagnosis, we performed a fine needle aspiration biopsy of the hepatic lesion under CT guidance. There was no growth in aerobic and anaerobic cultures of the material, but cytology revealed foci of organized microabscesses. Hemocultures of the patient were also negative. Because of the oral mucocutaneous lesions, we looked for HSV type 2 IgM and IgG enzyme immunoassays (ELISA) and results were found positive. There was a four-fold increase in the titer of HSV type 2 IgG after four weeks. The patient was treated symptomatically and liver lesions regressed after one month. We followed the patient for two years and liver ultrasound and biochemical values were all completely normal.

Table 1. Laboratory values in the patient with herpes hepatitis

	Initial	After 2 weeks	Normal ranges
Leukocyte /mm^3	2300	7300	4000-10000
Platelet /mm^3	70000	309000	130000-400000
ALT/AST (IU/L)	223/328	28/36	0-32/0-31
ALP/GGT (IU/L)	368/91	249/40	0-270/10-50
Total bilirubin (mg/dl)	4.5	2.5	0.0-1.1
Prothrombin time/sec	18	15	11.3-16.1
Sedimentation rate (mm/h)	68	62	0-20 mm

ALT: Alanine aminotransferase, AST: Aspartate aminotransferase, ALP: Alkaline phosphatase, GGT: Gamma glutamyl transpeptidase

DISCUSSION

Primary and recurrent infections of HSV types 1 and 2 can be accompanied by acute hepatitis in rare cases. The first case of herpes hepatitis was reported in a pregnant woman in the third trimester by Flewett et al. in 1969 (6). Acute herpes hepatitis has been reported mostly in pregnant women, in patients receiving immunosuppressive agents or corticosteroids, and in transplanted patients, but also rarely in immunocompetent patients. It has a fulminant course with a high mortality, but there are also cases with spontaneous complete recovery. Herpes hepatitis presents with nonspecific symptoms like fever, headache, nausea and vomiting, and abdominal pain, as in our case. There is leukopenia, elevation of liver enzymes and a mild elevation of bilirubin levels with coagulopathy. The triad of fever, elevation of transaminases and presence of leukopenia is suggested to be typical for herpes hepatitis (1-3). Kaufman et al. (3), in a review of 52 cases, reported fever in 82%, right hypochondrial pain and tenderness in 33%, nausea-vomiting in 18%, and oral and genital

mucocutaneous lesions in 57%. Oral and/or genital mucocutaneous lesions are diagnostic for herpes hepatitis but might not be present in every case. The combination of hepatitis and mucocutaneous lesions has been reported at different rates. Schlien et al. (7) reported this combination at a frequency of 52%, while Aboguddah et al. (8) reported 69% and Young et al. 49% (9). The localization of mucocutaneous lesions may vary. Sharma et al. (10) found these lesions in the genital region in pregnant women (13/15) and in the oropharyngeal region in nonpregnant women (12/18). Kaufman et al. (3) reviewed 52 cases and found steroid therapy in 10 cases, transplantation in 9 cases and pregnancy in 9 cases as the most frequent predisposing factor, whereas no risk factor was determined in 8 cases. They found a white blood cell count below 5000/mm^3 in 43% of patients, and platelet count below 150,000/mm^3 and disseminated intravascular coagulopathy in 35%. Our case received fresh-frozen plasma and platelets suspension at the first hospital, which points out the presence of thrombocytopenia and coagulopathy.

Fahy et al. showed multiple, nodular hypodense lesions in the liver in some cases of herpes hepatitis with imaging modalities like CT or MRI (2). This finding is not specific for herpes hepatitis and might also accompany diffuse metastatic abscesses or multifocal hepatoma. Therefore, they must be differentiated from malignancies and pyogenic abscesses. Our case was also diagnosed with malignancy at the hospital which referred her to us. The absence of viral markers, negative hemagglutination inhibition tests for *Echinococcus granulosus* and *Entamoeba histolytica*, sterile nature of biopsy material, presence of foci of microabscesses and gingivostomatitis led us to perform serological tests for herpes. Jacques et al. described four pregnant women with herpes hepatitis with fever, elevation of transaminases and multiple hypodense hepatic lesions on CT (1). In the differential diagnosis, they considered septic emboli and metastases, and the definitive diagnosis was obtained by immunoperoxidase stain of liver tissue.

Herpes simplex virus hepatitis is a difficult diagnosis in the absence of mucosal lesions and most of the cases are diagnosed at autopsy (2). In the series by Kaufman et al. (3), only 23% of the cases could be diagnosed before death. The histologic characteristic of the liver lesions is usually a combination of microabscesses with or without hemorrhage and hepatocellular necrosis (11). Isolation of the virus or the HSV DNA is the best method of diagnosis, but serological tests like ELISA or immunofluorescence might also be used. With these tests, there are IgM antibodies in the acute phase and/or demonstration of a four-fold or more rise in IgG antibodies in convalescence (11, 12).

The role of acyclovir in the treatment of herpes hepatitis is controversial. Some authors report that there is no difference between acyclovir versus no treatment with regard to mortality and recovery, but there are also some contradictory studies. Severe cases of fulminant hepatitis had high mortality even if they had received acyclovir, while other cases of acute hepatitis had a good outcome even without treatment (2, 10). It is not well known if acute herpes hepatitis is a self-limiting disease despite reports of recovery without any treatment, as in our case.

This report is interesting since it involves an immunocompetent patient with herpes hepatitis presenting with multiple hypodense lesions in the liver. The patient recovered completely without any antiviral treatment. In cases with hepatitis and mucocutaneous lesions, herpes hepatitis must be considered in the differential diagnosis.

REFERENCES

1. Jacques SM, Qureshi F. Herpes simplex virus hepatitis in pregnancy: a clinicopathologic study of three cases. Hum Pathol 1992; 23: 83-7.
2. Fahy RJ, Crouser E, Pacht ER. Herpes simplex type 2 causing fulminant hepatic failure. South Med J 2000; 93: 1212-6.
3. Kaufman B, Gandhi SA, Louie E, et al. Herpes simplex virus hepatitis: case report and review. Clin Infect Dis 1997; 24: 334-8.
4. Wesley FR, Short S, Weissmann D. Fulminant hepatitis during herpes simplex virus infection in apparently immunocompetent adults: report of two cases and review of the literature. Clin Infect Dis 1997; 24: 1191-4.
5. Tan G, Frankel WL, Suster S. Multiple foci of necrosis in the liver in a patient with T-cell lymphoma. Pathologic quiz case. Arch Pathol Lab Med 2003; 127: 1049-50.
6. Flewett TH, Parker RGF, Philip WM. Acute hepatitis due to herpes simplex virus hepatitis in an adult. J Clin Pathol 1969; 22: 60-6.
7. Schlien RD, Meyers S, Lee JA, et al. Fulminant herpes simplex hepatitis in a patient with ulcerative colitis. Gut 1988; 29: 257-61.
8. Aboguddah A, Stein HB, Phillips P, et al. Herpes simplex hepatitis in a patient with psoriatic arthritis taking prednisone and methotrexate. Report and review of the literature. J Rheumatol 1991; 18: 1406-12.

9. Young EJ, Chafizadeh E, Oliveira VL, et al. Disseminated herpes virus infection during pregnancy. Clin Infect Dis 1996; 22: 51-8.
10. Sharma S, Mosunjac M. Herpes simplex hepatitis in adults. A search for muco-cutaneous clues. J Clin Gastroenterol 2004; 38: 697-704.
11. Yaziji H, Hill T, Pitman TC, et al. Gestational herpes simplex virus hepatitis. South Med J 1997; 90: 347-51.
12. Corey L. Herpes simplex virus. In: Mandell GL, Bennett JE, Dolin R, eds. Principles and Practice of Infectious Diseases. 5th ed. Philadelphia: Churchill Livingstone 2005; 1762-80.